# ABDOMINAL SURGERY

# ABDOMINAL SURGERY

# ABDOMINAL

BY FORTY-ONE AUTHORS

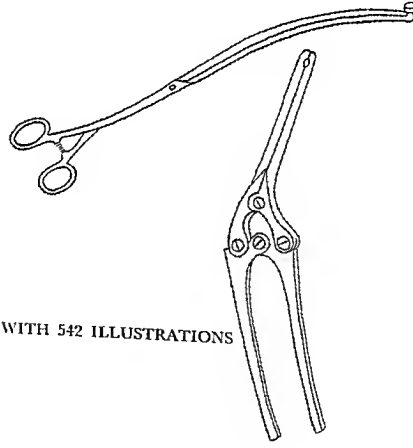

WITH 542 ILLUSTRATIONS

# SURGERY

*Edited by* ARTHUR W. ALLEN, M D

*and* DAVID WOOLFOLK BARROW, M D

*Foreword by* FREDERICK A COLLER, M D

PAUL B HOEBER, INC.
Medical Division of Harper & Brothers

The contributors unite in dedicating this book
to its editor, the late Dr Arthur W Allen
staunch friend, inspiring teacher,
great gentleman, superlative and devoted surgeon

---

ABDOMINAL SURGERY

*Copyright © 1961 by Paul B Hoeber Inc*
*Medical Division of Harper & Brothers*

*Printed in the United States of America*
*Designed by Nancy Etheredge*

*All rights reserved*
*For information address Paul B Hoeber, Inc*
*Medical Division of Harper & Brothers*
*49 East 33rd Street, New York 16 N Y*

*Library of Congress catalog card number 61 15210*
E L

# CONTENTS


CONTRIBUTING AUTHORS vii

FOREWORD xi
*Frederick A Coller*

PREFACE xiii

CHAPTER 1 ABDOMINAL INCISIONS 1
*Leon Goldman and Edwin J Wylie*

CHAPTER 2 PREOPERATIVE PREPARATION 24
*Walter G Maddock and T Howard Clarke*

CHAPTER 3 ANESTHESIA IN ABDOMINAL SURGERY 53
*John Adriani*

CHAPTER 4 POSTOPERATIVE CARE AND COMPLICATIONS IN ABDOMINAL SURGERY 77
*Alton Ochsner and John B Blalock*

CHAPTER 5 HERNIA 107
*Amos R Koontz*

CHAPTER 6 NONPENETRATING WOUNDS OF THE ABDOMEN 156
*John H Morton J Raymond Hinshaw and John J Morton Jr*

CHAPTER 7 PENETRATING WOUNDS OF THE ABDOMEN 164
*Leonard D Heaton and Donald H Glew Jr*

CHAPTER 8 SURGERY OF THE STOMACH 195
*Samuel F Marshall and Herbert D Adams*

CHAPTER 9 SURGERY OF THE DUODENUM 242
*James G Gray and John D Stewart*

CHAPTER 10 DISEASES OF THE LIVER EXCLUSIVE OF THE BILIARY TRACT 266
*Charles G Child, III, and Arthur J Donovan*

CHAPTER 11. SURGERY OF THE GALLBLADDER 311
*Frank Glenn*

CHAPTER 12 SURGERY OF THE BILE DUCTS 349
*Waltman Walters*

CHAPTER 13. BENIGN BILIARY STRICTURE 363
*William P Longmire, Jr, and Harvey N Lippman*

CHAPTER 14 SURGERY OF THE PANCREAS 399
*Dan W Elliott, Roger D Williams, and Robert M Zollinger*

CHAPTER 15 SURGERY OF THE SPLEEN 443
*M S DeWeese and Frederick A Coller*

CHAPTER 16 SURGERY OF THE SMALL INTESTINE 466
*Glenn E Behringer and Claude E Welch*

CHAPTER 17 DISEASES OF THE APPENDIX 508
*David Woolfolk Barrow*

CHAPTER 18 PRIMARY TUMORS OF RETROPERITONEUM, MESENTERY, AND OMENTUM 519
*Shaun Purdy Holman and Emile F Holman*

CHAPTER 19 NEOPLASMS OF THE COLON 525
*Joel W Baker and George Hugh Lawrence*

CHAPTER 20 ULCERATIVE COLITIS 548
*Henry W Cave and James E Thompson*

CHAPTER 21. DIVERTICULOSIS AND DIVERTICULITIS OF THE COLON 591
*Edward S Judd and John M Waugh*

CHAPTER 22 TUMORS OF THE RECTUM AND ANUS 604
*Rupert B Turnbull, Jr, and George Crile, Jr*

INDEX 641

# CONTRIBUTING AUTHORS

HERBERT D ADAMS, M D, F A C S
*Staff Surgeon, The Lahey Clinic, New England Baptist and New England Deaconess Hospitals, Boston, Consultant, U S Naval Hospital, Chelsea, Massachusetts*

JOHN ADRIANI, M D
*Professor of Surgery, Tulane University School of Medicine, Clinical Professor of Surgery and Pharmacology, Louisiana State University School of Medicine, Director, Department of Anesthesiology, Charity Hospital, New Orleans*

JOEL W BAKER, M D, F A C S
*Chairman, The Mason Clinic, Chief of Surgery, Virginia Mason Hospital, Seattle*

DAVID WOOLFOLK BARROW, M D, F A C S
*Formerly Professor of Surgery, Medical School of Marquette University, Consultant in Surgical Research and Development, Letterman Army Hospital, San Francisco*

GLENN E BEHRINGER, M D
*Assistant Surgeon, Harvard Medical School, Instructor in Surgery, Boston University School of Medicine, Assistant in Surgery Massachusetts General Hospital Attending Surgeon, U.S Veterans Hospital, Boston*

JOHN B BLALOCK, M D, F A C S
*Member of Staff, Ochsner Clinic and Ochsner Foundation Hospital, Assistant Professor of Surgery, Tulane University School of Medicine, New Orleans*

HENRY W CAVE, M D, F R C S (Ed Hon)
*Emeritus Clinical Professor of Surgery, Columbia University College of Physicians and Surgeons and Emeritus Chief of Surgery, The Roosevelt Hospital, New York City*

CHARLES G CHILD, III, M D
*Professor and Chairman of the Department of Surgery, University of Michigan Medical School, Ann Arbor*

T HOWARD CLARKE, M D, F A C S
*Associate Professor of Surgery, Northwestern University Medical School, Senior Attending Surgeon Chicago Wesley Memorial Hospital, Chicago*

FREDERICK A COLLER, M D, F A C S, F R C S (Hon Edin), F R C S (Hon Eng)
*Professor of Surgery, Emeritus, University of Michigan, formerly Chairman, Department of Surgery University of Michigan Medical School, Ann Arbor*

GEORGE CRILE Jr MD FACS
*Head of Department of General Surgery, Cleveland Clinic Foundation and the Frank E Bunts Educational Institute Cleveland*

M S DeWEESE MD MS Surg, FACS
*Associate Professor of Surgery University of Michigan Medical School Ann Arbor*

ARTHUR J DONOVAN, MD
*Assistant Clinical Professor of Surgery, Tufts University School of Medicine, First Surgical Service Boston City Hospital, Boston*

DAN W ELLIOTT, MD, MMSc
*Associate Professor of Surgery The Ohio State University College of Medicine Columbus*

FRANK GLENN, MD, FACS
*Lewis Atterbury Stimson Professor of Surgery and Chairman of the Department of Surgery Cornell University Medical College, Surgeon in Chief The New York Hospital New York City*

DONALD H GLEW, Jr, Major, MC
*Chief of Surgery U.S Army Hospital Aberdeen Proving Ground, Maryland*

LEON GOLDMAN MS (Physiol), MD, FACS
*Professor and Chairman of the Department of Surgery, University of California School of Medicine and Chief Surgeon Herbert C Moffitt—University of California Hospital San Francisco*

JAMES G GRAY, MD
*Staff Surgeon St Joseph's Hospital and Arnot Ogden Memorial Hospital, Elmira New York*

LEONARD D HEATON, Lieutenant General FACS
*The Surgeon General United States Army Washington, DC*

J RAYMOND HINSHAW, MD, DPhil (Oxon)
*Assistant Professor of Surgery University of Rochester School of Medicine and Dentistry Associate Surgeon Strong Memorial Hospital, Rochester, New York*

EMILE F HOLMAN MD MA (Oxon), FACS
*Professor and Chairman, Department of Surgery, Emeritus, Stanford University School of Medicine San Francisco*

SHAUN PURDY HOLMAN, MD
*San Francisco*

EDWARD S JUDD MD, MS Surg., FACS
*Consultant Section of Surgery, Mayo Clinic Professor of Surgery Mayo Foundation Graduate School University of Minnesota Rochester, Minnesota*

AMOS R KOONTZ, A M, M D, D Sc, F A C S
*Emeritus Assistant Professor of Surgery, Johns Hopkins University School of Medicine, Staff Surgeon, Johns Hopkins Hospital, Union Memorial Hospital, Church Home and Hospital, and Hospital for the Women of Maryland, Baltimore, Consultant in Surgery for the Surgeon General of the Army and for The Surgeon, Second Army*

GEORGE HUGH LAWRENCE, M D, F A C S
*Surgeon Virginia Mason Hospital and Mason Clinic, Seattle*

HARVEY N LIPPMAN M D
*Assistant Clinical Professor of Surgery, University of California at Los Angeles, School of Medicine Associate Attending Surgeon, Cedars of Lebanon Hospital Los Angeles*

WILLIAM P LONGMIRE, Jr, M D
*Professor and Chairman, Department of Surgery University of California at Los Angeles School of Medicine, Surgeon in Chief University of California Hospital, Los Angeles*

WALTER G MADDOCK M S, M D F A C S
*Professor of Surgery, Northwestern University Medical School, Chairman Department of Surgery Chicago Wesley Memorial Hospital, Chicago*

SAMUEL F MARSHALL M D
*Surgeon Formerly Lahey Clinic New England Baptist and New England Deaconess Hospitals Boston*

JOHN H MORTON M D, F A C S
*Assistant Professor of Surgery and Surgical Anatomy, University of Rochester School of Medicine and Dentistry Associate Surgeon, Strong Memorial and Rochester Municipal Hospitals Rochester, New York*

JOHN J MORTON Jr, M D, D Sc (Hon) Amherst F A C S
*Professor Emeritus of Surgery University of Rochester School of Medicine and Dentistry Formerly Chairman and Surgeon in Chief, Strong Memorial and Rochester Municipal Hospitals Rochester, New York*

ALTON OCHSNER M D
*Director of Surgery Ochsner Clinic and Ochsner Foundation Hospital Professor of Clinical Surgery Tulane University School of Medicine, New Orleans*

JOHN D STEWART, M D
*Professor of Surgery, University of Buffalo School of Medicine, Head, Department of Surgery E J Meyer Memorial Hospital Buffalo*

JAMES E THOMPSON, M D F A C S
*Associate Clinical Professor of Surgery Columbia University College of Physicians and Surgeons, Chief of Surgery Roosevelt Hospital New York City*

RUPERT B TURNBULL Jr M D C M, F A C S
*Staff Surgeon Cleveland Clinic Foundation and Frank J Lahey Foundation Institute, Cleveland Clinic Hospital Cleveland*

WALTMAN WALTERS, M D, M S (Surg), D Sc, F A C S
*Consultant, Section of Surgery, Mayo Clinic, Professor of Surgery, Mayo Foundation Graduate School, University of Minnesota, Rochester, Minnesota*

JOHN M WAUGH, M D, M S, F A C S
*Professor of Surgery and Chief of General Surgery, Mayo Foundation Graduate School, University of Minnesota, Chief of General Surgery, Head of a Section on General Surgery, The Mayo Clinic, Surgeon to Affiliated Hospitals of the Mayo Clinic Rochester, Minnesota*

CLAUDE E WELCH, M D, F A C S
*Visiting Surgeon, Massachusetts General Hospital, Clinical Associate in Surgery, Harvard Medical School, Boston*

ROGER D WILLIAMS, M M Sc, M D
*Associate Professor of Surgery, The Ohio State University College of Medicine, Columbus*

EDWIN J WYLIE, M D
*Associate Professor of Surgery, University of California School of Medicine, Attending Surgeon, San Francisco General Hospital and University of California Hospital, San Francisco*

ROBERT M ZOLLINGER, M D, F A C S
*Professor and Chairman, Department of Surgery, The Ohio State University College of Medicine, Columbus*

# FOREWORD

This book on abdominal surgery may well be considered a memorial volume to its Senior Editor, Arthur Wilburn Allen whose untimely death before all of the chapters were completed deprived the contributors of his final helpful comments and lost to its readers the wisdom and charm of his surgical philosophy that were to have appeared in this Foreword The entire concept of the work the chapter headings and content the choice of contributors and its objective were largely his and it is hoped by those who contributed to it that those who read it will feel that his ideals spirit and experience shine through although he is no longer with us in person He was particularly fitted to plan and to direct a presentation of surgery of the abdomen since he lived taught and practiced surgery during the vital time of surgery s greatest evolution While he maintained a wide and vivid interest in all fields of surgical progress his principal contributions and main interests were in surgical problems of disease of abdominal organs

At the time he started his professional career surgery was still in the height of the emphasis of its mechanistic phase that had been made possible by anesthesia antisepsis and asepsis The roentgen ray with the use of contrast media was beginning to make its new and revolutionary contributions to diagnosis of lesions of the gastrointestinal and biliary tracts New vistas opened that presented many new problems in operative technique that might have further glorified and accentuated the mechanical aspects of surgery except that fortunately a fresh and broader concept of surgery began to be evident

The general condition of the patient often critically poor because of anemia dehydration and malnutrition had been accepted as a necessary evil of his disease, but it often led to a high mortality and morbidity in those treated by operation

World War I presented newer and also nearly forgotten problems to surgeons in wound infection, shock empyema severe trauma to all anatomical areas that they were not prepared to meet and were unable to solve satisfactorily by methods and knowledge then available It became clear that there were then too few well qualified surgeons and those that did exist were unable to cope successfully with all of these new challenges

Because of the urgency of war the experimental method was finally called upon to aid and supplement clinical observations and trial and error treatment The satisfaction and complacency of the mechanical era with its emphasis on the operation alone began to disappear Because of this in the next decade a new surgery began to evolve based now upon the new spirit of inquiry that led inevitably to a wider and more intelligent use of the experimental method

Careful studies of end results led to dissatisfaction with many of the older techniques. New techniques could be and were evaluated in the laboratory before they reached the ward Many areas of graduate training in surgery at the university level were established The lag period between research in the basic sciences and its application to the sick in the clinic which often had been so long was shortened by a vivid recognition of its presence in the past Young surgeons learned research methods and solved many problems of the surgical patient in their

own laboratories The fundamentals of surgery—shock wound healing anesthesia infection—were re examined by new methods and with a critical approach

The physiological chemical and biological abnormalities associated with disease and trauma were studied and science suggested methods for their correction or avoidance Neurosurgery developed with increasing speed and skill through this closer relationship between clinic and laboratory Again the urgent demands on surgery made by the weight of new problems arising from World War II increased the tempo of research in fields of infection and trauma and led to an unbelievably rapid advance in surgery of the lungs the heart and the great vessels

Great and thrilling as these new dramatic advances are it should not be forgotten that important and solid additions to diagnosis and treatment have continued to be made in surgery of the abdominal organs Research on the physiological abnormalities of disease in abdominal organs has developed many operative methods for their control and correction Our original goal of removal of diseased areas can now be supplemented by alteration and correction of disordered function The liver spleen pancreas and their abnormalities of structure and function can now be treated with a certainty and sureness that was previously unknown

Most of the pathological effects of disease such as anemia dehydration and malnutrition can now be corrected before operation thus making possible a low mortality and morbidity rate Drops of ether and chloroform have evolved into anesthesiology a basic and important discipline The preparation of the patient for operation and his care during and after operation are emphasized in this book by complete and authoritative presentation The fundamentals of surgery as now known are emphasized Most of us become followers of tradition in what seem to be the less spectacular phases of an operation But if tissues are handled gently and hemostasis is secured there will be fewer infections If incisions in the abdominal wall are well chosen and appropriately closed there will be few disruptions and rare hernias in scar

In short there has developed an intellectual aspect to surgery that is infinitely more important than its mechanical component which was originally so much overemphasized Surgeons do themselves and their art a gross injustice in allowing the word surgery to become synonymous with operation Surgery is an art and a science that treats disease and injury by manual methods After all the experimental method is closely related to surgery both being a happy union of mind and hand

The contributors were selected with great care and I think that most will agree with wisdom The surgeons associated with the book are well and widely known for their interests and skills There is a wide geographical distribution thus assuring a national view rather than one that might be parochial

At one time many volumed systems of surgery were popular but they were expensive space occupying and unfortunately soon became obsolete The Editors planned this book to be a single volume system on one area of surgical interest It was not intended to be an operative manual and the older operations now only of historic value are excluded The illustrations are carefully chosen and demonstrate the methods preferred by the authors of each particular chapter

The intellectual and mechanical aspects of surgery are developed and presented together The book should be of interest and help to anyone caring for patients with pathology or abnormal physiology of abdominal organs Residents in training and surgeons young and old can learn or at least review the opinions and experiences of an outstanding group of American surgeons selected by a surgeon who was a skillful operator a wise clinician one who grew up with the union of surgery and science and who above all was devoted to his patients all of whom were to him people

FREDERICK A COLLER M D

# PREFACE

*Abdominal Surgery* was conceived as a readable, practical, concise yet comprehensive guide to the care of patients with abdominal disease amenable to surgery The step by-step details of surgical technique are carefully described and illustrated In addition, the Editors believe that the operation itself is but a part of the total care of the patient, therefore great care has been taken to explain total-body physiologic deficits encountered in various diseases and the methods for their correction Indications for surgery are discussed and where alternative procedures are available the relative indications and results to be expected have been presented in a practical way Discussion of methods not universally accepted, *satisfactory* as they may be in the hands of their advocates, has been minimized deliberately to save the reader time and, perhaps, confusion

The Senior Editor, Dr Allen, died during the preparation of the book, but the decisions of content and selection of contributors had already been made and were largely his For this he was uniquely qualified through personal acquaintance and through his vast clinical experience Contributors were chosen whose interest and experience in the field assigned made them eminently qualified to present the 'best current therapy

The implementation of *Abdominal Surgery* has been for the Junior Editor quite literally a labor of love for Dr Allen, who considered this book the final contribution of his long and brilliant career I am sincerely grateful to the contributors for the care, thoroughness, and complete competence with which their assignments have been carried out—a most fitting tribute to Dr Allen

D W B

CHAPTER 1

# ABDOMINAL INCISIONS

*Leon Goldman and Edwin J. Wylie*

Several factors must be taken into consideration in the planning and execution of an incision into or through the abdominal wall, each of which is a determinant in the performance of a successful operation Attainment of adequate exposure of the structures to be operated upon surpasses all other factors When the requirements for satisfactory exposure may be met by more than one approach through the abdominal wall, the selection of the approach is guided by the physique of the patient and the anatomic considerations governing the ease of closure, strength of the healed wound, duration and comfort of convalescence, restoration of normal function of the abdominal wall, and the cosmetic appearance of the resultant scar The following review is supplied to describe anatomic features that are of particular importance to the surgeon

## ANATOMY

SKIN The connective tissue bundles of the corium in the skin of the abdominal wall, as elsewhere in the body, are oriented in a linear fashion to create lines of tension, called Langer's lines (Fig 1-1) Incisions parallel to these lines tend to heal as fine lines. The scars of incisions that cross Langer's lines tend to widen transversely and to contract longitudinally Such contraction often creates a puckered appearance in the scar Overgrowth of the scar and formation of keloid are usually more prone to develop in incisions that cross Langer's lines

SUBCUTANEOUS TISSUE The subcutaneous tissue contains a layer of fat and superficial fascia In the upper half of the anterior abdominal wall the superficial fascia consists of a single layer Below the level of the umbilicus, however, it consists of two layers, the more superficial of which contains the cutaneous nerves and vessels There are many interneural connections between the sensory nerves that supply the skin, hence, an abdominal incision seldom causes cutaneous anesthesia unless the deeper primary nerve trunks are divided An analogous rich bed of vascular anastomoses in this layer protects the skin adjacent to an incision from becoming ischemic and hence removes many of the limitations that are encountered elsewhere in the body to the use of curved, irregular, or connecting incisions The superficial fascia possesses only slight tensile strength Its suture contributes no real strength to surgical closure of the abdominal wall

MUSCLES AND DEEP FASCIA The muscles, their enclosing fascial envelopes, and aponeurotic extensions, contribute to the basic strength of the abdominal wall (Figs 1-2, 1 3) The contractile function of the abdominal muscles is furthermore a powerful constrictive mechanism that aids in sneezing, coughing, defecation, and micturition These muscles function reciprocally

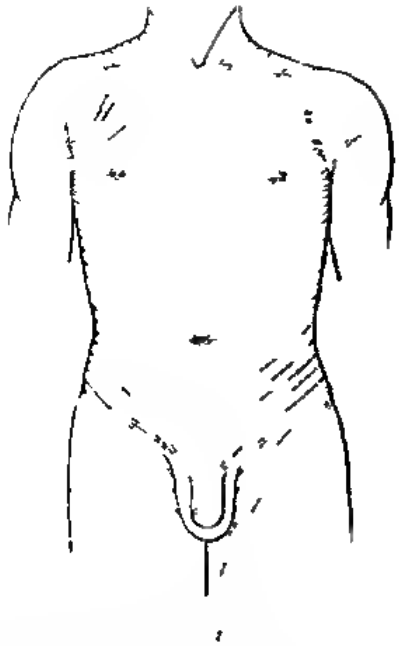

Fig 1 1 Langer s lines of cleavage in the skin following the distribution of the sub cutaneous fibrous tissue

with the action of the diaphragm during normal respiration They function antago nistically to the pull of the posterior spinal muscles to stabilize the position of the pelvis in all upright bodily positions In cisions that permit a rapid return to these functions contribute to a smoother post operative course

The central muscle mass is composed of a pair of vertically aligned rectus muscles extending from the thoracic cage to the pelvis The lateral muscle masses are made up of three large, flat, overlapping muscles arising in the flank These muscles extend medially and anteriorly by virtue of apo neurotic extensions to encase the rectus muscles, and insert into the fibrous band of the linea alba in the mid-line anteriorly The vector of force arising from the joint action of the lateral muscles acts to com press the anterior abdominal wall inward

The outermost lateral flat muscle is the

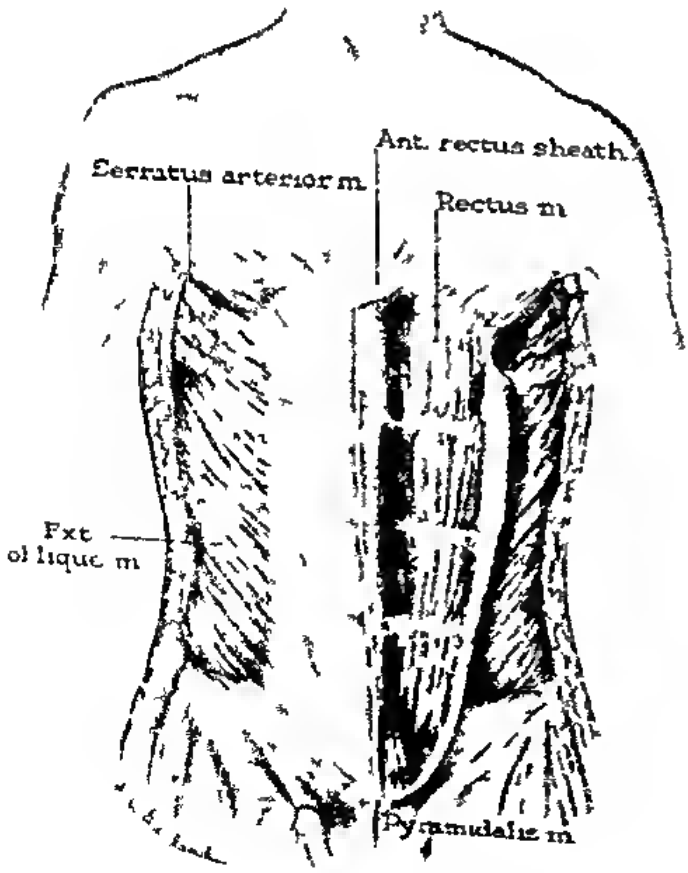


Fig 1 2 Superficial muscles of the abdominal wall

external oblique muscle It arises from the outer surfaces of the eight lower ribs and passes downward, forward and medially, to insert into the anterior half of the iliac crest the inguinal ligament and the pubis Adjacent to the lateral border of the rectus abdominis, its fibers become aponeurotic and pass anterior to the rectus muscle to become a portion of the anterior rectus sheath

The internal oblique muscle has its origin on the lateral half of the inguinal ligament, the iliac crest, and the lumbodorsal fascia Its fibers pass behind and at right angles to those of the external oblique muscle to insert into the four lower ribs The anterior extension of the internal oblique muscle is aponeurotic This aponeurosis in the upper abdomen splits into two lamellae, the anterior of which fuses with the aponeurosis of the external oblique to become part of the anterior rectus sheath The posterior lamella fuses with the underlying transversus abdominis aponeurosis and passes posterior to the rectus muscle In the lower abdomen, at a level beginning approximately 3 cm below the umbilicus the entire thickness of the internal oblique aponeurosis passes anterior to the rectus muscle

The innermost of the three flat muscles is the transversus abdominis This is a thinner muscle, which passes horizontally across the abdomen from the iliac crest, lumbodorsal fascia, and the six lower ribs to terminate anteriorly also as an aponeurotic layer Its aponeurosis passes posteriorly to the rectus muscle in the upper abdomen and anterior to the rectus muscle in the lower abdomen

The transversalis fascia lies underneath the transversus muscle In the upper ab

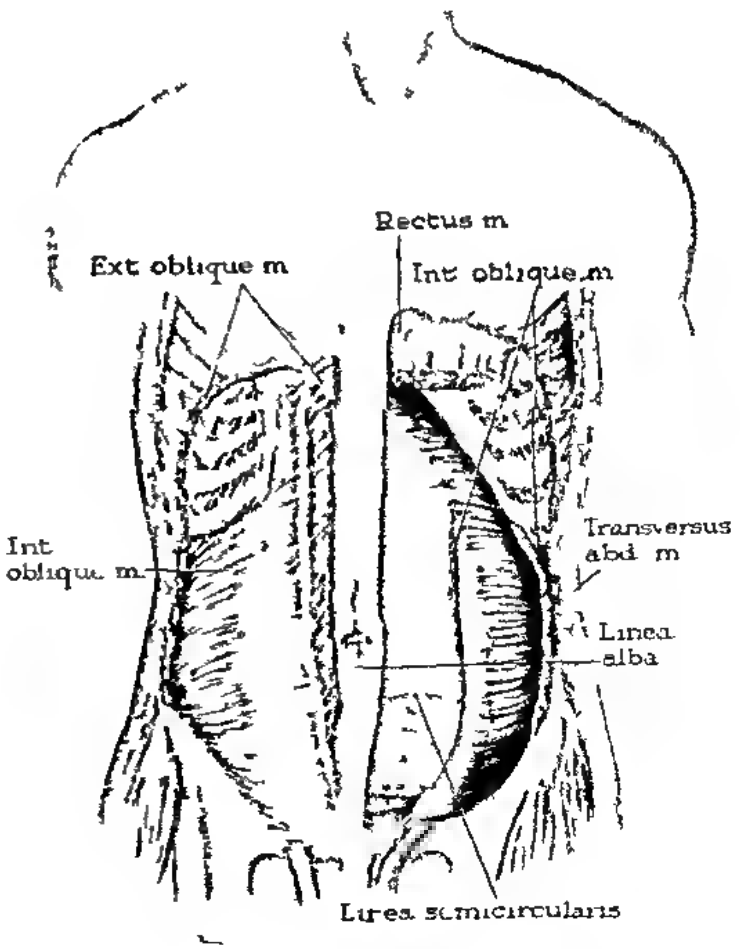


Fig 1 3 Deep muscles of the abdominal wall

domen this fascia is a relatively weak layer of fibrous tissue closely adherent to the peritoneum In the lower abdomen this layer exists as a stronger, more readily identifiable sheet of fibrous tissue The transversalis fascia is attached in

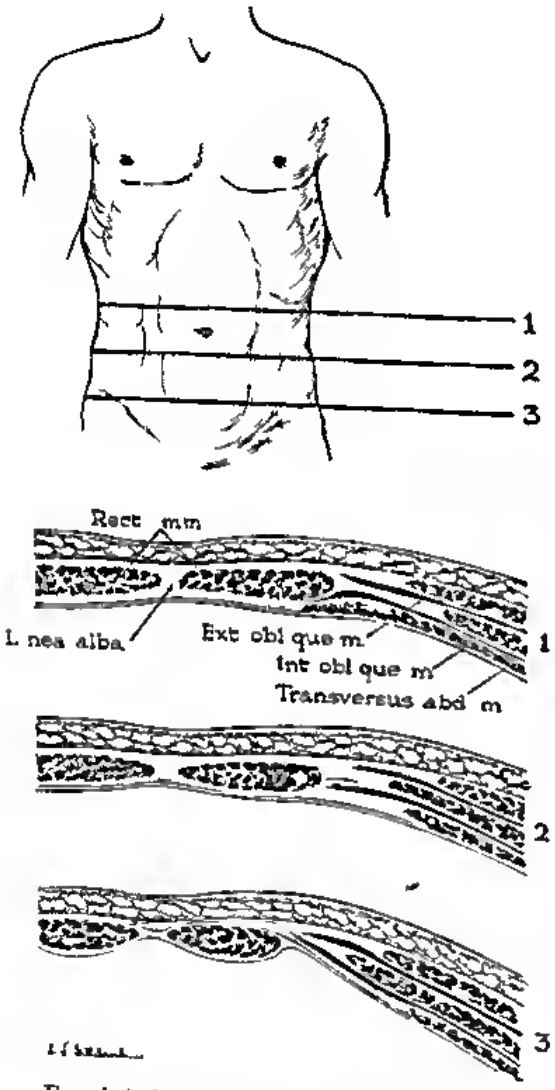


Fig 1 4 Transverse sections of the abdominal wall at three levels to illustrate the distribution of the aponeuroses of the lateral muscles in the formation of the anterior and posterior rectus sheath

feriorly to the inner lip of the iliac crest outer half of the inguinal ligament lacunar ligament and the pubic crest

The two rectus abdominis muscles occupy the central half of the abdominal wall At least one of these and its aponeurotic coverings must be dealt with in most major abdominal operations The recti arise from the pubic crest underneath the insertion of the external oblique and pass vertically upward to a wide insertion in the ensiform and costal margin as far laterally as the tip of the ninth rib The rectus muscle is marked by a series of two to five transverse tendinous striations by which the muscle is adherent to its sheath anteriorly Posteriorly the muscle is only loosely adherent to the posterior sheath and may be readily separated from it The adherence of the rectus muscle to the anterior sheath prevents significant retraction of the muscle when the sheath and muscle are divided in a transverse direction Suture of the sheath after a transrectus incision is adequate to reapproximate the divided muscle

Anterior to the lower part of the rectus muscle and within the rectus sheath is the pyramidalis a small pyramidal muscular slip that arises from the pubic crest between the external oblique and rectus muscles The pyramidalis extends upward and medially to terminate in a slender tendon that inserts into the linea alba midway between the pubis and the umbilicus Although the muscle acts to give tensile support to the linea alba no observable functional deficit is produced by its transection or denervation as a result of an adjacent incision

From the foregoing description it is apparent that the rectus sheath is in reality composed of the confluent aponeurotic fibers of the three lateral flat muscles and the transversalis fascia all the fibers of which run transversely It is for this reason that closure of a transverse rectus incision produces a stronger wound than does similar closure of a longitudinal rectus incision paralleling the muscle fibers In the lower abdomen up to a level 3 to 5 cm below the umbilicus all fibers (except those of the transversalis fascia) pass anterior to the recti Above this level (the semicircular line of Douglas) the fibers split to provide more equal support anteriorly and posteriorly the external oblique and half of the internal oblique

aponeuroses pass anteriorly and the internal oblique and transversus aponeuroses pass posteriorly (Fig. 1-4).

NERVES. The nerve supply (Fig 1-5) is of particular importance to the surgeon in the selection and performance of an abdominal incision, since interruption of nerve continuity may significantly weaken sectors of the abdominal wall. The effects of such interruption, in addition to interfering partially with the function and strength of the abdominal wall, include the development of uncomfortable, unsightly bulges and occasionally painful neuromata Since in most persons abdominal muscle function is diffuse and unspecific, no particular function is totally lost when nerve interruption is limited

The anterior abdominal wall is supplied by the six lower intercostal and first lumbar nerves Of some surgical significance is the observation that these do not run as single nerves but possess intercommunications in the intercostal spaces and as far as anteriorly as the lateral border of the rectus muscles. They pass from behind the costochondral junction to enter a plane anteriorly in the interval between the internal oblique and transversus abdominis muscles The only exception to this is that the anterior branch of the iliohypogastric nerve leaves this plane to pierce the internal oblique 2 cm medial to the anterior-superior spine, and passes anteriorly, medially, and inferiorly between the internal oblique muscle and the external oblique aponeurosis In transversing the anterolateral abdominal wall, the seventh and eighth nerves alter their obliquely downward course to turn up-

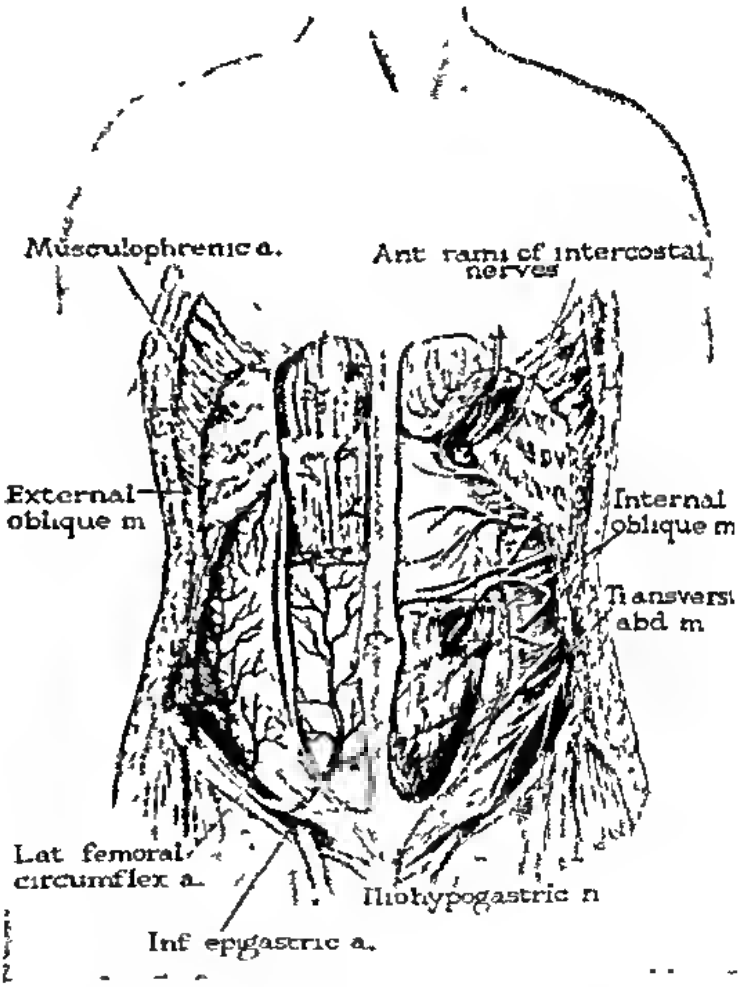


Fig 1-5 Distribution of nerves and blood vessels to the anterior abdominal wall

ward and parallel the costal margin The remaining four nerves continue caudally with increasing declination Upon reaching the lateral border of the rectus sheath the nerves pierce the sheath and enter the posterolateral aspect of the rectus muscle

The pattern of innervation of the abdominal wall and musculature is unique in that each muscle is innervated by multiple spinal nerves Division of any one nerve results in weakness of only a portion of the muscle to which it contributes Such weakness may furthermore be partially compensated for by interneural branches from adjacent nerves If the point of division is close to the lateral rectus border, however, the paucity of interneural fibers near the mid line causes a more pronounced denervation of the segment of the rectus muscle supplied by the specific motor branch It is for this reason that vertical incisions lateral to the rectus margin are undesirable

BLOOD VESSELS The blood supply (Fig 1-5) of the anterior abdominal wall is of less importance in the planning of surgical incisions than would be the blood supply in other areas of the body The upper portion of the abdominal wall is supplied by the six lower intercostal arteries that enter the wall along with the intercostal nerves In the groin, three superficial branches of the femoral artery (circumflex iliac superficial epigastric, and external pubic arteries) supply the lower quadrants At a deeper level are two larger arteries which are branches of the external iliac The deep circumflex iliac artery follows the line of the iliac crest into the flank in the plane between the internal oblique and transversus muscles The inferior epigastric artery passes upward and medially to the lateral border of the rectus and ascends behind that muscle to anastomose with the terminal branches of the superior epigastric artery The latter artery is the caudal extension of the internal mammary artery descending from the thorax Because of these multiple origins of arterial supply and the numerous collateral anastomoses, the surgeon is rarely concerned with the likelihood of devascularizing adjacent tissue when the major vessels in the line of incision are divided

## TYPES OF INCISIONS

In the introductory paragraphs the general principles that guide the surgeon in the selection of an abdominal incision were enumerated A further elaboration based upon anatomic considerations can now be made

Before an abdominal incision is made it is necessary that the surgeon have a clear working diagnosis of the condition for which the operation is to be performed The use of the term 'exploratory laparotomy' should be discouraged Pain in the right lower quadrant of the abdomen that is caused by appendicitis indicates that a muscle splitting McBurney incision should be used If the pain is due to a ruptured appendix and local abscess formation the incision should be modified at the peritoneal level to permit extraperitoneal entry to the abscess If the pain in the right lower quadrant is due to twisting of the right ovary or rupture of the right fallopian tube in an ectopic pregnancy a McBurney incision occasionally will be inadequate but may be safely extended For obstruction involving the small intestine, a relatively long vertical incision may be required, whereas obstruction involving the colon may call for a short differently placed incision to permit a preliminary decompressing cecostomy or colostomy These are but a few examples to indicate the importance of a sound preoperative diagnosis prior to the performance of the abdominal incision

An additional consideration in the choice of exposure is the potential need for extending or modifying an incision should the pathologic findings indicate that the initial incision was inadequate Methods available for increasing the exposure of the various abdominal incisions will be described in connection with the individual descriptions

Ease of closure, wound strength, and

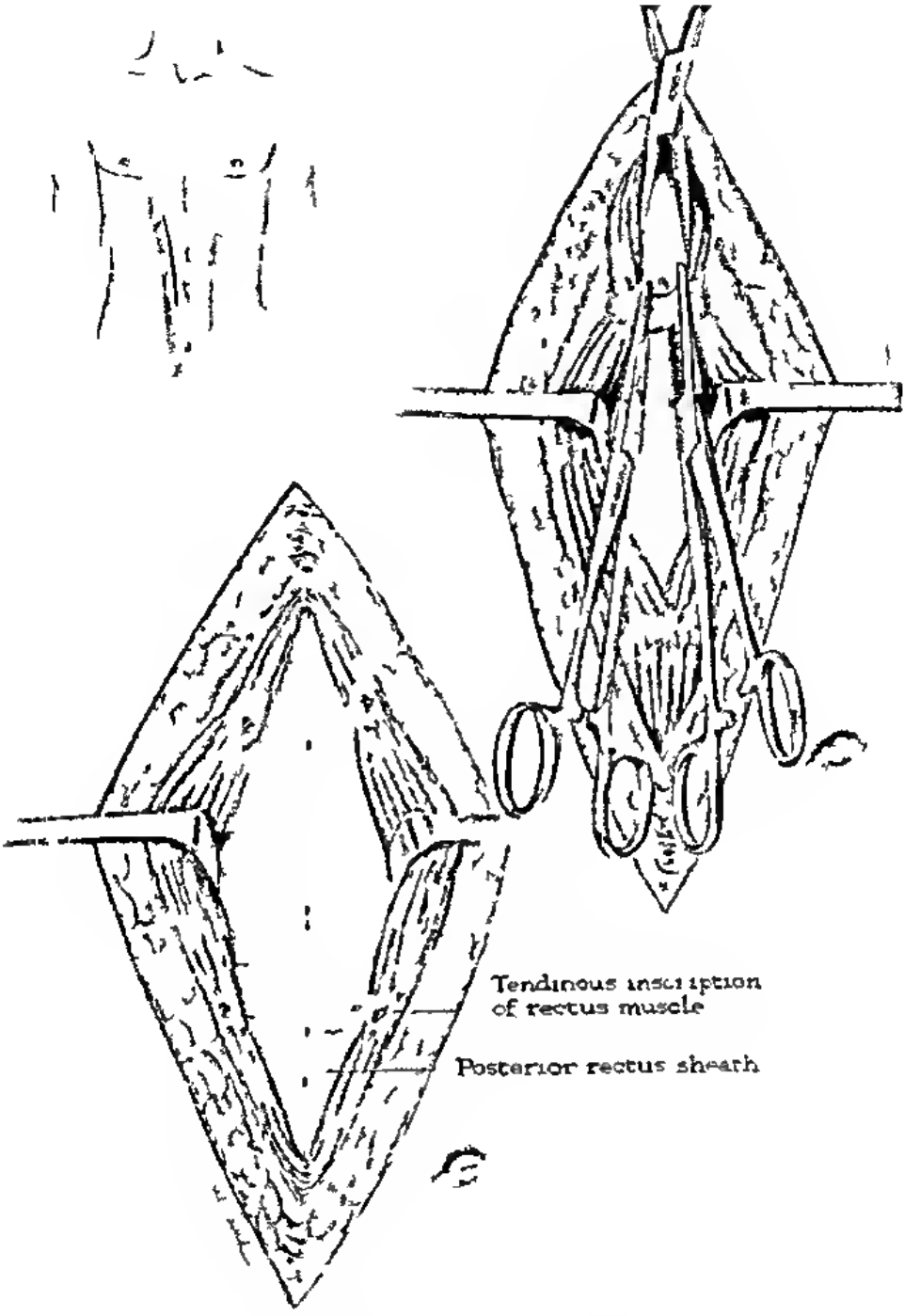


Fig 1 6 The rectus muscle splitting incision

smoothness of convalescence are largely determined by anatomic considerations The ideal incision is one that parallels the fibers of both muscle and nerve Although this can rarely be accomplished in the abdominal wall due to the crossed direction of the lateral muscles and the lateral innervation of the rectus muscles experience has shown the extent to which the ideal may be compromised without jeopardizing strength and function

## Vertical Incisions

The three vertical incisions commonly used in abdominal exposure are the midline, paramedian and rectus splitting These incisions had their greatest vogue

during the era of exploratory laparotomies By extension of the length of any of the three incisions adequate exposure of all portions of the abdomen can be obtained In certain patients with acute obstruction of the small intestine and in whom the exact site of obstruction can rarely be determined preoperatively, a vertical incision gives the easiest access to the various potential sites of obstruction The newer arterial reconstructive operations for lesions involving the abdominal aorta often require adequate exposure of the aorta as high as the renal arteries as well as exposure of the terminal branches of the aorta to the level of the femoral ring For exposure of this magnitude vertical incisions are necessary

The strength of the closed vertical incision during the immediate postoperative period is less than that of an oblique or transverse incision It is to be recalled that the aponeurotic extension of the lateral muscles form the anterior and posterior sheaths of the rectus muscle, and that the fibers of these aponeuroses course in a transverse direction The postoperative tensile strength of an incision that cuts these fibers is less than that of an incision that parallels them Inasmuch as the direction of maximum stress put upon the rectus muscle during coughing or retching is lateral rather than vertical vertical incisions may be more exposed to disrupting strains postoperatively than are transverse incisions

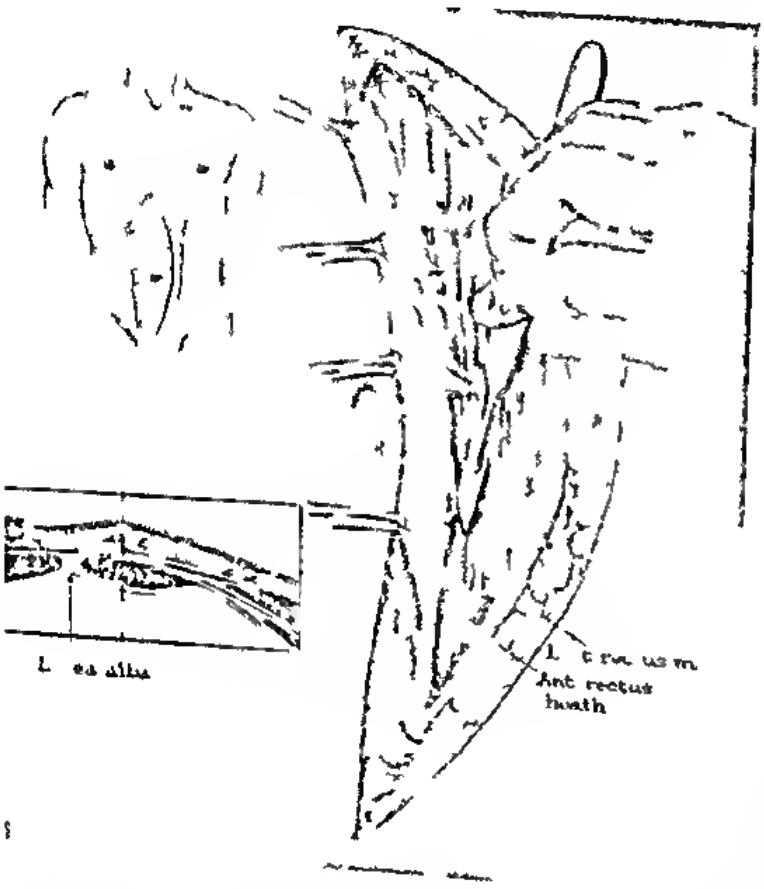


Fig 1 7 The paramedian incision The anterior rectus sheath is incised longitudinally and its medial flap is reflected to the l nea alba

Although incisional pain is predominantly a function of the degree of muscle retraction during operation most surgeons have observed that patients suffer less distress following operations employing transverse incisions than after operations in which vertical incisions were used Because of the parallel course of Langer s lines of cleavage transverse or oblique skin incisions result in a less unsightly scar

than do vertical incisions For these reasons the vertical incisions described below are gradually becoming restricted to those exposures for which transverse incisions are inadequate

RECTUS MUSCLE SPLITTING INCISION The rectus muscle splitting incision (Fig 1 6) may be applied at any point along the course of either rectus muscle The fascial and peritoneal incisions and muscle fiber separation are all made in the same plane The two layer fascial closure by dividing the stress is believed to add to wound strength In separating the fibers of the rectus muscle, it is important for wound comfort that this maneuver be performed by sharp dissection with preliminary division of blood vessels and minimal muscle retraction

The obvious disadvantage of the rectus splitting incision is the extent to which the portion of the rectus muscle medial to the incision is denervated The nerve fibers run transverse to the direction of the muscle fiber and each innervates a specific transverse segment of muscle The absence of innervation from adjacent nerves as is found more laterally in the abdominal wall makes it inevitable that a portion of the medial muscle group will be denervated by the transection of one or more nerve fibers This frequently results postoperatively in a vertical bulge of the abdominal wall between the incision and the mid line On the other hand preserving the loose areolar tissue attached to the fascia (as in a muscle splitting incision) may encourage fibroblastic consolidation of the fascial edges as described by Dunphy

PARAMEDIAN INCISION In the paramedian incision (Figs 1 7 1 8 1 9) the skin is incised in the same line as in the rectus splitting incision The anterior and posterior rectus sheaths are incised in line with the skin incision The belly of the rectus muscle however is retracted laterally without the division of any of its fibers or nerve supply The two layer fascial closure with an interposed muscle mass permits a stronger closure than the rectus splitting incision In the experience of the authors the incidence of postoperative wound dehiscence is less following the paramedian incision than following either of the other two vertical incisions

The only disadvantages of this incision are the difficulty in exposing the lateral cut edge of peritoneum behind the intact muscle belly and the occasional mid line bulge that may result if the muscle is not

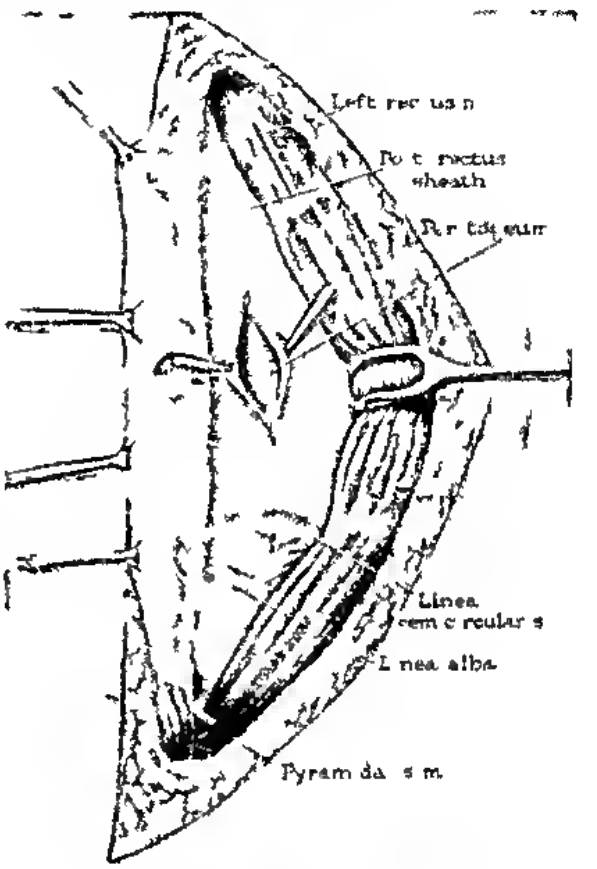


Fig 1 8 The paramed an incision The intact rectus muscle is reflected laterally to perm t incision of the posterior rectus sheath

accurately replaced adjacent to the linea alba

MID LINE INCISION A vertical mid line incision through the linea alba is technically the easiest and quickest to perform Very little bleeding occurs The division of the one fascial peritoneal layer gives immediate access to the abdominal cavity As in the paramedian incision the mid line incision may be extended to the full length of the abdomen This incision is still the commonest one for operations in the female pelvis It is of greatest value

when adequate exposure within a limited amount of time is paramount as in severe intra abdominal hemorrhage

The disadvantage of the vertical mid line incision is its inherent weakness The predominant lateral stress of the abdom

sectors of the two oblique muscles and the transversus muscle are frequently used when a specific but limited portion of the abdominal cavity is to be exposed The chief advantage of incisions of this type is the strength of the healing wound The

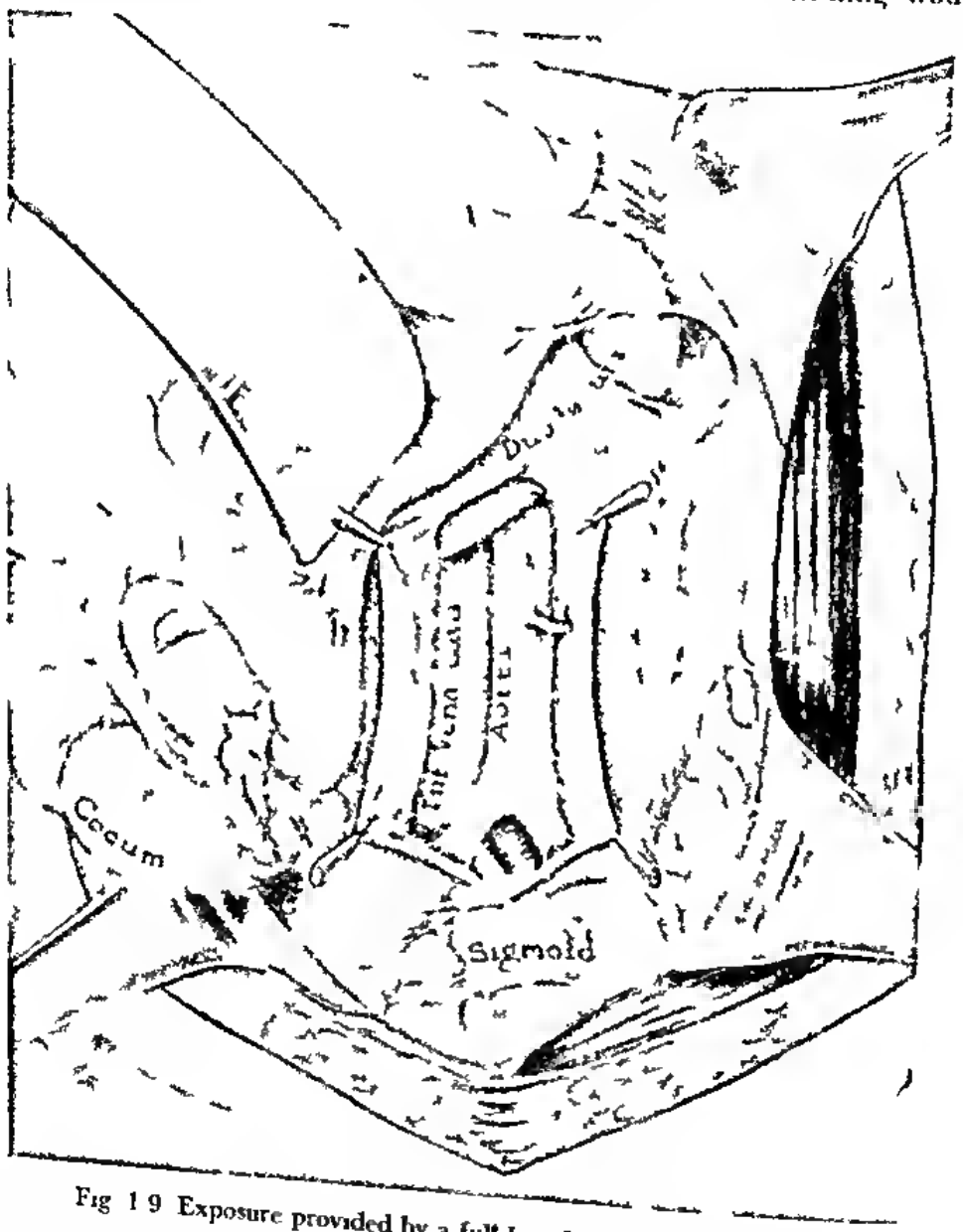


Fig 1 9 Exposure provided by a full length paramed an incision

inal wall the single layer closure and the transverse orientation of the aponeurosis are combined in one incision

## Muscle Splitting Incision

Muscle-splitting incis ons in the abdom inal wall developed through the lateral

normal tone of the separate muscle layers tends to hold the incision closed thereby lessening the tension that must be applied by sutures Forceful contraction of the abdominal muscles postoperatively by coughing or retching tends to tighten the operative wound further Denervation of adjacent muscle fibers can be avoided by

retracting the motor nerves to the rectus as they transverse the interval between the internal oblique and transversus muscles

The use of muscle-splitting incisions is limited to those operations requiring only partial exposure of the abdomen The right lower quadrant exposure of the disease appendix (McBurney incision) is the classic example. Others are the right upper quadrant exposure used to perform a Ramstedt pyloromyotomy for congenital hypertrophic pyloric stenosis, and the left lower quadrant exposure for colostomy of the sigmoid colon The muscle-splitting technique is also useful in the lateral areas of the midabdomen for a limited retroperitoneal approach or, on the right side, to permit resection of the ascending colon and cecum In our experience dehiscence or hernia occurs less often in this type of incision than in any other.

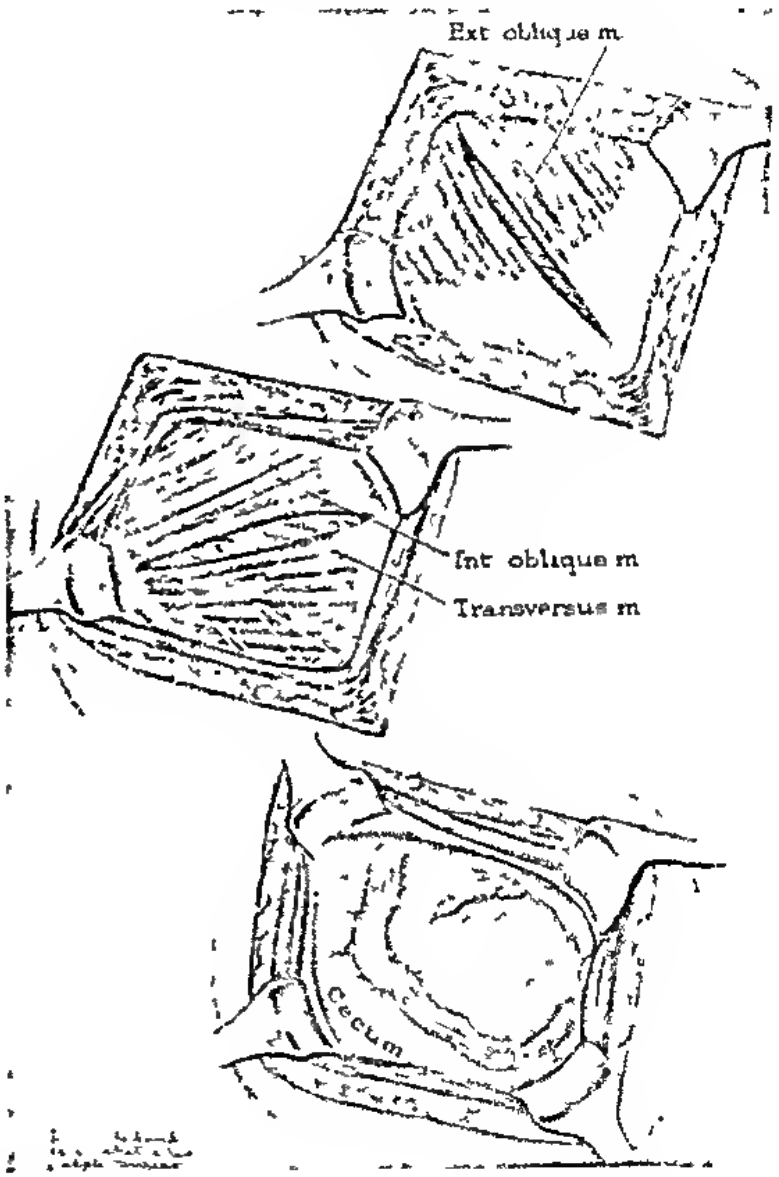


Fig 1-10 The McBurney incision

MCBURNEY INCISION. The right lower quadrant McBurney incision (Fig 1-10) is the muscle-splitting incision most familiar to surgeons The skin incision is made at right angles to a line connecting the anterior-superior iliac spine and the umbilicus with one third of the incision cephalad to this line. The fascia and fibers of the external oblique muscle are separated and retracted to expose the transversely coursing fibers of the internal

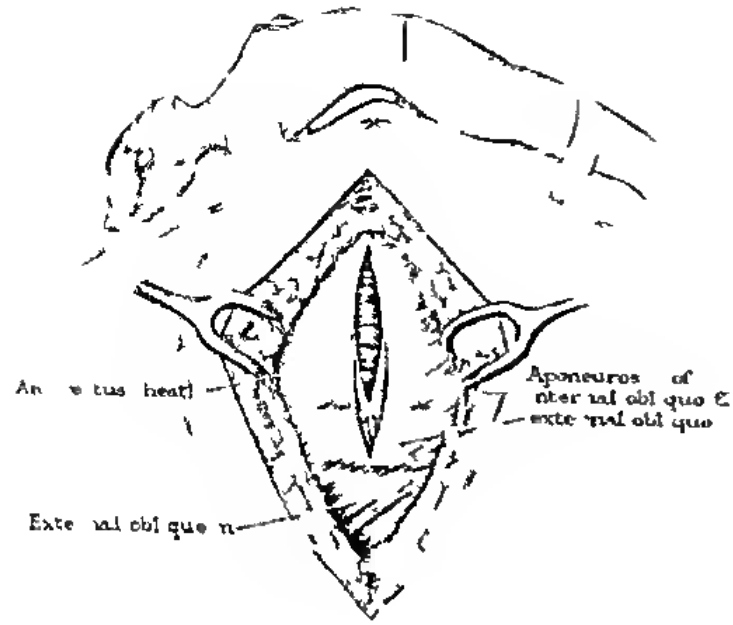


Fig 1 11 The lateral mid abdominal muscle splitting incision The transverse rectus sheath incision is extended laterally to the muscle fibers of the external oblique muscle

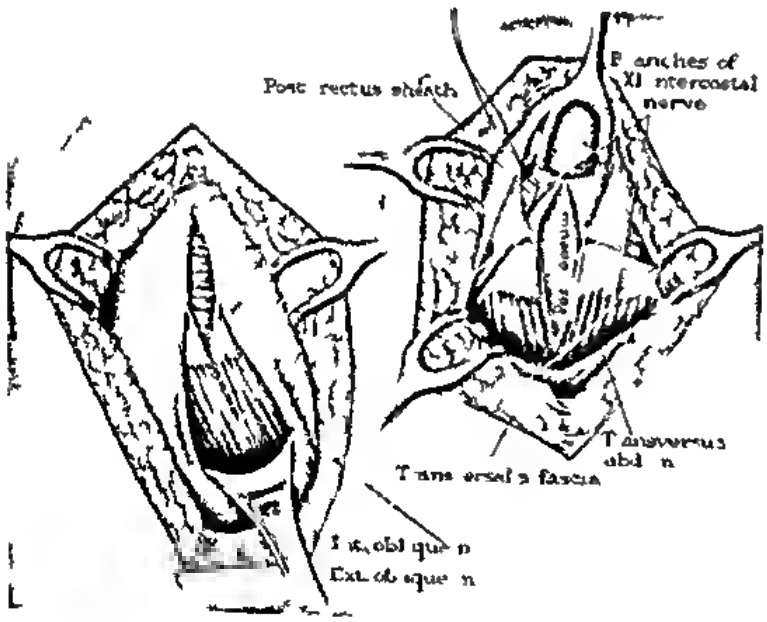


Fig 1 12 The lateral mid abdominal muscle splitting incision (*Left*) The external oblique muscle is retracted laterally and inferorly (*Right*) The fibers of the internal oblique and transversus abdominis muscles are separated The transversalis fascia is incised transversely

oblique muscle This muscle is also separated in line with its fibers Further retraction exposes the transversalis fascia or muscle whose fibers are digitally separated in the same manner This causes the peritoneum to bulge upward into the wound and permits its incision with clear visibility

Several modifications of this incision are frequently practiced For cosmetic reasons the skin incision may be made somewhat more transverse so that it parallels Langer s lines The entire incision may be placed higher or lower depending upon predetermined requirements for exposure of an appendix in an unusual position The external oblique muscle and fascia may be incised transversely (Rockey), although this sacrifices the advantages of a true muscle splitting incision For greater exposure the internal oblique opening may be enlarged (Weir) In performing the Weir extension the external oblique aponeurosis lying anterior to the rectus muscle is retracted medially and the portion of the anterior rectus sheath made up of the internal oblique aponeurosis is incised transversely The exposed lateral fibers of the rectus muscle are then re

tracted medially The rectus compartment may be incised longitudinally upward or downward in the event added exposure is necessary Access for drainage of an appendiceal abscess often may be obtained by developing the plane between the transversalis fascia and the peritoneum laterally to permit extraperitoneal entry into the abscess in its usual position in the iliac fossa

Although the exposure obtained by the McBurney incision is used chiefly for removing the appendix it is significant that most diseases of other organs or viscera in this quadrant with which the diagnosis of appendicitis may be confused can be suitably dealt with through the McBurney incision These pathologic conditions include inflammatory lesions of the terminal ileum Meckel s diverticulum, right ovary, and right fallopian tube

The advantages of the McBurney incision are increased wound comfort and strength and rapid recovery Dehiscence almost never occurs and the incidence of herniation is low even after wound sepsis has developed

TRANSVERSE LATERAL ABDOMINAL MUSCLE SPLITTING INCISION This is illustrated in Figures 1 11 1 12 and 1 13 Following a transverse incision to one side of the umbilicus the transverse incision in the anterior rectus fascia is extended laterally to the anterior fibers of the external oblique muscle Lateral and caudad retraction of the external oblique muscle permits sufficient exposure for separation of the fibers of the internal oblique and transverse muscles The anterior and posterior rectus sheaths are incised The rectus muscle is retracted medially

For exposure of the retroperitoneum the cleavage plane between the transversalis fascia and peritoneum is developed by blunt dissection The most direct route for dissection in this plane is caudad to reach the psoas muscle Cephalad dissection anterior to the prominent belly of the psoas muscle and medial retraction of the peritoneum retroperitoneal fat and ureter exposes the vena cava and the lumbar sympathetic chain

Additional exposure is rarely necessary except in the unusually obese patient More exposure may be obtained by transverse incision of the rectus muscle or of the medial fibers of the external oblique muscles

RIGHT UPPER QUADRANT MUSCLE SPLITTING INCISION This is favored by many surgeons for an approach to the

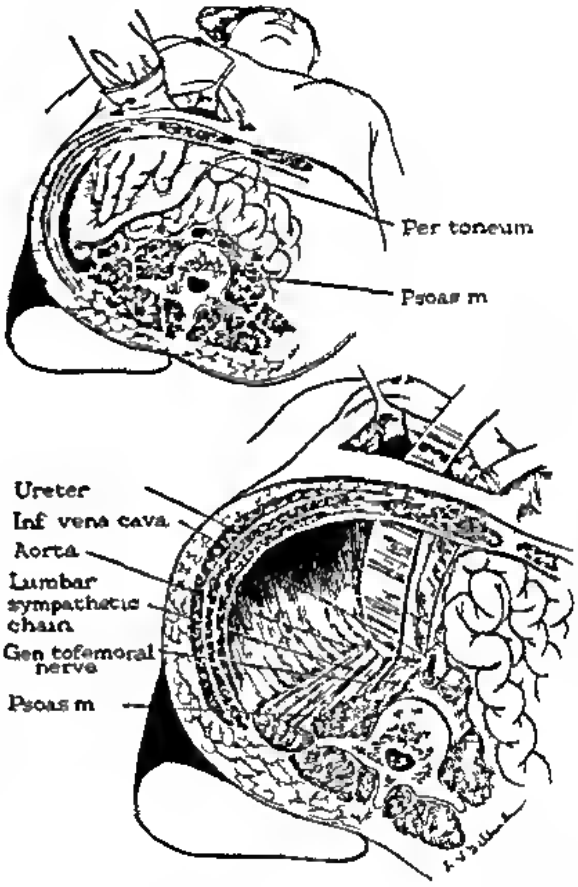


F g 1 13 Method of extraperitoneal d ssection to expose retroperitoneal structures through the lateral m d abdom nal muscle spl tt ng incision

pylorus in infants with hypertrophic pyloric stenosis Because the belly of the rectus muscle sweeps laterally in the upper abdomen an incision that splits the oblique muscles at this level must be placed more laterally than the otherwise similar incision in the lower quadrant The *occasional* difficulty in exposure under this circumstance has led most surgeons to prefer a high short right rectus splitting incision to ex

pose the pylorus in infants In both incisions the buttressing effect of the low position of the right lobe of the liver found in patients of this age is helpful during closure

## Transverse Incisions

The general superiority of transverse abdominal incisions to rectus splitting or retracting vertical incisions has become less a matter of debate as surgical experience has accumulated The earlier objections to any incision that cut one or both recti transversely were predicated on the belief that the recti would retract from the fascial edges and thereby weaken the closed wound In actuality the fibrous attachments between the anterior rectus fascia and the underlying rectus muscle prevent retraction of the muscle fibers from the edge of the wound The healed incision shows close apposition of the rectus fibers across the line of incision and no significant impairment of rectus function Furthermore under usual circumstances, no intercostal nerves are divided, or at the most only one Rarely is any defect in abdominal muscle function observed after a healed transverse incision Less incisional distress is the rule and the appearance of transverse incisions that follow Langer's lines is less objectionable than the wider puckered scars of vertical incisions

## Subcostal Incisions

RIGHT UPPER OBLIQUE INCISION The right subcostal incision is favored by many surgeons in the approach to the gallbladder and biliary tract (Figs 1-14, 1 15) It is particularly applicable in patients who have widely flared costal angles Inasmuch as the costal attachment of the rectus muscle extends far laterally, muscle division is occasionally limited to a transverse incision through only the belly of the rectus The upward inclination of the seventh and eighth intercostal nerves as they traverse the abdominal wall often makes it possible to preserve both nerves For greater exposure the incision may be extended across the mid line as illustrated with either division or lateral retraction of

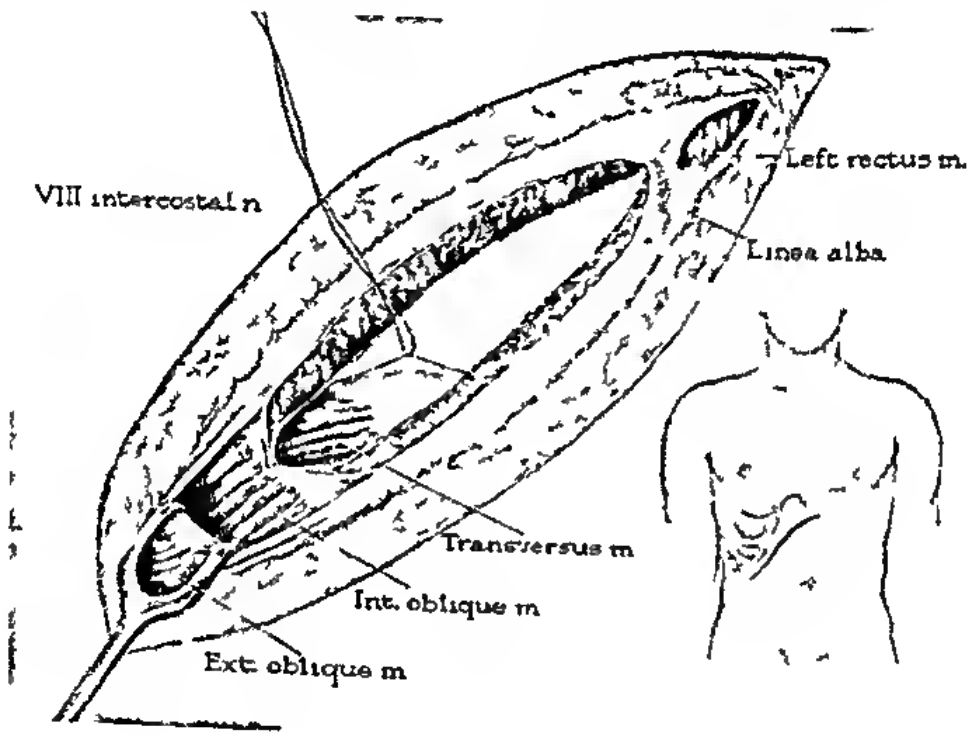


Fig 1 14 The right subcostal incision

the left rectus muscle Only in the very obese patient is it necessary to extend the incision into the oblique muscles in the right lateral abdominal wall

The only disadvantage of the upper oblique incision for biliary tract surgery exists in the patient in whom distal common duct exploration or duodenostomy may be required In these circumstances the first assistant may have difficulty in retracting the lower edge of the incision sufficiently for adequate exposure The possibility of additional exposure in right vertical incisions by caudad lengthening of the incision often makes the vertical incision superior when the need for extensive exposure of the biliary tract is anticipated

TRANSVERSE UPPER ABDOMINAL INCISION This incision which cuts both rectus muscles is frequently employed for operations on the stomach or pancreas The exposure obtained is equal to that gained from vertical incisions performed for the same purpose It possesses the general advantages of transverse incisions discussed previously and is particularly applicable in patients with flaring costal margins In rare instances a superior midline cephalad extension to the xiphoid process may be necessary for exposure of the cardioesophageal junction

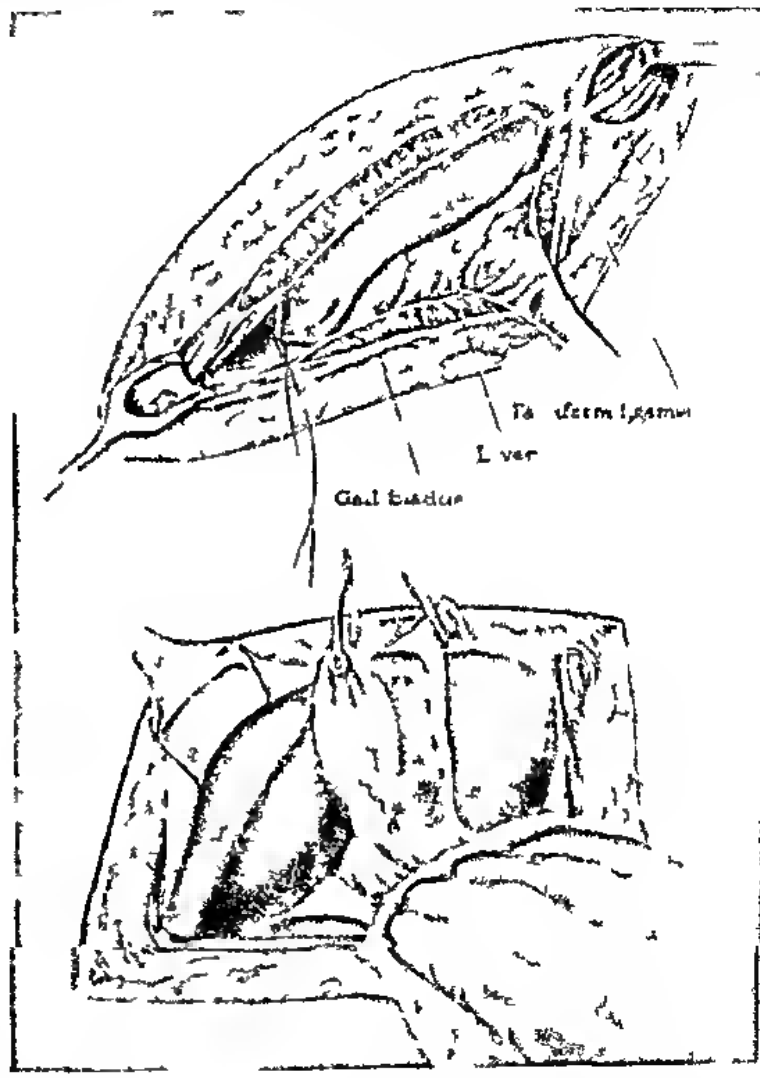


Fig 1 15 Exposure obtained by the right subcostal incision When this incision is used for biliary tract surgery it is seldom necessary to retract the left rectus muscle

TRANSVERSE MID ABDOMINAL INCISIONS These divide all muscle layers in line with the skin incision and are frequently used on the right abdominal wall for exposure of the cecum and ascending colon when resection of this segment of the colon is planned The relative simplic

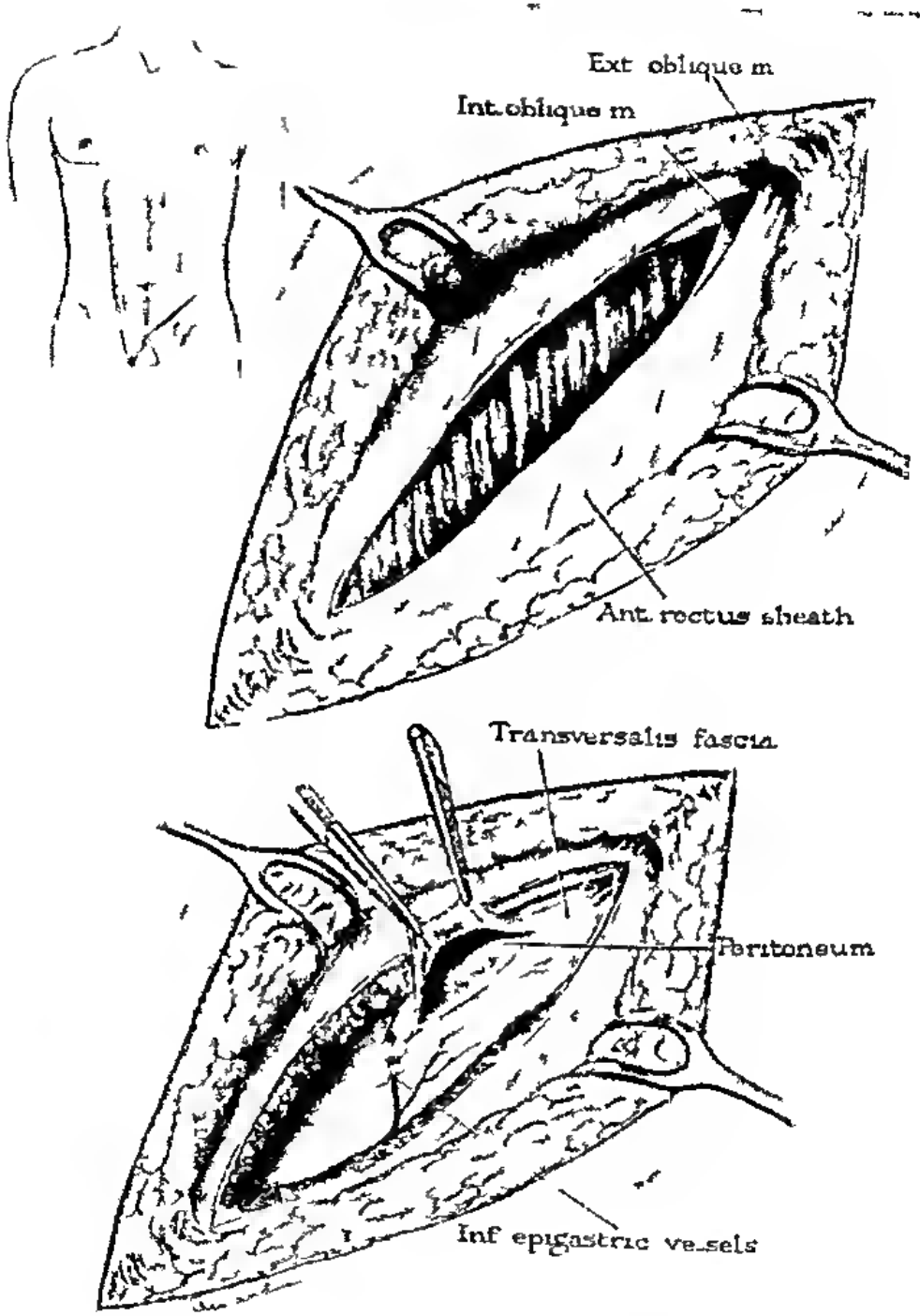


Fig 1 16 The lower abdominal oblique incision

ity of mobilizing the ascending colon and its short length permit adequate exposure through this incision for resection and ileotransverse colostomy The contrary is true in lesions of the ascending and sigmoid colon Resection of lesions in this segment often requires not only extensive dissection in the pelvis but in the area of the splenic flexure in the left upper quadrant In this circumstance either a vertical or an extensive left low abdominal oblique incision is necessary for adequate exposure

## Lower Quadrant Oblique Incisions

The low abdominal oblique incision (Figs 1 16 1 17) is particularly useful in obtaining retroperitoneal exposure of the

distal ureter and iliac vessels This incision, paralleling the fibers of the eleventh intercostal and the *ileohypogastric nerves*, reduces denervating muscle segments to a minimum It may be extended superiorly in line with the skin incision with little additional trauma

The noticeably greater postoperative wound comfort of this incision and the maximum cosmetic effect of an incision paralleling Langer's lines combine to make this a desirable incision when the conditions of adequate exposure are met For vascular procedures requiring exposure of the terminal aorta or contralateral iliac artery (aortic embolectomy, for example) the retroperitoneal exposure is frequently inadequate and for this reason has lost popularity in favor of the transperitoneal approach

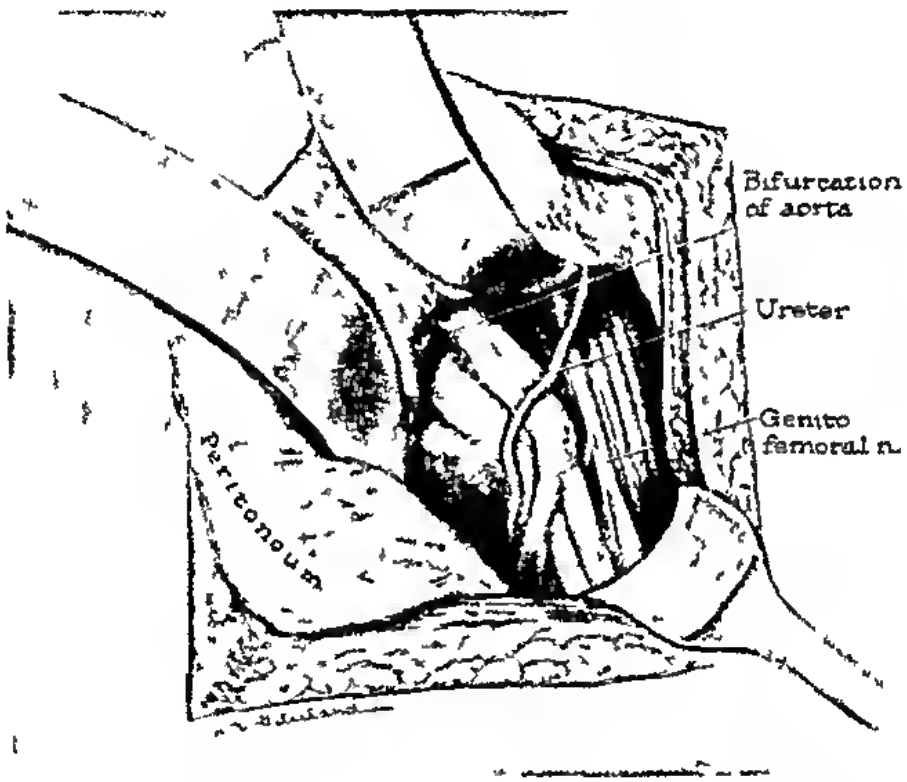


Fig 1 17 Exposure obtained by the lower abdominal oblique incision

## Pfannenstiel Incision

While the favored incision for gynecologic pelvic surgery is undoubtedly the low mid line incision, many surgeons frequently employ the Pfannenstiel incision (Fig 1-18) *One of the chief advantages* of this incision is its superior cosmetic result The incision is small and may be placed completely below the pubic hairline Since it follows the proper lines of skin cleavage and avoids postoperative tension, the incision almost always heals well The Pfannenstiel incision, which is parallel to the lines of stress, is accompanied by less postoperative pain wound dehiscence, and hernia formation than is the vertical incision, possibly because it employs the "gridiron" principle Moreover, upper abdominal obesity may be avoided

The chief disadvantage to this incision is that it offers limited exposure for the more complex pelvic operations, and it certainly is inadequate for removal of large pelvic tumors, accomplishment of any unsuspected necessary surgical procedure outside the pelvis, or dissection in a *deep* pelvis The problem of exposure can be improved to some extent by incising

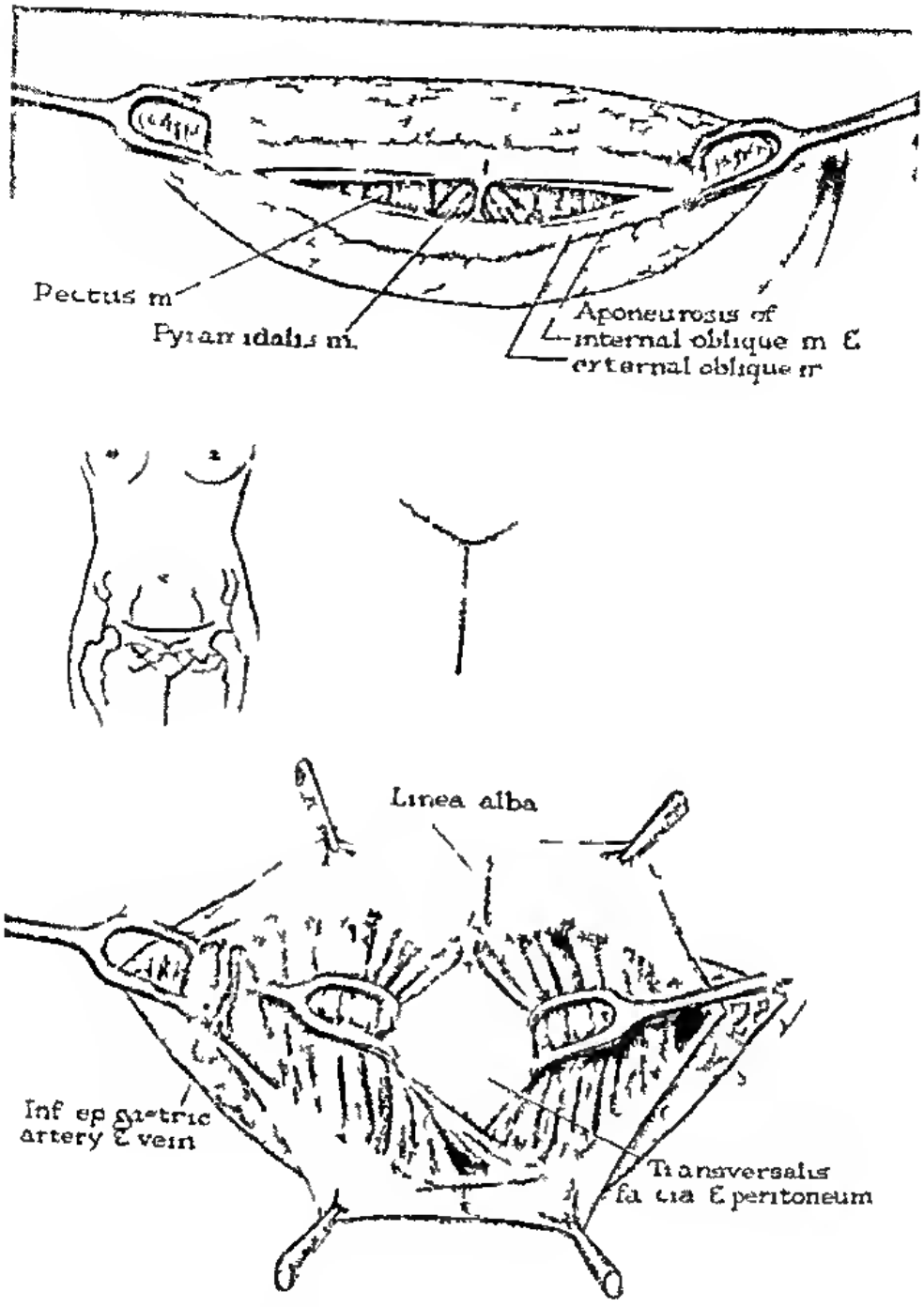


Fig 1 18 The Pfannenstiel incision

transversely the tendonous portion of the rectus muscles adjacent to the pubis (Cherney) The development and closure of the Pfannenstiel incision and its Cherney modification are more time consuming

Thus the Pfannenstiel incision is ideally suited for elective pelvic operations in a young woman with a shallow pelvis if extensive dissection or the removal of a large tumor is not contemplated and if the patient does not have a pre existing vertical scar

## Thoracoabdominal Incisions

Various incisions designed to provide simultaneous exposure of the abdomen and thorax have been introduced to meet

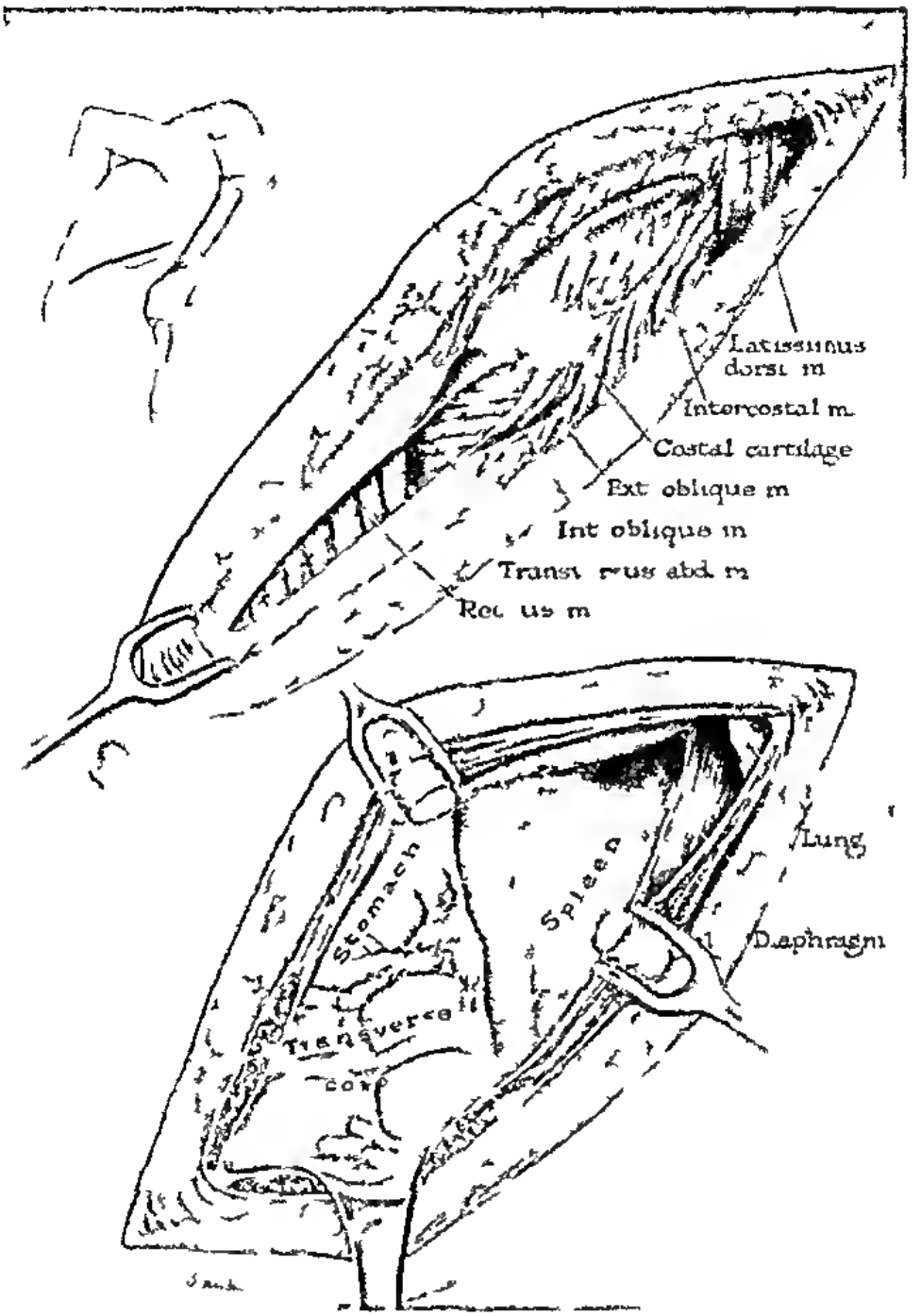


Fig 1 19 The left thoracoabdominal incision

the exposures necessary for the newer extensive abdominal operations These incisions are particularly valuable for concurrent exposure of the stomach and lower esophagus when radical resection of these structures is planned for performing splenorenal or portacaval venous anastomoses for removal of an enlarged spleen and neoplasms of the adrenal glands kidneys or other retroperitoneal structures and for the management of vascular disorders involving the lower thoracic and upper abdominal aorta

LEFT THORACOABDOMINAL INCISION The most frequently employed thoracoabdominal incision is shown in Figure 1 19 in which the thoracic portion of the incision extends along the ninth interspace

to pass across the abdominal wall to the mid line All fascial and muscular layers are transected in line with the skin incision Inasmuch as this incision parallels the course of the intercostal nerves incision (Fig 1-20), division of the diaphragm in this manner enables the surgeon to rotate the liver into the thorax, thereby permitting easy access to the retrohepatic structures

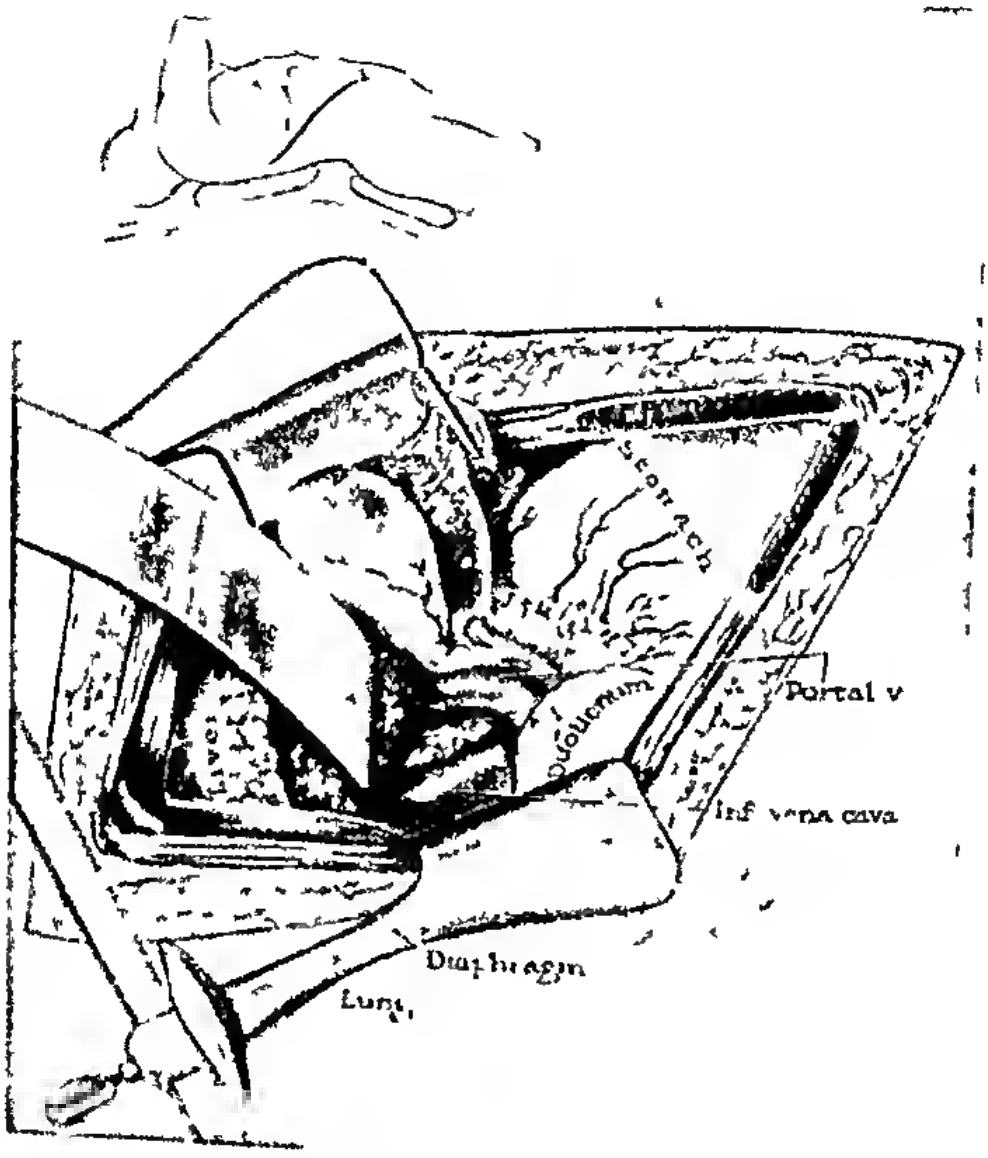


Fig 1 20 Exposure of the portal vein and vena cava through the right thoracoabdominal incision

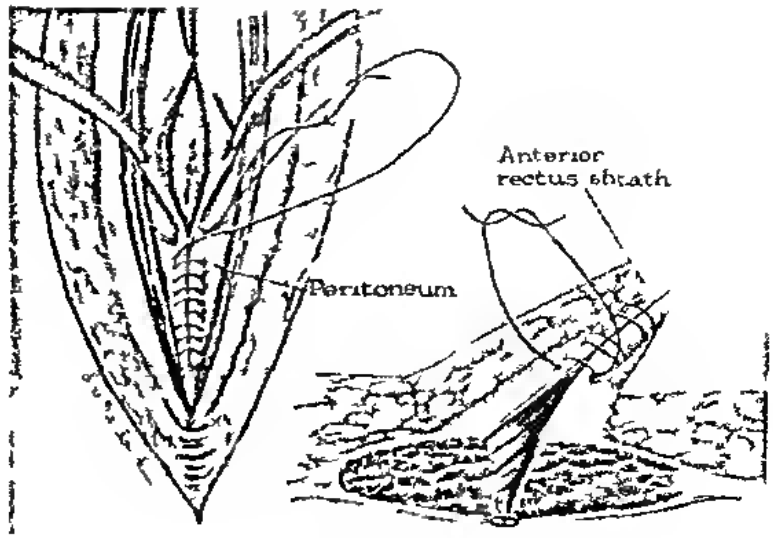


Fig 1 21 Method of approximation of peritoneum and anterior rectus sheath in a rectus incision

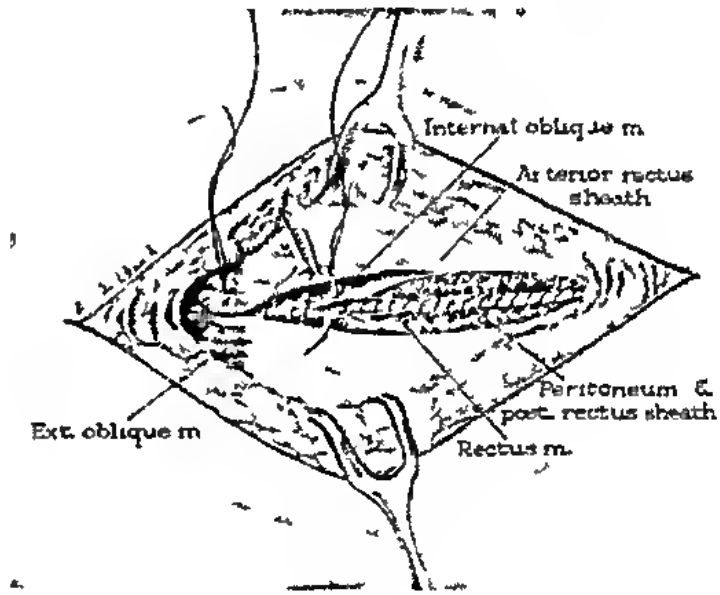


Fig 1 22 Method of closure of transverse incision in layers

the attic of the abdomen when combined with transverse division or fracture of the sternum at the upper angle and gentle retraction of the heart to the right This incision heals surprisingly well with a minimum of added postoperative discomfort

## CLOSURE OF ABDOMINAL INCISIONS

Next to satisfactory completion of the operation that is performed after the peritoneum is opened closure of the incision in the abdominal wall is the most important part of the surgical procedure Successful closure depends upon careful layer by layer approximation of the anatomic structures using only enough appropriately sized cotton or silk sutures to maintain wound apposition, inclusion of only sufficient tissue to hold the sutures adequately and adequate relaxation of the abdominal wall

Wound dehiscence, which occurs in approximately 1 per cent of all laparotomies may be kept at a minimum by correction of malnutrition, hypoproteinemia anemia electrolyte imbalance and vitamin deficiencies, especially that of ascorbic acid Adherence to the Halstedian principles of meticulous and gentle handling of tissues absolute hemostasis, adequate exposure, asepsis, careful layer closure, and the use

of nonabsorbable, small sized sutures should be rigidly observed

The electrocoagulating unit should be used sparingly, since excessive devitalization of tissue leads to greater inflammatory reaction and increases the possibility of infection Pulmonary complications should be anticipated, prevented if possible and treated adequately and immediately if they do occur Early recognition of wound infection may prevent extensive destruction of aponeurotic layers and resultant postoperative hernia or evisceration

Attention should be paid to the prevention and control of abdominal distention Reduction of weight should be achieved preoperatively in obese patients

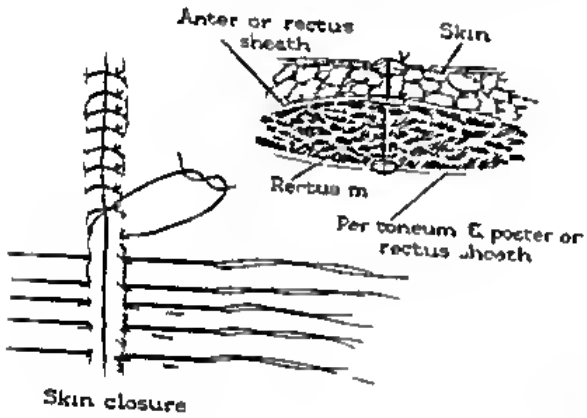


Fig 1 23 Sagittal section of rectus wound closure

During the early postoperative period, undue strain on the incision during ambulation should be prevented by having the patient use an abdominal binder and insuring that he has proper nursing assistance when he gets up from bed

Usually, incisions are closed with continuous absorbable sutures in the peritoneum and transversalis fascia and interrupted nonabsorbable sutures to the fascial layers and skin The peritoneal edges are grasped with fine hemostatic forceps, and the two margins are held in apposition in order to take the tension off the suture line during its placement The peritoneum and posterior sheath are sutured as one layer Doubled No 0 plain or chromic catgut sutures are placed continuously Care is taken to evert the edges of the peritoneum so that visceral adhesions will not occur (Fig 1 21)

Whenever the properitoneal deposition of fat is heavy or the structures are of questionable integrity, these structures are reinforced with interrupted figure of eight sutures of doubled No 40 or No 000 silk Continuous nonabsorbable sutures should not be used in abdominal closure It may be preferable to close the peritoneum with interrupted cotton or silk sutures in certain adult patients and children, many surgeons follow this practice routinely The anterior rectus fascia is approximated

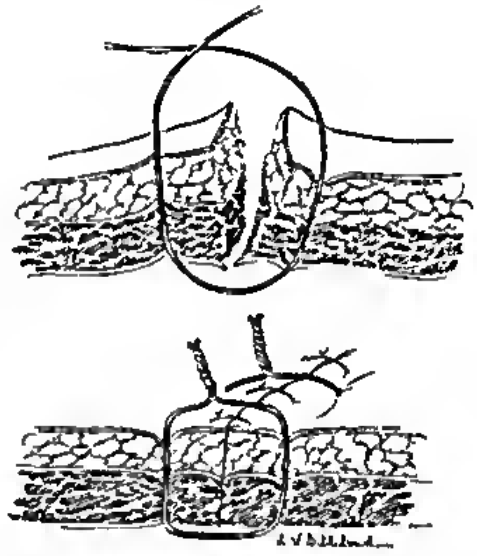

Fig 1 24 Through and through silver wire closure in instances of heavy contamination debility, or dehiscence

with interrupted figure of eight sutures of doubled No 40 cotton The surgeon must make certain that the fascia is definitely grasped for a distance of 0 8 cm to 1 cm from the edge During wound dehiscence, the sutures often tear through the fascial layer if the bite within the grasp of the needle is too small The rectus muscle is not sutured, since it is being attached to the anterior sheath, it is apposed when the edges of the fascia are brought together Muscle fibers are soft, friable, and hold sutures poorly, if they are sewn together they should be sewn loosely

In transverse or diagonal incisions, the internal and external oblique and the

transversalis muscles are sutured separately with interrupted stitches of No 40 cotton in a simple or figure of eight pattern (Fig 1-22)

Superficial fascia or subcutaneous fat is closed with interrupted No 60 or No 100 cotton sutures Very little is added to the tensile strength of the wound by the closure of fat, however, its approximation may prevent the formation of dead space and resultant collection of serum The edges of the skin are carefully approximated with interrupted sutures of No 60 or No 100 cotton or No 0000 silk (Fig 1 23) Interrupted sutures are used in the skin for more careful approximation If infection occurs, it will be possible to remove one or two sutures without disturbing the remainder of the wound Retention sutures of heavy silk, linen, or wire, placed through the fascia before it is closed, are useful in the obese, debilitated, or malnourished patient, or in patients in whom distention, vomiting, coughing, or hiccups may be anticipated

Through and through closure with No 20 silver wire sutures, as recommended by Reid, is carried through all layers and may prevent wound complications in the debilitated, elderly, poorly prepared or very ill patient This technique is also used in patients with extensive peritoneal contamination due to gunshot wounds colonic perforation or peritonitis of long duration During secondary closure after dehiscence or wound disruption it is usually impossible to approximate the friable layers, so that Reid s type of closure becomes necessary (Fig 1 24) This type of closure may also be used when time is a factor in the termination of an operation While there may not be accurate apposition of the various layers, the resultant scar provides a firm closure without hernia in most instances The sutures are usually left in place for two and a half to three weeks

When rubber dam drains are used they are usually brought out through a small stab wound in the dependent part of the abdominal wall closest to the area to be drained Such drains should not be brought directly through an abdominal vertical incision, but may be used in the lateral angles of a transverse or subcostal wound should the drainage tract be a direct one The main wound is thereby safeguarded from the possibility of infection or from subsequent herniation that such a defect might cause

## REFERENCES


Carter N B The combined thoraco-abdominal approach with particular reference to its use in splenectomy *Surg Gynec & Obstet 84* 1019 1947

Chemey, L S Modified transverse incision for low abdominal operations *Surg, Gynec & Obstet 72* 92, 1941

Edwards, L C, and Dunphy, J E Wound healing I Injury and normal repair II Injury and abnormal repair *New England J Med 259* 224 275, 1958

Halsted, W S The employment of fine silk in preference to catgut and the advantages of transfixing tissues and vessels in controlling haemorrhage *J A M A 60* 1119 1913

Hoag, C L A new approach to resection of cancer of the colonic flexures *California and West Med 45* 148 1936

Langer C Zur Anatomie und Physiologie der Haut *Sitzber Kaiserl Akad Wiss (Wien)*, 1861

McBurney C The incision made in the abdominal wall in cases of appendicitis with a description of a new method of operating *Ann Surg 20* 38, 1894

Reid M R, Zinninger, M M and Merrell, P Closure of the abdomen with through and through silver wire sutures in cases of acute abdominal emergencies *Ann Surg 98* 890 1933

Sanders R L Transverse incision in the upper abdomen *Ann Surg 104* 74, 1936

Singleton, A O, and Blocker, T G, Jr, The problem of disruption of abdominal wounds and postoperative hernia *J A M A 112* 122, 1939

Wolff, W I Disruption of abdominal wounds *Ann Surg 131* 534 1950

CHAPTER 2

# PREOPERATIVE PREPARATION

*Walter G Maddock and T Howard Clarke*

## PREOPERATIVE EVALUATION OF THE SURGICAL PATIENT

### General Considerations

The evaluation of a patient for surgery depends upon a knowledge of his general condition and the magnitude of the operative procedure and the greater the latter the greater the need for detailed information about the former A simple operation such as the repair of an inguinal hernia calls more for skill on the part of the surgeon than endurance by the patient so the basic thorough history physical examination blood and urine studies suffice in most cases From these a great deal of information is obtained, including the knowledge that the patient s heart condition is such that he can go about the routine acts of living without dyspnea orthopnea swelling of the feet and legs or chest pain suggesting angina pectoris Those who pass this most important and simple test can stand almost any carefully planned and skilfully executed surgical procedure as far as the heart is concerned but when the operation is of greater magnitude such as gastric colon or pancreatic resections etc, or when significant abnormalities are noted more careful studies of cardiac reserve and other organ functions are in order

In setting up the best possible conditions for a patient coming to surgery it is apparent that the days immediately before an operation can be used to best advantage if a well considered plan is carried out One needs to care for the patient s physical needs as well as his mental concerns

1 As soon as the operation is decided upon tell the patient why and give him some idea of what is going to be done Simple diagrams often help his understanding and are greatly appreciated Ask for and answer questions about the operation A discussion of the finances involved usually helps to set the patient s mind at ease
2 Plan for better use of the time at home before entering the hospital
   a Reduce nonessential activities and increase rest
   b Dietary considerations, if any, food vitamins
   c Drugs etc
   d Reduce excessive consumption of alcohol and tobacco
3 No patient scheduled for a major operative procedure should be admitted to the hospital the night before the operation There are too many things to be done to allow the patient to settle down in preparation for the surgery

4 Time in the hospital before surgery will serve to shorten the postoperative period
   a Allow for better study of the patient
   b Allow for better rapport between the patient and his physician, between the patient and the family, between the patient and the house staff
   c Allow more rest This permits a slowing down from the fast pace of a heavy business, family, or social schedule
   d Provide a period for corrective medications, drugs, foods, vitamins, etc

The additional studies commonly employed in evaluating the general status of a patient are well known and can be listed as follows, somewhat in the order of importance as to the information obtained

Chest roentgenogram may reveal abnormalities of the lung fields, heart and great vessel size and unusual configurations, tracheal displacement, substernal goiter, rib and thoracic spine pathology, levels of diaphragm, presence of fluid, etc
ECG for signs of myocardial ischemia and abnormalities of the conduction system
Stool examination for occult blood, alimentary tract bleeding or the presence of bile or parasites
General metabolism BMR, protein bound iodine, radioiodinated uptake
Blood analyses
   Nonprotein nitrogen, urea clearance creatinine kidney excretion tests
   Total proteins and albumin/globulin ratio for an index of general and protein nutrition and of liver function
   Fasting blood sugar carbohydrate metabolism, pancreatic disease
   Major electrolyte concentrations Na K, Cl, $CO_2$ combining power
Liver function tests
   Bromsulphalein retention
   Prothrombin content, response to vitamin K
   Total bilirubin Van den Bergh direct and indirect
   Thymol turbidity
   Cephalin flocculation
   Cholesterol esters
   Alkaline phosphatase
Circulating fluid volume often deficient in spite of normal hematocrits
Ascorbic acid level for vitamin C deficiency

## The Older Patient

In the past two decades it has become increasingly evident that the well prepared older patient undergoing an operation of even considerable magnitude by a competent surgical team stands the procedure about as well as the younger individual and convalesces satisfactorily unless concurrent disease is great or a serious complication develops

The steps in achieving this low operative mortality among the increasing number of patients over 60 years of age are readily evident

1 A thorough study of the general condition of the patient as well as of the present illness
2 Excellent preoperative care of concurrent disease and of the present illness
3 A skillful anesthetic operative team
4 Intelligent postoperative management, including the anticipation of possible complications and action to avoid them

In 1953 Warren Cole from a study of operability in the young and aged emphasized many important considerations for the older patient The vascular system of the elderly patient has lost varying degrees of elasticity with undoubtedly widespread decreases in general body function, but the various systems are still able to perform if the stress is not too great or too prolonged For example, arteriosclerotic changes in the kidneys tend to renal

dysfunction and the ill effects of arteriosclerotic nephritis, oliguria, and the like are not infrequent Vascular changes in the brain and heart have lowered the blood nutritional support to these structures so that additional decrements from hypoxia, anoxia, anemia, and hypotension are poorly borne Infection has long been recognized as poorly tolerated by the elderly Among others, Bosch and associates noted that of 48 patients past 60 who died following major operations in the antibiotic years of 1947 to 1949 infection was the cause of death in 31 2 per cent eight had peritonitis, six had pneumonia and one had septicemia In addition, 71 per cent of all postoperative complications were due to infections

A chronic degree of malnutrition is likely to be present in the aged They are often poor eaters and frequent avoiders of adequate meat and other protein-rich foods Despite this their tissues heal fairly well Wound dehiscence and separation are not peculiar to them alone, but almost always are associated with increased abdominal tension from vomiting, hiccoughing, coughing, distention, etc The problems offered by those patients with hypoproteinemia are discussed later

The effect of age on various operative procedures as reported by Cole is shown in Table 2-1

It will be noted that in operations where the stress is not great or other vital structures are not often involved in postoperative complications, amputations, appendectomies, radical breast resections, and thyroidectomies, there is no difference in the mortality of the patients under 60 from that of those over 60 Cholecystectomy has always shown a higher mortality rate in the older patient, and the difference is greater when complications are present requiring choledochostomy Glenn's figures also substantiate this fact, he having found a 9 6 per cent mortality rate for choledochostomy in patients past 50 compared to 1 5 per cent for those under 50

Partial gastrectomy in Cole's series offered the unusual situation of a major operative procedure with little difference in the mortality whether under or over 60 years of age Stewart and associates found the same situation, in 203 consecutive gastrectomies for benign ulcer the mor

TABLE 2 1 MORTALITY RATES IN MAJOR OPERATIONS COMPARING PATIENTS UNDER 60 WITH PATIENTS OVER 60*

| Operation | Under 60 years | | | Over 60 years | | | Over-all mortality (%) |
|---|---|---|---|---|---|---|---|
| | Number of cases | Deaths | % Mortality | Number of cases | Deaths | % Mortality | |
| 1 Amputation | 59 | 0 | 0 | 20 | 0 | 0 | 0 |
| 2 Appendectomy | 64 | 0 | 0 | 5 | 0 | 0 | 0 |
| 3 Breast radical | 122 | 0 | 0 | 67 | 0 | 0 | 0 |
| 4 Thyroidectomy | 287 | 0 | 0 | 44 | 0 | 0 | 0 |
| 5 Cholecystectomy | 169 | 0 | 0 | 54 | 1 | 1 8 | 0 4 |
| 6 Choledochostomy | 41 | 0 | 0 | 10 | 1 | 10 0 | 2 0 |
| 7 Colectomy | 43 | 2 | 4 6 | 26 | 2 | 7 7 | 5 7 |
| 8 Gastrectomy for Cancer | 34 | 2 | 5 8 | 36 | 1 | 2 8 | 4 3 |
| 9 Gastrectomy for ulcer | 67 | 1 | 1 5 | 24 | 0 | 0 | 1 1 |
| 10 Intestinal Obstruction | 25 | 2 | 8 0 | 7 | 1 | 14 4 | 9 4 |
| 11 Herniorrhaphy | 313 | 1 | 0 3 | 68 | 1 | 1 5 | 0 5 |
| 12 Oral & Neck Radical | 105 | 1 | 1 0 | 121 | 14 | 11 5 | 6 6 |
| 13 Pneumonectomy | 49 | 6 | 12 2 | 18 | 5 | 27 7 | 16 5 |
| 14 Rectum Radical Resection | 53 | 0 | 0 | 62 | 8 | 11 7 | 6 9 |

* Data from Cole *et al* *Surgery* 37 683 1955

tality rate was 1 25 per cent for patients under 50 years and 1 62 per cent for those over 50 One would expect a greater difference, but the stomach and duodenum have an excellent blood supply and peritonitis from such operations is uncommon As mentioned, peritonitis and other major infections are not tolerated well by the elderly

As operations become more formidable, including greater dissections and blood losses, interference with important physiologic functions of the urinary tract, the liver, the respiratory system and the maintenance of nutrition, the difference between the young and old becomes more apparent In Table 2 1 the operations for intestinal obstruction, radical oral and neck surgery for malignancy, pneumonectomy, and radical resection of the rectum all carried a much greater mortality for patients past 60 For those with oral and gastrointestinal tract lesions a preoperative wide nutritional defect often is present for several months and is correctible only with great difficulty as long as the surgical condition prevails The general plan is to do as much as possible to improve the patient s condition before surgery, operate and remove the pathology, then as quickly as tolerated have the patient eating to build back nutritional elements The reserve of these individuals is low and one major complication is often enough to cause death Complications should be anticipated and avoided by appropriate counteraction Moyer has emphasized that the magnitude of the operation is not as important a determinant of operative risk among the aged as is the duration of the period of physiological upset attending it

## PREOPERATIVE CORRECTION OF SYSTEMIC DEFICITS

### Anemia

Many surgical patients with anemia can not for one reason or another have their surgery postponed and therefore require transfusions of whole blood or packed red cells to correct this blood deficiency before operation Such therapy has been greatly aided by the use of blood banks in the past ten years, but transfusions can be overdone Reactions of one kind or another occur in 3 to 5 per cent of each bottle given and the mortality has been estimated

TABLE 2 2 BLOOD TRANSFUSION *

| *Complication* | *Probable frequency* | *Probable mortality* |
|---|---|---|
| GROUP I COMPLICATIONS OF TRANSFUSION ENDANGERING LIFE | | |
| A ANY TRANSFUSION HOWEVER CAREFULLY PERFORMED | | |
| Hepatitis | 1 in 150 to 1 in 6 000 | 10–20 per cent |
| Unpredictable hemolytic reaction | 1 in 10 000 | 25 per cent |
| Infected blood | 1 in 500 000 | 50 per cent |
| Serologic incompatibility | Should be zero | |
| Total | 1 in 6 000 to 1 in 150 | 1 in 50 000 to 1 in 1 500 |
| B TRANSFUSION IN A HURRY SINGLE WORKER OR INEXPERIENCED TEAM | | |
| Hepatitis | Up to 1 in 100 | 10–20 per cent |
| Infected blood | Up to 1 in 5 000 | 50 per cent |
| Incompatibility | 1 in 1 000 or more | 10 per cent |
| Total | Up to 1 in 95 | Up to 1 in 800 |
| GROUP II UNCOMFORTABLE COMPLICATIONS | | |
| Allergic reactions e g urticaria | about 2 per cent | nil |
| Febrile reactions | from 1–8 per cent | nil |

* George Discombe Blood Transfusion in Souttar and Gallagher *Textbook of British Surgery* vol III *Courtesy* William Heinemann

to be 1 in 1 000 to 3 000 transfusions With approximately 3 million transfusions given in a year in the United States, this amounts to 1 000 deaths from this therapeutic procedure Unfortunately errors in blood typing and cross matching are not more responsible for these deaths than are personnel errors such as wrong labeling of bottles, patients with closely similar names and taking the blood to the wrong operating room Therefore, a definite check by a planned procedure should be made in the operating room to see that the patient receives the right blood

Interestingly, the risk of transfusions is directly proportionate to the haste with which the transfusion is undertaken Discombe reports that transfusions prepared and given in a hurry are twice as hazardous as those given under ideal circumstances (Table 2 2)

Obviously if the urgency of the situation demands immediate transfusion the added risk must be accepted But the careful surgeon by the proper preoperative preparation of his patient and by a judicious estimate of the need for blood during surgery will have an adequate amount of cross matched blood readily available before the operation is started In this way he will reduce transfusion hazards

## Indications for Blood Transfusions

Surgical or hypovolemic shock is a most common indication for plasma or blood transfusions It is an acute reaction to a rapidly reduced circulating blood volume It can be brought about by a number of ways listed in Table 2 3

It should also be remembered that all patients with burns peritonitis or extensive operations such as abdominal perineal resections of the rectum or thoracotomies lose considerable amounts of protein-containing fluid into body cavities or by drainage and generally show a decrease in the total serum protein level of 1 Gm in the first postoperative week The early ingestion of food is essential and failure to begin eating soon or uncommon pallor, lethargy and weakness should call for an immediate study of the blood condition and ready recourse to transfusions

Transfusions usually are required for the preparation of patients with aplastic and hemolytic anemias In the presence of severe or prolonged infection, uremia or malignancy it may be impossible to relieve a severe anemia without multiple transfusions However, if time is not a critical factor, and if diet and medication will correct the blood deficit, there is little excuse for the use of preoperative transfusions

TABLE 2 3 PATHOGENESIS OF HYPOVOLEMIC HYPOTENSION (SURGICAL SHOCK)*

A Blood loss
  1 External as in lacerations amputations bleeding ulcer etc
  2 Internal as in femoral fracture crushing injury ruptured spleen or liver ectopic pregnancy etc
B Plasma loss
  1 External as in burns where blood may also be lost
  2 Internal as in peritonitis
  3 Crushing injury where generally more blood is lost than plasma
C Water deprivation Electrolytes are concentrated and not lost The therapy is water without salt
D Water loss Vomiting intestinal obstruction pancreatic or biliary fistulas and diarrhea Electrolytes also are lost and the therapy is water with electrolytes

*J G Allen and E A Stemmer The Use of Blood and Plasma in Surgical Practice Surgical Clinics of North America December 1955 Courtesy W B Saunders Company

ACUTE HEMORRHAGE This is the most frequent cause of hypovolemic shock among surgical patients and obviously needs correction before the effect becomes irreversible The important signs of serious blood loss have been well summarized by Allen and Stemmer First is the rise in pulse rate that represents the activation of adrenergic reflexes arising out of reduced blood volume and the reduced venous and intra atrial pressure Next is the drop in systolic arterial pressure, which usually does not occur in the well nourished and hydrated adult until after 800 to 1500 ml

of blood has been lost Neither the rise in pulse rate nor the fall in arterial pressure makes its appearance until the volume of blood loss is greater than can be compensated for by vasoconstriction Only then is the pulse rate accelerated in an efficient effort to maintain the systolic pressure by increasing cardiac output If the bleeding continues, the increased pulse rate fails to prevent a fall in systolic pressure The rise *in pulse rate is a late sign of hypovolemia* and the fall in arterial pressure an even later one The rise in pulse rate heralds the fact that the volume of blood lost already is too great for the compensating capacity of vasoconstriction The time to start blood replacement is when a rise in pulse rate first appears

BLOOD NEED DURING AND AFTER OPERATION The surgeon, his assistants, and the anesthesiologist together comprise the transfusion team in the operating room Just as the surgeon frequently is the first to observe the effects of anoxemia, the anesthesiologist may be the *first to* notice the magnitude of the blood loss An increasing pulse rate, a narrowing of the pulse pressure, a suction bottle filling with blood and a mounting pile of sponges and laparotomy pads are easily observed by the alert anesthesiologist while they may go almost unnoticed by the surgeon and his assistants engaged with mechanical problems in the abdomen It is the duty of the anesthesiologist so to advise the surgeon, and it is then the obligation of the surgeon to decide what are the patient's transfusion needs As a general rule the estimated blood loss is less than the actual amount shed (Table 2-4), and the discrepancy may well be 30 to 50 per cent below the actual figure It would be good training for all surgeons, for a time at least, to weigh used sponges and pads to gain experience on the volumes involved since once correct observations are made the lessons are never forgotten

If the patient comes to surgery with an adequate blood volume and with a hematocrit in the range of 40 to 48 per cent, his blood replacement needs will depend upon the amount of blood lost at the operation *Minor to moderate blood losses* do not need to be replaced since well-nourished patients with normal hemograms are able to adjust to losses up to 500 to 600 ml without difficulty Blood transfusions should be given for loss beyond this figure

If, on the other hand the patient comes to surgery with a diminished blood volume or with a markedly lowered hematocrit, his need for blood may far exceed the amount indicated by the blood lost This

TABLE 2 4 BLOOD LOSS IN OPERATIONS OF VARIOUS KINDS*

| Operations | Blood loss: Maximum, cc | Blood loss: Minimum cc | Blood loss: Average, cc |
|---|---|---|---|
| Biliary operations | 400 | 51 | 100 |
| Gastric operations | 650 | 45 | 233 |
| Splenectomies | 990 | 160 | 525 |
| Intestinal operations above sigmoid | 230 | 10 | 81 |
| Sigmoidal rectal and anal operations | 1 220 | 8 | 377 |
| Hernia operations | 306 | 11 | 74 |
| Miscellaneous abdominal operations | 546 | 14 | 218 |
| Pelvic operations | 680 | 22 | 266 |

* Frederick A Coller *et al* Blood Loss in Surgical Operations Chairman's Address *J A M A* Sept 2 1944 courtesy Journal American Medical Association

situation most frequently arises in inadequately prepared patients with unrecognized or uncontrolled bleeding and in those patients who are malnourished and chronically ill Under these circumstances a blood transfusion may be urgently needed early in the operation and before any appreciable amount of blood has been lost

As stated, the time to start blood replacement in the operating room on patients with initially normal hemograms is when a rise in pulse rate occurs and not later when arterial pressure falls, particularly in operations of some magnitude that are not near completion The alert surgeon will do even better by having

blood started when he knows blood loss has been 300 to 350 ml and from the nature of the operation is likely to continue at the same rate For operations of known high blood loss or for certain patients with hypoproteinemia a transfusion is started as soon as the operation is started

For operations of lesser magnitude such as thyroidectomy appendectomy cholecystectomy and large hernial repairs blood transfusions can usually be avoided and an additional risk thus eliminated

Allen stresses the point that often glucose in water plus the use of six month old liquid plasma will suffice to offset the more moderate blood losses and avoid the errors of typing and cross matching or the dangers of transmitting hepatitis through whole blood Allen also offers the intriguing thought that if one blood transfusion is enough to offset suspected hypovolemic shock then the situation is rather mild and 500 ml of plasma would probably do equally well He considers that if blood is needed in the surgical patient more than one transfusion is generally indicated A single transfusion makes no significant improvement in the patient with anemia and is too small a therapeutic effort in severe hypovolemic shock

Very rarely there may be need for intra arterial transfusion This is most likely to occur during surgery as the result of a sudden exsanguinating hemorrhage Then if accessible a large needle may be inserted toward the heart into the aorta or some other large artery and blood may be forced rapidly into the arterial circulation The common carotid brachial radial femoral and iliac arteries may be used for such arterial transfusions The risk of renewed uncontrolled bleeding following arterial transfusion limits the value of this procedure in the emergency treatment of patients with severe blood loss and in general the procedure has not gained much favor

### *Hazards of Transfusion*

BLOOD BANK ERRORS Typing and cross matching errors are responsible for most of the reactions from blood transfusions and may be due to mistakes in the primary type (AB A B and O) or in the proper identification of the Rh factor When high titer antisera are used for the tests these errors are reduced Other common causes of reactions are the clerical error of mislabeling the blood or confusing two recipient patients of similar names or bringing the blood to the wrong operating room The decision in the operating room to give a transfusion should be made by the operating surgeon usually with information given by the anesthetist Each bottle of blood should be checked by the surgeon or his resident as to type and recipient s name before transfusion is started This simple procedure has often obviated important errors

HEPATITIS About one in every 150 donors is believed to harbor the hepatitis virus and yet be undetectable by careful screening measures Fortunately only one in four receiving such blood develops hepatitis making an attack rate of about one in 600 Most figures place the incidence of transfusion hepatitis at 0 2 to 0 5 per cent which is a very appreciable disease incidence to be avoided when possible since virus hepatitis is a serious disease

Pooled plasma stored at room temperature for six months will not transmit the hepatitis virus nor will any other virus survive for this period Therefore each unit of plasma that can be substituted for a whole blood transfusion is a factor of safety for the patient It should be emphasized that drying freezing and refrigerating plasma do not result in the death of viruses as does six month storage at room temperature Use of plasma treated in the former manner is material to be avoided

OVERTRANSFUSION This danger is of not uncommon occurrence where transfusions are used enthusiastically Anxiety for a bleeding patient s life often pushes the administration of too much blood and may cause the death of the patient The effects of overtransfusion are listed in Table 2 5

Guynn and Reynolds point out that ex

eess transfusions do not produce arterial hypertension but do cause cardiovascular overfilling, and, after failure has begun, hypotension appears with terminally moist rales and voluminous frothy sputum During operations of potentially great blood loss and many transfusions they have adopted the safeguard of assigning one house officer to do nothing else but check on the volume of blood lost and correlate

TABLE 2 5 HAZARDS OF OVERTRANSFUSION*

| *Physiological effect* | *Clinical signs* |
|---|---|
| Increased blood volume | Circulatory overloading resulting in right heart failure and pulmonary edema |
| High hematocrit | Restlessness<br>Cyanosis<br>Rapid pulse rate<br>Rapid respiration<br>Venous distention<br>Increased venous pressure<br>Hypotension<br>Moist rales<br>Frothy sputum |
| Increased blood viscosity | Tendency to thrombosis |
| Citrate intoxication | Low ionized calcium<br>Cardiac arrest in diastole<br>Impaired clotting |
| Hyperkalemia | Cardiac irritability and arrest in diastole |
| Ammonia intoxication | Stupor and coma |

* V L Guynn and J T Reynolds The Use and Abuse of Blood Transfusions *Surg al Clinics of North America* February 1958 p 19 *Courtesy* W B Saunders Company

it with the amount of blood transfused This procedure frees the surgeon and the anesthetist for the other important parts of their job This precaution is doubly important in patients with limited cardiac reserve or a history of some degree of coronary disease

Treatment of overtransfusion is venapuncture and the rather rapid withdrawal of 500 ml of blood into a transfusion bottle Relief of heart strain and pulmonary edema often occurs within a few minutes and a second bloodletting rarely is necessary But when it has to be done some soul searching on the part of the medical staff is necessary to account for the dangerous condition being allowed to develop

CITRATE INTOXICATION This danger arises from the appreciable amounts of citrate solution administered when multiple transfusions are necessary It seems to remove ionized calcium from the blood, which impairs muscular sensitivity, and is a particular hazard in patients with poor renal function or hepatic damage It may be prevented by giving 1 Gm of calcium gluconate after every 1,000 to 1,500 ml of blood

POTASSIUM INTOXICATION This is a theoretical danger, more possible with bank blood kept in the icebox for several weeks, during which time slow hemolysis has increased the serum potassium content The possibility should be considered in any case where potassium retention is likely to occur In practice it is well not to use any bank blood more than ten days old, this same rule also lessens the chances of bacterial contamination

HEMOLYTIC REACTION UNDER ANESTHESIA Hemolytic reactions still constitute one of the serious complications of transfusions The clinical manifestations of a severe reaction are characteristic and usually occur soon after starting the blood or immediately after completion of the transfusion Commonly, the first symptoms are a tingling general sense of discomfort and anxiety, followed by lumbar pain, a feeling of constriction in the chest, cold clammy skin, a decrease in blood pressure, increase in pulse rate, and cyanosis Air hunger, nausea, and vomiting may be marked

Under anesthesia, where many transfusions of blood are given, these symptoms and signs are masked and the only indication of an untoward reaction is severe oozing from the whole operative area The surgeon observes that he cannot stop the bleeding If a sample of the patient's blood is immediately drawn, definite evidence of free hemoglobin in the serum is found There may be marked oozing of blood also from the transfusion site, the gums, uterus, or skin incision

blood started when he knows blood loss has been 300 to 350 ml and from the nature of the operation is likely to continue at the same rate For operations of known high blood loss or for certain patients with hypoproteinemia a transfusion is started as soon as the operation is started

For operations of lesser magnitude, such as thyroidectomy, appendectomy, cholecystectomy, and large hernial repairs, blood transfusions can usually be avoided, and an additional risk thus eliminated

Allen stresses the point that often glucose in water plus the use of six month old liquid plasma will suffice to offset the more moderate blood losses and avoid the errors of typing and cross matching or the dangers of transmitting hepatitis through whole blood Allen also offers the intriguing thought that if one blood transfusion is enough to offset suspected hypovolemic shock, then the situation is rather mild and 500 ml of plasma would probably do equally well He considers that if blood is needed in the surgical patient, more than one transfusion is generally indicated A single transfusion makes no significant improvement in the patient with anemia and is too small a therapeutic effort in severe hypovolemic shock

Very rarely there may be need for intra arterial transfusion This is most likely to occur during surgery as the result of a sudden exsanguinating hemorrhage Then if accessible, a large needle may be inserted toward the heart into the aorta or some other large artery and blood may be forced rapidly into the arterial circulation The common carotid, brachial, radial, femoral and iliac arteries may be used for such arterial transfusions The risk of renewed uncontrolled bleeding following arterial transfusion limits the value of this procedure in the emergency treatment of patients with severe blood loss and in general the procedure has not gained much favor

### *Hazards of Transfusion*

BLOOD BANK ERRORS Typing and cross matching errors are responsible for most of the reactions from blood transfusions, and may be due to mistakes in the primary type (AB, A, B, and O) or in the proper identification of the Rh factor When high titer antisera are used for the tests these errors are reduced Other common causes of reactions are the clerical error of mislabeling the blood, or confusing two recipient patients of similar names, or bringing the blood to the wrong operating room The decision in the operating room to give a transfusion should be made by the operating surgeon, usually with information given by the anesthetist Each bottle of blood should be checked by the surgeon or his resident as to type and recipient's name before transfusion is started This simple procedure has often obviated important errors

HEPATITIS About one in every 150 donors is believed to harbor the hepatitis virus and yet be undetectable by careful screening measures Fortunately only one in four receiving such blood develops hepatitis making an attack rate of about one in 600 Most figures place the incidence of transfusion hepatitis at 0 2 to 0 5 per cent, which is a very appreciable disease incidence to be avoided when possible, since virus hepatitis is a serious disease

Pooled plasma stored at room temperature for six months will not transmit the hepatitis virus, nor will any other virus survive for this period Therefore, each unit of plasma that can be substituted for a whole blood transfusion is a factor of safety for the patient It should be emphasized that drying, freezing, and refrigerating plasma do not result in the death of viruses as does six month storage at room temperature Use of plasma treated in the former manner is material to be avoided

OVERTRANSFUSION This danger is of not uncommon occurrence where transfusions are used enthusiastically Anxiety for a bleeding patient s life often pushes the administration of too much blood and may cause the death of the patient The effects of overtransfusion are listed in Table 2 5

Guynn and Reynolds point out that ex

cess transfusions do not produce arterial hypertension but do cause cardiovascular overfilling, and, after failure has begun, hypotension appears with terminally moist rales and voluminous frothy sputum During operations of potentially great blood loss and many transfusions they have adopted the safeguard of assigning one house officer to do nothing else but check on the volume of blood lost and correlate

TABLE 2 5 HAZARDS OF OVERTRANSFUSION*

| *Physiological effect* | *Clinical signs* |
|---|---|
| *Increased blood volume* | *Circulatory overloading* resulting in right heart failure and pulmonary edema |
| High hematocrit | Restlessness<br>Cyanosis<br>Rapid pulse rate<br>Rapid respiration<br>Venous distention<br>Increased venous pressure<br>Hypotension<br>Moist rales<br>Frothy sputum |
| Increased blood viscosity | Tendency to thrombosis |
| Citrate intoxication | Low ionized calcium<br>Cardiac arrest in diastole<br>Impaired clotting |
| Hyperkalemia | Cardiac irritability and arrest in diastole |
| Ammonia intoxication | Stupor and coma |

* S L Guynn and J T Reynolds, The Use and Abuse of Blood Transfusions *Surgical Clinics of North America* February 1958 p 19 Courtesy W B Saunders Company

it with the amount of blood transfused This procedure frees the surgeon and the anesthetist for the other important parts of their job This precaution is doubly important in patients with limited cardiac reserve or a history of some degree of coronary disease

Treatment of overtransfusion is venapuncture and the rather rapid withdrawal of 500 ml of blood into a transfusion bottle Relief of heart strain and pulmonary edema often occurs within a few minutes and a second bloodletting rarely is necessary But when it has to be done some soul searching on the part of the medical staff is necessary to account for the dangerous condition being allowed to develop

CITRATE INTOXICATION This danger arises from the appreciable amounts of citrate solution administered when multiple transfusions are necessary It seems to remove ionized calcium from the blood, which impairs muscular sensitivity, and is a particular hazard in patients with poor renal function or hepatic damage It may be prevented by giving 1 Gm of calcium gluconate after every 1,000 to 1,500 ml of blood

POTASSIUM INTOXICATION This is a theoretical danger, more possible with bank blood kept in the icebox for several weeks, during which time slow hemolysis has increased the serum potassium content The possibility should be considered in any case where potassium retention is likely to occur In practice it is well not to use any bank blood more than ten days old, this same rule also lessens the chances of bacterial contamination

HEMOLYTIC REACTION UNDER ANESTHESIA Hemolytic reactions still constitute one of the serious complications of transfusions The clinical manifestations of a severe reaction are characteristic and usually occur soon after starting the blood or immediately after completion of the transfusion Commonly, the first symptoms are a tingling general sense of discomfort and anxiety, followed by lumbar pain, a feeling of constriction in the chest, cold clammy skin, a decrease in blood pressure, increase in pulse rate, and cyanosis Air hunger, nausea, and vomiting may be marked

Under anesthesia, where many transfusions of blood are given, these symptoms and signs are masked and the only indication of an untoward reaction is severe oozing from the whole operative area The surgeon observes that he cannot stop the bleeding If a sample of the patient's blood is immediately drawn, definite evidence of free hemoglobin in the serum is found There may be marked oozing of blood also from the transfusion site, the gums, uterus, or skin incision

blood started when he knows blood loss has been 300 to 350 ml and from the nature of the operation is likely to continue at the same rate For operations of known high blood loss or for certain patients with hypoproteinemia a transfusion is started as soon as the operation is started

For operations of lesser magnitude such as thyroidectomy appendectomy cholecystectomy and large hernial repairs blood transfusions can usually be avoided and an additional risk thus eliminated

Allen stresses the point that often glucose in water plus the use of six month old liquid plasma will suffice to offset the more moderate blood losses and avoid the errors of typing and cross matching or the dangers of transmitting hepatitis through whole blood Allen also offers the intriguing thought that if one blood transfusion is enough to offset suspected hypovolemic shock then the situation is rather mild and 500 ml of plasma would probably do equally well He considers that if blood is needed in the surgical patient more than one transfusion is generally indicated A single transfusion makes no significant improvement in the patient with anemia and is too small a therapeutic effort in severe hypovolemic shock

Very rarely there may be need for intra arterial transfusion This is most likely to occur during surgery as the result of a sudden exsanguinating hemorrhage Then if accessible a large needle may be inserted toward the heart into the aorta or some other large artery and blood may be forced rapidly into the arterial circulation The common carotid brachial radial femoral and iliac arteries may be used for such arterial transfusions The risk of renewed uncontrolled bleeding following arterial transfusion limits the value of this procedure in the emergency treatment of patients with severe blood loss and in general the procedure has not gained much favor

### *Hazards of Transfusion*

BLOOD BANK ERRORS Typing and cross matching errors are responsible for most of the reactions from blood transfusions and may be due to mistakes in the primary type (AB A B and O) or in the proper identification of the Rh factor When high titer antisera are used for the tests these errors are reduced Other common causes of reactions are the clerical error of mislabeling the blood or confusing two recipient patients of similar names or bringing the blood to the wrong operating room The decision in the operating room to give a transfusion should be made by the operating surgeon usually with information given by the anesthetist Each bottle of blood should be checked by the surgeon or his resident as to type and recipient s name before transfusion is started This simple procedure has often obviated important errors

HEPATITIS About one in every 150 donors is believed to harbor the hepatitis virus and yet be undetectable by careful screening measures Fortunately only one in four receiving such blood develops hepatitis making an attack rate of about one in 600 Most figures place the incidence of transfusion hepatitis at 0 2 to 0 5 per cent which is a very appreciable disease incidence to be avoided when possible since virus hepatitis is a serious disease

Pooled plasma stored at room temperature for six months will not transmit the hepatitis virus nor will any other virus survive for this period Therefore each unit of plasma that can be substituted for a whole blood transfusion is a factor of safety for the patient It should be emphasized that drying freezing and refrigerating plasma do not result in the death of viruses as does six month storage at room temperature Use of plasma treated in the former manner is material to be avoided

OVERTRANSFUSION This danger is of not uncommon occurrence where transfusions are used enthusiastically Anxiety for a bleeding patient s life often pushes the administration of too much blood and may cause the death of the patient The effects of overtransfusion are listed in Table 2 5

Guynn and Reynolds point out that ex

cess transfusions do not produce arterial hypertension but do cause cardiovascular overfilling, and, after failure has begun, hypotension appears with terminally moist rales and voluminous frothy sputum During operations of potentially great blood loss and many transfusions they have adopted the safeguard of assigning one house officer to do nothing else but check on the volume of blood lost and correlate

TABLE 2 5 HAZARDS OF OVERTRANSFUSION*

| *Physiological effect* | *Clinical signs* |
|---|---|
| Increased blood volume | Circulatory overloading resulting in right heart failure and pulmonary edema |
| High hematocrit | Restlessness<br>Cyanosis<br>Rapid pulse rate<br>Rapid respiration<br>Venous distention<br>Increased venous pressure<br>Hypotension<br>Moist rales<br>Frothy sputum |
| Increased blood viscosity | Tendency to thrombosis |
| Citrate intoxication | Low ionized calcium<br>Cardiac arrest in diastole<br>Impaired clotting |
| Hyperkalemia | Cardiac irritability and arrest in diastole |
| Ammonia intoxication | Stupor and coma |

* V L Guynn and J T Reynolds The Use and Abuse of Blood Transfusions *Surgical Clinics of North America* February 1958 39 19 *Courtesy* W B Saunders Company

it with the amount of blood transfused This procedure frees the surgeon and the anesthetist for the other important parts of their job This precaution is doubly important in patients with limited cardiac reserve or a history of some degree of coronary disease

Treatment of overtransfusion is vena puncture and the rather rapid withdrawal of 500 ml of blood into a transfusion bottle Relief of heart strain and pulmonary edema often occurs within a few minutes and a second bloodletting rarely is necessary But when it has to be done some soul searching on the part of the medical staff is necessary to account for the dangerous condition being allowed to develop

CITRATE INTOXICATION This danger arises from the appreciable amounts of citrate solution administered when multiple transfusions are necessary It seems to remove ionized calcium from the blood, which impairs muscular sensitivity, and is a particular hazard in patients with poor renal function or hepatic damage It may be prevented by giving 1 Gm of calcium gluconate after every 1 000 to 1,500 ml of blood

POTASSIUM INTOXICATION This is a theoretical danger, more possible with bank blood kept in the icebox for several weeks, during which time slow hemolysis has increased the serum potassium content The possibility should be considered in any case where potassium retention is likely to occur In practice it is well not to use any bank blood more than ten days old this same rule also lessens the chances of bacterial contamination

HEMOLYTIC REACTION UNDER ANESTHESIA Hemolytic reactions still constitute one of the serious complications of transfusions The clinical manifestations of a severe reaction are characteristic and usually occur soon after starting the blood or immediately after completion of the transfusion Commonly, the first symptoms are a tingling, general sense of discomfort and anxiety, followed by lumbar pain, a feeling of constriction in the chest cold, clammy skin, a decrease in blood pressure, increase in pulse rate, and cyanosis Air hunger, nausea, and vomiting may be marked

Under anesthesia where many transfusions of blood are given these symptoms and signs are masked and the only indication of an untoward reaction is severe oozing from the whole operative area The surgeon observes that he cannot stop the bleeding If a sample of the patient's blood is immediately drawn, definite evidence of free hemoglobin in the serum is found There may be marked oozing of blood also from the transfusion site, the gums, uterus, or skin incision

The subsequent reaction may be mild or severe Postoperatively mild jaundice may occur but a more serious sequela is anuria or oliguria as a part of the lower nephron nephrosis syndrome

## Hypoproteinemia

Hypoproteinemia is one measurable and very important index of a deficient nutritional status in a sick patient and is a common finding in many surgical conditions The need for understanding important biochemical aspects of protein metabolism is so fundamental to the correction of hypoproteinemia in the surgical patient that a brief review of some of the basic concepts is presented

The daily protein requirement for an adult is commonly stated to be 1 Gm per kilogram of body weight This is an optimum figure by U S standards but many other peoples continue to be healthy with less than this amount The average sized pregnant woman is estimated to need 85 Gm of protein and the lactating woman 100 Gm daily to provide for herself and the baby Infants and children are considered to need 3 to 4 Gm of protein per kilogram of body weight per day to keep up with their tremendous growth requirements

Most surgical patients come to operation in satisfactory general condition This includes the great bulk of patients with acute trauma general surgical and gynecologic conditions rectal surgery eye ear nose and throat surgery In contrast, a small but definite percentage present themselves with varying degrees of malnutrition and hypoproteinemia the causes of which can be listed as follows

- Starvation insufficient food into alimentary tract
  - Carcinoma of oral cavity
  - Esophageal obstruction
  - Pyloric obstruction
  - Anorexia and asthenia
    - From protein starvation
    - Miscellaneous causes malignancy infection etc.
- Altered protein absorption
  - Diarrhea
  - Ulcerative colitis
  - Gastrojejunocolic fistula
  - Intestinal cutaneous fistula
  - Altered gastrointestinal mucosa after prolonged starvation
- Altered protein synthesis
  - Hepatic disease
    - Depressed albumin formation
    - Protein loss with ascites
- Excessive protein loss
  - Through kidneys nephritis
  - From vascular system
    - Whole blood operations or accidental trauma
    - Plasma large open wounds or burns
  - Serosal surfaces
    - Extensive suppurations empyema peritonitis

The surgical patient with any suggestion of nutritional deficiency should ingest a plentiful supply of protein a minimum of 100 Gm being considered desirable and more if possible up to a maximum of 300 to 400 Gm in exceptional circumstances of great protein losses such as for extensive burns

### *Effects of Protein Deficiency in Surgical Patients*

Experimental studies on animals and clinical observations over many years have well established the effects of protein deficiency One indication of this condition is a fall in the total serum protein from the normal of 6 5 to 7 Gm per 100 milliliters and a corresponding decrease in the albumin fraction In contrast there is little change in the serum globulins in protein depletion The plasma proteins particularly fibrinogen and albumin are largely manufactured in the liver whereas the globulin may be partly synthesized by the reticuloendothelial system Important to remember is the repeated evidence that measurable decreases in the plasma albumin concentration occur only after a severe loss of body proteins As a corollary refeeding experiments show such a slow

return of the plasma proteins to normal that it is evident the replenishment of the organ responsible for the formation of albumin and other protein replacements must first take place

Another point of importance is that valuable as the estimation of the serum protein level may be, it can be misleadingly high owing to a reduced plasma volume The latter is often a more sensitive index of protein deficiency This will be discussed later

DELAYED WOUND HEALING Innumerable experiments on animals have substantiated the clinical observations that the wounds of poorly nourished patients do not heal as well as those in good general condition In 1919, Clark showed on dogs that the long phase of wound healing was markedly shortened by a high protein diet Thompson, Ravdin, and Frank in 1938 found the reduced fibroplasia of severe hypoproteinemia to be quickly overcome if the plasma proteins were restored by an adequate house diet at the time the test incision was made

EDEMA, GENERAL AND LOCAL Starling first stressed the great role of the plasma proteins in drawing fluid from the tissues into the capillaries and that the major responsibility for this osmotic effect lay with the albumin fraction Low plasma proteins were then soon recognized as a precursor of edema and Moore and Van Slyke worked out the levels below which edema tended to develop, i e , a total protein of 5 5 Gm per 100 milliliters or albumin of 2 5 Gm per 100 milliliters With greater intakes of sodium chloride edema will occur at even higher levels Also, there is plenty of evidence to show that decreases in serum protein levels much less than the edema level indicate a substantial depletion of the labile protein in the body At the edema level figures, body protein is tremendously down and the situation is critical

Jones and Eaton were among the first to study edema in surgical patients and recognized the common factor of hypoproteinemia usually associated with long-inadequate diets Of 34 preoperative and postoperative patients about whom they were consulted

- 26 showed clinical edema of dependent parts
- 21 had diseases of the digestive tract
- 17 had a history of anorexia and marked undernutrition
- 8 had edema of the extremities postoperatively
- 5 had edema of the lungs
- 3 had edema of the stomach and intestines at operation
- 8 had partial obstruction of a gastroenterostomy stoma
- 4 had diarrhea from edema of the intestinal wall
- 1 died from obstruction owing to edema of the intestinal wall

Jones and Eaton recognized the part played by the excessive administration of saline solutions intravenously to these patients and that the immediate danger could be largely avoided by substituting a solution of 5 or 10 per cent glucose in distilled water Modern practice follows this rule and sodium chloride is given sparingly to patients unless there are abnormal losses of electrolytes from the gastrointestinal tract by vomiting, diarrhea suction, etc

Concerning gastroenterostomy stoma dysfunction, Mecray Barden, and Ravdin showed in animals that the gastric emptying time and the time the head of a water barium meal took to traverse the small bowel were both increased in inverse proportion to the concentration of protein in the plasma The lower the plasma proteins the longer the time for the stomach to empty and the barium to reach the cecum Swelling at the site of a traumatic injury is also increased by hypoproteinemia

GREATER SUSCEPTIBILITY TO SHOCK This has long been recognized in the hypoproteinemic animal, and more attention should be paid to it in the hypoproteinemic patient Whipple and associates in 1921 reported shock as a manifestation of tissue injury following plasma

protein depletion by plasmapheresis Ravdin, McNamee, Kamholz, and Rhoads added significant figures in their finding that whereas an average of 45 ml of blood per kilogram of body weight had to be removed in order to produce a hypotension of 60 or less lasting 30 minutes in normal dogs, an average of only 25 ml of blood per kilogram of body weight was sufficient to bring about this state in hypoproteinemic dogs depleted of protein by plasmapheresis and a low protein diet Elman's studies emphasized further what all surgeons should remember, i e, that in the presence of hypoproteinemia shock develops from very slight losses of blood and without treatment a great decrease in the already low plasma protein concentration ensues

LOWERED RESISTANCE TO INFECTION A great deal of evidence supports the thesis that with hypoproteinemia there is a lowered resistance to infection With the endemic occurrences of malnutrition in areas of the world the incidence of infection has always been higher In 1937, G H Whipple, that superb investigator of hypoproteinemia and its effects, showed that protein depleted dogs were very susceptible to infection and that once infection had developed the usual methods for the successful regeneration of plasma proteins were much slower in action The mortality rate of rats infected with living pathogenic bacilli is greatly increased by hypoproteinemia Cannon and his associates demonstrated this lowered resistance to infection in many ways and showed among other things that the experimental animal s ability to produce agglutinins to antigens such as killed typhoid bacilli is much reduced by the hypoproteinemic state

With infections still playing a considerable part in the morbidity and mortality of operations, particularly for the older patient, the need is evident for preoperative improvement in the nutritional status of depleted patients, if at all possible If it is not accomplished the fact should be due to inability to do so, rather than failure to consider the need

GREATER SUSCEPTIBILITY TO LIVER DAMAGE At one time it was thought that carbohydrate per se protected the liver of experimental animals against chloroform damage Later evidence indicated that the beneficial effect from sugar was due to its "protein sparing" action In 1939 Goldschmidt, Vars, and Ravdin demonstrated on rats that the major protection afforded the liver to injury by chloroform was related to the liver's protein content They found a progressive increase of liver necrosis after chloroform anesthesia as the liver fat content increased, and this was independent of glycogen content Whatever benefit apparent from glycogen was obtained by replacement of fat Protein feeding was outstanding in reducing the liver necrosis of chloroform, even in those livers with a high lipid content It is significant that animal studies have shown that in the course of protein depletion the liver loses protein, decreases in size, and becomes soft and fatty

From clinical observations there is every reason to believe that in the presence of hypoproteinemia human livers emulate the unfavorable conditions found in the experimental animals Consequently when a nutritional deficiency is evident in a patient, an attempt should be made to correct it preoperatively If this is impossible, one should restore hemoglobin and blood volume levels to normal by transfusions, operate to correct the surgical condition and return the patient to eating a normal diet as quickly as possible

LOWERED CIRCULATING BLOOD VOLUME Blood volume studies are being used more extensively now than ever before The plasma labels most widely employed are the Evans blue dye, (T 1824) and more recently radioiodinated serum proteins Each method properly employed is accepted as reliably measuring the plasma volume

Primary disturbances of whole blood volume are best exemplified by the sudden decrease in total blood volume resulting from internal or external hemorrhage, and are at first corrected by expansion of plasma volume alone, there being no im

mediately available reserve store of erythrocytes With only slight or moderate blood losses, full compensation or even transient overcompensation may be observed With more severe acute losses, the failure of compensation leads to the syndrome of clinical shock In such cases the blood volume is reduced at least 30 or 40 per cent below normal, and the clinical picture parallels closely the reduction in circulating blood volume Plasma volume studies are valuable additions to other data in the management of acute hemorrhage

A very important contribution of blood volume studies is the finding that subacute or chronically ill patients without a history of gross bleeding but usually with at least a moderate nutritional deficiency may show deficits of plasma volume up to 1 5 liters and of whole blood up to 3 liters The hematocrit or hemoglobin levels may not mirror this deficiency and thus be misleading The astute surgeon confronted with a patient who has recently lost considerable weight through disease will assume the plasma volume level is low and use this estimation in the preoperative care of the patient or check it by one of the tests before surgery Transfusions will probably be indicated if dietary correction is not possible

### *Protein Depletion After Operation*

Plasma protein levels almost always fall appreciably after major operations In a series of thoracic surgery operations without preoperative hypoproteinemia and with careful replacement of all blood lost at operation, Thornton found an average decrease in the plasma protein concentration of 1 Gm per 100 milliliters in 31 of 32 patients within the first postoperative week Operations for carcinoma of the colon and for intestinal obstruction are followed by a 25 per cent drop in the plasma proteins and Ariel reported greater decreases in patients with cancer of the gastrointestinal tract than for other patients Protein losses following severe burns are notoriously high several groups finding plasma protein levels down to 3 0 to 5 0 Gm per 100 milliliters in such patients even following strenuous measures to combat such a fall

For patients with major surgical lesions, postoperative care considers protein depletion Blood and serum are lost into and around tissues at the operative site and carried away by drains such as in a thoracotomy wound or from the perineal wound of a combined abdominoperineal resection The continued use of intravenous fluids is a losing proposition of insufficient calories and therefore poor utilization of any protein given To return the patient to eating is the primary aim, since there is no substitute for food by mouth

### *The Evaluation of Protein Deficiency in Surgical Patients*

GENERAL SURVEY A good estimation of the protein situation in a surgical patient can be made from a consideration of the following factors

1 Optimum weight of the patient
2 Present weight
3 Plasma protein level
4 Plasma albumin level
5 Plasma volume
6 Nitrogen intake
7 Nitrogen output

The first five above can be readily ascertained in most hospitals, the last two require extensive studies impractical for most patients not undergoing research projects They have, however, furnished extremely important basic information applicable to clinical surgical care

The plasma protein and albumin levels have considerable value as indicators of protein deficiency but, as already stated, are late signs of body protein loss and therefore are often near normal and not of much value in early but pertinent protein deficits The blood protein values will be maintained at the expense of liver and muscle stores, but with no reserve the stress of trauma or infection easily breaks this false front and the true situation is

revealed by low blood protein values When they are lowered, total body protein has been seriously depleted Also, normal values may be misleading in another way With the concentration of blood components present in dehydration abnormally high figures will be obtained, and the astute clinician will repeat the test to learn the true condition after the dehydration has been corrected

Of greatest value in the evaluation of protein deficiency is the evidence of a total nutritional deficiency as shown by a recent loss in weight The history of an appreciable decrease in weight because of disease unquestionably presents a nutritional problem and one having aspects other than protein in spite of the fact that the major object in feeding patients is to replenish or maintain protein stores For example energy requirements must be met at all times but because of disease or injury the sick individual often has reduced intake of food and increased energy requirements Under such conditions the major burden falls upon fat stores, which unfortunately cannot meet all the energy demands of the body There is an irreducible glucose requirement needed to prime the machinery of fat oxidation Protein reserves will be called upon to furnish this irreducible glucose minimum unless the patient is fed carbohydrate In disease, the body can ill afford to waste protein in this way A carbohydrate deficit is thus a serious matter, more so than a caloric deficit, which can be partly made good from fat depots The great value of eating or being given intravenously 100 Gm of glucose per day the amount present in 2000 ml of 5 per cent dextrose in water, was ably shown by Gamble His studies made evident that under starvation conditions this 100 Gm glucose intake diminishes protein losses by 50 per cent, prevents or relieves ketosis, and reduces sodium and water losses from the extracellular fluid by half Few surgeons actually realize what wide benefits are accomplished by this simple therapy

A sufficient caloric intake is a special problem to many ill surgical patients, both preoperatively and for a variable period postoperatively Even the well nourished subject given the essential carbohydrate needs and enough protein to replace that lost by wear and tear will maintain a protein deficit if his diet does not at the same time provide an adequate supply of calories Under conditions of disease or trauma energy requirements are poorly met

All this adds up to the fact that the patient who has lost appreciable weight as emphasized by Elman and Cole, is not a good surgical risk and should have his nutritional deficiency corrected preoperatively if possible How far behind on protein a surgical patient can be is illustrated by Cole in the hypothetical case of a 10-pound weight loss Each pound of body weight represents 15 Gm of body nitrogen, which is equivalent to 90 Gm. of protein For the 10 pound weight loss this represents 900 Gm If as is usual there is a five day postoperative food deficiency period there may easily be another 900 Gm of protein loss making a total deficit of 1,800 Gm To attempt to correct even half of this in nine postoperative days would require the eating of 100 Gm each day for the deficit plus 70 Gm for daily maintenance, equaling 170 Gm of protein daily Not many patients will do as well in the postoperative period, and it is not surprising that several weeks or even months are needed to recuperate from a long illness

CHRONICALLY DEPLETED PATIENTS These individuals usually have suffered from some chronic debilitating disease for a number of months and are malnourished through poor eating Both the quantity and quality of their food has been low and weight loss very evident Among other things their poor sustenance is reflected in a reduced circulating blood volume, a hypovolemic state often referred to as chronic shock" Pulse rate and systolic pressure often are normal the hemoglobin content, red blood count, and total serum proteins may be at the

lower limits of normal and may not reflect the existing serious degree of hypovolemia present To appreciate the serious degree of depletion present, cognizance must be taken of the long time history of poor dietary intake, the weight loss, the pallor, poor tissue turgor, and poor venous filling These patients can stand little stress and strain and urgently need preoperative support

If time is available and the surgical condition permits the intake and digestion of food, eating is encouraged by every means to have the patient gain weight A daily minimum of 2,500 to 3,000 calories is needed along with 150 to 200 Gm of protein 1,000 mg of vitamin C, 5 to 10 mg of vitamin K, and a generous intake of all vitamin B group Nasogastric tube feeding of a prepared high protein substance such as Sustagen can well be used in some cases, or a daily whole diet blenderized to liquid form can be given similarly The use of testosterone to improve utilization of protein and of ACTH or cortisone for a few days to improve general well-being and appetite is occasionally well worthwhile With catabolism reversed and weight gain showing anabolic processes active the individual is a much improved candidate for surgery

For the patient unable to eat or digest food for one reason or another, blood and plasma transfusions must be relied upon to restore circulating fluid volumes The question of such solutes to restore total plasma proteins will be taken up under correction of hypoproteinemia Hemoglobin is a protein too, and to restore it and circulating fluid volume the average adult patient in this debilitated group should receive 1 000 to 2 000 ml of whole blood Guynn and Reynolds use a simple estimation the patient should receive no less than 100 ml of blood for every pound of gradual weight loss that has occurred during the last two months For example, a patient who has lost 20 pounds in the most recent months should be given 2 000 ml of blood in the preoperative period A slow transfusion of 500 ml of whole blood every second day should be correlated with the general improvement in the patient The amount may be too large for the smaller adult

### *The Correction of Hypoproteinemia*

ORAL FEEDING It cannot be emphasized too strongly that oral feeding is the method of choice in correcting protein deficiencies, and every effort should be made to employ this physiologic route It is often abandoned too quickly or resumed too slowly by those not willing to supervise the arduous details of encouraging a sick patient to eat more food The sum of a concerted effort may raise the intake to 2,500 to 3 500 calories a day Improvement usually follows attentive nursing care, catering to the patient s dietary whims, multiple small feedings, spiritus frumenti for those who like it, bile salts, pancreatic extract granules and finally small doses of ACTH for three or four days may result in a feeling of well being and increased appetite Protein intake should be high close to twice the normal of 1 Gm per kilogram of weight, and up to 300 to 400 Gm have been given in severe protein loss cases such as burns Fat is tolerated poorly by sick patients and about 15 per cent of the calories from this source is recommended if intestinal symptoms prevail

It is true that a patient with an alimentary tract carcinoma is unlikely to benefit by force feeding and no such effort should be made for this group, but as emphasized by Cole, there are many with benign lesions who have lost more than 10 to 15 pounds of weight in recent weeks who will be materially improved preoperatively by feeding to a gain of at least three to five pounds, thus signifying a change in their nutritional status from catabolism to anabolism

NASOGASTRIC TUBE FEEDING Supplying liquid food through a small polyethylene tube is an adjunct method employable in many instances if the patient will not or cannot eat normally Elman lists the following indications

1. Malnutrition without organic cause anorexia nervosa
2. Anorexia from the effects of active acute or chronic disease
3. Postconvalescence malnutrition persisting because of anorexia
4. Patients with mechanical impediments to eating or swallowing
5. Semiconscious or unconscious patients
6. Preoperative malnutrition in patients needing more rapid nutritional rehabilitation
7. Persistent postoperative malnutrition
8. Undernourished patients who can eat but in whom more rapid rehabilitation is desirable

Sustagen has been a very satisfactory tube feeding material, and a 900-Gm mixture contains

| | | |
|---|---|---|
| Protein | 210 Gm | 840 calories |
| Carbohydrate | 600 Gm | 2400 calories |
| Fat | 30 Gm | 270 calories |
| | | 3510 calories |
| Thiamine | | 10 mg |
| Riboflavin | | 10 mg |
| Ascorbic acid | | 300 mg |
| Nicotinamide | | 100 mg |
| Ca pantothenate | | 40 mg |
| Pyridoxine hydrochloride | | 5 mg |
| Folic acid | | 2 5 mg |
| Cyanocobalamin B-12 | | 4 mg |

Diarrhea cramps nausea and vomiting are disturbing complications in some patients with tube feeding Of usefulness for these patients is the administration of paregoric or camphorated tincture of opium 8 ml q i d, and Banthine up to 100 mg q i d Of great importance in nasogastric tube feeding is care not to use a continuous drip but to give a small portion every hour starting slowly with 20 to 30 ml each hour and increasing up to 200 to 300 ml per hour as tolerance develops

An excellent mixture for jejunostomy or gastrostomy tubes can be made up of the strained vegetables and meats prepared for infants Mixed with boiled skim milk and with vitamins added this source provides an excellent quality of foodstuffs and is usually very well tolerated

INTRAVENOUS ALIMENTATION The use of blood, plasma, and serum albumin in the preparation of the hypoproteinemic patient for operation has many proponents but is expensive and has some inherent hazards Allen and Steininer state the daily transfusion of a liter of plasma will elevate the plasma protein concentration within three to six days with little change for the first two or three days and then a rapid improvement As the plasma volume begins to increase, a decrease in the circulating hemoglobin concentration occurs because of dilution, this can be corrected by giving 500 ml of blood to each liter of plasma With such a schedule the patient is brought to surgery with a normal concentration of hemoglobin and plasma protein This treatment should be considered in the very poor risk patient The expense of such a plan is decreased in those hospitals that make available plasma from outdated blood The vast majority of slight to moderately depleted patients will improve with restoration of plasma volume, red cell mass water and electrolytes with good recovery following well planned and executed surgery

Human serum albumin should be considered as a source of protein in cases of severe nutritional depletion much the same as human plasma is considered There is evidence that a large portion of the administered albumin may be used in the manufacture of tissue protein In numerous studies albumin has been shown to be extremely effective in restoring the blood pressure of patients in shock any given amount of albumin being equivalent to a much larger volume of plasma Its effects are said to be more rapid and longer lasting than those of plasma

Protein hydrolysates given intravenously are now generally accepted as a source of protein for the needy patient although an occasional study casts some reflection on their utilization Allen recently reported that puppies whose only source of protein was this material given intravenously failed to grow and died in about

the same fashion as did litter mates receiving no protein

The utilization of protein hydrolysates intravenously and the utilization of other protein, seem to depend upon the same factors, i e, whether or not the patient receives sufficient calories simultaneously Experimental data available indicate that protein hydrolysates are capable of building up plasma proteins provided the caloric requirements of the patient are covered and a positive nitrogen balance is maintained Moore and his associates, studying various aspects of this question, emphasized the "need" of the patient for protein in addition to the caloric intake Some of the excessive nitrogen outputs recorded in preoperative patients given protein hydrolysates indicate that wastage may occur in the normally nourished patient, whereas if the patient is depleted and is receiving calories from other sources such wastage does not occur Moore concludes from all the data available that there is good support for the clinical use of protein hydrolysates intravenously in the depleted patient preoperatively, where there is need and an adequate caloric intake, utilization is good This is approximately the same conclusion to be drawn from all dietary studies on the utilization of oral protein that a positive nitrogen balance and slow restoration of plasma proteins will occur if at the same time an adequate supply of calories is given

A contrast occurs in the fate of protein and hydrolysate nitrogen given to the postoperative patient In the immediate postoperative period it is very difficult to attain a positive nitrogen balance with either food protein or protein hydrolysates intravenously If postoperative nitrogen intake is maintained it is accompanied by a high excretion rate and a negative balance, even if the caloric intake is adequate In several of Moore's cases the hydrolysate nitrogen was excreted almost as rapidly as it was given This finding is not unusual since the transient period of nitrogen loss is characteristic of the normal postoperative response whether or not oral intake is maintained, and intravenous hydrolysate does not alter this response Moore emphasizes that this should not detract from the surgeon's interest in protein hydrolysates later in the convalescence where starvation conditions continue as a result of continued disease or complications and where supplementary nitrogen may be lifesaving The infusion of protein hydrolysate in the peripheral blood gives the cells of muscle, liver, and kidney a protein building block, utilization of which depends not only upon the value of the building block but also on the question of whether or not construction is going on In the starved patient construction will go on when the blocks are given The postoperative patient has altered his balance in the direction of deamination and excretion of the nitrogen The new building blocks share in this tendency, exposing more nitrogen to the excretory pathway Prolonged infusions of protein hydrolysates over a period of many days must inevitably result in an increase of plasma volume or plasma protein concentration

A postoperative patient receiving 2,000 ml of 5 per cent protein hydrolysate in 5 per cent dextrose is receiving 12 Gm of nitrogen and 400 calories Ordinarily this amount of nitrogen requires 2,400 calories for maximal utilization As the postoperative period progresses, the nitrogen balance becomes more dependent on intake of nitrogen and less upon posttraumatic metabolic changes As convalescence progresses more food can be taken by mouth, leading to larger positive balances

Fat emulsions for intravenous purposes have been prepared by several laboratories and used successfully in patients They are a concentrated source of calories and thus conserve protein, an impressive aid to the nutrition of depleted patients The fat particles average less than 1 micron in diameter, and 1 liter of the 15 per cent emulsion in 4 per cent glucose provides 1,600 calories The administration of 644 infusions by Preston *et al* to 30 seriously ill surgical patients, many of whom were unable to take nourishment by mouth, gave the following results

In most cases one infusion of 600 ml (960 calories) was given daily and ten patients received 35 or more such daily infusions In general, the fat emulsions were well tolerated and the reactions were minor On only three occasions was it necessary to discontinue an infusion because of a reactive chill No febrile reactions occurred with 81 4 per cent of the infusions a temperature increase of 1 1° F occurred with 15 8 per cent, and only 2 8 per cent were associated with a temperature elevation of 3 1° F or more Vasomotor changes including variations in blood pressure and pulse were infrequent and insignificant Nausea followed 30 of the infusions, there was anorexia with 14, vomiting with 11, and dizziness with 15 After approximately two weeks of infusions, liver function, as shown by bromsulphalein retention, cephalin flocculation, and thymol turbidity tests, was impaired to some extent in almost all patients The effect was most apparent in the bromsulphalein excretion studies and was generally of mild to moderate degree, excretion tended to return to the preinfusion status after the emulsions were discontinued There were no changes attributable to the fat emulsions in the total serum bilirubin, the serum protein levels or the albumin/globulin ratio Preston *et al* felt that their patients had benefited materially from the much increased caloric intake and that fat emulsions could be safely used for periods of less than two weeks

In the suggestions for use of Lipomul I V, the adult dosage is stated as not more than 2 units of 500 ml daily, the total not to exceed 14 infusions As a general rule, if Lipomul I V is to be given daily for more than 7 days, the fasting serum should be examined for evidence of lipemia before additional infusions are administered The patient is considered to have reached the point of maximum tolerance when lipemia persists for 18 to 24 hours following an infusion Lipemia may be detected by simple observation of the serum or by photoelectric procedures Clinical indications of hyperlipemia may be an unexplained fever temperature rise, hepatomegaly, splenomegaly anemia, or evidence of bleeding not attributable to the primary disease

POTASSIUM INTAKE Cannon and his associates have presented considerable evidence to show that for favorable nutritional rehabilitation a good diet should furnish both nitrogen and potassium For instance, in protein depleted rats effective recovery followed an adequate supply of calories vitamins, amino acids, and salts whereas with the removal of potassium from the salt mixture the animals failed to gain weight adequately, and cardiac lesions and death ensued The addition of small amounts of potassium enabled the animals quickly to recover and achieve effective protein repletion Eliel, Pearson and White have shown that patients deprived postoperatively of potassium and phosphate lost more nitrogen than those given optimal amounts of these substances

Such experiments stress the need for potassium to all patients offering any nutritional problem in the preoperative or postoperative period Cannon believes the manifestations of potassium deficiency become more marked as the intake of sodium chloride increases Since the latter is often given to the ill surgical patient there is need for potassium, 40 mEq daily is a basic amount and more should be given if there are abnormal losses

## Vitamin Deficiencies

Vitamins are not a real problem in the management of surgical patients since they are readily available and easily given if there is any suggestion of nutritional deficiency Generally accepted values for daily maintenance of an average adult and for those with deficiency are given in Table 2 6

Determination of the prothrombin time discloses any deficiency of vitamin K which is essential to the formation in the liver of prothrombin, the precursor of the active clotting agent, thrombin Whenever lower than normal values are found parenteral vitamin K should be given and response is usually good except in pa

tients with severe liver disease such as advanced cirrhosis For maintenance of normal values it may be administered either orally or parenterally Since bile salts are required for the absorption of vitamin K, they are given with the oral preparation if hepatic or biliary disease is present, the daily dosage commonly suggested being 2 to 4 mg of natural vitamin K or menadione with bile salts or 5 to 10 mg of water-soluble K substance without bile salts If the parenteral route is necessary, 5 to 10 mg of the water soluble form of vitamin K can be given subcutaneously, intramuscularly, or intravenously

Streptomycin orally has been shown to reduce the synthesis of vitamin K by intestinal organisms and other antibiotics and sulfonamides are capable of producing the same result It is usually wise to give supplemental vitamin K when any of these substances are given by mouth

Vitamin C also has a prominent place in the nutrition of surgical patients, as in any therapeutic nutrition Its most important known effect is on collagen formation, which forms the framework of connective tissue and the substructure of osseous tissue and dentine Collagen tissue formation requisite to the healing of soft tissues ceases in absolute scurvy

Ascorbic acid exerts a strong influence on the detoxification processes, on the colloidal condition of intercellular substances, and in the healing of wounds It is not stored to any great extent in the tissues other than the adrenal and pituitary glands, and under stress conditions the adrenal cortex rapidly becomes depleted of its ascorbic acid It is unquestionably desirable to maintain adequate body stores of ascorbic acid at all times, and it is particularly desirable to do so for surgical patients Malnutrition may well have lowered its normal intake, and the marked stress of severe burns has been found associated with an almost zero blood ascorbic acid concentration and similarly low urinary excretion values These low levels associated with severe stress are thought due to increased utilization of vitamin C Under any acute stress condition resulting from disease a daily intake of 1 Gm of ascorbic acid is recommended, decreasing later to 300 mg under more moderate circumstances

TABLE 2 6 VITAMIN REQUIREMENTS

| | | *Daily maintenance* | *Amount suggested with deficiency* |
|---|---|---|---|
| A | Oleovitamin A | 5000 I U | 25 000–50 000 I U |
| D | Irradiated ergosterol etc | 400 I U | 2 000– 5 000 I U |
| B | Thiamin chloride | 1 6–2 0 mg | 10–25 mg |
| | Riboflavin | 1 6–3 0 mg | 5 15 mg |
| | Nicotinic acid | 15 20 mg | 250–500 mg |
| | Pantothenic acid | 10 mg | 20 mg |
| | Pyridoxine hydrochloride | 1 2 mg | 2 mg |
| | Biotin | ? | 75–300 μg |
| | The cobalamins $B_{12}$ | ? | 4 μg |
| | Folic acid | 1 mg | 5 10 mg |
| C | Ascorbic acid | 75 mg | 300–1 000 mg |
| E | Tocopherols | 30 mg | 200–600 mg |
| K | 3 Methyl 3 Phytyl 1 4 Naphthoquinone | 1 μg | 5–10 mg |

## PREOPERATIVE PREPARATION OF PATIENTS WITH ASSOCIATED SYSTEMIC DISEASES

### General Considerations

The average patient coming to surgery without any associated systemic diseases

may be considered a standard risk The mere presence of some other unrelated disease introduces a new hazard that must be overcome if the operative mortality and the postoperative morbidity are to be kept in line While there may be times when an operation cannot be delayed the surgeon must realize that each uncorrected or only partially corrected dysfunction inevitably complicates the patient's future course

This observation is most strikingly illustrated by an analysis of the mortality and morbidity statistics for elective and emergency surgery in the aged since it is in this group that associated systemic diseases most frequently occur

TABLE 2 7 COEXISTING DISEASES*

| *Disease* | *Number of Patients* |
|---|---|
| Arteriosclerotic heart disease | 42 |
| Hypertensive cardiovascular disease | 39 |
| Congestive heart failure | 36 |
| Cancer of another site | 23 |
| Chronic renal disease | 20 |
| Benign prostatic hypertrophy | 17 |
| Chronic pulmonary disease | 15 |
| Diabetes | 14 |
| Previous cerebrovascular accident | 10 |

*L F Wilkins and C D Knight Abdominal Surgery in the Aged *Courtesy A M A Archives of Surgery*

Wilkins and Knight reviewed their experience following 307 intraperitoneal operations on patients over the age of 64, subjected to surgery during the years 1955 and 1956 There were 51 deaths in the series for an operative mortality of 16 6 per cent, compared with a 2 1 per cent mortality for all operations on the general surgical service

The mortality rate for emergency surgery, often performed without adequate control of associated diseases, was 27 per cent in contrast to a rate of 11 per cent for nonemergency procedures

While only one third of all the patients exhibited other significant disease (Table 2 7) about half the fatalities were caused by complications unrelated to the surgical disease itself (Table 2-8) Many of the nonfatal complications similarly could be directly attributed to unrelated, co-existing diseases (Table 2-9) Thus it is obvious that unrelated systemic diseases must be

TABLE 2 8 FATAL COMPLICATIONS*

| *Cause of death* | *Number of Patients* |
|---|---|
| Heart disease | 9 |
| Pneumonia | 8 |
| Shock | 8 |
| Uremia | 6 |
| Metabolic | 6 |
| Undetermined | 5 |
| Peritonitis | 4 |
| Pulmonary embolus | 2 |
| Cerebrovascular accident | 2 |
| Intestinal obstruction | 1 |
| Total | 51 |

*L F Wilkins and C D Knight Abdominal Surgery in the Aged *Courtesy A M A Archives of Surgery*

TABLE 2 9 NONFATAL COMPLICATIONS*

| *Complication* | *Number of Patients* |
|---|---|
| Wound infection | 22 |
| Severe hypotension | 14 |
| Pneumonia | 10 |
| Cardiac failure | 6 |
| Cardiac arrhythmias (new) | 6 |
| Urinary tract infection | 6 |
| Thrombophlebitis | 4 |
| Peritonitis | 3 |
| Intestinal obstruction | 3 |
| Wound hemorrhage | 3 |

*L F Wilkins and C D Knight Abdominal Surgery in the Aged *Courtesy A M A Archives of Surgery*

recognized, evaluated and, if possible, corrected before the patient is subjected to surgery

It is worth emphasizing that in Wilkins and Knight s series the presence of uremia at the time of surgery was of ominous prognostic significance Such patients should be carefully evaluated, given every form of supportive therapy, and the value

of the operation should be thoughtfully judged against the poor general outlook

## Heart Disease

While the surgical patient with preexisting heart disease today has a better chance to survive than formerly, he still remains a poorer risk than the patient free of heart disease Dana and Ohler, examining the results of comparable major surgery in cardiac and noncardiac patients, observed that the cardiac group carried a 7 4 per cent mortality versus 1 4 per cent mortality in the noncardiac group In addition, the cardiac group exhibited a 21 6 per cent incidence of postoperative cardiovascular and pulmonary complications versus a 5 6 per cent incidence in the noncardiac group

The increased risk varies considerably with the type and severity of the heart disease, the magnitude of the operation, and the skill of the surgical team The surgeon must be satisfied that the anticipated benefit of surgery justifies the increased hazard in the cardiac patient

Congenital heart diseases are relatively rare It therefore is difficult to assess their role in the recovery of the patient undergoing abdominal surgery Because many of these patients are polycythemic there is an increased risk of intravascular clotting This risk may be somewhat reduced by maintaining adequate hydration in both the preoperative and the postoperative period While anticoagulant therapy may be used it rarely is justified since it substitutes the hazard of postoperative bleeding in this group of patients

Patients with rheumatic heart disease do considerably better than those with arteriosclerotic heart disease Morrison, in a large series, reported an operative mortality of 3 7 per cent for rheumatic patients, 14 8 per cent for arteriosclerotic heart disease patients, and 11 1 per cent for syphilitic heart disease patients If the rheumatic heart is well compensated there should be little increase in surgical risk Congestive heart failure, however, presents a serious problem Digitalis, sodium restriction, and mercurial diuretics may be required to restore compensation In this group it is thought that all but the most urgent surgery should be deferred for a month or six weeks after correction of the decompensation

The patient with aortic stenosis is likely to get into trouble, nor are there any reliable precautions to be taken In the presence of aortic stenosis the surgeon should be doubly sure of his indications for surgery and the family of the patient should be forewarned of possible fatality

Mitral stenosis, not disabling in itself, is a much less serious problem and surgery is well tolerated if there is little or no cardiac decompensation

Arteriosclerotic heart disease is the most formidable enemy of the surgeon Etsten and Proger state, coronary disease in the form of atherosclerosis occurs in 50 per cent of people between the ages of 45 and 50, and for all practical purposes patients beyond 60 years of age should be dealt with as though they had coronary atherosclerosis" Since most major abdominal surgery now is performed on patients over the age of 45, the arteriosclerotic heart is a constant worry to the surgeon It is important to decide whether a patient with some coronary atherosclerosis is merely a potential candidate for coronary heart disease, whether he has progressed to a state of chronic coronary heart disease, or whether he is exhibiting typical or atypical signs of acute coronary heart disease The patient with potential or with chronic coronary heart disease will stand an operation almost as well as the patient with a completely normal heart On the other hand, a patient with acute coronary heart disease is such a poor risk that only the most urgent surgery should be performed Recovery from acute coronary heart disease is exceedingly slow Every effort should be made to avoid surgery for at least three months after the cardiac condition has become stabilized

A careful history and repeated electrocardiograms usually will help establish the cardiac status of a patient Once this status has been established and a decision

for surgery has been made, the preoperative preparation consists of correcting any electrolyte imbalance and any marked anemia or polycythemia Digitalization and the use of quinidine or Pronestyl rarely may be required Proper rapport between the patient and the anesthesiologist is essential Sedative drugs of the barbiturate series probably are better than the more depressing morphinelike drugs There is general agreement that chlorpromazine and related drugs should not be used During surgery it is important that hypotension be prevented Should it occur and persist in spite of remedial measures this should be taken as presumptive evidence that an acute coronary occlusion has occurred The outlook then becomes grave indeed and the operation should be terminated as promptly as possible

## Impaired Liver Function

Liver damage frequently is a part of surgical diseases in the abdomen If the liver damage is severe the surgical risk may become prohibitive unless measures are taken to remedy the liver deficit As a rule the deficits primarily associated with obstructive phenomena are less dangerous than those associated with hepatocellular disease Unfortunately as biliary tract involvement progresses it becomes increasingly difficult to distinguish between hepatocellular disease and duct obstructions Numerous tests constituting a liver profile are used to help separate these two groups of diseases However, many of these tests valuable early in the course of liver disease later may become quite worthless and sometimes may even be misleading The few tests that remain accurate are extremely valuable For example an elevated thymol turbidity with increased urinary urobilinogen points to hepatocellular disease If the prothrombin time is greatly prolonged and there is little or no improvement after use of parenteral vitamin K the parenchymal damage is severe and the storm warnings should be up An elevated alkaline phosphatase with a normal thymol turbidity indicates obstructive disease with jaundice Under these circumstances an increased prothrombin time usually is the result of failure to absorb vitamin K and there will be prompt improvement when parenteral vitamin K is given

Whether the liver dysfunction is predominantly due to obstruction or is the result of hepatocellular disease, the surgeon should try preoperatively to improve the liver function While the response to parenteral vitamin K will be prompt and essentially complete in a matter of a few hours to a few days, it may take weeks of preparation with high calorie diets rich in proteins and carbohydrates, to produce a significant improvement in other hepatic functions When the liver damage is due to starvation, either the result of disease or from inadequate diet the calorie intake should be increased on a gradual basis until it reaches an optimum level of approximately 3 000 to 3,500 calories Parenteral protein, whole blood plasma or albumin transfusions may speed the improvement

The greater the degree of hepatocellular damage the slower recovery will be If under these circumstances there seems any reasonable hope that further delay will result in improved liver function the surgeon should make haste slowly Coincident with improved liver function will be an improvement in appetite, in protein and antibody synthesis and in the general nutrition of the patient There also is less danger of falling into the trap of operating upon a patient with an evolving hepatitis or a patient with chlorpromazine poisoning

There are times when it is apparent that the liver damage will remain unchanged or will continue to increase unless an operation is performed The surgeon then must accept the challenge of the added risk

## Impaired Kidney Function

Impaired renal function not only increases operative mortality and postopera

tive morbidity but it restricts the use of drugs antibiotics, and anesthetic agents Moreover, parenteral fluids must be given with extreme care

The preoperative recognition and correction of renal defects will forestall many unnecessary complications A detailed history may reveal evidence of past renal damage while physical findings of hypertension and funduscopic changes may also suggest kidney diseases A routine urinalysis and a blood nonprotein nitrogen determination are essential to determine renal disease Albuminuria may be of variable significance Associated with casts and red blood cells, it usually indicates active renal disease and surgery, if feasible, should be deferred

If the urinalysis and nonprotein nitrogen are normal the patient may be considered a good operative risk as far as his kidneys are concerned

If the nonprotein nitrogen is elevated and there is a high urine specific gravity the patient may have an acute nephritis or some extrarenal problem such as dehydration, shock, hemorrhage, or a severe infection In this group only the most urgent surgery should be performed without further study and appropriate remedial measures

If the nonprotein nitrogen is elevated and there is a low fixed urinary specific gravity it usually indicates intrinsic renal disease These patients remain relatively poor operative risks even when the nonprotein nitrogen level improves during the period of preoperative preparation Their kidneys have little reserve and minor fluctuation in blood pressure and in electrolyte and water balance may lead to irreversible disturbance in renal function This observation also is true for patients with a normal nonprotein nitrogen and a low fixed urinary specific gravity

Usually it is possible, by adequate preoperative preparation, to improve the blood nonprotein nitrogen Little can be done to improve the function of a kidney that constantly produces urine of a low fixed specific gravity This finding should warn the surgeon He must carefully weigh the risks and benefits of the contemplated surgery, knowing that his patient represents a greater surgical risk than usual

## Pulmonary Disease

Bronchopulmonary diseases rarely are so severe that they become the major contraindication to abdominal surgery However, they are the most frequent single source of operative and postoperative complications and, uncorrected, they may unfavorably influence the recovery of the patient While there are times when little can be done to improve the function of a diseased heart, liver, or kidney, the diseased lung usually will respond rapidly to relatively simple measures For these reasons it is important that the preoperative pulmonary status of the patient should be determined and that adequate pulmonary function should be assured

Bronchopulmonary disorders in general may be considered under two headings

1 Those affecting pulmonary ventilation
2 Those related to pulmonary infections

Obviously, those diseases that reduce pulmonary ventilation will limit the choice of preoperative medications and anesthetic agents Some degree of hypoxia may be hard to prevent during the operation In the recovery period hypoxia may become a serious problem, particularly if the incision constricting dressings or upper abdominal pain further reduces respiratory efficiency Following the repair of some large hernias, with the replacement of viscera in the abdomen, the diaphragm may be pushed upward greatly reducing the vital capacity

Abnormal bacterial flora in the respiratory tract, the result either of chronic pulmonary disease or of recent infection, may be followed by bronchitis, bronchopneumonia, and atelectasis in the postoperative period

There is little difficulty in recognizing the patient who is completely free of pul

monary disease The problem becomes more difficult in patients who may fail to recognize that they have a chronic productive cough or that they are unusally dyspneic At times it is hard to distinguish between dysfunctions of pulmonary origin and cardiac origin Various historical data and physical findings should cause one to suspect pulmonary disease

1 History of known pulmonary disease
2 Shortness of breath on moderate exertions
3 A chronic cough, which may or may not be productive
4 Unusual amounts of sputum
5 History of wheezing asthma, or allergies
6 Occupational exposure to dust hazards
7 Marked deformity or rigidity of the thoracic cage
8 Cyanosis
9 Clubbing of the fingers
10 Prolonged expiratory effort associated with rales and wheezing

The degree of impairment of pulmonary function may be estimated in a variety of ways Chest x rays in inspiration and expiration may give visual evidence of restricted pulmonary ventilation Exercise tolerance tests and vital capacity determinations probably are sufficient to establish the degrees of difficulty in most instances In determining the vital capacity it is important to know the rate of expiration It is assumed that the vital capacity should be delivered in three seconds or less A prolonged expiratory time suggests obstructive bronchial disease which may interfere with anesthesia and complicate the postoperative recovery of the patient When these examinations have been done and there is still doubt concerning pulmonary function it may be necessary to perform a variety of more complex pulmonary function studies When an infectious factor is suspected sputa should be examined repeatedly and cultures should be made for significant organisms

### *Preoperative Treatment of Bronchopulmonary Disease*

Preoperative preparation should attempt to (1) improve pulmonary function by increasing vital capacity, (2) reduce coughing so that convalescence will be more comfortable and so that there will be less risk of wound dehiscence, (3) eliminate pathogenic organisms so that there will be less chance of postoperative pulmonary infections

These objectives are best accomplished by explaining the problem to the patient and enlisting his support Frequently he will have to give up smoking for some time before surgery He may have to take breathing and coughing exercises These exercises may be improved by using aerosol inhalations with bronchodilator substances and wetting agents When antibiotics are added to the treatment, it seems to make little difference whether the antibiotics are used in the aerosol or are given systemically

The rate of improvement should be charted by daily records showing changes in the vital capacity variations in the quantity and character of the sputum and alterations in the bacterial flora of the sputum If a large hernia is to be repaired where viscera have lost their right of domain it may be valuable to maintain a rather high pressure pneumoperitoneum for several days to two or three weeks before surgery is performed

Occasionally as in bronchiectasis and in marked emphysema with bleb formation the pulmonary deficit may be so severe that these conditions will require surgical intervention for their correction before the planned abdominal surgery can safely be performed Patients with pulmonary fibrosis may have such a crippling and irreversible pulmonary deficit that only lifesaving abdominal operations are justified

The asthmatic patient presents a special problem The asthma may be on an allergic basis or of long standing and the patient may be allergic to many extrinsic irritants This patient is best prepared for surgery by attempting to remove all allergy producing agents from the patient s

environment A second group of asthmatic patients are those thought to be sensitive to bacteria in their own respiratory tracts patients with the so called intrinsic asthma or asthmatic bronchitis These patients are much more prone to postoperative pulmonary complications such as bronchitis pneumonia and atelectasis They should be prepared for surgery by using the antibiotic best suited to control the suspected offending organisms They also should receive expectorant and bronchodilator drugs to reduce the chance of postoperative complications and to make the anesthetic less difficult Morphine is considered unsafe as a preoperative and postoperative medication

Drug allergies should be discovered and carefully avoided The surgeon should inquire about the possible earlier use of cortisone in treating the patient s allergy and if it has been used the patient must be protected by cortisone administration in the preoperative and postoperative period

## Diabetes Mellitus

Because diabetes affects more than 1 per cent of the population it is an important complicating factor in the preparation and management of surgical patients

While glycosuria is the commonly recognized manifestation of diabetes careful personal and family history as well as preoperative blood sugar determination frequently will expose previously unsuspected diabetes This is particularly true in older patients and in those with mild diabetes who have an elevated renal threshold for sugar excretion

The patient s latent diabetes must be recognized before surgery since the stress of trauma and the postoperative use of intravenous glucose may cause confusion in the immediate postoperative period The preoperative recognition and proper management of diabetes can make the diabetic patient a relatively safe operative risk In the fifteen years between 1940 and 1955 the surgical mortality among diabetics has fallen from 12 per cent to 2 or 3 per cent The known diabetic already adequately controlled by diet and insulin is not likely to cause much trouble The inadequately controlled and the latent unrecognized diabetic patients are much more serious problems In these patients a correct diagnosis of abdominal disease may be difficult Even when a diagnosis has been established it may be impossible to assess the relative urgency of the surgical problem and the need for adequate preoperative control of the diabetes Hasty surgery probably costs more lives than it saves and a few hours spent preoperatively in relieving diabetic acidosis and in improving electrolyte patterns may be rewarded by a lower mortality and a smoother convalescence

The diabetic patient scheduled for elective surgery should be thoroughly prepared Long acting insulin should be replaced by an intermediate insulin such as Lente or NPH insulin Weight should be controlled by diet with sufficient protein to assure a positive nitrogen balance Ideally the insulin carbohydrate and fat intake should be so adjusted that the fasting blood sugar level will fall in the range of 120–150 mg per cent

In the immediate preoperative period the intermediate insulin should be replaced by crystalline insulin and the patient should be placed on the so called six hour management so that the fluctuating insulin requirements may be accurately and promptly supplied

The diabetic patient who must have emergency surgery usually needs additional insulin This is best given as crystalline insulin half immediately into a vein and half into the subcutaneous tissues The initial dose may vary from 20 to 50 units depending upon the severity of the illness the existing diabetic state and the amount of acidosis present Later insulin needs which may be satisfied more slowly in intravenous infusions will depend upon the various blood chemistry reports

It should be mentioned that as the patient enters the period of postoperative recovery hypoglycemia is more dangerous than a mild hyperglycemia This is particularly true for the patient who may

have been given a general anesthetic and also for the patient who is arteriosclerotic and somewhat hypertensive The shock state of a severe hypoglycemic reaction may initiate an irreversible chain of events

For these reasons, among others spinal anesthesia is to be preferred and a mild hyperglycemia should be tolerated

## PREOPERATIVE ORDERS

### Sedation

The need for preoperative sedation is variable depending upon the patient s metabolic state the interplay of pain and anxiety the nature of the contemplated surgery the type of anesthesia to be used and the previous drug experience of the individual patient Because so many variables affect both the choice of sedative agent and the dosage it would be unwise to attempt a rule-of thumb presentation of the proper drug and proper dosage

The drugs usually used in preoperative sedation fall into four general categories narcotics sedatives tranquilizers and belladonna drugs

Of the narcotics morphine is the most commonly used opium derivative A number of synthetic opiumlike agents (Demerol Dromoran Nisentil) are also in common use These narcotics are most effective as analgesics and therefore they are most useful when preoperative pain is an important factor and when a painful operation is to be performed with one of the weaker anesthetic agents such as ethylene or nitrous oxide Contrary to common opinion there is little evidence that the preoperative use of narcotics reduces the amount of general anesthetic required Probably narcotic drugs are used too frequently in preoperative medication and they often might better be replaced by less depressing and more truly sedative drugs

When sedation is indicated chloral hydrate is a useful agent in those patients sensitive to the barbiturates and in the aged but the barbiturates remain the most versatile and widely used sedative drugs They range from the supershort acting thiopental through the short acting secobarbital and pentobarbital sodium to the long acting barbital and phenobarbital In using these drugs one should remember that the very short acting barbiturates are detoxified rapidly in the liver while the long acting barbiturates are excreted unchanged through the kidneys In either circumstance an adequate liver and kidney function must be assured

The sedative drugs that produce cerebral cortical depression without narcosis are most useful in promoting sleep and in overcoming anxiety during the preoperative hospital stay They probably should be used more widely to replace the narcotics in the immediate preoperative medication of patients Because sedative drugs are so commonly used by the adult population many patients have established a dependence upon some one of them Some patients will have developed a marked tolerance for these drugs and they will require much larger doses than those normally recommended

The tranquilizers are newcomers in the pharmacologic field and chlorpromazine (Thorazine) and meprobamate (Miltown Equanil) are the most widely prescribed While they may be useful during the preoperative hospital stay there seems little to justify their use as a preanesthetic medication They are not without danger since they often seem to enhance the effects of other drugs and of course chlorpromazine will occasionally produce rather severe biliary stasis and jaundice

Of the belladonna group of drugs atropine and scopolamine are the most frequently used Their main function is to reduce secretions in the respiratory tract and to reduce reflexes affecting the circulatory system acting through the vagus nerve In addition scopolamine will decrease the nausea and vomiting associated with morphine while producing some euphoria and considerable amnesia For this reason scopolamine in some instances is considered superior to atropine

The anesthesiologist having evaluated the patient in advance and knowing the

surgeon should be allowed to designate the appropriate preoperative medications their dosage and mode and time of administration In the past most preoperative medications have been given orally or into the subcutaneous tissues but now the intravenous route is often employed In this way the absorption and action of the drugs is speedy and more certainly predictable If for any reason the day s operating schedule needs last minute revision the operating team is not presented with an inadequately sedated patient or with one who already is recovering from the effects of some sedative or potent narcotic administered too soon

## Diet

Obviously the preoperative diet orders will depend upon the surgical disease and the operat on planned The diet always should be designed to aggravate the existing disease as little as possible to bring the patient to the operating table in optimum nutritional state to assure that the crit cal operative area is free of food and feces and to guarantee that the stomach is empty of food so that the anesthetic program may be carried out without fear of regurgitation and aspiration of irritating gastric contents Thus the patient with an obstructive or inflammatory lesion might be on nothing by mouth for some time before surgery while the patient with a duodenal or gastric ulcer might be kept on frequent feedings until the day of operation The patient with gallbladder disease may be allowed a rather l beral diet as long as fats are restricted while the patient about to undergo large bowel surgery should be placed on a low res due or liquid diet for two or three days before surgery

As a general rule patients should have nothing by mouth in the eight to twelve hour period before surgery This gives reasonable assurance that the stomach will be free of food at the time of operat on For all major abdominal procedures continuous nasogastric suction applied just before the operation has great advantage in insuring that the stomach is empty and kept so during the surgery and immediately afterward

## Attention to the Bowels

Intra abdominal operations are facilitated by a collapsed stomach and intestines Not only is it easier to handle collapsed intestines but it is much easier to maintain an adequate operative field The exploration of abdominal viscera is more accurate if the bowel is empty and when unexpected disease is encountered it may more readily be recognized and treated if the bowel has been properly prepared With the bowel collapsed there is less difficulty in closing an abdominal wound The immediate postoperative course of the patient is smoother if the gut is not stimulated by retained feces and there is less danger of a fecal impaction if the large bowel is empty This is particularly true when the patient has been subjected to barium x ray studies in the recent preoperative period For these reasons it is generally desirable to have the bowel empty at the time of operation

An empty gastrointestinal tract may be obtained by purging by using enemas and by withholding foods with solid residues Obviously at times each method will have its advantages and there will be times when one or another method will be contraindicated Occasionally even with preoperative catharics and enemas there will be considerable quantities of gas distending the intestines This may result from poor enema techn que but more commonly it is caused by air swallowing a phenomenon most frequently observed in times of emotional stress When particularly pronounced the harmful effects of air swallowing may be reduced by the use of continuous gastric suction during the twelve-hour period before surgery

The use of antibiotics in the preoperative preparation of the bowel for intestinal surgery has received almost universal acceptance and is credited with lowering the morbidity and the mortality rates of colon surgery However Coller in stressing the need for continued attention to technical

detail points out that "an anastomosis heals not because it is in a sterile field but because it has been subjected to minimum trauma has a good blood supply, and is not under undue tension" There can be little doubt that a reduction in the number of intestinal bacteria will result in less inflammation at the line of anastomosis and more certain and more rapid healing The preoperative use of intestinal antibiotics certainly permits a more extensive use of segmental resection of the colon with primary anastomosis

There are several methods of preparing the bowel with antibiotics All involve the use of one or more bacteriostatic agents for a short time (a few hours to several days) after the bowel has been cleansed with enemas or with a cathartic Cohn and Longacre after extensive studies using a variety of bacteriostatic agents separately and in various combinations concluded that neomycin alone was very satisfactory but that a combination of tetracyclin and neomycin gave still better results They recommended cleansing the bowel with enemas or saline cathartics and then placing the patient on a minimum residue diet and a regimen of 200 mg of tetracyclin and 1 0 Gm of neomycin by mouth every hour for four hours and then every 6 hours for 72 hours This is in general agreement with the reported findings of Phillips Dearing and Waugh Davis and his associates obtained equally good results with neomycin alone given as a single 4 Gm dose 24 hours before surgery or in 1 Gm doses every 4 hours for 24 hours before surgery

These observations suggest that long periods of bowel preparation and the use of Sulfasuxidine and Sulfathaladine is not required to produce a satisfactory cleansing of the bowel

## The Patient on Anticoagulant Therapy

Patients recently on anticoagulant therapy present a special problem in preoperative management. While a prolonged prothrombin time adds little to the risk of operative and postoperative hemorrhage, most surgeons prefer to have anticoagulant medicines discontinued and their effects neutralized before submitting the patient to major surgery

If the patient has been on heparin merely discontinuing its use will result in a return to a normal prothrombin time in 12 to 36 hours If there is urgent need for immediate surgery the heparin effect can be neutralized quickly by giving 50 mg protamine sulfate intravenously If this does not produce the desired result a further dose of 10 to 20 mg is usually sufficient

If one of the so called antiprothrombin drugs (Dicoumarol Tromexan Phenylindandione) has been used an interval of two to five days usually is required for the spontaneous return to a normal prothrombin time Vitamin K in doses of 10 to 20 mg intravenously usually will produce a normal prothrombin time in a few hours If an immediate response is needed the prothrombin deficit may be overcome by a transfusion of 500 to 1 000 ml of whole blood or plasma

## Gastric Lavage

Aspiration of gastric content is a more frequent and a much more serious complication of surgery than is generally recognized Morton and Wylie in 1951 reported their findings after reviewing the records of 350 deaths associated with anesthesia They found that 43 of these deaths were due to vomiting and the regurgitation of gastric content Culver in a clinical experiment using 300 unselected patients injected a dye into the stomach and found that while only 8 per cent vomited 26 per cent regurgitated the dye during anesthesia The dye was found in the trachea or bronchi in 16 per cent When gastric suction was used the incidence of regurgitation was only half as great as when no suction was used It is probable that many of the unexplained pulmonary complications are the result of aspiration of gastric contents These findings emphasize the need to guard against regurgitation and aspiration

There is little excuse for a patient undergoing elective surgery to come to the operating room with a full stomach Dietary restriction for a few hours before surgery and the use of nasogastric suction usually suffice The emergency case presents a different problem since undigested food frequently is present in the stomach Merely because the patient may have vomited large amounts is no reason to assume that he has emptied his stomach Indeed the reverse is more likely to be true If the operation cannot be deferred or performed under local or spinal anesthesia measures to prevent regurgitation must be taken

The passage of a Levine tube or a larger gastric lavage tube followed by lavage with saline, water, or bicarbonate of soda solution may produce rather complete but still uncertain emptying of the stomach Fisher reports a more certain method for preventing the aspiration of stomach contents

A Miller Abbott tube is inserted into the patient s stomach and 30 to 60 cc of air is injected into the balloon The tube is then withdrawn until the balloon is tight against the esophageal orifice in the stomach and the contents are effectively sealed in the stomach Gentle traction on the tube is maintained while the patient is anesthetized and a cuffed endotracheal tube has been inserted After the cuff has been inflated the Miller Abbott tube can be deflated since traction on the inflated balloon causes hiccups in some patients At the conclusion of the operation the endotracheal tube is left in place until the patient s reflexes have returned sufficiently to protect the airway or the Miller Abbott balloon may be reinflated

## Nasogastric Suction

It may be desirable to establish and maintain nasogastric suction before surgery This suction is likely to produce a more completely collapsed stomach and small bowel In addition it frequently will allow the surgeon to draw the tube through a gastrointestinal stoma if he so desires Recently gastric suction has been established postoperatively through a gastrostomy using often a mushroom or Foley catheter This is an effective and comfortable method in many instances of possible long term need or for the older patient

## Vaginal Preparation

If lower abdominal surgery is planned for a woman and there is some possibility that a colpotomy or a hysterectomy might be performed, the patient should have a vaginal preparation

## Indwelling Catheters

When abdominal surgery is to be performed in the region of the bladder or when the operation is likely to be unusually long it may be wise to place an indwelling Foley catheter in the bladder This may be done before surgery or in the operating room after anesthesia has been commenced The use of such a catheter assures a collapsed bladder during surgery and prevents overdistention of the bladder during the postoperative period In addition the urinary output may be followed throughout the operation, a valuable observation in the critically ill patient and in operations performed during prolonged hypotension

If the surgeon is in any doubt about the location and course of the ureters in relation to his field of operation he may find it useful to have ureteral catheters inserted The ureters then may be identified much more readily

## REFERENCES

Allen J G and Stefsmer E A The use of blood and plasma in surgical practice *Surg Clin North America* p 1597 Dec 1955

Bosch D T Islam A Tan C T C and Belling C A The elderly surgical patient *AMA Arch Surg* 64 269 1952

Cohn I Jr and Longacre, A B Preoperative sterilization of the colon *Antibiotic Annual* New York Med Fncy., Inc pp 105 117 1955 1956

Cole W H Schneewind J H and

CANHAM, R Role of protein metabolism in surgery *Surgery 37* 683, 1955

COLLER F A *Cancer of the Colon and Rectum* Monograph American Cancer Society, Inc Library of Congress Catalog Card 56 12087, p 64, 1956

COLLER F A, CROOK, C L, and IOB, V Blood loss in surgical operations *J.A.M.A 126* 1, 1944

CRANDON J H Nutrition in surgical patients *J A M A 158* 264, 1955

CULVER G A, MAKEL, H P, and BUCHER, H K Frequency of aspiration of gastric contents by the lungs during anesthesia and surgery *Ann Surg 133* 289, 1951

DANA, J B, and OHLER, R L Influence of heart disease on surgical risk *J A M A 162* 878, 1956

DEARING, W H, and NEEDHAM, C M Effect of oral administration of neomycin on the intestinal bacterial flora of man *Staff Meet Mayo Clin 28* 502, 1953

DISCOMBE, C Blood Transfusion *Textbook of British Surgery*, Vol III Edited by SIR HENRY SOUTTAR and J C COLLIGHER London William Heinemann Medical Books Ltd, 1958

DUDLEY, H A F *Principles of General Surgical Management* London F & S Livingstone Ltd, 1958

ETSTEN, B, and PROGER, S Operative risk in patients with coronary heart disease *J A M A 159* 845, 1955

FISHER C W Prevention of aspiration of stomach contents *Anesthesiology 14* 506, 1953

GUYNN V L, and REYNOLDS J T The use and abuse of blood transfusions *Surg Clin North America* p 19, Feb 1958

KREMEN, A J The problem of parenteral nitrogen administration in surgical patients *Surgery 23* 92, 1948

MILLER, W F, CADE, J R, and CUSHING I E Pre operative recognition and treatment of bronchopulmonary disease *Anesthesiology 18* 483, 1957

MONOGRAPH *Protein Nutrition in Health and Disease* Reprinted from *J.A.M.A* April 14 21, 28, May 12, 26, June 2, 9, 23, 30 1945

MOORE, F D, and BALL, M R *The Metabolic Response to Surgery* Springfield Ill, Charles C Thomas 1952

MORRISON, D R Risk of surgery in heart disease *Surgery 23* 561, 1948

MORTON, H J V, and WYLIE, W D Anaesthetic deaths due to regurgitation or vomiting *Anaesthesia 6* 190, 1951

PHILLIP, D F, DEARING, W H, and WALGH J M Comparison of complications following intestinal surgery after oral and parenteral pre operative antibiotic preparation *Surg, Gynec & Obst 106* 145, 1958

POLLACK, H *Therapeutic Nutrition* National Research Council Publication 234 Washington, D C, 1952

PRESTON, F W, BARNES, A U, MANDEL, E E STALEY, C J, and TRIPPEL, O H Effects of repeated infusions of a fat emulsion in surgical patients *Metabolism 11* No 6, Part II 758, 1957

RHOADS, J E Protein nutrition in surgical patients *Surg, Gynec & Obst 94* 417 1952

SCHNEEWIND, J H Precautions in determination of operability as related to nutrition *Surg Clin North America* p 31, Feb, 1958

VAN ITALIE, T B, MAYER, J, and STARE F J Nutrition in clinical medicine *New England J Med 250* 199, 1954

WILKINS L F, and KNIGHT, C D Abdominal surgery in the aged *A.M.A Arch Surg 76* 963, 1958

MEDICAL COLLEGE LIBRARY UDAIPUR

CHAPTER 3

# ANESTHESIA IN ABDOMINAL SURGERY

*John Adriani*

Besides the insensibility to pain the one other essential requirement of any method of anesthesia for abdominal surgery is that it provides muscle relaxation Without relaxation the operator is handicapped and cannot perform the operation deftly and with ease The abdominal muscles are powerful and are relaxed only by potent, general anesthetics, by blocking the nerve supply with local anesthetics, or by muscle relaxing drugs

There is some difference in anesthesia both technically and from the standpoint of postoperative morbidity, for upper abdominal operations and those of the lower abdomen and pelvis Techniques suitable and adequate for lower abdominal surgery may be objectionable for upper abdominal Spinal anesthesia, for example, serves admirably for lower abdominal and pelvic surgery but is not always satisfactory when operating in the upper abdomen There invariably is some discomfort, owing to traction More profound general anesthesia is necessary to relax the upper abdominal musculature Reflex response to visceral traction and manipulation is greater in the upper abdomen than the lower There is greater awareness of diaphragmatic movements, which often interfere with surgical manipulations

## FACTORS IN SELECTION OF ANESTHESIA

In selecting anesthesia for any purpose the following factors must be considered (1) The status of the patient, (2) the nature of the operation to be performed, including its duration and seriousness, as well as technical factors, (3) the effects of anesthetic drugs upon the patient, (4) the skill of the surgeon and (5) the skill of the anesthetist Anesthesia is selected with the assumption that both surgeon and anesthetist are competent

As is the case in other branches of surgery, a variety of risks is encountered in abdominal surgery Some patients are extremely old some are young some are newly born or premature Some are excellent risks while others are in a shocklike state or even moribund Some are dehydrated, jaundiced, and emaciated or may have a nonsurgical disease complicating the surgical disease The selection of anesthesia is governed largely by the status of the patient and the magnitude of the procedure

The first decision made is whether to use general anesthesia or some form of regional anesthesia, such as a spinal block Many surgeons prefer spinal anesthesia be

cause it affords excellent operating conditions Many patients are reluctant to accept spinal anesthesia Frequently the patient is persuaded and at times coerced into accepting spinal block There are various reasons why a patient objects to spinal anesthesia Some are unwilling because they do not wish to be awake during the operation These can be promised sedation with amnesic drugs and be assured that they will remember nothing Others fear the alleged sequelae of spinal anesthesia It is best to accede to the wishes of these and use another form of anesthesia lest one be involved at a later date in litigation for technical assault In good risk patients the choice between general anesthesia and spinal anesthesia is one of personal preference rather than intolerance by the patient Each method has its own advantages hazards and objections Infiltration and field blocks are usually reserved for poor risk patients or for performing minor procedures

## GENERAL ANESTHESIA

One has a choice of a number of drugs for general anesthesia However basically three are used ether cyclopropane or the combination of an intravenous ultra short acting barbiturate such as (thiopental) a muscle relaxant and nitrous oxide Nitrous oxide ethylene and vinyl ether are relatively impotent to be used as sole agents Combinations of drugs are the trend in present day practice Single agent anesthesia is uncommon

### Ether

Although used less today than heretofore ether is still the stand by The objections such as nausea vomiting prolonged induction and postoperative somnolence are overlooked when safety becomes the prime consideration Improvements in techniques of administration have been many The objectionable prolonged unpleasant induction has been overcome by the preliminary use of a combination of thiopental and a gas such as cyclopropane nitrous oxide or ethylene Ether has many overlooked advantages such as the wide margin of safety the fact that no other drug is necessary to obtain relaxation and that it causes varying degrees of exaggerated breathing which results in an increase in ventilation and freedom from respiratory acidosis It is the general anesthetic least complicated by respiratory acidosis Assisted or artificial respiration is not necessary

### Cyclopropane

Cyclopropane is one of the most useful of the inhalational anesthetics The rapidity and pleasantness of induction the prompt recovery and its lability are obvious advantages Anesthesia may be deepened and lightened at will Relaxation may be obtained with cyclopropane alone but deep anesthesia is necessary Muscle relaxants or ether is added instead

Cyclopropane affects the cardiovascular system more than ether The cardiac output is not decreased because myocardial depression does not occur unless anesthesia is deep Cardiac irritability is enhanced and arrhythmias varying anywhere from an occasional premature beat to ventricular tachycardia may occur They are most frequent during deep anesthesia or when ventilation is inadequate The coadministration of epinephrine norepinephrine and chemically allied sympathomimetic amines enhances cardiac irritability to such a degree that ventricular tachycardia or even ventricular fibrillation is possible The combination of epinephrine and cyclopropane therefore must never be used The addition of ether to cyclopropane mixtures minimizes or eliminates irregularities

Cyclopropane anesthesia causes a diminution in ventilation Strangely the arterial oxygen saturation does not decrease and the venous blood oxygen content is increased However carbon dioxide is retained and respiratory acidosis develops At the conclusion of anesthesia hypotension may develop this is believed to be the result of sudden release of the accumulated carbon dioxide A hyper

tension commonly occurs during cyclo propane anesthesia This is associated with the hypoventilation and is probably due to retention of carbon dioxide At times oozing occurs during anesthesia with this drug This is due to one or a combination of two factors the elevated blood pressure and a local vasodilatation, both of which are ascribed to carbon dioxide retention Bleeding and clotting times are unchanged, however The oozing ceases once the wound has been closed Oozing is not necessarily a characteristic of cyclopropane anesthesia but also occurs with other anesthetics, such as thiopental, particularly if accompanied by diminished ventilation

Respiration must be assisted, manually or mechanically, to ventilate the patient adequately during cyclopropane anes thesia An apnea frequently follows The hyperventilation reduces the blood carbon dioxide tension below the level necessary to activate the respiratory center, which is much depressed by the drug Controlled (artificial) respiration then becomes neces sary The addition of ether has a 'stimu lating effect and causes an increase in the depth of respiration, obviates the need of augmentation, or of controlling respiration The writers feel the combination of cyclopropane and ether is ideal for ab dominal surgery In addition to the effects on respiration ether facilitates muscle re laxation and protects against arrhythmias Premedication with morphine and scopol amine, intravenous injection of thiopental or other thiobarbiturate at the time of in duction to complete basal narcosis, fol lowed by cyclopropane and ether as needed, is the author s preference A muscle relaxant, preferably succinyl choline, facilitates endotracheal intubation It may also be added when the peritoneal cavity is opened and at the time of closure Reflex activity usually returns in the operating room as soon as the anes thetic is discontinued

Some anesthetists use light cyclopropane anesthesia combined with a continuous drip of succinyl choline With this, respiration must be controlled continuously The objections to controlled respiration will be discussed further on Both cyclopropane and ether are flam mable and, therefore, cannot be used if thermocoagulation is necessary

## Nitrous Oxide, Thiopental, and a Muscle Relaxant

The important intravenous anesthetics are ultra-short acting thiobarbiturates, the better known of which is thiopental A number of newer thiobarbiturates have been recently introduced, the better known of which are thiamylal (Surital) and methitural (Neraval) These are pharmacologically similar to thiopental and used exactly the same way and for the same purposes Barbiturates are non analgesic and do not effectively block reflexes unless used in dangerously large doses Consequently they are not suitable as sole agents for anesthesia They may be used for basal narcosis, in which case they may be combined with an analgesic drug to abolish reflex activity

The most widely used complemental agent is nitrous oxide Nitrous oxide is an impotent anesthetic requiring alveolar concentrations of approximately 80 per cent to yield anesthesia and loss of reflex activity An additive effect is established between the two drugs, which enhances the effect of the nitrous oxide In other words the unconsciousness obtained with difficulty with nitrous oxide is made com plete by the thiopental The analgesia that the thiopental lacks is supplied by nitrous oxide The two drugs complement each other Neither drug is capable of causing adequate muscular relaxation for major surgery A muscle relaxant, therefore, is added to overcome this difficulty

The rapid awakening from thiopental narcosis is well known This apparent rapid recovery is seen when administration is first commenced It is due to the rapid uptake of the drug by the fat depots of the body and the ready diffusibility through the blood brain barrier The thiobarbiturates are slowly detoxified Repeated administration causes an accumula tion in the body Prolonged somnolence,

circulatory and respiratory depression follow the use of more than 1 to 1½ Gm The nitrous oxide and the muscle relaxant allow far less thiopental to be used and provide more effective anesthesia than would be obtained if the drug were used as a sole agent The possibility of cumulative effects is lessened In long procedures it is customary to add a narcotic usually meperidine to augment the analgesic action of the nitrous oxide in order to keep the total dose of thiopental to a minimum

The muscle relaxants most commonly used as adjuncts to anesthesia are tubocurarine syncurine (Decamethonium) and succinyl choline (Anectine) Of the three succinyl choline is most widely used The drug is rapidly detoxified into choline and succinic acid by the plasma cholinesterases Its action therefore is fleeting In order to obtain a sustained effect it is given by a continuous drip during the time relaxation is required The muscle relaxants will be described subsequently

Some anesthetists administer the thiopental by continuous drip also Others use the fractional technique Which technique is used is a matter of personal preference Many trespasses are made in the name of anesthesia by unskilled individuals using these three drugs Some omit the nitrous oxide and rely only upon the thiopental and the relaxant The dual combination is used extensively in areas where anesthesia is administered by unskilled persons The thiopental causes unconsciousness and the muscle relaxant paralyzes so that the patient is rendered immobile and cannot protest Some anesthetists have lapsed into a comfortable rut and use this combination routinely on all patients for all surgical procedures The casual observer not familiar with problems of anesthesia is deceived by the apparent simplicity of this method

The compelling indication for the triple combination is in situations in which a fire hazard is present and a flammable inhalational anesthetic cannot be used It seems clear that the disadvantages of a nonflammable anesthetic outweigh the few minutes saved by using the thermocoagulator for hemostasis

Some of the objections to the triple combination are as follows (1) Cumulative effects of drugs are difficult to avert, particularly in prolonged operations Prolonged apneas from the use of large quantities of succinyl choline are common (2) Respiration is usually depressed or ceases entirely, necessitating the use of assisted or controlled respiration (3) Laryngeal spasm is obviated by the action of the relaxant on the vocal cords but autonomic activity is not abolished bronchial spasm is possible and often occurs (4) The anesthesia is usually uneven in depth because each drug is administered in a haphazard manner and at random It is being realized more and more that many of the ills of general anesthesia are the result of hypoventilation Yet many anesthetists resort to the use of techniques and drug combinations that depress respiration and then expend considerable effort to obviate the sequelae with elaborate apparatuses and the quasi effective assisted or controlled respiration Such difficulties in my opinion are better avoided by using other drugs or technique

## Muscle Relaxants

The muscle relaxants are nonanesthetic nonhypnotic substances whose action is primarily peripheral They act by blocking the transmission of impulses from the peripheral nerves to striated muscle They neither reduce the frequency of nerve impulses nor depress the activity of muscle fibers Two pharmacologic types are recognized those that interfere with the depolarizing action of acetyl choline at the junctional membrane of nerve and muscle fiber and those that cause a persistent depolarization of the membrane

The alkaloid tubocurarine which is the active principle of curare decamethonium (Syncurine) and succinyl choline (Anectine) are the most widely used muscle relaxants Succinyl choline is the most popular and widely used of the three Tubocurarine is nondepolarizing and acts

by inhibiting acetyl choline while decamethonium and succinyl choline act, initially at least, by causing persistent depolarization

The muscle relaxants have been a boon to abdominal surgery However, they are not as simple-acting as is often believed It is being realized more and more that their action is complex and that some central depressant effects may develop Prolonged periods of apnea are not uncommon, particularly when large quantities are used over protracted periods of time in quantities that cause respiratory paralysis, and controlled respiration has been necessary The apneas are not easily explained, are worrisome, and often persist for hours They have occurred following use of all the relaxants but the incidence appears to be higher following the use of succinyl choline Perhaps this is explained by the fact that succinyl choline is used far more extensively than curare Among the explanations offered are (1) The patient has a low serum cholinesterase level The succinyl choline is slowly hydrolyzed Low levels are found in debilitated cachectic patients, those with anemias, and those with liver diseases (2) Part of the dicholine is partially hydrolyzed incompletely to the monocholine, particularly during prolonged use of large quantities as may occur during the "drip" technique The monocholine, which appears to have a blocking, nondepolarizing effect instead of a depolarizing action, accumulates (3) There is some evidence that central depressions are caused by large quantities of relaxants or by hypnotic and narcotic drugs used as adjuncts, such as thiopental and meperidine (Demerol) The adjunctive drugs are often used in excess because there is no reliable guide to dosage

## REGIONAL ANESTHESIA

Regional or conduction anesthesia is employed when one wishes to obviate the risks, disadvantages, and discomforts of general anesthesia Spinal block, peridural block, field block (the intercostal and lumbar nerves), and infiltration are the types ordinarily employed for abdominal surgery

### Spinal Anesthesia

Spinal anesthesia for abdominal surgery is either "medium" spinal for lower abdominal or "high" for upper abdominal surgery The drug must reach the upper thoracic segments to obtain high spinal anesthesia, while paralysis of the lumbar and lower thoracic segments suffices for lower abdominal surgery The seemingly haphazard spinal anesthesia techniques of yesterday have been supplanted by more precise modern techniques in which extent and degree of blockade and intensity are well controlled The extent or level of spinal anesthesia is controlled by the dosage of the selected drug, specific gravity of the solution, the volume of the solution the rate of injection and the position of the patient after injection Solutions heavier (hyperbaric) or lighter (hypobaric) than spinal fluid are used Solutions of the same specific gravity (isobaric) are seldom used The effects of gravity are utilized in directing the drug to the desired spinal segments The spinal cord, in most adults, ends between the first and second lumbar vertebrae Lumbar puncture is always performed below this site to avoid trauma to the cord Obtaining the proper height or level of anesthesia is most important, particularly in upper abdominal surgery The head down supine position favors caudad migration of a hypobaric solution A hyperbaric solution gravitates cephalad In the head up position the reverse is true Glucose is added to solutions to make them hyperbaric Hyperbaric techniques are more common than hypobaric

DRUGS USED FOR SPINAL ANESTHESIA

The duration of spinal anesthesia is controlled by selecting the proper drug Duration is a function of the chemical structure of the drug Varying the dosage does not affect duration appreciably

Blocks induced with procaine, piperocaine (Metycaine), and hexylcaine (Cyclaine) last approximately one hour,

those with tetracaine (Pontocaine) last approximately two hours, while dibucaine (Nupercaine) lasts three hours Epinephrine (0 5 mg ) added to solutions of any of these drugs increases the duration action of each approximately 60 per cent Long-lasting anesthesia by the single injection method is obtained by using dibucaine or tetracaine combined with epinephrine Tetracaine with epinephrine provides anesthesia long enough for most two to three hour abdominal procedures Some anesthesiologists use the continuous (actually the repeated or serial) spinal technique for long operations A catheter of small bore is introduced intrathecally through which the drug is injected at necessary intervals

PHYSIOLOGIC DISTURBANCES CAUSED BY SPINAL ANESTHESIA Certain physiologic disturbances of significance occur during spinal anesthesia High spinal anesthesia causes a blockade of sensory motor and autonomic fibers in the sacral, lumbar, and lower thoracic segments The sympathetic fibers in the thoracic segments are blocked but the parasympathetic fibers, since they pass along the cranial nerves, remain active This denervation of the autonomic nervous system in the lower part of the body and partial denervation in the upper contributes to the hypotension characteristic of spinal anesthesia, as well as to the bradycardia, nausea, and vomiting It also causes contraction of the bowel Liver, renal, and pulmonary function are not affected The major derangements are circulatory Circulation time is prolonged, cardiac output is reduced and venous return to the heart is decreased

ADVANTAGES OF SPINAL ANESTHESIA Some of the advantages of spinal anesthesia are as follows (1) It provides excellent muscle relaxation (2) The block is accompanied by little or no disturbances of metabolic processes, if there is no hypotension (3) Loss of consciousness, excessive secretions excitement, postanesthetic nausea, somnolence, and other disagreeable features of general anesthesia are avoided (4) Cautery or electrical equipment may be used if necessary The operator may administer the spinal anesthetic himself, provided he has a competent individual overseeing the patient afterward

DISADVANTAGES OF SPINAL ANESTHESIA Unfortunately spinal anesthesia presents a number of serious and often disregarded drawbacks (1) Once anesthesia has been instituted it cannot be terminated should any untoward reaction occur (2) The duration, although predictable, is not always certain The operation may outlast anesthesia and supplemental general anesthesia becomes necessary This subjects the patient to the hazards of two anesthetics (3) Failures resulting from technical errors occur, even in the hands of the skilled (4) Paralysis of the intercostal muscles (in high spinal block) results in hypoventilation (5) Hypotension though readily controllable by the use of vasopressor drugs, may at times be precipitous and lead to cardiac arrest Vasopressors such as ephedrine phenylephrine (Neosynephrine), methoxamine (Vasoxyl) are usually effective in overcoming hypotension in healthy subjects However, patients with cardiovascular defects do not always respond satisfactorily The drug must be administered intravenously Therefore a vein should be cannulated immediately after anesthesia is induced When hypotension is anticipated one may administer the vasopressor prophylactically (6) Neurologic complications are rare but do occur, nonetheless They are severe when they do These are described further on (7) The patient is conscious throughout the operation Some patients are not psychically suited for spinal anesthesia and are not cooperative This objection can be obviated by the use of sedation or basal narcosis (thiopental) (8) The vagal pathways to the viscera are not blocked Impulses pass upward to the medulla This causes nausea and vomiting when traction is made or the organs are manipulated (9) Impulses also pass in a retrograde manner, along the sympathetic chain and thence into the cord above the level of the block The patient experiences pain in the chest, neck or back when the traction is made or the viscera are manipulated This is one of the chief reasons why spinal anesthesia is objectionable for

upper abdominal surgery A complete blockade is not always obtained, even when anesthesia extends into the lower cervical segments because impulses also pass along the phrenic nerves The patient experiences shoulder pain This is common during cholecystectomy (10) The incidence of pulmonary complications, particularly atelectasis, is nearly twice that experienced with low spinal

CONTRAINDICATIONS TO SPINAL ANESTHESIA Unfortunately, there are situations in which spinal anesthesia should not be used There are others where individualization is necessary The contraindications, therefore, are absolute and relative (1) Spinal anesthesia, particularly high spinal, should not be used when cardiovascular diseases are present, inasmuch as the circulatory system is vulnerable Severe hypotension, disturbances in the cardiac rhythm the presence of myocardial diseases may be relative contraindications to medium spinal Spinal anesthesia is poorly tolerated by patients with hypotension or hypovolemia (2) Neurologic diseases, be they degenerative, suppurative, or otherwise are contraindications even though on evidence exists that such diseases are aggravated by the anesthetic Patients may, at a later date, ascribe symptoms of the disease to the spinal anesthetic and institute legal proceedings (3) High spinal anesthesia should not be used in the face of severe pulmonary insufficiency Intercostal paralysis decreases the tidal exchange and causes a further reduction in ventilation In the good risk patient this paresis may be of little consequence In the poor risk patient, however, this is a most objectionable feature (4) Spinal anesthesia is contraindicated in patients who have well defined anemia because the oxygen carrying power of the blood is reduced Tissue anoxia may occur (5) Spinal anesthesia is contraindicated in patients who have increased intra abdominal pressure owing to tight gaseous distension ascites, or large tumors A severe, precipitous often irreversible fall in blood pressure may follow induction of the block (6) Spinal anesthesia is contraindicated in patients who have septicemia because bacteria may be carried into the spinal canal by the needle (7) Infections at the site of the lumbar puncture are contraindications (8) Patients of advanced age tend to develop circulatory disturbances more frequently than younger subjects because the vasomotor compensatory mechanisms are not able to maintain homeostasis (9) Children are psychically unsuited for spinal anesthesia and, therefore, are not good subjects for it (10) Distortions of the bony changes in the vertebral column often preclude the use of spinal anesthesia because lumbar puncture is difficult to perform

POSTANESTHETIC NEUROLOGIC COMPLICATIONS Neurologic complications may occur after spinal anesthesia The most common, vexsome, and annoying of these is postlumbar-puncture headache This is caused by leakage of spinal fluid from the perforation made in the dura by the needle The headache is transient and leaves no sequelae, fortunately

The least common, most serious complication, and the most feared is the paraplegia, which is often called the 'cauda equina syndrome" The exact cause of this is not known Myelitis and arachnoiditis have been found in some of these when laminectomy was performed after the syndrome has appeared Pre existing neurologic diseases particularly tumors of the spinal cord and errors in technique, are believed to play a role

Palsies of the cranial nerves, particularly of the sixth, may also complicate spinal anesthesia These are associated with loss of cerebrospinal fluid and postlumbar puncture headache Contamination owing to poor technique has caused meningitis, arachnoiditis, and peridural abscess Backache, which at times follows lumbar puncture, may be due to trauma to the periosteum, intraspinous ligaments, to the intervertebral disc, or to aggravation of preexisting skeletal muscle disorders

## Epidural Anesthesia

The spinal nerves may be blocked as they pass through the epidural space The spinal nerves acquire a sheath, which is a

continuation of the dura as they pass from the subarachnoid space The dose of local anesthetic necessary is five or six times that required for spinal block because the drug must penetrate this outer neural sheath The needle is introduced in the lumbar area in the same manner as it is for lumbar puncture A syringe containing saline a capillary tube or a small balloon is fitted into the hub of the needle in order to determine when the needle enters the peridural space A negative pressure is created in the space by bowing of the back and stretching the longitudinal ligaments When the bevel enters the peridural space the fluid in the capillary tube is drawn inward if a balloon is used it collapses if saline in a syringe is used the resistance on the plunger suddenly disappears and the fluid passes inward easily Neither the dura nor the arachnoid should be pierced—otherwise a spinal block results The period of latency before anesthesia is established is much longer 10 to 15 minutes than in a spinal block Relaxation is not as complete as it is with subarachnoid block The incidence of failures is higher The needle may inadvertently pierce the subarachnoid space in which case one hesitates to complete the block When this occurs however the needle may be pushed into the subarachnoid space and a spinal anesthetic given instead

A modified form of epidural anesthesia is obtained by introducing the needle through the sacrococcygeal membrane and injecting a large volume of local anesthetic solution into the caudal canal Ordinarily in caudal block 25 or 30 cc of 1 per cent procaine are injected Anesthesia of the caudal areas only is obtained However, if larger volumes are employed the drug is forced into the lumbar and thoracic portion of the peridural space and analgesia for abdominal surgery may be obtained One objection to this technique is that the total dosage anesthetic drug necessary for adequate anesthesia may be excessive

Epidural block is more difficult and cumbersome to induce and less certain than subarachnoid block Epidural anesthesia has the same uses and purposes as spinal anesthesia The indications for epidural anesthesia by the lumbar route are few There is less possibility of meningitis Neurologic complications are allegedly less frequent in comparison to spinal anesthesia However, this point is debatable because the block has been employed less extensively than spinal block and comparative data are not available The block is actually a paravertebral block because the drug migrates from the epidural space through the intravertebral foramen along the spinal nerves There is evidence that some of the drug passes into the subarachnoid space also Therefore the argument that the drug does not come into contact with the nerve roots or the cord as in spinal anesthesia is not valid

The disadvantages of peridural block are (1) that the needle may be inadvertently placed in the subarachnoid space instead of the epidural and an overdose of local anesthetic drug deposited there (2) Muscle relaxation is not always adequate (3) Level of analgesia is unpredictable and difficult to control (4) Reactions from the local anesthetic drug may occur from absorption because large amounts are needed for effective blocking (5) The drug does not easily penetrate each of the spinal nerves and anesthesia is incomplete or segmental (6) There is always a possibility of intravascular injection because the epidural space is lined with a plexus of veins

## Drugs Used for Regional Anesthesia

The quantities of local anesthetics used for spinal anesthesia are relatively speaking small compared to the amounts used for direct nerve blocking and infiltration Reactions from the systemic effects of local anesthetics circulating in the blood therefore are extremely rare In other techniques greater quantities are used Reactions are relatively speaking common Before proceeding with the discussion of the regional technique a summary of the important local anesthetics will be necessary In order to be of practical value for

regional anesthesia a drug must produce adequate, intensive anesthesia that is rapid in onset and of sufficient duration to permit successful completion of the operation In addition, it should not cause local irritation, should have low systemic toxicity and be compatible with vasoconstrictors The effective concentration of a local anesthetic varies with the size of the nerve fiber The autonomic and sensory fibers in a mixed nerve are smaller than the motor and are, therefore, affected first A blockade of the sensory and the autonomic fibers develops before the motor This apparent selectivity depends on the fiber size, which in turn influences the ease of penetration of the drug into the fibers Drugs penetrate non myelinated fibers more easily than the myelinated Penetration into large nerve trunks, since they have a larger surface and a denser perineural sheath, occurs more slowly than into small nerves Solutions used for blockade of larger centrally located nerve trunks should be more concentrated than those for the smaller peripherally located branches Blockade of the nerve endings in the skin and subcutaneous areas may be accomplished with still more dilute solutions Fifteen or twenty minutes often elapses before anesthesia is completely established when blocking large nerve trunks The ability of a drug to penetrate the membrane of a nerve fiber during induction of anesthesia is a physical factor that varies with the molecular configuration of the drug Longer-lasting drugs diffuse more slowly and, therefore, have a longer latent period During recovery, when the concentration of the drug in the medium surrounding the nerve is reduced below the equilibrium level, the outward diffusion likewise is slow This apparently explains the variations in duration of drugs

PROCAINE Procaine, the best known and most universally used, is the safest of the local anesthetics Newer drugs appear gradually to be supplanting it Procaine is rapidly detoxified and eliminated Reactions are mild when they occur and local damage to tissues is uncommon The maximum concentrations and volumes for nerve blocking or infiltration for the average adult are as follows

2% not more than 50 cc in one hour (1 Gm )

1% not more than 100 cc in one hour (1 Gm )

½% not more than 200 cc in one hour (1 Gm )

Procaine possesses no topical action and cannot be used to anesthetize mucous membranes Duration of anesthesia with procaine in a nerve block, averages 45 minutes Two per cent solutions are required for blocking large nerve trunks such as are encountered in paravertebral and peridural block 1 per cent is satisfactory for field block and 0 5 per cent for infiltration

TETRACAINE Tetracaine (Pontocaine) is ten times more potent and more toxic than procaine It is the drug most widely used for spinal anesthesia It may be used for infiltration and nerve blocking Solutions of 0 1 per cent are usually employed However, most workers prefer less toxic drugs One milligram of tetracaine is equivalent to 10 mg of procaine in anesthetic potency Duration of action of tetracaine is almost twice that of procaine Epinephrine prolongs the block 60 per cent or more

LIDOCAINE Lidocaine (Xylocaine) is extensively used for nerve blocking and infiltration It has a very brief latent period and produces immediate anesthesia when injected Anesthesia lasts one hour without epinephrine and two to three hours with epinephrine The volumes and strengths of solutions recommended are approximately half to two thirds of those for procaine in similar situations Lidocaine possesses striking ability to diffuse through the tissues The incidence of failures compared to procaine is reduced considerably because if by chance the needle is introduced at a distance from a nerve, an effective block may still be obtained because the drug diffuses over a wide area and may still reach the nerve The effects upon the motor nerves are more intense than they are with procaine.

PIPEROCAINE Piperocaine (Metycaine) is closely allied chemically to cocaine, being an ester of benzoic acid It is slightly more potent and longer lasting than procaine Solutions of 1 5 per cent are suitable for blocking large and medium sized nerve trunks A 1 per cent solution should be used for smaller nerve trunks and for infiltration

Several new drugs have clinically received acceptance Two will be mentioned, hexylcaine (Cyclaine) and chlorprocaine (Nesacaine) The duration of action, toxicity, and general usage appear to parallel those of procaine Volumes, dosages, and concentrations are similar

VASOCONSTRICTORS Vasoconstrictors prolong the effect of local anesthetics The most efficient vasoconstrictor is epinephrine Concentrations of 1 100,000 usually suffice Vasoconstrictors are usually omitted if the patient has cardiovascular disease, peripheral vascular disease, hyperthyroidism, or has had a sympathectomy Phenylephrine (Neosynephrine), ephedrine, norepinephrine, and related amines are nowhere near as effective

SPREADING FACTORS The enzyme Hyaluronidase is added to solutions of local anesthetics to facilitate spread over a wider area The enzyme causes increased absorption from the infiltrated areas and a decrease of duration of the block Its value has been questioned by most anesthetists The writer prefers lidocaine, since "spreading" is obtained without use of the enzyme

REACTIONS TO LOCAL ANESTHETICS When a local anesthetic is rapidly absorbed into the vascular system after injection or topical application a reaction results Reactions are of two types, based on mechanisms of causation the circulatory (cardiovascular) type and the stimulating (central nervous system) type The circulatory type, characterized by circulatory collapse, is the result of myocardial depression, dilatation of the vascular bed, or a combination of these two factors Hypotension, bradycardia, and other manifestations of vascular collapse occur In severe cases the reaction may appear abruptly Pallor suddenly appears, followed by syncope, respiratory failure, and death In some cases the onset is slower and circulatory failure supervenes gradually The patient may become drowsy and pass into a comalike state Reactions of this type have been ascribed to idiosyncrasy or sensitivity That they are due to overdosage and a high blood level of the drug is well established When hypotension is the chief manifestation a vasopressor such as ephedrine or phenylephrine (Neosynephrine) intravenously counteracts the depression Should asystole be suspected, cardiac massage and artificial respiration must be instituted simultaneously without delay

The central nervous system stimulation type of reaction is usually ushered in by excitement and disorientation which are quickly followed by convulsions and other symptoms of intense central nervous system stimulation The prodromal signs are frequently assessed lightly and termed hysteria The severity and duration of the stimulation depends upon the pharmacologic nature and rapidity of absorption of the drug Convulsive manifestations may be fleeting and be followed by depression of the nervous system particularly when large amounts of the drug are absorbed The patient then becomes comatose, completely depressed, and develops circulatory and respiratory failure

Convulsions are controlled by the intravenous administration of an ultrashort acting barbiturate such as thiopental (Pentothal), thiamylal (Surital), or hexobarbital (Evipal) If none of these is available a short acting barbiturate such as secobarbital (Seconal) or pentobarbital (Nembutal) may be used The barbiturate is slowly given intravenously in quantities sufficient to control convulsions The ultrashort acting barbiturates are more suitable for this purpose because they act quickly and are more potent Barbiturates merely antagonize the stimulating action of the drug They do not hasten detoxification or elimination of local anesthetics They neither overcome the depressant effect on the circulatory

system nor do they antagonize the paralytic phase of a reaction They are suitable only to control convulsions They do not neutralize' the local anesthetics

Regional anesthesia in any form should not be attempted without having available an ultrashort acting barbiturate, a vasopressor drug, syringes and some effective method of administering artificial respiration

Pallor, tachycardia, tremor, and excitement caused by combining epinephrine with local anesthetic drugs may at times be confused with the prodromal phases of a reaction However, epinephrine does not cause disorientation, convulsions, and coma

## Field Block

ABDOMINAL FIELD BLOCK Abdominal field block is frequently used for poor risk patients The upper abdomen is innervated by the last seven intercostal nerves which, at the costal margin, branch and supply respectively the skin, the subcutaneous tissues, the muscle layers, the fascia, and the parietal peritoneum The block is performed in one of two ways (1) A wall of local anesthetic may be infiltrated along the costal margin from the xyphoid to the lateral border of the rectus muscle or (2) each nerve may be injected indirectly in the intercostal spaces The term field block should be reserved for the former and intercostal nerve block for the latter technique

For field block intradermal wheals are raised at the tip of the xyphoid at the tenth costal cartilage, and at the lateral border of the rectus at the level of the umbilicus A 5 or 8 cm needle, depending upon the thickness of the abdominal wall, is attached to a 10 cc syringe The injection is commenced at the lowermost wheal by passing the needle through the superficial fascia, using 0 5 per cent procaine or other drug of choice of equivalent strength The needle is inclined toward the rectus muscle and introduced so that it pierces the fascia and the muscle A feeling of a break of resistance is noted when the fascia is entered The needle is then advanced 0 5 to 1 centimeter deeper, depending on whether the patient is lean or obese, and 2 cc of the local anesthetic solution is injected in this area The needle is withdrawn almost to the skin and reintroduced through the same layers in a fanwise manner and an equivalent volume is injected a number of times in both caudad and cephalad directions, so that a 'wall' of local anesthetic drug is deposited over a distance of 4 or 5 cm along the costal border The needle is withdrawn and the injections are repeated in the same fanwise manner through the remaining wheals along the costal margin so that each group of fans connects with the next and forms a continuous wall The subcutaneous tissues are infiltrated also so that all the wheals are connected and make a continuous line from the xyphoid to the last intradermal wheal The injections are performed bilaterally The wall of local anesthetic may be extended downward along the entire rectus muscle by raising wheals at the lateral border of the rectus below the level of the umbilicus as far as the pubic, if the contemplated operation is in the lower abdomen

INTERCOSTAL NERVE BLOCK To perform an intercostal block the patient is placed in the supine position and the skin is prepared in the routine fashion An intradermal wheal is raised over the lower border of the 6th to 12th ribs along the posterior axillary line A 5 cm 22 or 24G needle is introduced through each wheal until contact is made with the lower border of the rib The soft tissues in the region of the puncture are directed downward with the thumb of the left hand until the point of the needle is opposite the lower border of the rib The needle is inserted 0 25 to 0 5 cm beyond the lower border of the rib Paresthesias may be elicited if the wheal encounters the nerve Two cc of 2 per cent procaine or other drug of choice of equivalent strength may be used The intercostal nerve, artery, and vein lie in the intercostal groove, the vein being inferior to the artery and the nerve

being inferior to both the vein and artery A depth marker is placed on the shaft of the needle so that the needle will not be introduced into the pleural space

Intercostal block or abdominal field block may be supplemented by sedation with thiopental or other thiobarbiturate or anesthesia with ethylene, nitrous oxide or light cyclopropane

SPLANCHNIC BLOCK Splanchnic block may be necessary as an adjunct to intercostal nerve block, abdominal field block, local infiltration or spinal block when discomfort is felt in the thorax The splanchnic nerves (the greater, lesser and least) arise from the 5th to 12th thoracic segments The greater splanchnic nerve passes from the thorax through the crus of the diaphragm and enters the semilunar ganglion These are bilateral The splanchnic nerves are accessible at the first lumbar vertebrae behind the crus of the diaphragm In a postlateral position on the right side, is the vena cava and on the left the aorta The splanchnic nerves may be reached by two routes the extra abdominal or posterior and the transabdominal or anterior The posterior route is used for the relief of intra abdominal pain During operation the transabdominal route is the only feasible route so it will be described here

The landmarks for the transabdominal route are (1) lesser curvature of the stomach, (2) lesser omentum, (3) first lumbar vertebrae (4) the aorta, (5) the vena cava and (6) the hepatic artery

The procedure is as follows Retract the left lobe of the liver gently upward with a retractor Draw the stomach slightly toward the left and downward to tense the lesser omentum Palpate the hepatic artery originating near the coeliac axis This can be identified by its pulsations Place the left index finger so that it makes contact with the anterior surface of the first lumbar vertebrae Inject 10 cc 0 5 per cent procaine into the lesser omentum near the cardia Identify the aorta and place the left index finger between it and the vena cava and retract it laterally Introduce the 22G needle at the radial side of the index finger and inject 50 to 75 cc of 0 5 per cent procaine holding the needle firmly to avoid displacement Keep the needle on the radial side of the finger, never in the mid line or on the right side, to avoid trauma to the vena cava The needle may be displaced by respiratory movements and enter a blood vessel Aspirate frequently during the injection

PARAVERTEBRAL LUMBAR BLOCK Bilateral paravertebral lumbar block may be performed for anesthesia of the pelvis and lower abdomen However, there is a good deal of overlapping between the lumbar nerves and the lower intercostals, so that anesthesia is seldom adequate Discomfort is usually felt from exploration and use of packs and retractors The block, therefore is seldom satisfactory

## Infiltration

Infiltration anesthesia is frequently employed for poor risk patients One per cent procaine solution is usually employed In children and debilitated patients 0 5 per cent solutions are effective Infiltration is not always the best choice for poor risk patients because hypotension frequently develops from the myocardial depression caused by the drug even before the operation begins Then of course the surgical trauma superimposed during local anesthesia is the same as it would be under general anesthesia and in some cases is greater, particularly if anesthesia is not adequate

## Intentional Hypotension During Operation

It has been known for some time that sympathectomized animals withstand hemorrhagic shock for longer periods of time than those with intact vasomotor systems This principle appears to hold true in humans also Hypotension is deliberately induced by denervating the vascular system to minimize blood loss during surgical procedures in which hemorrhage is antic

ipated Denervation is accomplished by (1) inducing a total spinal block, (2) using a ganglionic blocking drug, (3) using a sympatholytic drug Some workers induce hypotension by performing arteriotomy The vasomotor system remains intact in this technique

Arteriotomy consists of drawing blood from one of the radial arteries into a sterile receptacle containing an anticoagulant until the desired blood pressure drop is obtained The blood is retransfused when the need for the hypotension is over Since the vasomotor control is not interrupted the advantages of sympathectomy are not obtained when this technique is employed Of the two techniques generally used to induce hypotension, total spinal block and ganglionic blockade, the latter is the simplest In present day methods two ganglionic blocking drugs are used, hexamethonium and a proprietary thiophanium derivative called Arfonad The Arfonad is more extensively used in this country because of its evanescent action The drug is rapidly infused intravenously by the drip technique Usually the blood pressure is reduced to 80 systolic or less If allowed to remain below 60 mm Hg systolic for any length of time the renal blood flow may be impaired Obviously, since the circulation time is prolonged, thrombosis of the cerebral, coronary, mesenteric, and other vessels is a possibility Cerebral damage from local tissue anoxia, anuria and reactionary hemorrhage are other hazards of this method of anesthesia Blood must be replaced as lost since these patients do poorly if a hypovolemia state develops The technique is designed primarily to avoid blood loss and to create a bloodless field when excessive oozing is anticipated Arterial bleeding is not decreased The method is reserved for extirpation of malignant tumors or in benign conditions in patients in whom a lifesaving operation could not be performed without causing fatal hemorrhage The hypotension should not be maintained for more than an hour, otherwise cerebral damage results from inadequate perfusion of the brain

## Hypothermia

Central nervous system depressants inactivate the heat regulatory centers The body temperature of an anesthetized patient tends to become the same as that of the external environment In warm surroundings hyperthermia develops, in cold, hypothermia Under ordinary circumstances in operating rooms body temperature fluctuates 2° or 3° C below normal This decrease in temperature is insignificant Drastic cooling can be accomplished by external application of ice

Hypothermia is a recent innovation in surgery The primary purpose of cooling is to decrease metabolism Temperatures ranging from 28° to 24° C are attained This reduction in metabolism is advantageous for surgery during which the blood supply must temporarily be occluded through an area or in patients who have a low arterial oxygen saturation It may make possible an otherwise impossible operation in a debilitated subject The patient is cooled externally by immersion in a tub of ice water by wrapping in a special blanket composed of rubber coils through which ice water flows or by surrounding the body with ice packs Internal cooling by circulating the blood through plastic coils or surrounding the heart with cold saline is used to a lesser extent

Constant monitoring with an electrocardiograph, continuous recording of temperature with rectal thermometers, and periodic determinations of blood pH are necessary because serious irreversible physiologic disturbances may occur As the temperature falls below 30° C artificial respiration becomes necessary because spontaneous respiration ceases at 28° C Cardiac irritability increases markedly at 24° C and ventricular fibrillation may occur Respiratory acidosis due to retention of carbon dioxide, further enhances the cardiac irritability and increases the possibility of ventricular fibrillation Forced ventilation is necessary to control the blood carbon dioxide tension Ventricular fibrillation is difficult to reverse once it occurs Shivering, because it predisposes to ventricular fibrillation, must

be avoided by having the patient adequately anesthetized Frostbite and fat necrosis are possible technical complications

Cooling by the use of drugs alone, such as a combination of chlorpromazine, Phenergan, and meperidine, has been described by certain European workers but it appears to be of doubtful practicability There is some possibility that hypothermia may be of value in abdominal surgery Certainly it is of value for resection of the abdominal aorta

## METABOLIC DISTURBANCES CAUSED BY ANESTHESIA

### Acid Base Balance

Most anesthetics cause some changes in the metabolic processes of the body Those resulting from disturbances in respiration, particularly respiratory acidosis, are most prominent Metabolic acidosis eventually supervenes if respiratory acidosis is allowed to persist During deep ether anesthesia the plasma concentration of anions resulting from nonvolatile acids is increased particularly the lactate and pyruvate ions This, presumably, is due to impaired carbohydrate metabolism following the increased output of epinephrine Most anesthetics, initially at least, cause little or no metabolic acidosis in the nonacidotic patient An existing acidosis such as is encountered in dehydration, in diabetic patients, shock, renal insufficiency, and so on is usually enhanced by anesthesia, particularly ether, and the narcotics

A pre-existing metabolic alkalosis may complicate operation Such a patient may be sensitive to the effects of hyperventilation and delay the return of a spontaneous respiration

Anesthetics often interfere with reflex control of respiration, which in turn results in deviations of blood gas content Patients who have had muscle relaxants or excess nonvolatile anesthetics such as thiopental or narcotics may have ineffective spontaneous respiration, complicated by anoxia or carbon dioxide retention or both The inhaled percentage of oxygen may be high enough to maintain full oxygenation but ventilation is inadequate to prevent carbon dioxide retention The signs of hypercapnia are variable and depend upon the susceptibility of the patient to carbon dioxide Hypercapnia is least common during ether anesthesia because ventilation is as a rule increased by this drug Sudden reversal of the hypercapnic state may precipitate hypotension Evidence exists that cardiac arrest may occur following this sudden change The long range effect of slight respiratory acidosis unless allowed to persist, is not significant Long standing respiratory acidosis eventually leads to difficulty and becomes complicated with metabolic acidosis

### Carbohydrate Metabolism

Some anesthetic drugs have significant effects on the metabolism of carbohydrates Ether and chloroform cause glycogenolysis which in turn results in hyperglycemia There is considerable evidence that this is caused by release of epinephrine and sympathetic overactivity The rise in blood sugar is less frequent during thiopental narcosis, cyclopropane, spinal and local anesthesia When anesthesia is complicated by anoxia, the rise is pronounced

Changes in protein metabolism caused by anesthesia are per se of little significance The effects of surgery are of far greater significance The serum proteins and levels of nonprotein nitrogen are altered considerably by surgery but little by anesthesia Data on the effects of anesthetics upon the metabolism of fats are meager

### Liver Function

The writings on the effects of anesthesia upon the liver are at times confusing Although it is difficult to assess many of these data, the bulk of the clinical evidence indicates that most anesthetics cause some transient impairment of hepatic function The effects studied are the ability of liver to excrete dyes (Bromsulfalein), conversion of various sugars to

glucose, the ability to oxidize fats, detoxifying functions, and production of abnormal proteins On the whole the impairment of function is temporary and reversible and is not associated with symptoms of clinical significance Much evidence exists that the accentuation of liver disease may be avoided by proper preoperative preparation Such details as correcting the nutritional status of the patient by supplying vitamins, proteins, and carbohydrates, avoiding halogenated hydrocarbons, attention to dosage of anesthesia and proper anesthetic techniques such as maintaining adequate ventilation, are important Nonvolatile drugs that are detoxified by the liver should not be used, so as to avoid possible prolonged somnolence

### Renal Function

Most general anesthetics suppress renal function and cause a decrease in urinary output Changes occurring during general anesthesia are of vascular origin, presumably the result of a renal vasoconstriction, rather than to a direct effect of the anesthetic drug upon the nephron Surgery presumably does not impose any further change During spinal anesthesia there is little alteration in renal function if no hypotension develops During hypothermia there is also interference with tubular secretion and reabsorption Glomerular filtration is reduced The tubular reabsorption of various electrolytes is altered for several days in the postoperative period

### Effects on Adrenal Glands

Certain of the metabolic disturbances associated with anesthesia and surgery, notably sodium retention and water retention, increased potassium excretion and negative nitrogen balance, resemble in many ways those produced by hyperactivity of the adrenal cortex For many years the activity of the adrenal gland has been associated with anesthesia An increase in both sympathetic activity and output of the adrenal hormones occurs with most general anesthetics Existing data on blood corticosteroid levels, scant as they are, indicate that there is an increase during anesthesia This increase, however, is small compared to the increase caused by operation Patients who have been under treatment with cortisone or ACTH before coming to operation may have a depressed adrenal cortical function and may fail to respond to stress stimuli in the usual and normal fashion A shocklike state may develop during operation unless the same or increased dosage of the hormones is given prior to or during the procedure This hypotension appears to be irreversible and does not respond to fluids or vasopressors unless intravenous hydrocortisone is used also

## REFLEX ACTIVITY DURING ABDOMINAL SURGERY

Reflexes are activated by handling of the viscera during abdominal surgery that affect both the circulatory and respiratory systems These reflexes are seen more frequently during general than during regional anesthesia and in upper abdominal more than in lower abdominal operations Various names have been given to these but they are most often designated as the celiac plexus reflex or the Bruer Luckhardt reflex This reflex activity is not a consistent occurrence, either in frequency or intensity For this reason these have eluded description and classification One of the prominent and almost consistent manifestations of this reflex activity is adduction of the vocal cords, which gives rise to a partial laryngeal spasm This spasm is more frequent when such anesthetics are used as cyclopropane and thiopental (and other thiobarbiturates), which manifest some spasmogenic activity The spasm is laryngeal as a rule but it may also be bronchial Ventilation is impaired from the partial obstruction The movements of the diaphragm are spasmodic and jerky and interfere with the operation The inadequate ventilation interferes with the absorption of inhalational anesthetics Relaxation is poor Usually the spasm is more frequent and severe in upper abdominal surgery

These reflexes are caused by traction upon any organ but they occur more often when the structures of the biliary system, the stomach the spleen or diaphragm are manipulated Endotracheal intubation solves the problem by holding the vocal cords apart The endotracheal tube does not solve all the problems, however When thiopental is used alone or in combination with nitrous oxide and a muscle relaxant, the bronchial reflexes are obtunded Thus the laryngeal spasm is avoided but bronchial spasm still can develop In addition to the laryngeal and bronchial spasm, a hypotension and bradycardia are a part of the picture The hypotension is characterized by a fall in systolic blood pressure a fairly well maintained or slightly decreased diastolic pressure, a narrowing of the pulse pressure, and bradycardia The hypotensive syndrome may occur without the laryngeal spasm It is seen more frequently in upper abdominal surgery during ether anesthesia in patients who are debilitated with a hypovolemia The hypotension usually appears as soon as the peritoneal cavity is opened This may be due to changes in the intra abdominal pressure

Vagolytic drugs such as atropine and levohyoscyamine intravenously often correct the difficulty The pulse rate increases and the systolic pressure rises after the intravenous use of 0 5 or 0 4 mg of the drug However, if hypovolemia or some disease of the cardiovascular system is present, the reversal by these drugs is only short lived and the blood pressure falls again When the hypotension is due to manipulations in the lower abdomen the sympathomimetic amines appear to be more effective When the blood pressure does not respond to drug therapy one should suspect a hypovolemia, even though there appears to have been no loss of fluid

## VOMITING AND REGURGITATION

Many operating room fatalities result from asphyxia caused by aspiration of gastric contents as a result of vomiting or regurgitation during anesthesia One must differentiate between vomiting and regurgitation The terms are incorrectly often used synonymously The difference between them is important, particularly in respect to prophylaxis Vomiting is an active response requiring voluntary effort Regurgitation is passive and involves no voluntary effort Regurgitation is not necessarily associated with activity of the vomiting center It often occurs when the vomiting center has been inactivated by anesthetics The fluid content of the stomach passes along the esophagus as the cardiac sphincter relaxes, when the stomach and intestines are manipulated during operation, or from effects of gravity when the patient is tilted Such regurgitation is often massive, occurs silently, and without warning Regurgitation may occur during light or deep anesthesia The anesthetist is often unable to prevent it Aspiration into the trachea results unless the patient is intubated with a cuffed endotracheal tube Vomiting usually occurs when anesthesia is lightened inadvertently or deliberately from the third to the second stage The vomiting center is depressed by anesthetics Therefore, a patient in surgical anesthesia cannot vomit and will not vomit if anesthesia is maintained at a constant level

Stimuli that may cause vomiting are relayed to the medulla from many areas of the body Therefore, vomiting and aspiration may occur in conscious patients undergoing surgery with spinal or local anesthesia Some physicians erroneously assume that a conscious patient cannot aspirate because the pharyngeal and laryngeal reflexes are active The patient being operated upon is in the supine position restrained, often has obtunded reflexes and often cannot lift his head to prevent aspiration The writer has seen this occur This catastrophe is most apt to occur during operations for intestinal or pyloric obstruction with retention No type of anesthesia assures immunity from this catastrophe Acutely ill, semicomatose so-called "toxic" patients have obtunded laryngeal and tracheal reflexes They easily aspirate, whether or not they are under

the influence of a general anesthetic The patient with a full stomach invariably attempts to vomit when anesthesia is induced irrespective of the type of anesthetic used The wisest course to follow in managing such patients is to defer operation whenever possible No rule of thumb can be applied in regard to the number of hours one must wait for the stomach to empty Such measures as using emetics or gastric lavage are rarely effective in completely evacuating the stomach In the event an operation cannot be deferred and general anesthesia is necessary one should employ a technique that allows a rapid induction and the use of a cuffed endotracheal tube Cyclopropane or thiopental with a muscle relaxant to facilitate rapid intubation is best suited for the purpose Ether or other drugs may be added later if necessary

Regurgitation and aspiration into the trachea may occur silently and unknown to the anesthetist This has been demonstrated by introducing dyes into the stomach preoperatively and identifying them in the gastric contents in the pharynx and the trachea at the conclusion of anesthesia Some of the factors favoring silent regurgitation are as follows (1) Difficult or prolonged inductions (2) The presence of the stomach tube Perhaps the stomach tube prevents snug application of the face piece and anesthesia may be technically more difficult because of the leak that develops at the mask (3) The head up position Patients in the head up supine position aspirate more frequently than those in the head down The supine head down position is always preferred when vomiting is anticipated

## ENDOTRACHEAL INTUBATION

No refinement in modern medicine has added as much to the safety of anesthesia as has endotracheal intubation Intubation is not absolutely mandatory for abdominal surgery but it does much toward providing safe anesthesia and ideal operation conditions There are a number of reasons why the endotracheal tube is desirable (1) As has been mentioned, one important function of the endotracheal catheter is to prevent laryngeal spasm When the peritoneum is opened and traction is made upon the viscera or in pelvic structures laryngeal spasm results (2) An endotracheal catheter properly introduced prevents aspiration of vomitus or regurgitated gastric contents (3) Obese individuals and others in whom the airway is difficult to control can only be safely anesthetized with an endotracheal tube in place The tube may be introduced with topical anesthesia with the patient awake (4) The tube is mandatory when muscle relaxants are used continuously throughout the operation (5) It is also mandatory when controlled or assisted respiration is necessary

## CONTROLLED RESPIRATION

It is common practice deliberately to induce an apnea and maintain respiration artificially during general anesthesia This is desirable during abdominal surgery because it facilitates the procedure by providing a quiet abdomen The anesthetist inflates the lungs by rhythmically and intermittently compressing the breathing bag of the apparatus Expiration is passive This procedure is called controlled respiration Endotracheal intubation is necessary safely and adequately to execute controlled respiration The apnea is induced by using a drug that depresses the respiratory center usually a nonvolatile drug such as morphine or meperidine in combination with cyclopropane The overdistention of the alveoli by the pulmonary inflation excites the Hering Breuer reflex which inhibits inspiration In addition a hypocapnia develops from the manual ventilation that is an additional factor to the development of the apnea The apnea is difficult to produce with ether Some anesthetists produce apnea by curarizing the patient and causing total muscle paralysis

The effect of increased pressure on the airway for long periods leads to a reduction in cardiac output by interfering with

the venous return to the heart Patients whose circulatory status is within normal limits withstand intermittent positive pressure breathing much better than those who have cardiovascular disease In turn patients who are chronically ill and who have a decreased blood volume dehydration or anemia may develop hypotension and cardiac failure as a result of prolonged controlled respiration particularly if it is done in a hit or miss fashion

## PREMEDICATION

There is no single best way to premedicate a preoperative patient Preanesthetic medication techniques are a matter of individual preference Actually premedication is part of the anesthetic procedure and should therefore be selected by the anesthetist Anything more than a general discussion of basic concepts of the subject would be superfluous The purpose of premedication is fourfold (1) To obtain psychic sedation (2) to obtain an additive effect with the weak impotent anesthetics such as nitrous oxide (3) to minimize secretions and (4) for prophylaxis to counteract undesirable side effects of the anesthetic such as vagal stimulation increase in cardiac irritability and so on

As a general routine the writer prefers a narcotic such as morphine (10 mg ) or meperidine (75 to 100 mg ) in combination with scopolamine (0 4 mg ) intravenously one hour prior to anesthesia The narcotic together with the scopolamine relieves anxiety and produces amnesia In addition an additive effect is obtained that reinforces the less potent drugs The scopolamine has an anticholinergic effect that reduces secretions Some anesthetists prefer basal narcosis with intravenous barbiturates instead of narcotics The writer finds narcotics superior when inhalational anesthetics are used The induction and maintenance of anesthesia are smoother Narcotics and barbiturates combined with phenthiazine tranquilizers such as chlorpromazine are often recommended There is a certain hazard involved in using this combination because the phenthiazine ataractics are sympatholytic and often cause a difficult to reverse hypotension as soon as or shortly after anesthesia is commenced. Patients should be given secobarbital 100 mg or pentobarbital 100 mg for night time hypnosis the evening before operation

## ANESTHESIA IN INFANTS AND CHILDREN

Basically the problems of anesthesia for abdominal surgery in infants and children are similar to those of the adult The requirements for relaxation and the difficulties owing to reflex activity are the same Anesthesia for all types of surgery is more difficult and hazardous in children The size of the infant and the differences in physiology from that of the adult make anesthesia more complex. Infants and children are unable to withstand even brief periods of anoxia or carbon dioxide excess Fluid and electrolyte disturbances that accompany surgical diseases of children complicate problems of anesthesia still more

Regional anesthesia is usually unsatisfactory in infants and small children because they are psychically unsuited for it. Various block procedures are difficult to induce in children since the landmarks are not as discernible as they are in adults. General anesthesia therefore is usually selected Ether and cyclopropane are the drugs of choice Endotracheal intubation obviates reflex spasm and assures an adequate airway Larger children are managed like adults depending upon their size psychic make up and ability to cooperate Above the age of twelve most of the problems are managed as they would be in the adult

## SPECIAL PROBLEMS

The basic principles mentioned in the foregoing paragraphs apply to all the phases of abdominal surgery There are

however, special features of surgery of certain of the organic systems that merit some detailed discussion

## Surgery of the Biliary Tract

Patients undergoing biliary tract surgery are frequently middle-aged, obese, short in stature, with short necks and thick abdominal walls Hypertension, diabetes, or other degenerative diseases are often present If the disease is inflammatory, fever, leukocytosis, dehydration and jaundice may be present The abdomen may be rigid Adequate exposure is difficult to obtain, therefore complete muscular relaxation is necessary Adhesions may be present, which makes the operation difficult and adds to the operating time Cholecystograms may be required during operation The x-ray apparatus precludes the use of flammable anesthetics Traction on the mesenteries and other biliary tract structures initiates reflex activity

Many surgeons demand spinal anesthesia for upper abdominal surgery because it affords excellent relaxation Traction upon the upper abdominal structures causes pain impulses to pass in a retrograde manner along the sympathetic chains into the cord above the area of blockade The patient experiences pain in the shoulder, the neck, or the chest. This discomfort is difficult to eliminate unless the spinal anesthetic is supplemented with some form of general anesthesia These manipulations also initiate nausea and vomiting, which hamper the surgeon considerably Other objections are listed under spinal anesthesia in the beginning of the chapter

For good risk patients, cyclopropane intratracheally combined with a muscle relaxant is a good choice A basal of thiopental may be used for induction Ether may be added if necessary Should cyclopropane be contraindicated, ether intratracheally preceded by nitrous oxide may be used Muscle relaxants may be added as needed The triple combination of nitrous oxide, thiopental, and a muscle relaxant is suggested as a third choice

Endotracheal intubation is necessary for biliary tract surgery, not only to provide a patent airway but to prevent the jerky, spasmodic respiration caused by traction reflexes Field block or intercostal block combined with light cyclopropane or nitrous oxide anesthesia is used for surgery for poor risk subjects Field blocks supplemented with a splanchnic block to obtund visceral pain and reflexes may also be used Some surgeons prefer infiltration instead of blocks When employed by skillful, gentle operators such a choice may be justified but in the hands of unskilled operators the trauma inflicted is great

Chronically ill, jaundiced, emaciated patients undergoing surgery for cholecystogastrostomy and similar palliative procedures are unable to withstand prolonged, formidable surgery or deep anesthesia Light anesthesia using cyclopropane intratracheally is satisfactory If not feasible, field block or intercostal block combined with nitrous oxide, ethylene, or light cyclopropane may be used Nonvolatile drugs such as thiopental, the narcotics, and muscle relaxants should be used sparingly or not at all, particularly if the jaundice has been long standing

## Gastric Surgery

The status of patients undergoing gastric surgery varies considerably Many are chronically ill and poorly nourished with anemia, low serum proteins vitamin deficiences, electrolyte imbalance weight loss, and gastric retention Preoperative administration of blood, proteins, electrolytes, and so on is an important part of the preparation of such patients

Traction reflexes are a problem also Retention may be present, particularly if the pylorus is obstructed A stomach tube is usually necessary Some anesthetists after evacuating the stomach remove the tube, before commencing anesthesia, to simplify induction and maintenance and to reduce the possibility of aspiration Operating time is an important consideration, particularly when regional anesthesia is used The problems and choice of anesthesia are

similar to those outlined for surgery of the biliary tract

Patients undergoing gastrectomy for hemorrhage usually are or have been in shock The selection of anesthesia does not differ from that for other gastric surgery if the blood pressure is stabilized and deficiencies in blood volume have been corrected Cyclopropane or ether intratracheally with a muscle relaxant is the most satisfactory choice Light cyclopropane anesthesia combined with field blocks may be used to perform surgery in poor risk exsanguinated patients The use of spinal or deep ether anesthesia or the combination of a muscle relaxant and thiopental is not advised when prolonged bleeding has been a factor Local anesthesia may be used for extremely poor risk patients

## Gastrostomy

Gastrostomy is usually perfomed when obstruction is present Such patients may be dehydrated emaciated and have nutritional deficiences When the obstruction is acute and the physical status is good anesthesia is managed in the same manner as that for other operations of the upper abdomen The possibility of aspiration of regurgitated stomach contents must be borne in mind Intratracheal cyclopropane ether, or the combination of nitrous oxide thiopental and succinyl choline may all be used In emaciated sickly poor risk patients local anesthesia or field block is preferred

## Gastroenterostomy

Anesthesia for gastroenterostomy is managed in the same manner as that for other gastric operations If pyloric obstruction is present precautions against aspiration are necessary The patient may be emaciated dehydrated and show other signs of nutritional deficiencies When the condition of the patient is good the choices are similar to those outlined for gastrectomy and biliary tract surgery Field block or intercostal block combined with nitrous oxide or light cyclopropane anesthesia may be used for poor risk patients Light cyclopropane anesthesia with infiltration of the rectus muscle with 1 per cent procaine is also preferred by some surgeons This combination works admirably Muscle relaxants are best avoided in poor risk subjects undergoing upper abdominal surgery

## Vagotomy

Vagotomy may be performed with the type of anesthesia recommended for gastrectomy The principles are identical and the same contraindications apply

## Esophagogastrectomy

The management of anesthesia for esophagogastrectomy depends upon the surgical approach The transthoracic approach followed by the abdominal approach may be used or the abdominal sometimes is followed by the thoracic approach Endotracheal cyclopropane or cyclopropane ether is the usual choice if the thoracic approach is used If cyclopropane is contraindicated ether intratracheally preceded by nitrous oxide may be used Muscle relaxants may be used to obtain adequate relaxation Nitrous oxide combined with a basal of thiopental and a muscle relaxant is selected if a cautery is used Endotracheal intubation is necessary because positive pressure and assisted or controlled respiration are required for the open chest

## Perforated Viscus

The patient with a perforated viscus is without exception acutely ill Often such patients are in shock in extreme pain dehydrated or comatose The abdomen is usually rigid and boardlike Overcoming the boardlike rigidity is not a simple matter Surgeons ask for spinal anesthesia because they think in terms of the relaxation it affords However, spinal anesthesia is not a good choice in acutely ill patients particularly if they have been in shock Cyclopropane intratracheally or ether combined with a muscle relaxant is

preferable Nitrous oxide with a basal of thiopental is a less desirable choice

### Pancreatic Surgery

Patients with pancreatic disease are usually chronically ill and show signs of anemia, emaciation, and cachexia as a result of digestive disturbances Jaundice may be present Anesthesia for pancreatic surgery is managed in the same manner as that for biliary surgery and other upper abdominal operations, bearing in mind, of course, that such procedures are long and time-consuming The reflex activity, difficulties in obtaining relaxation, and other technical problems of anesthesia are similar to those for gastrectomy and biliary tract surgery

### Splenectomy

Anesthesia for splenectomy is similar to that for biliary tract and gastric surgery Exposure is not easily obtained, therefore extreme relaxation is necessary Splenectomy for traumatic rupture, for blood dyscrasia, for fibrosis may be complicated by shock from hemorrhage Techniques that may be complicated by anoxia or hypotension are not used Spinal anesthesia is objectionable for the same reasons it is objectionable for biliary and gastric surgery Cyclopropane intratracheally combined with a muscle relaxant or ether is the best choice under these circumstances The tendency to bleed in blood dyscrasia concerns both surgeon and anesthetist The anesthetist avoids instrumentation with airways, laryngoscopes, needles, and catheters, otherwise uncontrollable hemorrhage may occur

### Intestinal Operations

The selection of anesthesia for intestinal surgery, whether it be the large or small bowel, is the same as that for gastric and biliary surgery with one exception there is less objection to spinal anesthesia Most intestinal resections, enterostomies and enterotomies may be performed adequately with spinal anesthesia Cyclopropane or ether intratracheally may be used if spinal anesthesia is contraindicated or undesirable A muscle relaxant may be necessary as an adjunct especially with the cyclopropane The combination of nitrous oxide and thiopental with a muscle relaxant may also be used although it is a less desirable choice In poor risk subjects, intercostal or abdominal field block combined with light cyclopropane, ethylene, or nitrous oxide anesthesia may be used

### Intestinal Obstruction

Laparotomy for the relief of acute intestinal obstruction presents difficulties for both the anesthetist and the surgeon, particularly if the obstruction is 'late' The patients are acutely ill, distended, and dehydrated Disturbances of blood electrolytes, shifts in acid base balance, and disturbed renal function are often present Fecal vomiting and shock are common The surgeon is hampered by the distended and dilated loops of bowel The anesthetist is confronted with the problems of regurgitation and aspiration and providing adequate relaxation

For late" obstruction general anesthesia with insertion of a cuffed endotracheal catheter is mandatory The tube may be introduced with the patient awake. If this is not possible, a rapid induction with cyclopropane or thiopental intravenously and a muscle relaxant to facilitate *intubation is the next best choice* The cuff is promptly inflated Ether may be added or a muscle relaxant may be used if the patient is not relaxed Spinal anesthesia should be avoided Patients with increased intra abdominal pressure from any cause do poorly under spinal anesthesia A precipitous hypotension that is difficult to reverse and does not respond to vasopressors may lead to cardiac arrest. In addition, regurgitation and fatal aspiration may occur The use of local or spinal anesthesia does not assure against aspiration, even though the tracheal reflexes are active, because the patient is in the prone position and cannot help himself

Spinal anesthesia may be used for early

intestinal obstruction if the patient is in good condition, and there is no distention, gastric dilatation, or shock This method of anesthesia provides excellent exposure and facilitates exploration However, cyclopropane or ether intratracheally with a muscle relaxant is equally as satisfactory, particularly if the status of the patient is uncertain and the degree of intestinal and gastric dilatation unknown

## Ileostomy and Cecostomy

Relief of obstruction attempted by ileostomy or cecostomy when the patient is too ill to undergo exploratory laparotomy may be performed with local anesthesia For patients in good condition, spinal or inhalation anesthesia techniques described for intestinal surgery may be used

## Colonic Resections

Colectomies in good risk subjects may be performed using spinal or inhalation anesthesia Cyclopropane ether or cyclopropane alone combined with a muscle relaxant may be used Where a cautery is used and general anesthesia is required, the combination of nitrous oxide, thiopental, and a muscle relaxant is the usual choice In poor risk subjects field block or local anesthesia may be used

Combined abdominoperineal resections are, with few exceptions, relatively long procedures usually performed for excision of new growths or scarred areas Most patients are middle-aged or in the older age group Shock and blood loss are common Spinal anesthesia is preferred by most surgeons Dibucaine (Nupercaine) combined with epinephrine by the single injection method may be used to obtain a prolonged block lasting four or five hours Some prefer continuous spinal anesthesia When general anesthesia is selected, cyclopropane with a muscle relaxant or cyclopropane-ether is satisfactory The combination of thiopental, nitrous oxide, and a muscle relaxant is less desirable because large amounts of thiopental are necessary to maintain anesthesia over a long period of time

## Intra-Abdominal Suppuration

Intra-abdominal abscesses may occur anywhere but are usually located in the pelvis or in the subhepatic or subdiaphragmatic area Infections of the genitourinary tract give rise to abscesses in the upper quadrants, appendicitis in the cecal area and perforation of diverticulae in the sigmoid area Perforations of the stomach or gallbladder and rupture of abscesses in the liver from amebae and pyogenic infection give rise to abscesses in the subdiaphragmatic area on either the left or right side Patients who have intra abdominal suppuration are usually acutely ill Signs of sepsis, fever, and leukocytosis are present and such patients are often referred to as toxic Dehydration, electrolyte disturbances, acidosis owing to vomiting, and inability to eat are present Since they are acutely ill these patients cannot undergo formidable surgery or extensive manipulations The usual procedure is exploration for incision and drainage of the abscess Cyclopropane is usually an excellent choice of anesthesia for these patients because it disturbs metabolic processes little if at all also, it is labile and affords adequate relaxation most of the time Ether may be used if cyclopropane is contraindicated Muscle relaxants may be used cautiously as adjuncts to either drug The combination of thiopental, nitrous oxide, and a muscle relaxant is a less desirable choice and contraindicated when the patients are severely ill Marked depression of respiration and slow recovery in the postoperative period seem common in these patients when these drugs are used The use of spinal anesthesia is advised only when the abscesses are in the lower abdomen in the patient who is in fairly good condition Field block and local infiltration may be used in poor risk subjects or in those in whom the abscess is superficial, well localized, and easily accessible

## Lower Abdominal Surgery

Anesthesia for lower abdominal surgery does not differ remarkably from that for upper abdominal surgery except that there

is little or no objection to spinal anesthesia Although relaxation of approximately the same degree is required, it is obtained with greater ease

As in upper abdominal surgery, the physical status of the patient varies with the surgical disease Some patients are in excellent condition Others may have anemia, jaundice, sepsis, and other symptoms or there may be other complicating diseases Traction reflexes also occur during operations in the lower abdomen but they are not as frequent nr as troublesome as in upper abdominal surgery Nausea, vomiting, and regurgitation may occur particularly when dealing with intestinal obstruction, wound disruption, volvulus, peritonitis, or other acute abdominal conditions As in upper abdominal surgery, electrolyte imbalance and other biochemical disturbances may be present, particularly if there has been previous interference with nutrition or protracted vomiting or dehydration

Cyclopropane combined with a muscle relaxant is used to a large extent for surgery of the lower abdomen If cyclopropane is not desired, ether may be used or may be combined with cyclopropane A muscle relaxant is not necessary as a rule owing to the potency of ether A basal narcosis of thiopental may be used prior to the inhalation anesthetic The combination of nitrous oxide, thiopental, and a muscle relaxant is commonly used but is a less desirable choice Whether or not an intratracheal catheter is used depends upon the ease of maintenance of the airway In obese patients its use facilitates anesthesia Spinal anesthesia is ideal for lower abdominal surgery, if the patient is psychically suited for it Field block or intercostal block combined with a splanchnic block may be used for poor risk patients

## Evisceration

Resuturing for dehiscence and evisceration are best done with inhalation anesthesia When the patient is in poor condition, and many are, local anesthesia may be adequate In patients in good condition, cyclopropane combined with a muscle relaxant is suitable Wound disruptions are often complicated by intestinal obstruction The possibility of regurgitation and of aspiration should be considered These patients therefore, should be examined closely and if evidence of intestinal obstruction exists, should be managed in the same manner as those with intestinal obstruction

## Hernia

Hernias are usually inguinal, femoral, or incisional Inasmuch as most hernial sacs usually are extensions of the peritoneal cavity and the sac contains intestines, omentum and other viscera selection and the management of anesthesia are essentially as described for abdominal surgery in which the peritoneal cavity is entered Patients may be in any age group Many are infants and children who have congenital weaknesses that become manifest shortly after birth, others are young or middle-aged who develop or have an aggravation of a hernia owing to trauma from their occupation, and still others are old persons whose tissues have become weakened so that herniations develop A moderate degree of relaxation is required for repair of hernias in the lower abdomen Considerable relaxation is needed for repair of incisional hernia The peritoneal cavity must be entered when incisional, epigastric, or umbilical hernias are repaired Anesthesia for incisional hernia therefore differs in no way from that recommended for upper abdominal surgery

Usually patients develop hernias as a result of their occupation and are males in good physical condition The average duration of operation for inguinal and femoral herniotomies is between one and two hours There is little blood loss or trauma Traction reflexes manifested by laryngeal spasm from tension on the cord or the sac may occur under general anesthesia but are absent during spinal or local anesthesia Spinal anesthesia is ideal for this type of surgery in adults If not desired, cyclopropane combined with a muscle relaxant may be used Ether preceded by nitrous oxide is suitable, also,

if cyclopropane is not desired The combination of thiopental nitrous oxide and a muscle relaxant may be used also Local anesthesia is satisfactory in skilled hands Many operators feel that the distention of the tissues by the local anesthetic solution distorts structures and may contribute to improper repairs and subsequent recurrences Local anesthesia is frequently selected in the older poor risk subjects

The anesthetic management of patients with strangulated hernias differs from that in patients with a simple hernia Local infiltration anesthesia may not give adequate relaxation for reduction of a strangulated viscus and is rarely used Spinal anesthesia gives excellent relaxation but the patient s condition may be impaired by dehydration distension hypovolemia and electrolyte changes so that spinal anesthesia seems less desirable than the inhalation agents discussed in the section on intestinal obstruction Adequate preoperative preparation and systemic support are of prime importance in patients with strangulated hernia as in all others regardless of the type of anesthesia that is used

CHAPTER 4

# POSTOPERATIVE CARE AND COMPLICATIONS IN ABDOMINAL SURGERY

*Alton Ochsner and John B Blalock*

## GENERAL ASPECTS

Postoperative care should begin immediately after completion of the operation when the patient is being readied for transfer from the operative suite to the recovery unit The anesthesiologist should remain in attendance and, in addition to attending to the tracheobronchial toilet and extubation of the patient, if endotracheal anesthetization has been employed, he should be consulted with reference to the patient s condition as well as to the medication, transfusions, and other fluids that were administered during the operation Only by utilizing this assistance in assessing the balance between fluid loss and replacement can appropriate postoperative plans be formulated

The numerous recent medical advances have had a tendency almost to stereotype postoperative care of the average patient Better preoperative evaluation and preparation, safer methods of anesthetization, ready access to almost unlimited amounts of blood and ever increasing numbers of powerful antimicrobial agents against existing and potential infections have permitted steady extension of the surgical horizon with ever-decreasing morbidity and mortality rates

Although it is a tribute to the attainment of such diagnostic and technical proficiency that the probable postoperative course of most patients can be predicted with a high degree of accuracy at the conclusion of an operation, it is imperative that each patient receive individual consideration of each phase of his postoperative care Failure to adhere to this precept would subject some patients to unnecessary treatment on the one hand, and some to preventable complications on the other

In most patients the period immediately after operation is the most critical in the entire postoperative course In those who have been anesthetized for periods up to several hours, the anatomic relations may have been considerably altered and all vital processes have been maintained at variable degrees of efficiency under artificial conditions Medications having a wide variety of usually depressing effects on the various organ systems and fluids equal to or in excess of the patient's normal circulating blood volume may have been administered In this state of altered physiology of virtually every organ system the patient

enters the postoperative period During this critical time he must be kept in a recovery room where all resuscitative measures are readily available and where he will be under constant surveillance of competent, specially trained attendants Frequent determination of blood pressure, pulse rate and respiratory rate serves as a monitor of the most vital processes and any significant alteration in the patient s condition will usually be promptly indicated by a change in one of these The general appreciation of the critical nature of the recovery period' has led to widespread institution of facilities for specialized care of these patients during this period

## Postoperative Orders

It is well to restate any previous orders still in effect when additional orders are written This obviates the real possibility of duplication of medication and other treatment Subsequently, orders should be changed only after the patient is examined and his course determined since last seen After abdominal operations patients should be seen at least every twelve hours The practice of ordering fluids removal of suction tubes, and changes in diet and activity many hours before the time the orders are to be executed is hazardous Although one can usually anticipate the needs of a patient for the next morning one cannot be certain that orders that prove to be inappropriate will be intercepted

## Fluids

All patients on whom an abdominal operation is performed with use of a local, general, or lumbar anesthetic should be given sufficient fluids to replace the calculated loss during the preoperative, operative and postoperative periods of restriction of oral intake until normal alimentation can be resumed The duration of functional ileus may vary from twelve to eighteen hours in the simplest cases to days in the more complicated ones and depends largely on the amount of peritoneal trauma The time for resumption of oral intake can usually be determined by evidence of resumption of peristaltic activity as determined by auscultation the passage of flatus, and the highly important criterion of the patient's desires Just as the infant surgical patient indicates his needs and usually his capabilities by resumption of the sucking reflex, so older patients have inclinations toward hunger or anorexia, which are accurate gauges of their ability Small amounts of water and later bland and easily assimilated foods are best tolerated by the alimentary tract that has been subjected to an operation or has been lying idle as a consequence of an operation on adjacent structures Some parenteral supplemental intake may be necessary during the first one or two days of oral feeding

## Bowel Elimination

The process of bowel elimination is interrupted as a result of the preoperative cleansing the period of fasting and usually further limitation of intake for a few days This is frequently of more concern to the patient than to the surgeon and is of no consequence insofar as convalescence is concerned A simple explanation for the reason for cessation of elimination usually reassures the apprehensive patient The expected absence of bowel elimination for a few days requires no therapy, such as intestinal stimulants, cathartics or enemas in most cases However, the possibility of fecal impaction should be kept in mind and ruled out by rectal examination

## Activity of Patient

The positioning and activities of the patient need be restricted usually only by the limitations imposed by the patient s strength pain the dressing and drainage tubes. Especially during the early days optimum aeration of the lungs as well as assistance in raising tracheobronchial secretions can be facilitated by scheduled changes of position from the back to either side at two- or three hour intervals when

ever practical In all patients with tracheobronchial secretions deep breathing and frequent coughing are enforced Encouragement of ambulation on the first or second postoperative day is desirable for a number of reasons Keeping the period of total disability to a minimum is beneficial to the patient from the standpoint of morale as well as physical welfare Avoidance of the profound sense of weakness attendant upon enforced bed rest of only a few days for any cause is most desirable Maintenance of muscle tone and strength and stimulus to cardiorespiratory activity and venous return from the lower extremities are the more tangible benefits from such activity On more exacting evidence there are sound scientific reasons for the advisability of keeping the period of total disability to a minimum Consistent alterations in protein metabolism and electrolyte balance accompany enforced bed rest

## Medication

The judicious use of analgesics and sedatives is an important part of the postoperative care Pain which is a natural accompaniment of an operation or of complications thereof is not only frightening and demoralizing to the patient but if uncontrolled can have more tangible deleterious effects Tachycardia intestinal ileus and restriction of respiration as well as general body movement favor deterioration and exhaustion of both mental and physical reserve Allaying these deleterious sensations and providing relaxed comfort and short periods of sleep reduce the metabolic demands and maintain the patient s confidence and stamina Additional specific medications such as digitalis or insulin for cardiac or diabetic patients should be provided as indicated

## Urination

Attention to the function of the urinary bladder should be given early in the postoperative course Under certain circumstances it is desirable to insert a catheter either before or immediately after operation For example ineffectual bladder function might be expected after extensive operations especially in the lower part of the abdomen and pelvis or after operations on the genitourinary tract The need for frequent urine specimens as in patients with diabetes or lower nephron nephrosis is another indication for immediate insertion of a catheter Unless an indwelling catheter is otherwise indicated urination may be facilitated by having the patient sit or stand When however the patient is not able to void catheterization should not be delayed because of the danger of overdistention of the bladder If retention recurs or it is first detected after the bladder has been greatly distended an indwelling Foley catheter should be employed for at least 72 hours Such overstretching sprains the bladder musculature and an adequate period of absolute rest of the bladder is the most certain and quickest way to restore normal function Because of the high incidence of bacilluria and often actual clinical infection associated with urinary indwelling catheter drainage administration of a highly soluble sulfonamide is desirable for three days after such drainage of the urinary tract

## Gastrointestinal Decompression

Preoperative decompression of the gastrointestinal tract can usually be assured by abstinence of intake for ten to twelve hours This obviates the need for preoperative suction tubes except in cases of obstruction of the gastrointestinal tract If the gastric tube is introduced after induction of anesthesia the patient is spared this added ordeal A collapsed stomach and upper intestinal tract during operation are especially desirable in upper abdominal surgery to minimize the possibility of regurgitation and aspiration and thereby insure safer anesthetization

Postoperative gastrointestinal suction requires individual consideration Because a period of intestinal dysfunction (functional ileus) follows almost any abdominal

operation, insertion of an indwelling gastric tube through one naris for continuous gastric suction is indicated in all patients undergoing laparotomy except the simplest, such as appendectomy Also, in all operations requiring gastro enteric anastomosis continuous gastric suction is indicated An indwelling gastric suction tube passed through the nose is usually well tolerated for two or three days, after which nasal and pharyngeal irritation and sinusitis may occur Only when the tube must be left in for many days do the more formidable complications of laryngeal irritation and esophagitis deserve serious consideration

A variety of additional methods of intubation may be used in particular circumstances Any one of the several long intestinal tubes utilizing the distal balloon may be introduced before or during operation through the nose or through a gastric stoma to insure intestinal patency or to minimize the space within the abdomen that is being occupied by the small intestine The entire small intestine may be fluted on a few feet of tube and placed in one fourth of the abdomen This greatly facilitates exposure during operation and reduces the space required to accommodate the intestines postoperatively Need for the rectal tube should be determined on the basis of abdominal and rectal examination

### Antibiotics

The antibiotics are of great value in preventing potential infection and controlling existing infection The ease and economy with which they can be used and their low incidence of inherent ill effects have resulted in their frequent and indeed sometimes indiscriminate use postoperatively Surely any patient in whom infection is anticipated should receive appropriate antibiotics However if infection is not anticipated antibiotics are not indicated Of immediate concern is the possible development of sensitivity so that if use of the antibiotic is continued or if it is given subsequently, mild to severe allergic manifestations occur Of equal although more remote importance is the possibility that the microorganisms will become resistant to the antibiotic This may be of no immediate consequence but it may lead to a serious, overwhelming infection From the beginning it was evident that emergence of drug resistant strains of organisms would be the inevitable developments of antibiotic therapy Such strains are much in evidence already with reference to the early antibiotics penicillin and streptomycin and there is every reason to believe that similar resistance will develop to other antibiotics Fortunately there seems to be a virtually inexhaustible potential for the development of new antibiotics

## FLUIDS AND ELECTROLYTES

The remarkable facilities for homeostasis are seldom exhibited more convincingly than in the economy of body fluid and electrolytes in the postoperative patient Through this intricate interplay of complex mechanisms such fluid and electrolytes as are available are utilized to the greatest possible advantage However the inevitable insensible loss and mandatory sensible loss largely in the form of urine to act as the vehicle for elimination of metabolites, limit the period to two or three days during which time this self regulatory mechanism can operate before there is a deleterious effect on the organism In the average patient equilibrium of fluids and electrolytes can be restored promptly by parenteral administration of simple carbohydrate-containing solutions such as glucose or invert sugar in water saline or Ringer s solution

If this early period is prolonged because resumption of normal alimentation is delayed or the excretory mechanism becomes defective or both treatment is not as simple The normal body processes are curtailed in accordance with the total body economy of the alarm state Even so the various organ systems must continue functioning and the materials to support this function must be supplied

The aim of postoperative fluid and electrolyte therapy is to prevent or minimize depletion of body stores and even body tissues by supplementing the needed materials Such supportive therapy is given on the basis of careful clinical evaluation and expected requirements

Numerous laboratory tests are used but too frequently they indicate the temporary value in constantly changing chemicometabolic processes and only by correlating all laboratory data with the clinical manifestations can the true status of the patient be ascertained It must be realized that the oft-quoted "normal values of sensible and insensible water loss and electrolyte blood levels are found in *normal* individuals However, the postoperative patient is not normal and it is unreasonable to expect his fluid and electrolyte behavior to be entirely normal Effective and, of course, only partially understood mechanisms function to keep the imposed degree of abnormality in a range consistent with at first, survival, and then convalescence and restoration to a normal state The compulsion to treat patients until the results of laboratory tests become normal, that is, "treating the chart" rather than the patient, should be avoided As a general rule, it is far safer to undertreat with regard to fluid and electrolytes than to overtreat Seldom will a patient be allowed to reach a dangerous state of dehydration whereas the danger of overhydration in real, especially in children and old people and in those with impaired excretory systems

The status of renal function is of utmost importance If function is normal, the margin of safety in fluid and electrolyte therapy is wide Excesses of fluid are excreted and compensation for deficiency may be brought about by conservation of the fluid that is available In like manner, with the exception of potassium, the kidneys are able to excrete or retain electrolytes to the best advantage of the individual By reason of this remarkable balancing effect exerted by the kidneys a fairly wide range of safety is maintained

Orders for postoperative fluid therapy are written on the basis of the estimated deficit that has occurred up until conclusion of the operation and the anticipated need for the first arbitrary period usually until the next morning For consistency it is best to formulate such orders at the same time each day and in most institutions this is done in the morning The patient can be examined, and the record of the intake and output during the previous twenty-four hours considered, together with the available laboratory results that relate to this part of his care Further, it is presumed that the patient had the best possible fluid and electrolyte balance before operation Establishment of the individual's response to operation as an example of the alarm reaction has served to clarify many heretofore poorly understood alterations in the postoperative period The requirements for fluid and electrolytes are so closely related that it is usually practical to consider them together

Estimation of the daily requirements for the patient under normal conditions serves as a starting point in formulating orders As a result of the conservation of fluid and of most electrolytes in the immediate postoperative period, the figures for the sensible and insensible fluid loss and the electrolyte loss except for potassium as based on healthy normal individuals are usually higher than those needed by most postoperative patients Allowance must be made for fever and losses from drainage from the gastrointestinal and biliary tracts and peritoneal cavity or from large wounds The expected water and sodium retention and potassium excretion during the immediate postoperative period in response to adrenocortical activity and the increase in the antidiuretic hormone should influence fluid and electrolyte administration Although this response is short lived (from two to three days as a rule) and is self-limiting, there is convincing evidence that the volume and total ionic content of the extracellular space are increased at the expense of the intracellular compartment and an improper amount in the ionic content of administrated fluid can easily cause

further, perhaps dangerous enlargement of this space In most patients this period of two or three days can be handled by judicious use of simple solutions of dextrose or invert sugar in water supplemented with vitamins The slight potassium loss is of no consequence for this short time unless it is augmented by excessive losses, as in copious gastrointestinal drainage It is far easier to combat fluid and electrolyte imbalance prophylactically with small safe quantities of each than to restore reasonably normal values in a patient in whom electrolyte imbalance has developed Consequently, solutions containing appropriate amounts of sodium chloride, potassium, and calcium should be given early Urine volume is the most valuable single index of the fluid requirement, provided renal function is reasonably good In reality, water for formation of urine is made available after the other priorities have been met and, therefore, a 24-hour urine volume of 800 to 1,000 ml will usually indicate adequate hydration Adequate renal function is possible with a urine volume of 500 ml, and indeed, the kidneys require excretion of this much fluid even in the face of moderately severe dehydration

If renal function is altered, the margin of safety is sharply reduced In such cases strict attention must be given to both the quantity and quality of fluid administered, since the kidneys are incapable of normal excretory function It is imperative that such cases be recognized early Failure to do so and the false impression that the reduction of renal function is due to dehydration are grave errors

Attempts to initiate or stimulate renal function by supplying increased amounts of fluid and electrolytes lead to waterlogging of the patient and the attendant hazard of water and electrolyte excesses In such cases fluid therapy should be reevaluated because these patients have an expanded extracellular space and in some instances a 'third fluid compartment' from which fluid eventually will be mobilized by recalling the compartment into the available circulating extracellular space Experience has taught that incomplete hydration is necessary until urinary formation is resumed

In the meantime, and this usually extends into periods of eight or ten days, fluid therapy must not be calculated on estimated 24 hour sensible plus insensible loss for a normal patient, as this will invariably prove to be too much Rather the volume should range from 200 to 300 ml plus equivalent amounts of previous 24 hour urinary output and other sensible loss A catheter should be placed in the bladder in order to recover all urine formed Maximum amounts of glucose or invert sugar for protein sparing effect, vitamins, and such antibiotics as may be indicated should be given Oral administration of fluid is usually inadvisable, as utilization is uncertain Such patients will be benefited by passage of catheters into the inferior vena cava via the greater saphenous vein at the groin or into the subclavian or innominate vein by way of the cephalic vein at the anterior aspect of the shoulder Because these catheters empty into a large venous stream, they can be used for administration of small volumes of concentrated solutions (including 50 per cent glucose) with virtually no discomfort to the patient and with negligible danger of chemical phlebosclerosis Such a catheter large enough to accommodate a No 17 or No 15 needle can also be used to obtain blood samples for chemical determinations Frequent determinations of hemoglobin hematocrit blood urea nitrogen, serum chloride, $CO_2$ combining power, and sodium and potassium concentrations are valuable indications of the efficiency of homeostasis in the absence of renal function as well as the need for auxiliary measures to reduce potassium concentration These include gastric, small intestinal or peritoneal lavage, or if facilities are available, use of an artificial kidney Such urine as is formed can be analyzed for electrolyte content for evidence of returning renal function Electrocardiographic evidence of impending or existing hyperkalemia is of help in this condition The fluid that is given should be high in carbo-

hydrate content for its caloric value and its protein sparing effect and because significant amounts of potassium are utilized in its metabolism

With resumption of renal function, which at first is imperfect, great care must be exercised in the maintenance of fluid and electrolyte balance Once renal function of significant degree is resumed (after eight to ten days of oliguria), excessively large amounts of dilute urine are excreted for the first two to three days During this phase of polyuria large amounts of water and adequate amounts of electrolytes must be supplemented to avert deficiencies Thereafter gradual return to fairly normal volume and constituents of urine occurs

Practically all patients who have had an abdominal operation have functional inactivity of the gastrointestinal tract (adynamic ileus), which persists for varying periods of time according to the extent of peritoneal trauma Fluids and electrolytes lost by vomiting, aspiration of gastric contents, diarrhea, or peritoneal exudation require replacement If complications such as continued peritoneal irritation resulting from peritonitis occur, fluid and electrolyte replacement becomes more complicated Losses through the intestinal tract require replacement with appropriate amounts of properly balanced electrolyte solutions according to the ionic concentration and type of fluid lost Gastric losses are best replaced by 0 45 per cent to 0 9 per cent solutions of sodium chloride Significant losses from drainage of the small intestines and biliary tract result in depletion of basic ions, which are prominent constituents of such drainage Moderate losses for brief periods usually respond favorably to administration of equal volumes of infusions containing normal saline or Ringer's solution Copious or prolonged drainage necessitates use of parenteral fluids containing higher concentrations of basic ions, such as a 3 per cent solution of sodium chloride, Ringer s solution fortified with potassium chloride up to 50 mEq /L , or 1/6 M sodium lactate solution Maximum amounts of carbohydrates should fortify whatever fluids are given to increase the caloric intake and spare utilization of body stores and tissues insofar as possible Metabolism of body protein can be curtailed somewhat, positive nitrogen balance restored, and to some extent proteins formed by parenteral administration of amino acid preparations The parenteral administration of the third basic dietary constituent, fat, is being developed but has not yet been sufficiently perfected to justify uncontrolled usage

## BLOOD TRANSFUSION

Whole blood transfusions should be given postoperatively if anemia develops because reparative processes occur optimally only when hemoglobin values are nearly normal An additional benefit of blood transfusion therapy is that it provides a source of the multiple protein factors necessary for optimum antibody formation The probable benefits of blood transfusion must be weighed against the possible ill effects and it is likely that there is seldom indication for one bottle of blood' In properly conducted laboratories the danger of incompatibility should be so slight that it can be disregarded Incompatability because of subgroups not determined by standard cross-matching based on the four major groups and the Rh grouping are rare and of minimal consequence

The danger of transmission of disease by transfusion has become of negligible importance with the notable exception of viral hepatitis In spite of the best screening methods available to eliminate infected donors, this ailment continues to plague any service on which a significant number of transfusions is performed It accounts for the greatest number of transfusion complications, which is sufficient reason for not using transfusions unless really indicated In addition to a significant mortality rate, those who survive viral hepatitis are sick for several weeks to several months, and many suffer significant loss of hepatic function Symptoms and signs of hepatitis usually appear

one and a half to three months after the inoculation but in rare cases (probably related to the concentration of the inoculation) may occur as early as three to four weeks or as late as six months Such a complication in a patient who has otherwise recuperated from his illness is indeed discouraging In addition the predominant symptoms of nausea anorexia and malaise and the rigid therapeutic restriction are even worse

The diagnosis is suspected from a history of transfusion or in occasional cases of parenteral injection of fluids or medications As an epidemiologic control measure every effort should be made to identify the responsible donor or the source of inoculation Results of hepatic function tests are unfortunately inconsistent and not entirely reliable although in general they are consistent with hepatocellular damage Of especial value in these patients is the recently developed test of transaminase one of the most reliable tests in determining hepatocellular function The utmost caution should be exercised to prevent reoperation in these patients for possible obstruction of the biliary tract Such a diagnosis is especially likely to be considered if the original operation was related to the liver biliary tract or pancreas To subject these patients to an exploratory operation is to court disaster because of their poor tolerance to anesthetization and operative trauma In doubtful cases the diagnosis of hepatitis can usually be made by percutaneous liver biopsy with the Vim Silverman needle If doubt still exists and unless there is likelihood of extrahepatic obstruction that can be relieved there is usually more to be gained by a period of medical therapy than by immediate operation

Treatment of serum hepatitis consists in rigid restriction of physical activity and a high caloric high carbohydrate high protein diet with sufficient fat to make the diet palatable and with vitamin supplements In the more intractable cases cortisone therapy is of decided value Lacking any effective method of eliminating carrier donors or of rendering contaminated blood innoxious homologous serum jaundice constitutes the greatest single risk of transfusion therapy at the present time

Pooled plasma is inferior to whole blood because of the lack of the formed elements that is erythrocytes leukocytes and platelets The last two constituents however are relatively short lived in transfused blood except under exacting conditions Plasma is also inferior to blood because of its lack of oxygen carrying capacity and because hemoglobin is important in the reparative process and provides an additional source of proteins On the other hand plasma is the nearly perfect substitute for extracellular fluid It can be preserved indefinitely and there is no possibility of incompatibility However because fresh pooled plasma is even more hazardous as regards viral contamination than whole blood it is imperative that plasma not be used until it has been stored at room temperature for at least six months The reason for this is that as demonstrated by Allen and associates the contaminating virus which remains viable indefinitely when kept cold or even frozen dies within this time at room temperature

Serum albumin is an additional available blood constituent which is particularly desirable in albumin deficiency but its cost at present prohibits its use in large amounts Additional blood substitutes are plasma expanders which are available for emergency use to provide a medium with an osmotic pressure range that is similar to that of blood plasma Most of these agents are relatively innocuous inert compounds of large molecular size this accounts for their ability to expand the circulating blood volume temporarily They are of inestimable value in acute blood volume deficiencies but there are few indications for their use postoperatively

## POSTOPERATIVE COMPLICATIONS

In spite of the increase in the magnitude of surgical procedures there has

been a significant decrease in the incidence of postoperative complications with corresponding reduction in morbidity and mortality rates Supportive therapy, by rendering a patient a safer surgical risk, decreases the incidence of complications Most complications during and after operation can be prevented Numerous maneuvers during the operation, such as insertion of drains, peritoneal toilet, or employment of gastric suction tubes, are specific preventive measures against postoperative complications The surgeon must be alert to the possible development of postoperative complications so that he may recognize these as soon as they occur In no phase of surgery is more critical judgment needed than in the early recognition and treatment of postoperative complications The patient who was ill preoperatively and has been subjected to the trauma and stress of an operative procedure is less able to withstand a complication than an otherwise well person The diagnosis and treatment may be obvious, as in the case of wound dehiscence, or it may tax one's ingenuity, as in cases of postoperative acute cholecystitis, intraperitoneal abscess, shock, electrolyte imbalance, or paralytic and mechanical ileus

## Postoperative Hemorrhage

Until recent years postoperative bleeding was generally attributed to a technical fault in hemostasis, but it is now evident that many cases of bleeding from operative wounds are due to a disturbance in the clotting mechanism However, the more tangible causes for bleeding, such as incomplete hemostasis or slipping of a ligature, must be considered first, as surgical correction is promptly curative It is dangerous to assume that postoperative bleeding is due to a defective coagulating mechanism, and unless such a cause is strongly probable, exploration of the operative area is indicated In patients having elective surgical procedures who have had proper preoperative evaluation, postoperative bleeding should rarely be due to a pre existing bleeding tendency, such as hemophilia, thrombocytopenia, hepatic disease, or anticoagulant therapy On the other hand, such causes must be considered in patients who have had emergency surgical procedures Search should be made in the history for evidence of abnormal bleeding tendency after previous operations, injuries, or dental extractions Also, physical examination of the bleeding patient postoperatively should include a search for evidence of bleeding from sites remote from the wound, such as from vena puncture or mucous membranes

Many cases of postoperative bleeding prove to be due to abnormalities of hepatic function, massive replacement of blood, or both Less common causes are incompatibility of blood, certain plasma expanders, and existence of certain inhibitory or fibrinolytic properties in the blood

It has long been realized that the liver is intimately involved in the process of coagulation This was first evidenced by the hemorrhagic tendency shown by patients with hepatic disease, and eventually substantiated by identification of specific deficiencies in substances involved in the clotting mechanism in such patients It now seems evident that not only established pre-existing hepatic disease but impairment of the hepatic function of a previously normal person, in response to surgical trauma and anesthetization, may be sufficient to initiate or perpetuate bleeding by disturbance of the production of prothrombin or fibrinogen An imbalance between the less well understood accelerators and inhibitors may be at fault

Patients receiving multiple blood transfusions during and after operation are the other large group of postoperative patients likely to have defective coagulating mechanisms Hepatic injury incident to the underlying cause that necessitated massive replacement of blood, such as shock or hepatic anoxia, may likewise contribute to the general defect in these patients The deleterious effect of a large amount of citrate on a normal liver seems

unlikely but it has recently been shown that the impaired liver can be further injured after large amounts of citrated blood have been given The patient who is given as much as or even more than his blood volume may have a deficiency of fibrinogen of circulating platelets, and of the labile accelerator factor for the conversion of prothrombin to thrombin, which are the major deficiencies of stored blood preserved in citrate solution Naturally, the greater the volume of transfused blood and the more rapidly it is given, the more dilute will the patient's own blood become and the more significant will the deficiencies of the transfused blood become

Platelet deficiency, precipitated by incompatible blood transfusions or large amounts of large molecular plasma expanders and hypofibrinogenemia owing to fibrinolysins, make up the remainder of the better understood mechanisms of postoperative bleeding Hypofibrinogenemia is characterized by depletion of fibrinogen or fibrin by either impaired production or a lytic process arising in the blood of certain patients The latter is most likely to occur in patients who have had massive replacement of blood necessitated by pulmonary, pancreatic, or pelvic operations or for metastatic carcinoma of the prostate, hepatic disease, or shock Because of the complexity of diagnosis and treatment of such conditions, the aid of a hematologist should be obtained if one is available

By a logical approach to problems of postoperative hemorrhage owing to defective coagulability of the blood, it is usually possible to determine the likely cause and thereby employ specific corrective measures Evidence of a bleeding tendency in areas remote from the operative wound are, of course, strongly suggestive of such a defect Determination of platelet count bleeding and clotting time, clot retraction and possible clot lysis, and prothrombin time may indicate the nature of the defect Such studies should be done early but it is often necessary to begin therapy before the results of such studies are obtained As a rule the problem is most quickly and certainly solved by administration of transfusions of fresh whole blood collected in containers designed to preserve platelets, such as silicone coated bottles or plastic bags Supplemental platelet-rich transfusions and infusions of fibrinogen are highly beneficial when compensating for specific deficiencies With adequate hepatic function, prothrombin deficiencies can be corrected by vitamin K therapy, and when such a deficiency is a consequence of dicoumarol, use of K I oxide insures the most prompt return to normal

## Postoperative Shock

Maintenance of adequate circulation postoperatively is imperative Postoperative shock may be due to a number of causes but the most frequent is inadequate circulating blood volume This deficiency may result from loss from the vascular tree, as in hemorrhage or extravasation from pooling of blood within the vascular bed but outside of the actual circulating stream, in response to neurogenic or humoral mechanisms, or from cardiac failure

Whatever the cause of shock, the clinical picture is usually the same It is characterized by low blood pressure tachycardia, thready pulse, restlessness, and cold dry skin with collapse of the superficial veins and evidence of increased respiratory effort The probable causes of shock must be determined in order to initiate proper treatment

The preoperative status, the course during operation, and the time and mode of onset of the evidence of shock postoperatively should be reappraised Did the patient have evidence of diminished blood volume or of the chronic shock syndrome before operation? Did he receive adequate replacement therapy during operation? Had there been further excessive losses since operation? Was he seriously debilitated or had he had adrenal stimulating or supplemental therapy? Is there a significant infectious element in his illness?

Is it likely that the myocardium is deficient because of pulmonary embolism, toxicity, or disease of the coronary arteries?

## Hypovolemic Shock

The most common cause of postoperative shock is a deficiency in the circulating blood volume as a result of a discrepancy between blood loss and blood replacement This discrepancy may be the result of incorrect evaluation of the blood volume status preoperatively, of the estimate of the blood loss incurred at operation, or of subsequent concealed or obvious bleeding Most patients with a normal preoperative blood volume can tolerate slow losses of 500 to 1,000 ml of blood without signs of shock However, debilitated patients, who frequently have blood volume deficiencies (chronic shock), exhibit frank shock on almost any further diminution of blood volume and require replacement of at least the same amount as they have lost Such blood volume deficiencies should be corrected preoperatively, because, as has been shown these patients do not tolerate trauma well and usually evidence of shock develops during the operation If bleeding is at a sufficiently slow rate to permit restoration of an effective blood volume by migration of fluid from the extracellular and intracellular compartments into the intravascular compartment hypotensive shock does not occur In such cases the characteristic hemodilution effect of supplementing whole blood with fluid is reflected in the lower hemoglobin and hematocrit values The relatively rapid loss that usually precipitates postoperative shock does not allow time for this restoration of blood volume, and hence permits development of shock accompanied by deceptively normal hemoglobin and hematocrit values Failure to realize that these normal values are only from a sample of blood and have little bearing on the total volume of blood is a common source of error in treating postoperative shock Actual estimate of the blood volume may be obtained by means of Evans blue dye (T-1824) or a radioactive tagged constituent of the blood, such as red blood cells or albumin, if measures more accurate than clinical impression are indicated When blood is lost, it should be replaced by whole blood rather than by plasma or plasma expanders except in extenuating circumstances As valuable as these substances are in emergencies, they fall far short as a substitute for needed whole blood

A measure that has regained favor in combating hypotension is the judicious use of vasoconstricting agents to restore and maintain peripheral vascular tone *when shock persists after the blood volume has been sufficiently restored* Such agents are not a substitute for adequate replacement therapy, and one should guard against their misuse in lieu of such therapy Norepinephrine, with its almost specific effect on the peripheral vascular bed, is most effective for this purpose By the drip administration of an infusion containing 4 mg of norepinephrine per 500 ml of physiologic saline solution it is possible literally to titrate the blood pressure back to a satisfactory level and maintain it at that level However, extreme caution must be used in administering this potent vasoconstrictor as the blood pressure may rise to dangerous heights in a matter of minutes The usual maintenance dose of 4 to 8 $\mu g$ per minute can be gradually reduced as the blood pressure returns to normal A significant number of cases of shock that would formerly have proved to be irreversible are now salvaged by proper application of this therapy

## Shock Owing to Adrenal Insufficiency

Postoperative shock owing to adrenal insufficiency occurs often enough to justify consideration of this diagnosis in any case of shock not readily explained by other causes Formerly, such episodes occurred in patients having pituitary disease that affects the adrenal glands or in those with adrenal dysfunction, which is now known to be adrenal exhaustion in certain debilitated patients To this relatively small

proportion must be added the larger number of patients who have induced adrenal suppression from medication and the few who have had surgical or radiologic ablation of the pituitary or adrenal glands Appropriate therapy before, during, and after operation should avert this postoperative complication

Most susceptible persons can be detected by the history and clinical examination Greatest confusion is likely to arise in the group having unsuspected adrenal insufficiency This may be due to a primary destructive process in the adrenals, to adrenal substitution therapy at the time or in recent months that was not disclosed or, in the chronically ill patient, to the inability of the adrenals, which have been functioning maximally, to withstand further stress It should be emphasized that most patients exhibiting signs of shock postoperatively have inadequate circulating blood volume because of inadequate blood replacement, resumption of active bleeding or peripheral vascular collapse not resulting from adrenal insufficiency

Nonetheless, adrenal insufficiency should be considered early, but the more likely causes should be established or discarded promptly, and if response to adequate therapy is not immediately favorable, the possibility of adrenal insufficiency should be investigated Members of the family should be questioned regarding whether the patient has received medication that may have been suppressive to the adrenal glands The sodium concentrations of specimens of serum and urine obtained simultaneously are of diagnostic value Normally, there is great disparity in the serum sodium and urine sodium concentrations A urine sodium concentration approaching or exceeding the serum sodium level is strongly suggestive of renal tubular dysfunction or adrenal insufficiency The former should have been detected in the preoperative examination or, if resulting from an operative or postoperative complication, should be detected by the simpler renal function tests

Failure of response to what should be adequate blood volume restoration and vasoconstricting agents and reasonable evidence that further blood loss is not at fault justify institution of measures to correct adrenal insufficiency in spite of no apparent cause The agents employed are specific when indicated and the dangers attending their judicious use are negligible An effective regimen is immediate intravenous administration of 100 mg of hydrocortisone and an infusion containing additional hydrocortisone and norepinephrine The norepinephrine must be administered by drop in a concentration not in excess of 4 mg per 500 ml of solution The blood pressure must be taken at least every five minutes to insure its maintenance at an adequate but safe range A daily maintenance dose of 5 mg of desoxycorticosterone acetate intramuscularly is usually indicated during the period of cortisone therapy Norepinephrine is given until the blood pressure is maintained at an adequate level without its support and the dosage of cortisone can gradually be decreased When use of cortisone is discontinued, a small stimulating dose of ACTH should be given

## Septic Shock

Peripheral vascular collapse resulting from severe infection, that is, septic shock has recently been re emphasized and deserves special consideration The possibility of this complication should be considered in all patients with severe infection if it is to be recognized early when therapy is effective These patients usually have clinical and laboratory evidence of infection, although the severity may not be appreciated until shock becomes evident This is usually the result of rapid extension of the inflammatory process with bacteremia or absorption of toxins The grave prognosis depends more on the underlying infection than on the shock itself Therapy consists in prompt institution of the usual measures against shock

massive specific antibiotic therapy, and such surgical measures as may be indicated

## Shock on a Cardiac Basis

With an increasing proportion of elderly patients being operated upon, the number of potential postoperative cardiac problems that may be first manifested as hypotension and interpreted as shock is increased The most common types are impaired myocardial function, accompanying auricular fibrillation or other arrhythmias, and coronary insufficiency with or without coronary occlusion They may be associated with reduced cardiac output, lowered blood pressure, and evidences of shock The aging heart subjected to stress, especially if associated with periods of anoxia and hypotension, is vulnerable to the complication thrombosis in an area of atherosclerosis Occurrence of hypotension in an older patient, especially if associated with cardiac arrhythmia demands immediate clinical and electrocardiographic evaluation of the heart In such cases preoperative studies for comparison are invaluable in determining the significance of postoperative findings Treatment must be directed toward the basic cardiac problem, as well as cautious treatment of the shock, so as to minimize the ill effects attending prolonged periods of hypotension

## Carbon Dioxide Poisoning

In the immediate postanesthetic period, especially if cyclopropane has been administered, some patients exhibit a state of hypotension that must be differentiated from true shock Except for the lowered manometric blood pressure, these patients have none of the other indications of abnormal cardiac or respiratory function The process is usually self limiting, resolving as the patient fully reacts from the anesthetic It is attributed to diminution of peripheral vascular tone as the consequence of altered blood pH caused by carbon dioxide retention It subsides promptly upon resumption of normal respiratory physiology and requires no specific therapy in itself

## Pulmonary Complications

The most frequent postoperative complications involving the respiratory system are atelectasis, pneumonia, and pulmonary embolism The less common conditions pulmonary edema and congestive atelectasis, are formidable complications that also deserve consideration The urgency of prophylaxis in regard to a function so vital as that of the respiratory system is obvious

ATELECTASIS This is the most common postoperative pulmonary complication Routine postoperative radiologic examination of the chest often reveals parenchymal shadows in the form of strands or disks of increased density They represent segmental or subsegmental bronchial occlusions and, in most instances, are transient and inconsequential If, however, such areas persist and are converted into foci of bronchopneumonia, or if bronchial occlusion involves the larger bronchi, including a primary bronchus, the complication is serious

The multitudinous factors that predispose to occlusion of the airway and parenchymal compression begin during the anesthetic period, and continue during the first few postoperative days Drugs or anesthetic agents may dry secretions, cause swelling of the bronchial mucosa, or spasm of the bronchial musculature Diminished respiratory excursion or suppression of cough predisposes to atelectasis even before the operation has been completed Other factors are excessive sedation, aspiration, and restriction of excursion of the diaphragm, chest wall, and abdomen because of pain and dressings

Avoidance or minimizing of these factors is important in prevention of atelectasis and in its treatment once it has occurred Bronchorrhea owing to cigarette smoking or chronic bronchitis and upper

respiratory infections definitely predispose to development of atelectasis The smoker should refrain from smoking for seven to ten days preoperatively, and infections of the respiratory tract should be controlled whenever possible All mucus should be aspirated from the tracheobronchial tree before removal of the endotracheal tube if one has been used While the patient is recovering from the effects of the anesthetic, he should be protected against possible aspiration by close supervision and suction of pharyngeal secretions The patient should be placed on his side with his head turned so that secretions will gravitate out of the mouth Atelectasis usually develops during the anesthetic or early recovery period as it is almost invariably evident within the first 48 hours postoperatively Other prophylactic measures are periodic deep breathing turning the patient from side to side and to the back at least every two hours, and steam inhalation at the slightest suggestion of difficulty in raising sputum Medicinal inhalations for bronchial dilatation and liquefaction of secretions and local antibiotic therapy are of great prophylactic value in specific cases and of therapeutic benefit in patients who have experienced atelectasis Such measures consist of the aerosol inhalation of Vaponephrin to which aqueous penicillin in doses of one hundred thousand units can be added In patients in whom tenacious bronchial secretions require more liquefaction, pancreatic dornase (Dornovac) (fifty thousand units) may be added to the aerosol mixture If such measures are utilized it is imperative that the patient be physically able to bring up the secretions by coughing, either with or without the aid of postural drainage If the patient is unable to do this, the secretions should be removed by periodic tracheal suction or bronchoscopy as needed Tracheobronchial suction may be done at the bedside A No 16 or No 18 French rubber catheter is introduced into the trachea through the nares or mouth By altering the position of the patient the physician can advance the catheter into the major bronchi to stimulate effectual coughing as well as to aspirate appreciable amounts of retained secretion

The extent of involvement in atelectasis varies from small patches to an entire lung and, of course, portions of each lung may be involved The severity of symptoms is proportionate to the amount of pulmonary parenchyma involved There may be few or no signs or symptoms with involvement up to the segmental areas When an entire lobe (and most often it is a lower lobe) is rendered airless by atelectasis, fairly conclusive evidence can be obtained from clinical examination and confirmed by proper radiologic views of the chest The patient appears acutely ill with tachycardia, fever, and often evidences respiratory embarrassment The roughly triangular area corresponding to the collapsed lower lobe can be outlined on physical examination by the area of dullness, absent breath sounds, and diminished vocal fremitus Radiologic examination of the chest with special lateral and oblique views to delineate the areas normally obliterated by the heart shadow in the erect posterior anterior view gives confirmatory evidence

Prompt institution of vigorous measures to restore aeration of the involved area and prevent recurrence in the same or other areas is necessary Inhalation of medicated vapor for dilation of the bronchi and liquefaction of the secretions, tracheal aspiration and such postural drainage as the patient can execute, are usually effective If such is not the case, bronchoscopy should be employed to avert the danger of frank pneumonitis and permanent bronchial damage The aforementioned conservative measures should be intensified during the first few days after a bout of atelectasis has been corrected and a broad spectrum antibiotic should be given to lessen the danger of pneumonitis in the involved area Occasionally, tracheostomy is indicated if there is difficulty in evacuating the bronchial secretions

PNEUMONIA Pneumonia usually occurs within 18 hours of operation or after about a week In the former instance it is almost invariably due to atelectasis aspira

tion or a pre existing respiratory disease in the latter it is usually due to pulmonary embolism and infarction The almost ubiquitous use of antibiotics with suppression of the bacterial flora in the upper respiratory passages has undoubtedly been a major factor in lessening the incidence of pneumonitis resulting from pre existing infections If pneumonitis occurs as a primary entity or is superimposed on other pulmonary disease the patient should be given specific antibiotics as determined by smear culture and sensitivity studies and supportive measures as indicated

PULMONARY EMBOLISM As the result of thrombi which almost invariably originate in the lower half of the body pulmonary embolism continues to be a major postoperative problem Such thrombi are swept into the venous stream and lodge in the arborization of the pulmonary arterial system They vary in size from minute ones to casts of the major pelvic or deep peripheral veins and may be single or multiple Occlusion may involve any portion of the pulmonary vascular bed up to the common pulmonary artery or even the outflow tract of the right ventricle

The resulting symptoms are extremely variable The rather stereotyped previous concept of thoracic pain dyspnea and hemoptysis has been replaced by the realization that this disease is characterized by clinical and radiologic inconsistencies The most important requirement in recognition of this complication is awareness of its possible existence and of the extreme variability in clinical manifestations As evidenced by the unsuspected finding of pulmonary emboli at necropsy in a significant number of cases the condition is often unrecognized during life The patient s initial response may be negligible the first evidence of embolization being found in the roentgenogram of the chest or at necropsy or there may be a rapidly fatal cardiopulmonary disturbance Any degree of intensity of signs and symptoms between these two extremes may be exhibited In general the intensity of the response is commensurate with the magnitude of the embolization

It has been justifiably emphasized that patients with phlebothrombosis in whom development of a pulmonary embolus is imminent have a strange sense of impending disaster This may be because an embolism has already occurred with the resulting perhaps subconscious awareness of sudden change in one s state of health Tachycardia thoracic discomfort or frank pleuritic pain and some degree of dyspnea are the more common clinical manifestations of embolism Frank pain indicates the existence of an actual infarction and when the diaphragmatic pleura is involved pain is frequently referred through the phrenic nerve to the dorsum of the shoulder

In the absence of pulmonary infarction no abnormalities are detected in roentgenograms of the chest and without pain and hemoptysis the diagnosis is difficult Embolization of sufficient magnitude to increase significantly the resistance in the pulmonary vascular bed often causes alterations in the roentgenogram of the chest and electrocardiogram Evidence of increased prominence of the right ventricle and of the main pulmonary artery are the primary radiologic findings suggestive of pulmonary embolus in addition to infarction and effusion when these occur Diagnostic evidence of right ventricular strain may be demonstrated by electrocardiographic examination The tracings that are most diagnostic are obtained from precordial leads and as would be expected the greater the occlusion of the vascular bed the more diagnostic this evidence will be In severe cases electrocardiographic findings differentiate between massive pulmonary infarction and coronary occlusion The somewhat delayed laboratory evidence of elevation of the leukocyte count and erythrocyte sedimentation rate and roentgenographic evidence of infarction and effusion are largely confirmatory

Treatment of pulmonary embolism consists in supportive measures to the cardiopulmonary system because of the damage already incurred and institution of measures to prevent further embolization The patient who survives the first few hours

after occurrence of a pulmonary embolus has a good chance of overcoming the pulmonary damage provided he is spared further embolization by prompt appropriate therapy Use of digitalis oxygen therapy and limitation of the demands on the pulmonary system usually is sufficient treatment of the pulmonary lesion Necrosis and suppuration are infrequent sequelae of bland pulmonary infarction the more usual course of events being recanalization of the vessels and resumption of function of the pulmonary tissue involved In patients with sizable infarcts possibly associated with some degree of effusion and those whose embolus originated from an infected focus of suppurative thrombophlebitis antibiotic therapy should be employed Pulmonary embolism usually originates from an area of phlebothrombosis rarely in an area of suppurative thrombophlebitis and even more rarely from nonsuppurative thrombophlebitis Because of the persistent danger of more clots becoming detached and further embolization we believe it is imperative to prevent these emboli from being transported to the heart and lungs This can be accomplished only by ligating the venous system on the cardiac side of the area of thrombosis

Because of the advances in cardiac surgery in the last decade it seems reasonable to hope that revival of the use of the Trendelenburg operation or pulmonary arterial embolectomy in certain well selected cases may become a practical reality Surely one of the greatest tragedies in surgery is the otherwise healthy patient convalescing from a successful operation whose life is snuffed out by a massive pulmonary embolus The decision to undertake such a procedure would depend on the certainty of the diagnosis and the assumption that death would supervene otherwise Survival for a sufficient length of time after massive embolism occurs often enough to permit such a procedure to be undertaken with deliberation in an institution with personnel and equipment for cardiac surgery

ventricular decompensation pulmonary edema may be manifested postoperatively as a combined respiratory and cardiac complication The characteristic apprehension dyspnea and production of large amounts of frothy blood stained sputum together with diffuse bubbling rales throughout all pulmonary areas are diagnostic This complication is most likely to occur in persons with known cardiac disease who may or may not have experienced similar episodes and required digitalization in the past Treatment is directed toward increasing cardiac efficiency by digitalization and emergency measures to lessen the demands on the lesser circulatory system by phlebotomy, trapping of significant volumes of blood by application of tourniquets to the extremities and use of positive pressure oxygen therapy

CONGESTIVE ATELECTASIS A syndrome involving the respiratory system that is being recognized postoperatively with increasing frequency is congestive atelectasis It is produced by apparently selective overloading of the pulmonary vascular bed without the necessary accompaniment of systemic vascular engorgement Most of these patients have received too rapid and abundant if not excessive parenteral fluids during and after the operation Patches of intense congestion of the pulmonary vascular bed with some interstitial extravasation but with little or no transudation into the air spaces characterize the pathologic picture and account for the symptoms Severe compromise of the available respiratory volume by compression of the air spaces gives rise to the atelectatic or relatively airless state of the lung and accounts for the severe dyspnea and cyanosis The physical and radiologic signs are often misleading in that they are not consistent with the patient's obviously critical condition The rigidity of the pulmonary parenchyma imposed by the congestion results in critical loss of compliance with severe respiratory embarrassment

Treatment is largely supportive that is sedation and oxygen therapy with special care to avoid further increased demands

problem in treatment is often presented by the coexistence of systemic hypotension Attempts to correct this abnormality have as their aim centralization of the blood volume which produces further embarrassment of the lesser circulatory system Fluids and vasoconstricting drugs must be prescribed with caution to avert the dangers of systemic hypotension on the one hand and further pulmonary insult on the other The condition is apparently not a variant of pulmonary edema resulting from left ventricular failure as it is not benefited by the usually efficacious measures of rapid digitalization phlebotomy and positive pressure respiration employed in such cases The high mortality rate emphasizes the necessity for avoiding excessive and too rapid fluid therapy

## Acute Gastric Dilatation

Acute gastric dilatation is one of the most treacherous postoperative complications Because it is relatively infrequent develops insidiously and may occur at any time in the postoperative period the diagnosis is likely to be completely overlooked or to remain undetected until the patient is seriously ill The term is somewhat of a misnomer in that the characteristic atony and dilatation of the stomach are associated with a similar condition of the proximal duodenum It usually results from disregard for the period of functional inactivity (adynamic ileus) of the gastrointestinal tract during which time gastric and enteric secretions persist but peristalsis is inhibited If fluids are permitted by mouth the condition is greatly aggravated with retention of large quantities of fluid and air in the stomach As the gastric distention increases the atony increases and the process may become irreversible Because the stomach becomes completely devoid of contractile power vomiting is ineffectual

Characteristically the patient repeatedly regurgitates small amounts of usually darkly stained foul smelling fluid which the apathetic often shocked patient barely raises to the lips and allows literally to spill out of the mouth This scant discharge is analogous to the overflow of a distended atonic urinary bladder It results from compression of the stomach by the diaphragmatic and abdominal musculature and the vomiting reflex lacks the component usually contributed by the gastric musculature Such feeble attempts at vomiting upper abdominal fullness and signs of acute fluid and electrolyte depletion to the extent that shock may be imminent or present are classical

Prevention of the fatal outcome that is highly probable if untreated depends on prompt recognition and proper treatment Decompression by gastric suction and quantitative and qualitative restoration of the depleted circulatory system are eminently successful if instituted before irreversible shock or gastric perforation occurs The best treatment however is prophylactic and is accomplished by the almost routine use of continuous gastric suction in all persons in whom adynamic ileus is likely In this way the retained gastrointestinal secretions and swallowed air are removed and dilatation of the stomach with possible gastric atony is prevented Once gastric dilatation occurs the gastric contents must be evacuated promptly often with a large gastric tube and the fluid and electrolyte deficiency must be quickly corrected

## Adynamic Ileus

As in the case of acute gastric dilatation paralytic or adynamic ileus is a functional disturbance affecting primarily the small but sometimes the small and large intestines A much rarer occurrence is an almost pure functional disturbance of the colon with tremendous gaseous distention limited to the large intestine Adynamic ileus may occur as a result of stressing any part of the body but it is much commoner after intraperitoneal or extraperitoneal trauma The duration of functional inactivity can be reduced by appropriate definitive measures

The possibility of paralytic ileus of some degree can be anticipated in a sufficiently

high percentage of abdominal surgical cases to justify institution of the easy and effective prophylactic measures available in most cases Use of these measures only after ileus has developed unnecessarily subjects patients to a preventable complication that is associated with considerable morbidity and some mortality Effective prophylactic measures include withholding of oral intake until peristalsis is re established, and gastric suction by a gastric tube passed after the patient has been anesthetized if a general anesthetic is used, or after sedation if lumbar anesthesia is employed This avoids the former harrowing experience for the patient, family, and physician when the gastric tube was inserted before the patient was taken to the operative suite Also it insures decompression of the upper gastrointestinal tract during the operation and during the period of expected dysfunction of the gastrointestinal tract Most patients tolerate the tube well

Untreated adynamic ileus is manifested by abdominal distention nausea vomiting dull abdominal pain and great diminution or absence of peristaltic sounds There is evidence of deficiency of electrolytes and fluids because of the loss into the intestine and by vomiting Flat and erect or lateral decubitus roentgenograms confirm the presence of distention of both the small and large intestine Although fluid levels are more common in organic obstruction they do occur in paralytic ileus

Treatment of paralytic ileus consists in prevention of further accumulation and, insofar as possible evacuation of the intestinal contents The conventional gastric suction tube serves admirably in preventing any further accumulation of swallowed air, salivary secretions and gastric secretions Its efficacy in removing any of the contents of the small intestine depends on its passage through the pylorus or on a patulous pyloric canal and reverse intestinal peristalsis In any event its effectiveness does not extend beyond the upper loops of the small intestine The single or double lumen small intestinal tube offers great benefit in such cases and in all but the mildest cases should be employed instead of the simple gastric tube It results in decompression of both the stomach and small intestine The efficacy of these tubes depends on peristaltic activity, which advances the balloon beyond the second part of the duodenum Frequently, the patients who need intestinal decompression the most are improper candidates because of ineffectual peristalsis Nevertheless the method deserves every effort as the treatment is specific and the response dramatic when it can be effected Fluoroscopic guidance with or without flexible stilets in competent hands aids passage through the pylorus and mercury weighted balloons often facilitate placement of the tip of the tube well within the duodenum From this point on as the intestines become decompressed peristalsis returns and the tube advances along the intestinal tract decompressing succeeding loops Even so the tube cannot be relied upon to decompress the large intestine unless it actually advances into this segment and in such cases because of the increased consistency of the intestinal contents this is likely to be unsuccessful

The paralytic colon may be decompressed from below by passage of a colon tube plus judicious rectal instillation of small quantities of warm solutions in an effort to stimulate peristalsis However there is nothing to be gained from distention of an already overly stretched colon which has become retractory to the normal stimulus of stretching by use of repeated enemas Passage of a colon tube well into the sigmoid by proctoscopy with the patient in the lateral decubitus position may be beneficial and should be employed whenever distention of the colon and especially the cecum seems to be approaching a dangerous degree

When paralytic ileus is due to additional factors such as mesenteric vein thrombosis operative measures must be used Adynamic ileus may follow or be superimposed on organic intestinal obstruction This may result from overdistention and paresis of the intestinal musculature Adynamic ileus may likewise be compl

cated by mechanical intestinal obstruction, when loops of immobile, distended, and edematous intestines become agglutinated to one another with production of one or multiple sites of acute angulation and obstruction ("water hose kinks") Fortunately, for the one making the decision treatment is usually the same for the advanced stages of these two processes that is, operative intestinal decompression

## Mechanical Ileus

In contrast to adynamic ileus, which develops in the early postoperative period, mechanical ileus, which in fact depends on recurrence of intestinal activity for its symptoms, is usually a delayed postoperative complication As the name implies, there is a physical impediment to the continuity of the intestinal lumen, which may be either partial or complete The more complete the obstruction the more rapidly progressive and clear cut the clinical picture Postoperatively, a patient is susceptible to many causes of obstruction but, because the surgeon has recently explored the abdomen, he has an advantage in determining the possible cause By far the most frequent cause is fixation of the intestines by adhesions that cause acute angulation of the intestines with production of a "water hose kink" These adhesions are at first fibrinous but rapidly become organized Other causes are adhesions owing to localized or generalized peritonitis, edema, or intussusception of anastomotic sites, intestinal compression by insinuation into peritoneal defects and volvulus Symptoms depend on interruption of the propulsive function of the intestine proximal to the obstruction Pain, though often accompanied by constant discomfort, is characterized by episodes of more intense colic, often concomitant with audible peristalsis Nausea, vomiting, and anorexia are early signs The degree of distention largely depends on the level of the obstruction and the length of intestine proximal to the obstruction Obstipation is, of course, the eventual development, but one should not be misled by the occurrence of one or more bowel movements or significant fecal return from enemas Such can be expected until the intestine distal to the obstruction has been evacuated

In obstructions associated with a disturbance of intestinal vascularity small amounts of decomposing blood are passed by rectum The patient appears ill, suffers episodes of acute abdominal pain, and may have abdominal distention that is generalized or is predominately in one half or one abdominal quadrant, depending on the degree and duration of the obstruction If the distention is limited to an abdominal quadrant, it is usually indicative of volvulus Distended coils of intestine can be detected by inspection only in frail persons, but frequently segments of distended intestines are palpable Discrete masses representing volvulus or localized abscesses may be demonstrable Except in late stages when intestinal exhaustion has developed, characteristic peristaltic sounds of forceful borborygmi and rushes and high pitched tinkles and plinks occur Auscultation for many minutes may be necessary but pathognomonic sounds can usually be detected Roentgenographic examination demonstrates the distended intestine above the site of obstruction and may incriminate only a few loops or the full length of the intestine Fluid levels are more likely in mechanical obstruction than in paralytic ileus and if the process has existed for a significant length of time, there is likely to be evidence of intraperitoneal accumulation of fluid This latter development is demonstrated by the impression of increased density of the abdomen on the flat film (ground glass appearance) and possibly a hazy giant fluid level in the upright film An impression as to the thickness of the intestinal wall can be gained by noting the distance between the columns of intraluminal gas in adjacent loops of intestine (Fig 4 1) The patient may have manifestations of fluid and electrolyte depletion, and of toxicity, depending on the duration of the obstruction and the adequacy of supportive therapy

Once the diagnosis of mechanical obstruction has been established, initial therapy should consist of correction of fluid and electrolyte deficiencies and use of gastric suction In early cases of simple obstruction from fibrinous adhesions, such measures may be curative Return of adequate peristalsis may overcome such points of fixation or intestinal decompression may relieve "water hose kinks" If a double lumen intestinal tube is inserted and successfully passes the duodenum, the small intestine may be decompressed, as the intestine becomes fluted on the tube as it advances

If, however conservative therapy does not result in decompression of the intestine and improvement of the patient's condition within a few hours conservative therapy must be abandoned and the patient should be operated upon If viability of the intestinal wall is in question, the patient should be reoperated on as soon as it is considered safe Too often a dangerous or irreversible stage of depletion has been permitted to develop before the futility of nonoperative therapy is accepted Even after several days of obstruction most patients can tolerate resection or decompression and the golden hour should not be lost in wishful procrastination Because of the danger of aspiration during vomiting lumbar anesthetization is preferable to general anesthesia The probable level of obstruction can usually be localized to one quadrant of the abdomen on the basis of clinical and roentgenographic examination and the area may be approached through the original or a new incision In the presence of massive intestinal distention the intestinal wall is extremely thin and much manipulation may result in rupture This can be prevented by early decompression of several loops of intestine

Fig 4 1 Roentgenograms of the abdomen in the (*left*) supine and (*right*) erect positions of a patient with mechanical obstruction of the small intestine The distended obstructed loops of intestine with valvulae conniventes are evident in each film The linear density between adjacent loops of intestine in the supine view indicates edema of the intestinal wall or intraperitoneal fluid Use of the horizontal roentgen ray beam in the erect film demonstrates fluid levels in loops of the intestine

by insertion into the intestinal lumen through the antimesenteric surface a large bore needle connected to the suction Before removal of the needle a purse string suture is placed around the needle and tightened and tied immediately after withdrawal of the needle

After decompression of the intestine the abdomen can be safely explored to determine the cause of the obstruction The obstruction should then be relieved by freeing of adhesions evacuation of an abscess or resection of devitalized intestine, as indicated Thereafter an attempt may be made to advance the intestinal tube in order to decompress the intestines postoperatively However frequently frustrating attempts to pilot the flexible tube through the pylorus and duodenum are abandoned after considerable loss of time but the attempt often proves rewarding enough to be worth the effort

In the case of resection with open anastomosis decompression is readily accomplished by passage of a rounded suction tube or large catheter along the intestine in each direction evacuating it as it advances In cases of moderate to severe distention in which it is not an actual necessity to open the intestines the benefit derived from carefully performed enterotomy with complete intestinal decompression outweighs the potential dangers of this procedure Such a maneuver evacuates the intestine of its noxious contents and materially hastens recuperation of the intestine Further postoperative care should be directed toward aiding the intestine to resume its function largely by insuring its rest plus parenteral restoration of the deficiencies incurred from the complication Postoperative obstructions of the colon are fortunately few They are treated by proctologic measures whenever possible or by laparotomy and release of adhesions resection of the involved portion of the intestine or colostomy as the situation demands In resective procedures usually on an unprepared intestinal tract the operative field should be generously irrigated with saline solution and a dilute solution of neomycin may be instilled into the peritoneal cavity and intestinal lumen This latter maneuver is associated with some risk of respiratory arrest because of its curarelike action in some instances and is especially hazardous in infants and young children Proximal colostomy or large tube cecostomy should be included as a safety measure after resection of the colon in seriously ill patients who have not had the benefit of bowel preparation The inconvenience attending elective closure of the colonic stoma or simple withdrawal of the cecostomy tube after the patient has recovered is not great and the protection may be lifesaving

## Enterocolitis

Development of resistant organisms is an expected consequence of antibiotic therapy and such organisms may be found in postoperative infections Emergence of such strains subjects the host to what amounts to inoculation with organisms peculiarly adapted for growth In large measure postoperative infections that develop in the face of antibiotic therapy are produced by such organisms The frequent oral administration of antibiotics before and after operation provides an opportunity for emergence of resistant organisms from the normal flora of the intestinal tract This is clearly demonstrated in the increased incidence of staphylococcic enteritis in such patients It should be remembered however that this complication develops not only after oral antibiotic therapy but can occasionally be precipitated by parenteral administration of such medications as well as in persons who have had no antibiotics As a result of the high concentration of the antibiotic in the intestinal lumen the susceptible organisms are killed and the resistant ones begin to predominate The micrococcus *pyogenes* variety *aureus* of the Staphylococci family is a frequent resistant bacterium and by its luxuriant overgrowth produces a specific type of enteritis

The symptoms are mediated through a powerful enterotoxin which is liberated

into the intestinal tract for absorption The patient, most often one known to be vulnerable to such an infection, is acutely ill with fever, toxicity, and symptoms suggestive of peritonitis, ileus, or intestinal obstruction Usually the lower intestinal tract is principally involved and there are fulminating episodes of diarrhea, characterized by passage of mucous containing watery stools

The illness may rapidly deplete the patient of fluids and electrolytes, and prompt supportive measures are necessary to combat such depletion, which may progress to frank shock Transfusions of blood and plasma as well as infusion of liberal amounts of electrolyte solutions may be required Smear and culture of fecal specimens should be taken for identification of organisms and sensitivity studies

Meanwhile, the patient should be given an antibiotic that he has not taken before and that is likely to be effective against staphylococci The newer antibiotics to which the bacteria are least likely to have been exposed are usually effective Because bacteremia sometimes occurs as a part of this type of infection, intensive parenteral as well as oral medication is required If the patient fails to respond favorably to this therapy within twenty-four to thirty-six hours, an additional antibiotic should be given The severity of the infection precludes postponing treatment until sensitivity studies have been completed, but more specific medication may be necessary after such studies

## Acute Cholecystitis

The far greater than coincidental occurrence of acute cholecystitis as a postoperative complication of unrelated operations has been well documented The attack is usually fairly typical but the correct diagnosis is likely to be delayed since the clinical picture is superimposed on that related to the primary procedure Clinical manifestations usually appear shortly after resumption of oral intake and consequent stimulation of the gallbladder, which has been well demonstrated to be suppressed during stress Cholelithiasis is usually present The most frequent cause for delay or failure of diagnosis is that the illness is attributed to persistence or development of postoperative ileus The most important factor in making the diagnosis is awareness of the possibility of this disease Treatment should be cholecystectomy or cholecystostomy, depending on the patient's condition If the latter is considered advisable, it can be done safely with use of local anesthesia even though the patient may be seriously ill The morbidity and mortality rates in patients with acute cholecystitis treated conservatively are far greater than the risk of removing or decompressing the gall bladder

## Intraperitoneal Infections

The frequent use of antibiotics preoperatively and postoperatively has significantly decreased the incidence of post-operative inflammatory complications However, when such infections do occur, although potentially they are no less lethal, the clinical course may be bizarre because of attenuation of the microorganisms by the antibiotic The diagnosis may be dangerously delayed because of the masking effect of antibiotic therapy

Peritonitis is usually the result of introduction of bacteria into the peritoneum from the gastrointestinal or biliary tract by spontaneous or traumatic rupture of the viscera or by intentional open operations That the peritoneum is inoculated with a variety of pathogenic bacteria in most such cases is well established but the infrequent development of peritonitis is testimony to both the natural resistance of the peritoneum and the effectiveness of the antibiotic therapy Undoubtedly, appreciable numbers of subclinical infections are aborted Other infections occur, but because of bacterial attenuation may produce minimal manifestations so that recognition of the infection is delayed until the patient is seriously ill

Residual infections within the peri

toneal cavity have a predilection for the subphrenic space and the cul-de-sac of Douglas Infection of one or more of the subphrenic areas is due usually to extension from the site of peritoneal contamination or direct extension from adjacent subdiaphragmatic structures The possibility of subphrenic and other intraperitoneal abscesses must be considered in all patients with peritoneal contamination Much can be accomplished prophylactically during the operation by removal of blood and serous exudates from the recesses of the abdominal cavity, because blood is an ideal culture medium for growth of bacteria Gentle lavage of the subphrenic spaces, as well as the other abdominal recesses, with warm saline solution immediately before closure of the wound, is an effective prophylactic measure for removing both organisms and the pabulum for their growth The use of a sump drain is valuable in preventing reaccumulation of these fluids during the postoperative period

Subphrenic and subhepatic infections are usually the result of staphylococci, streptococci or colon bacilli or a combination of these These infections occur as a sequel to appendicitis or to upper abdominal operation or other trauma, and they have a predilection for the right side, particularly the right posterior superior space The less frequent involvement on the left is more likely to be associated with malignant lesions of the stomach, pancreas, or colon, which undoubtedly is a factor in the higher mortality rate in left sided subphrenic and subhepatic infections

The diagnosis of subphrenic infection can usually be suspected from a history of possible contamination and signs of infection, such as fever, leukocytosis, and abdominal tenderness The tenderness in right posterior superior space infections is characteristically over and limited to the right twelfth rib, and in right inferior space infections, which are infrahepatic, tenderness is beneath the right costal margin Confirmatory or suggestive roentgenographic evidence may be demonstrated in about three fourths of the cases, especially if appropriate positions and penetration technics are employed Posterior, anterior, and lateral roentgenograms should be obtained In right posterior superior space infections the lateral portion of the diaphragm is elevated in the postcroanterior roentgenogram and the costophrenic angle is obliterated In the lateral roentgenogram the posterior portion of the diaphragm is elevated with obliteration of the posterior costophrenic angle Rarely, there is evidence of gas beneath the diaphragm or of pleural effusion, the latter being due to transphrenic migration of the offending microorganism or toxins The ease of displacement of the stomach and spleen militates against early displacement of the left leaf of the diaphragm and renders radiologic diagnosis somewhat less certain than in cases involving the right side Subphrenic infections that develop in patients receiving antibiotic therapy often produce minimal evidence of their existence until the infection is advanced However, it is evident that the patient is ill or is convalescing more slowly than anticipated, but the total and differential leukocyte counts are often not high enough to indicate significant infection An erythrocytic sedimentation rate out of proportion to that expected in the postoperative state is of importance Significant elevation almost invariably accompanies appreciable accumulation of necrotic or purulent material

Subphrenic and subhepatic infections should be treated by prompt extraserous drainage (Fig 4 2) Diagnostic aspiration of suspected areas is undesirable because of a more than theoretic likelihood of spreading infected material to new areas and because of the high percentage of negative results, which may further delay definitive treatment All true subphrenic, right subhepatic and left anterior inferior spaces are readily accessible for extraserous drainage Selection of the site for drainage depends on the location of the abscess In right posterior superior abscesses a posterior approach permits extraserous drain-

age without contamination of pleural or peritoneal cavities The incision is made along and parallel to the twelfth rib, which is resected in its entirety (Fig 4-2) Through the bed of the twelfth rib, a transverse incision is made at the level of the first lumbar spinous process The diaphragmatic attachment is incised and

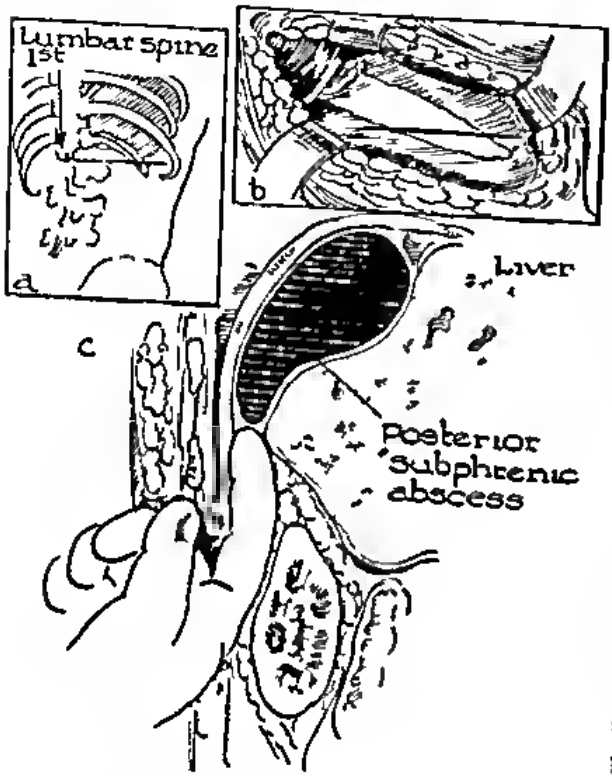


Fig 4 2 Technique of drainage of a posterior subphrenic abscess (*a b*) Cutaneous incision overlies twelfth rib Site of entry into retroperitoneal space through bed of resected twelfth rib at level of first lumbar spinous process (*c*) Dissecting finger is plunged into abscess cavity

the posterior parietal peritoneum is exposed This is dissected from the under surface of the diaphragm until the abscess which is located above the liver and posterior to the right lateral ligament is reached The dissecting finger is plunged into the abscess cavity and drainage is instituted In abscesses of the right anterior superior space drainage can be accomplished extraperitoneally by an incision parallel to and just below the costal arch Extraserous entry into the abscess cavity is possible by mobilizing the transversalis fascia and peritoneum from the abdominal wall on the underside of the diaphragm until the abscess is encountered The fortunately rare but less accessible collection in the left posterior inferior space or the lesser omental bursa can be drained posteriorly or through an approach that traverses the greater peritoneal cavity Because several weeks may be required for complete obliteration of these sizable abscess cavities adequate drainage by semirigid rubber tubing through a wide aperture should be employed The drainage tube should be withdrawn gradually as indicated by the progress of obliteration of the dead space, which can be determined clinically and roentgenographically These examinations may include instillation of radiopaque dye into the abscess cavity, or the measuring of the volume of the cavity by instillation of saline solution

The other natural recess in the peritoneal cavity that is frequently the site of localized infection is the cul-de sac of Douglas Such infections are usually the sequelae of contamination of the general peritoneal cavity or of the lower half of the abdomen after operations on the intestinal tract or the pelvic portion of the genitourinary tract In fact, there is a tendency for peritoneal exudate particularly with the upper part of the body elevated, to gravitate into the cul-de sac of Douglas As in subphrenic infections cul de sac infections probably occur frequently but are not recognized and resolve spontaneously However, because significant infection in the cul de sac can be detected rather easily it should be diagnosed early

As in other residual intraperitoneal infections there are systemic signs of persistence of infection such as fever and leukocytosis In the beginning of their development there may be few localizing manifestations Because of the proximity of the urinary bladder, rectum and anus to the cul-de-sac, the patient often complains of urgency and frequency of urination a sense of rectal fullness and anal incontinence These may be associated with local abdominal discomfort Diarrhea

with increased mucus owing to the associated proctitis is common On rectal examination the anal sphincter is often relaxed, and high on the anterior wall may be an area of tenderness and induration or, in advanced cases, fluctuation The induration with suppuration feels like an apple with a rotten spot in the middle The rectal mucosa is edematous and feels succulent

Treatment consists of adequate drainage of the abscess, preferably through the rectum A large bore needle connected to a syringe is inserted, frequently without the aid of anesthesia, into the "rotten spot in the apple" If pus is aspirated, with the needle still in place a longitudinal incision is made through the anterior rectal wall into the abscess cavity The edges of the incision are separated by means of a hemostat and soft rubber tubes are inserted into the cavity for drainage The contents are quickly evacuated and the cavity is obliterated because of the intra abdominal pressure The tubes will be spontaneously extruded when the cavity is obliterated

## Venous Thrombosis

Whereas the incidence of many post operative complications has decreased because of the control of shock, sepsis, and electrolyte imbalance, the incidence of venous thrombosis has increased through the years This complication develops in about one of every five hundred patients admitted to general hospitals It occurs in people of all ages, although it most often affects those of advancing age It must be remembered that venous thrombosis is a complication of medical as well as surgical conditions

### *Types*

In a consideration of postoperative venous thrombosis it is important to differentiate between the main types Most cases will fall into one of two large categories thrombophlebitis or phlebothrombosis Thrombophlebitis is usually nonseptic but occasionally it may be septic Especially in surgical patients chemical thrombophlebitis may occur as a consequence of parenteral therapy but we have never seen this process lead to embolization

In *thrombophlebitis*, or phlegmasia alba dolens, an inflammatory process occurs within the wall of the vein and the thrombus is secondary to the changes in the venous endothelium This condition has been known since the time of the ancients It produces definite clinical manifestations Because the thrombus within the vessel is secondary to the inflammatory changes in the venous endothelium the clot is a white thrombus, which is firmly attached to the venous wall Such a thrombus in itself is rarely responsible for pulmonary embolism but it may serve as the site of development for a thrombus that may become an embolus by one of two processes The thrombus may undergo suppuration, as when it becomes involved by bacterial infection and septic thrombophlebitis ensues or a propagating bland red thrombus may build up on the organizing thrombus and may be swept into the venous stream as an embolus

The other major type of thrombotic disease *phlebothrombosis*, occurs insidiously and often defies diagnosis It is unassociated at the outset with an inflammatory process in the venous wall but consists of a coagulation thrombus in a previously normal vein The thrombus probably is the result of two factors One, a predisposing factor, is increased coagulability of the blood resulting from changes in the blood constituents caused by tissue damage and the other, a precipitating factor, is slowing of the blood flow in the veins of the lower extremity The predisposing factor is probably due to tissue damage (operative trauma, accidental trauma or invasion of tissue by infection or neoplastic disease) and is most likely a protective mechanism The precipitating factor is a consequence of general circulatory retardation attending diminished activity, such as bed rest, inactivity of the muscles of the lower ex-

tremity, particularly the calf muscles, increased abdominal tension from gaseous distention of the intestinal loops, tight abdominal bandages, decreased negative pressure within the thorax occasioned by shallow breathing, and a decreased vis a tergo through the capillary bed

Septic or suppurative thrombophlebitis is an important subtype of thrombophlebitis These patients usually have an obvious source of infection with involvement of a portion of the venous system in the septic process, and actual showers of septic bacterial emboli are thrown into the venous stream The patient has the characteristic manifestations of a systemic infectious process

The two types of venous thrombosis also differ as to prognosis True thrombophlebitis is usually associated with a relatively good prognosis as regards life In fact, unless adequate therapy is instituted early, these patients live long enough for postphlebitic sequelae to develop On the other hand phlebothrombosis is a potentially fatal disease from the onset, the clot, being only loosely attached to the venous wall can become detached readily with production of a pulmonary embolus, with resultant nonfatal or sudden fatal embolism

THROMBOPHLEBITIS The clinical manifestations of venous thrombosis also vary according to the type of the lesion The patient with thrombophlebitis of the deep veins is usually ill The temperature is elevated and the involved extremity is swollen painful and tender, and usually has a whitish discoloration In thrombophlebitis of the superficial veins there is redness over and along the course of the veins, such as the long saphenous vein In deep thrombophlebitis not only is the extremity white but it feels colder than the other leg and the peripheral arteriolar pulsations are diminished as a result of reflex vasospasm of the arterioles in the homolateral extremity

Except when suppuration is superimposed on this type of thrombophlebitis which is rare, antibiotics are of no value because the process is not bacterial in origin Phenylbutazone, which exerts an antiphlogistic action is, however, of benefit in early cases The treatment of thrombophlebitis consists of application of pressure bandages from the toes to the groin, active mobilization of the extremity, and early ambulation as soon as the temperature becomes normal Because vasoconstriction plays an important role in production of symptoms and prolongation of the process vasodilatation of the arterioles of the involved extremity is of importance This is best accomplished by interruption of the lumbar sympathetic ganglia with local anesthetic agents, such as procaine or lidocaine (Xylocaine) Either this can be performed repeatedly (the number of times necessary depending upon the time required for complete subsidence of symptoms) or a polyethylene catheter can be inserted in the retroperitoneal space so that repeated injections can be made

The technique of anesthetization of the lumbar sympathetic ganglionated chain is relatively simple (Fig 4 3) If the patient is not too ill it is best to have him in the supine position with a pillow under the abdomen to straighten the lumbar curve If, however, he is acutely ill, as many of these patients are, it is best to place him in the lateral decubitus position The spinous processes of the first, second third and fourth lumbar vertebrae are identified, and two fingerbreadths lateral to each of these, a cutaneous wheal is produced with procaine A long fine lumbar puncture needle is introduced perpendicularly to the skin until it impinges against the transverse process The transverse process is used as a landmark because whereas the subcutaneous fat and the erector spinae mass may vary considerably in a fat, muscular man and a small, thin woman there is relatively little difference in the thickness of the bodies of their vertebrae After the point of the needle impinges against the transverse process, the direction of the needle is changed slightly, either above or below and introduced for an additional two fingerbreadths The point of the needle then lies in the retroperitoneal space near

the anterolateral surface of the bodies of the lumbar vertebrae, and through each of the four ports, 5 to 10 cc of the local anesthetic agent is injected This floods the retroperitoneal area where the lumbar sympathetic ganglia are located, and satisfactorily anesthetizes the ganglia Injections are repeated at 12-hour to 24 hour intervals until the patient's temperature has returned to normal, which usually requires only a few days For some time after complete subsidence of fever and amelioration of pain, the patient must continue wearing supportive bandages and must be active because movement of lymph is greatly favored not only by arteriolar pulsation but also by contraction of the muscles of the extremity

PHLEBOTHROMBOSIS The clinical picture in phlebothrombosis differs greatly from that of thrombophlebitis Approximately 40 per cent of patients have no symptoms or signs whatever, the first manifestation of the disease being a pulmonary embolus Therefore, it is imperative to look for evidence of venous thrombosis in all persons who have been operated on, particularly older people with infection or neoplastic disease who have been ill for some time Tenderness in the region of the calf or pain on dorsiflexion of the foot (Homans' sign) associated with tachycardia out of proportion to other manifestations is often present

Although many physicians believe that phlebothrombosis can be treated satisfactorily with anticoagulants, we are convinced that anticoagulants are of little or no value in preventing detachment of a clot that has already formed Were one able to predict in which patients phlebothrombosis would occur, administration of anticoagulants prophylactically would be of great value Unfortunately, the danger of hemorrhage is much too great to warrant routine administration of anticoagulants to every patient upon whom operation is performed Although administration of anticoagulants in sufficient dosage to patients with thrombosis will

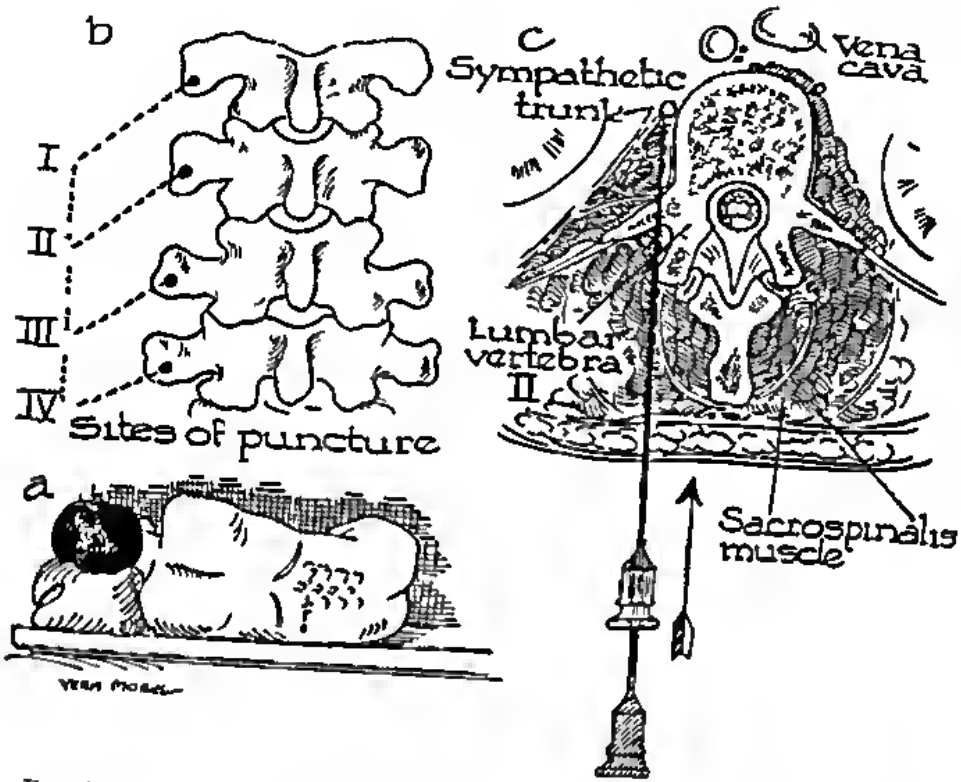


Fig 4 3 Technique of anesthetization of lumbar sympathetic ganglionated chain

prevent formation of additional thrombi, it will in no way prevent detachment of a clot that has already formed

From our experience we are convinced that the only rational therapy of phlebothrombosis is application of a ligature between the area in which the clot is located and the heart In patients in whom the process seems to be localized in the region of the calf and with the exception of patients who have undergone a pelvic operation, it is our policy to expose the superficial femoral veins bilaterally and, if a clot cannot be demonstrated at the level of the junction of the superficial femoral with the common femoral vein to ligate the superficial vein If however, a clot is found at this junction, thrombectomy is performed the vein is ligated, and the wound is closed, after which the inferior vena cava is ligated In patients in whom phlebothrombosis develops after a pelvic operation vena caval ligation is recommended as the primary procedure We have observed embolization in 11 patients who had previously had clots removed that were located proximal to the termination of the superficial femoral vein We do not advocate ligation of the vena cava or superficial femoral vein as a prophylactic measure or for the postphlebitic syndrome We believe that these procedures should be reserved for those patients in whom it can serve as a life saving measure Application of a ligature between the area of phlebothrombosis and the heart will prevent migration of a loosened thrombus to the heart and lungs

In patients with suppurative thrombophlebitis and evidence of showers of septic emboli into the general circulation or in those in whom pulmonary embolization has occurred ligation of the venous system on the cardiac side of the thrombotic process is indicated It is dramatically effective as a means of averting a possible fatality, and the postoperative sequelae can be made consistent with normal activity by the conscientious use of compression bandages and later compression stockings periodic bed rest with elevation of the extremities and use of phenylbutazone for evidence of acute recurrent thrombophlebitis should it occur

It must be emphasized that the ideal treatment of venous thrombosis is prophylaxis, particularly in phlebothrombosis Prophylactic measures include early ambulation, forced contraction of muscles of the legs, particularly forced plantar flexion of the foot against a resistance, deep breathing, avoidance of tight abdominal binders and prevention or correction of ileus Prompt institution of adequate therapy in both phlebothrombosis and thrombophlebitis results in prompt subsidence of symptoms and prevention of sequelae

## Wound Complications

Postoperative wound complications usually consist of hematomas infection or impaired healing with wound dehiscence, or evisceration Postoperative hernias usually result because of one or a combination of these early complications Hematomas, if uninfected, often require no active therapy If there is evidence of localized collection of blood in the wound in contradistinction to interstitial extravasation into the perimetry of the wound evacuation is indicated As many cutaneous sutures should be removed as are necessary to permit evacuation of the clot which acts as a wedge that separates the edges of the wound

Significant infection of an operative wound of the abdomen is almost invariably secondary to contamination of the wound at operation It is evidenced by pain tenderness swelling redness and even fluctuation of the wound and requires removal of sutures and drainage Barring a breach in technique such contamination results from introduction of infection from the outside as in penetrating wounds or from soiling of the wound with material from the abdominal viscera The poor blood supply of the subcutaneous fat renders it particularly susceptible to such an infection Because of the great likelihood of anaerobic infection of the thick adipose layer in obese patients

whenever the abdominal wall may have been contaminated or whenever the gastrointestinal tract has been opened it is desirable to institute prophylactic measures These consist in delayed closure of the skin and subcutaneous fat layer (Fig 4-4) The peritoneum and fascia are carefully approximated with interrupted cotton sutures (cotton is preferable to silk because the latter is much more likely to cause persistent sinuses in the presence of infection) Cutaneous sutures are omitted but heavy sutures inserted at some distance from the wound edge pass through the deep fascia and then emerge at some distance from the opposite wound edge and then are inserted through both wound edges (near far suture) but are not drawn taut and tied The wound is loosely packed with fine mesh gauze and the far near sutures are loosely tied with bow knots After three to four days the wound surface is much more resistant to infection and the wound can be closed with reasonable assurance of satisfactory healing As a bedside procedure after administration of morphine the bow knots are untied the gauze strip that has been moistened with saline is removed and the sutures are tied snugly The total period of hospitalization is not prolonged by the secondary closure the sutures being removed on the seventh or eighth postoperative day and in many instances convalescence is shortened by averting a wound infection One of the particular dangers of such an infection is that it is usually anaerobic and causes severe phlegmon of the abdominal wall

Extrusion of serous or serosanguinous fluid from an abdominal wound demands investigation because of the possibility of wound disruption Whereas subcutaneous seromas occur occasionally especially if the subcutaneous layer was not approximated with sutures wound disruption is the more common cause of such drainage and it must be ruled out by digital examination of the wound In complete wound dehiscence the patient is usually aware that the wound ruptured

Although no wounds are invulnerable to wound separation there are some factors that may increase the incidence Longitudinal incisions such as the mid line paramedian and lateral rectus incisions are more liable to separation Such wounds are perpendicular to the lines of stress of the effective musculature of the

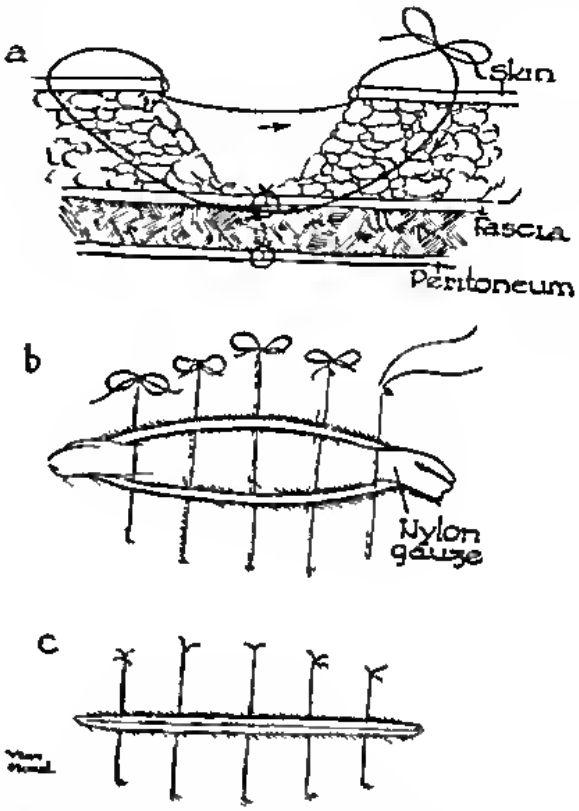


Fig 4 4 Technique of delayed closure of skin and subcutaneous layer (*a*) Cutaneous sutures extend beneath fascia to encircle this portion of the wound (*b*) Coaptation of wound edges is prevented by placement of nylon gauze in subcutaneous fatty layer and sutures are loosely tied with a bow knot (*c*) After three or four days closure is completed by loosening the sutures removing the nylon gauze and tying the sutures tightly

abdominal wall which is made up of the flat muscles and their fascial extensions the anterior and posterior rectus sheaths Transverse hockey stick gridiron and thoracicoabdominal incisions that are placed so as to parallel the lines of dominant muscle pull are much less susceptible to separation The pull of muscles which is considered to be a big factor in separa

tion of longitudinal incisions, actually favors closure of wounds of these latter types Debility, obesity, pulmonary complications causing coughing, distention, and use of absorbable sutures are all predisposing causes for wound separation Other factors are those that interfere with wound healing, such as hypoproteinemia, vitamin C deficiency, and wound infection

The extent of damage must be evaluated by digital exploration of the wound whenever it is possible to close the wound Those showing only outer fascial separation simply require resuture, which may be done with use of a local anesthetic In the presence of complete dehiscence with evisceration, a general anesthetic is the best means of controlling pain incident to placing of large through-and-through sutures Significant intestinal distention, often a contributory cause of wound disruption, may render closure difficult and possible only with considerable tension In such cases careful enterotomy at one or more levels with emptying of the bowel by passage of a suction tip or catheter through succeeding loops greatly facilitates the procedure and makes for smoother convalescence Rarely will a wound disrupt a second time, because as demonstrated by Sandblom there is no lag in wound healing after the second closure

## REFERENCES

Allen, J G, Emerson, D M, Barron, E S G, and Sykes, C Pooled plasma with little or no risk of homologous serum jaundice *J A M A 154* 103 1954

Altemeier, W A, and Coit, W Septic shock *Ann Surg 143* 600, 1956

Cannon, P R, Wissler, R W, Woolridge, R L, and Benditt, E P The relationship of protein deficiency to surgical infection *Ann Surg 120* 514 1944

Clark, J H, Nelson, W, Lyons, C, Mayerson, H S, and DiCarlo, F T Chronic shock, the problem of reduced blood volume in the clinically ill patient *Ann Surg 125* 418, 1947

Gliffton, E E, Grossi, C, and Siegel, M Hemorrhage during and after operation secondary to changes in the clotting mechanism, physiology and methods of control *Surgery 40* 37, 1956

Dock, W The undesirable effects of bed rest *S Clin North America 25* 437, 1945

Dripps, R D Immediate decrease in blood pressure seen at the conclusion of cyclopropaine anesthesia, "cyclopropaine shock" *Anesthesiology 8* 15, 1947

Fine, J The role of the intestine in traumatic shock *Am J Gastroenterology 29* 596, 1958

Gibbs, N M Venous thrombosis of the lower limbs with particular reference to bed rest *Brit J Surg 45* 209, 1957

Glenn, F Acute cholecystitis following surgical treatment of unrelated disease *Ann Surg, 126* 411, 1947

Harley, H R S Subphrenic abscess *Thorax 4* 1, 1949

Howland, W S, Schweizer, O, Boyan, C P, and Dotto, A C Physiologic alterations with massive blood replacement *Surg, Gynec & Obst 101* 478, 1955

Hurxthal, L M Postoperative shock due to adrenal insufficiency *S Clin North America 37* 715, 1957

Israel, H L, and Goldstein, F The varied clinical manifestations of pulmonary embolism *Ann Int Med 47* 202, 1957

Ochsner, Alton Venous thrombosis *Illinois M J 108* 213 1955

Ochsner, Alton The value of extraserous drainage in subphrenic abscess *Surgery 43* 319, 1958

Ochsner A and DeBakey, M Subphrenic abscess collective review and an analysis of 3 608 collected and personal cases *Internat Abstr Surg 66* 426, 1938, in *Surg, Gynec & Obst* May, 1938

Perlmutter, M Rapid test for adrenocortical insufficiency preliminary report *J A M A 160* 117, 1956

Randall, H T Water and electrolyte balance in surgery *S Clin North America 32* 415 1952

Sandblom, P The effect of injury on wound healing *Ann Surg 129* 305, 1949

Turnbull, R B, Jr Clinical recognition of postoperative enterococcic (staphylococcic) enteritis *J A M A 164* 756, 1957

MEDICAL COLLEGE LIBRARY UDAIPUR

CHAPTER 5

# HERNIA

*Amos R Koontz*

While much has been written about hernia for many decades the subject has been and still is one badly neglected by a large segment of our profession It is highly important, not only because nearly all classes of practitioners see hernias and are asked their advice about them but also because of the hundreds of thousands of hernia sufferers in the country Too many physicians consider hernia of little or no importance It must be remembered that it is highly important to the patient who has a hernia To consider hernia of little importance is to belittle their nature and potential consequences

Unless the physician consulted has a thorough knowledge of hernia he is not capable of giving his patient sound advice with regard to the handling of it It is a lack of knowledge that makes physicians steer their patients away from operation Almost all hernias should be operated upon soon after their appearance unless there is some special indication to the contrary Contraindications are indeed few these days yet a great many patients who intend to have their hernias operated upon are discouraged by the attitude of the physician who first sees them All too often a physician will simply advise his patient to get a truss Very few of them though will tell their patients where to go to get the truss and fewer still will have the patient come back after he gets the truss in order to make sure that it has been properly fitted Other physicians will tell their patients not to be concerned that the hernia will probably never give them any trouble nor require an operation Such attitudes have often been very costly to the patient Many patients in the prime of life who would have their hernias repaired if given proper advice often have their operations delayed by improper advice until they are in their 70s or 80s and have undergone the discomfort of wearing trusses for several decades only finally to come to operation because their trusses will no longer retain the hernias owing to the atrophy of tissues caused by wearing the truss and also to the deterioration of the tissues concomitant with advancing age

Undoubtedly the all too high recurrence rate in the past has been one deterrent to the operative repair of hernia on the part of both the profession and the laity The recurrence rate from various clinics has been reported as high as 10 to 25 per cent It is undoubtedly still entirely too high The reason for this is that the operation has in entirely too many cases been very poorly done That is still true of entirely too many cases One reason for this is that chiefs of service in a great many hospitals feel if only subconsciously that the operation is of little importance and turn it over to junior members of the staff without having them properly supervised in the actual operative technique employed and giving them entirely too much leeway in their choice of the operation The

younger the surgeon, the more fixed his ideas are apt to be with regard to the operation for hernia repair and the poorer his results Good results may be obtained by many methods, but no matter what method is employed fundamental principles must be understood and meticulous care must be exercised in every detail of the operation By so doing it has been demonstrated that the recurrence rate may be reduced below 1 per cent

## INGUINAL HERNIA

An inguinal hernia is a hernia that emerges through some portion of the inguinal canal Inguinal hernias are by far the most common of all types of hernia They are more common in the male than in the female However, Coley states that inguinal hernia forms 60 per cent of all ruptures in women and exceeds the total number of femoral hernias in both sexes.

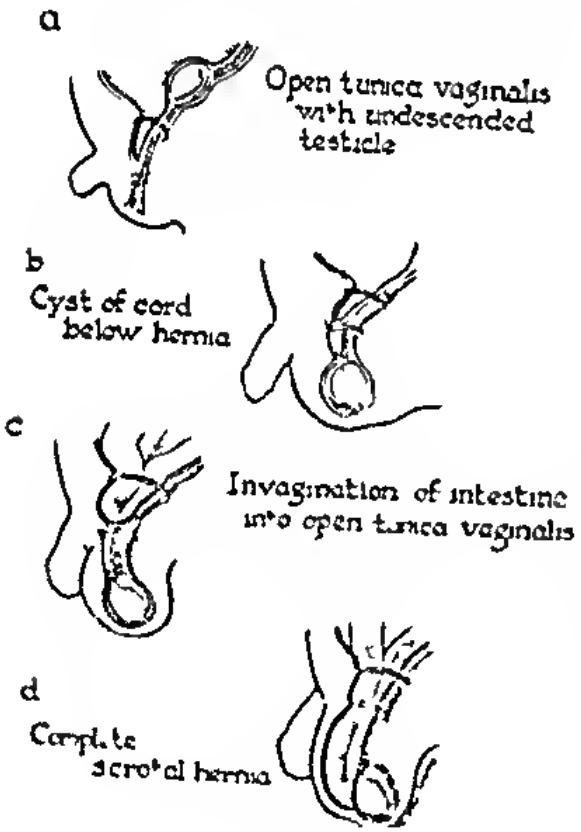


Inguinal hernias are of two types direct and indirect Approximately 92 per cent of inguinal hernias are of indirect variety The *indirect* inguinal hernia sac emerges through the internal ring traverses the inguinal canal in close apposition to the cord (or the round ligament in the female) and emerges at the external ring The neck of the sac lies external to the deep epigastric artery In *direct* inguinal hernia the sac comes directly through Hesselbach's triangle internal to the deep epigastric artery, appears at the external inguinal ring without traversing the canal and does not have a close relationship to the spermatic cord

It is the general consensus that all inguinal hernias are due to congenital defects The inguinal canal readily lends itself anatomically to the formation of such defects Embryologically the testicle is a retroperitoneal organ lying in the lumbar region As it descends into the scrotum the process of peritoneum that is carried with it normally becomes obliterated except the part immediately surrounding the testicle which remains as the tunica vaginalis There not infrequently, however persists an unclosed portion of the peritoneal process in the region of the internal ring the preformed sac of Coley which forms the basis for the future development of a hernia Even though no preformed sac exists it is obvious that a hernia may develop if the arrangement of the musculature around the cord is not tight Direct hernias most frequently occur in adults past 40 years of age They are seldom seen in children But even in direct hernias it is reasonable to suppose that there was a congenital weakness in the transversalis fascia or a direct hernia would not have occurred Hereditary tendency in hernias is well known They

external ring are *complete* These may appear as masses in the inguinal region or they may extend into the scrotum and become *scrotal* hernias Direct hernias seldom become scrotal hernias However I have operated on seven such cases In the female a complete hernia may enter the labium majus and be known as a *labial* hernia

it was present at birth The term congenital as used here applies to the anatomically completely open peritoneal tube with the testicle at the bottom of it rather than to the fact that it was present at birth

A hernia that has *forfeited the right of domicile* is one in which so much of the abdominal contents have become fixed in

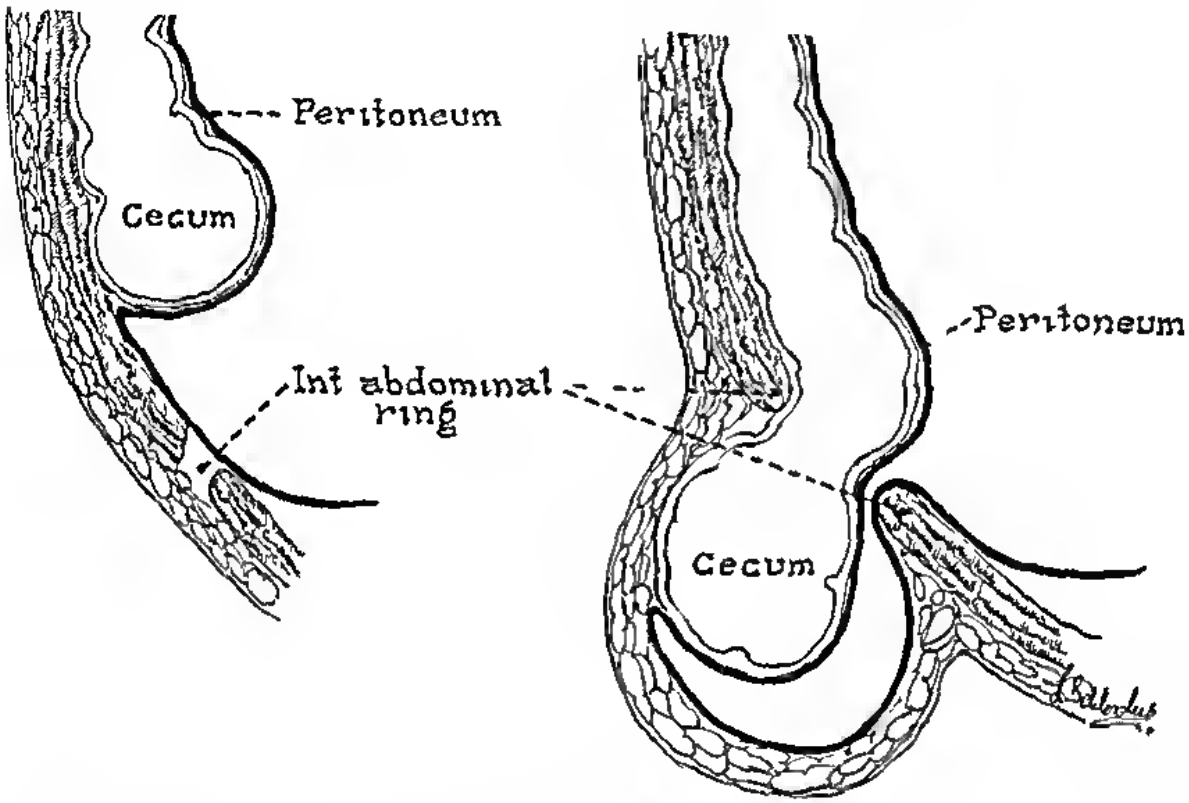


Fig 5 2 Development of a *sliding hernia* by *migration* of the cecum through the inguinal ring The posterior wall is retroperitoneal and when herniated is not included in the hernia sac (*Original drawing furnished by the author*)

A so called *congenital* hernia is a type of indirect inguinal hernia in which the peritoneal process does not close at all at the time of the descent of the testicle into the scrotum Owing to nonclosure of this process the testicle lies in the hernia sac which is really a tube of peritoneum connecting the testicle with the main peritoneal cavity, the testicle lying at the bottom of the tube There may be all degrees of closure of the peritoneal tube from the completely open one to only a small portion of the proximal end remaining open (Fig 5 1) The latter type in reality is a congenital hernia also in that

the hernia sac that there is not room enough in the abdominal cavity for the replacement of the exiled organs Such cases are now happily seldom seen but do occasionally occur

A *sliding hernia* is one in which a viscus forms part of the wall of the hernia sac The cecum sigmoid and bladder are the most common viscera involved The cecum and sigmoid are involved only in indirect hernias These hernias are formed by the large bowel sliding through the internal ring posterior to the peritoneum (Fig 5 2) Sliding hernias of the bladder are common in both direct and indirect

hernias but more common in direct Sliding hernia of the bladder is also common in femoral hernias

## Symptoms

Very often the first symptom is the accidental discovery of a mass in the groin Sometimes the patient, on lifting a heavy object, will experience pain in the groin as the first symptom of his hernia, thinking that the effort caused the hernia, which is seldom if ever the case Often patients have no discomfort at all or there may be a sense of dragging down discomfort In infants the appearance of a mass on crying is generally the first symptom As time goes on the hernia mass generally gets larger and effort causes discomfort in the hernia sac, probably owing to pinching of the peritoneum The size may increase until there is such a large mass in the scrotum that it interferes with ambulation

## Physical Signs

The external inguinal ring can be palpated by invaginating the scrotum with the index finger It has generally been considered that an *external inguinal ring of normal size* admits only the tip of the index finger This is questionable Many patients with much larger external inguinal rings which easily admit the entire end of the index finger never develop hernias Three large series of patients with enlarged external rings, with controls running up into the thousands have been studied (Gardner Chassin Ferguson) in men in the armed services and in college students. It was found that over a period of years there was no appreciable difference in the number of hernias developing in the men having large external inguinal rings and in those having small ones A normal external inguinal ring is therefore variable in size

The patient with a hernia may have no visible mass even while standing The surgeon then places his index finger in the external ring by invagination of the scrotum and has the patient either cough or hold his breath and strain down (the latter is often more effective) If a hernia is present he will feel a bulging impulse come down against the end of the finger The fact that he feels no such impulse, however, does not prove that the patient has no hernia I have seen patients with small scrotal hernias who on coughing had no impulse whatsoever when examined early in the morning, the hernia having retracted during the night and showing no signs at all After being on their feet for several hours, the hernia then emerges and is evident If there is a small mass in the groin with patient standing it can often be reduced even while he is standing If the mass is larger, and especially if it is scrotal, it cannot be reduced until the patient lies down Even then, such hernial masses are often not immediately reducible, but the patient gives the history that they reduce themselves during the night while he is in the recumbent position (unless they are completely irreducible)

## Diagnosis

Entirely too many men have been turned down for military service and for employment solely because of *enlarged external inguinal rings* This is a matter of education and there is reason to believe that the situation is improving

A hernial mass in the groin is generally easily differentiated from other tumors in that region An *inflamed hernia* which is rare might possibly be confused with *adenitis* As a rule the history and the physical signs are all that are necessary to establish the diagnosis

A *lipoma* of the cord may give all the physical signs of inguinal hernia As these lipomata are generally derived from preperitoneal fat and come through the internal ring they often cause an enlargement of that ring, even when no hernia sac is present They should therefore really be called *fatty hernias*, and, when operated upon a repair of the internal ring should be made to close the opening in the transversalis fascia through which they emerged

*Hydrocele* is generally easily distinguished from hernia by transillumination However a large hydrocele often so impinges itself upon the external inguinal ring that it is impossible to palpate that ring with the finger in order to determine whether a hernia is also present Occasionally when a patient with a hydrocele lies down the hydrocele fluid will disappear into the abdominal cavity This means of course, that the patient has a congenital hernia and not a true circumscribed hydrocele Sometimes also in patients with hydroceles the hydrocele fluid gradually disappears during the night which means that there is a small opening between a persistent processus vaginalis and a hernia sac *Hydroceles of the cord* are often more difficult to differentiate from hernia but this can usually be done by the fact that the mass is small nonreducible and fluctuant

*Femoral hernia* can usually be differentiated from inguinal hernia because it emerges below Poupart s ligament instead of above Poupart s ligament However some femoral hernias burrow subcutaneously overlap Poupart s ligament and are confused with inguinal hernias In such cases especially in fat people it may be difficult to determine whether the sac emerges above or below Poupart s ligament However, if the hernia is reduced and the finger placed in the external ring it can usually be determined when the patient coughs whether the hernia emerges through the ring or through the femoral canal The diagnosis may be difficult in the female owing to the greater difficulty in accurately palpating the external inguinal ring

Sometimes it is easy and sometimes difficult to differentiate between *indirect* and *direct* hernia before operation However if when the hernia can be reduced pressure is put over the internal ring (a point 1 cm mesial to the midpoint of a line running between the spine of the pubis and the anterior superior spine of the ilium) and the patient then coughs the hernia does not usually recur if it is indirect but does if it is direct This test may be confusing depending upon the patient s anatomy and is especially apt to be confusing if the patient has a *saddlebag hernia* (both direct and indirect) Often the diagnosis of a direct hernia is easy especially in thin people and can be made by looking at the patient across the room owing to the globular instead of pearlike shape of the mass The preoperative differentiation of these two types of hernia is largely one of academic importance in any case as the same incision is made for the repair of both hernias All patients should however be examined in both the erect and recumbent positions If in the recumbent position the patient can be made to contract his muscles some estimate of the strength of the floor of his canal can be made which is not possible while he is under anesthesia

*Sliding hernia* is not easy to diagnose before operation If a hernia has a large ring through which most of the contents of the hernia sac are easily reducible but part is not reducible a sliding hernia should be suspected

## Treatment

The nonoperative treatment of inguinal hernia will be mentioned briefly only to be dismissed curtly The only treatment to be considered except in the most unusual circumstances is operative treatment The injection treatment has a most limited usefulness so the injection technique will not be discussed here Trusses should not be worn in other than very exceptional circumstances Not only do they give only temporary relief they cause the formation of adhesions and bring about pressure atrophy of the tissues A hernia should be operated upon as soon as it appears Then the operation is simple and the prospects of a cure almost 100 per cent when the operation is properly done Many hernias are neglected for years and the older patient often in advanced years may find that even when wearing a truss the hernia cannot be retained Owing to discomfort partial obstruction or strangulation they have to come finally after years of dis

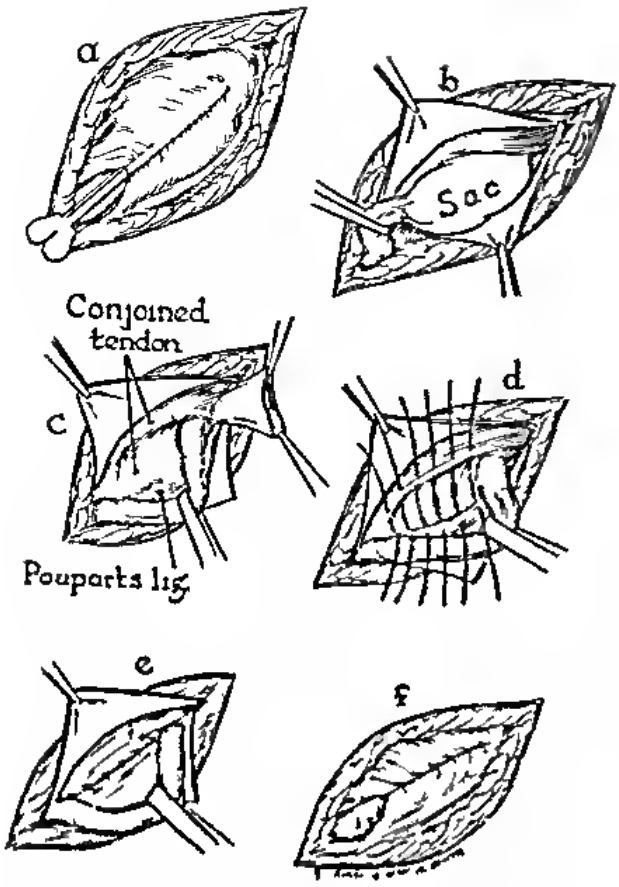


Fig 5 3 Bassini hernia repair An incision is made through the skin and subcutaneous tissues parallel and 1 cm superior to Poupart s ligament The aponeurosis of the external oblique is divided in the direction of its fibers down to the inguinal ring (*a*) Incision over a grooved director may facilitate this The sensory nerves lying just beneath the aponeurosis should be avoided (*b* and *c*) The hernia sac is separated ligated high and the excess removed (*d*) The cord is then separated and the defect or weakness in the transversalis closed (*e*) The conjoined tendon is then sutured to Poupart s ligament beneath the cord care being taken to secure satisfactory approximation at the pubis and at the internal ring (*f*) The aponeurosis of the external oblique the subcutaneous tissues and the skin are then approximated in separate layers over the cord (From Kelly and Noble *Gynecology and Abdominal Surgery* vol II 1914 W B Saunders Co Courtesy W B Saunders Co

comfort to operation Many of these patients would have been operated upon when the hernia first appeared if they had been so advised by their physicians If the physician can realize what happens to these hernias as the years go by, he will not be casual about the hernia and will advise operation as soon as it appears

THE CLASSICAL OPERATIONS For almost 70 years the Halsted and Bassini operations have been considered classical operations in the surgical world Halsted and Bassini published their operations simultaneously and independently The main difference between the operations was that Halsted transplanted the cord subcutaneously and Bassini transplanted it between the internal oblique muscle and the external oblique aponeurosis About ten years later Ferguson (1899) advocated leaving the cord in its bed and not transplanting it at all While Ferguson's operation has been widely used, it has not been as widely used as Halsted s or Bassini's. Lotheissen in 1898 first sutured the conjoined tendon to Cooper's ligament in the repair of both inguinal and femoral hernias This method has been popularized during the last fifteen years by the work of McVay and Anson The operation that has been most widely used throughout the world since Halsted and Bassini published their operations around 1890 has been the Bassini operation This was probably because Bassini was a European surgeon at the time when European medicine dominated the medical world, and Halsted was a young and relatively unknown American surgeon at a time when American surgery was really just beginning There are many indications however that the Halsted operation has gained popularity as the years have gone by A recent questionnaire sent to 286 of the leading surgeons in the country showed that the Bassini operation is the most popular for small indirect inguinal hernias while the original Halsted operation is the most popular for large indirect and for direct hernias

The Bassini operation which will undoubtedly continue to be done by a large number of people is shown in Figure 5-3 Figure 5 3 shows that the flaps of the aponeurosis of the external oblique are simply approximated not overlapped Overlapping was not done in either the original Halsted or the Bassini operation

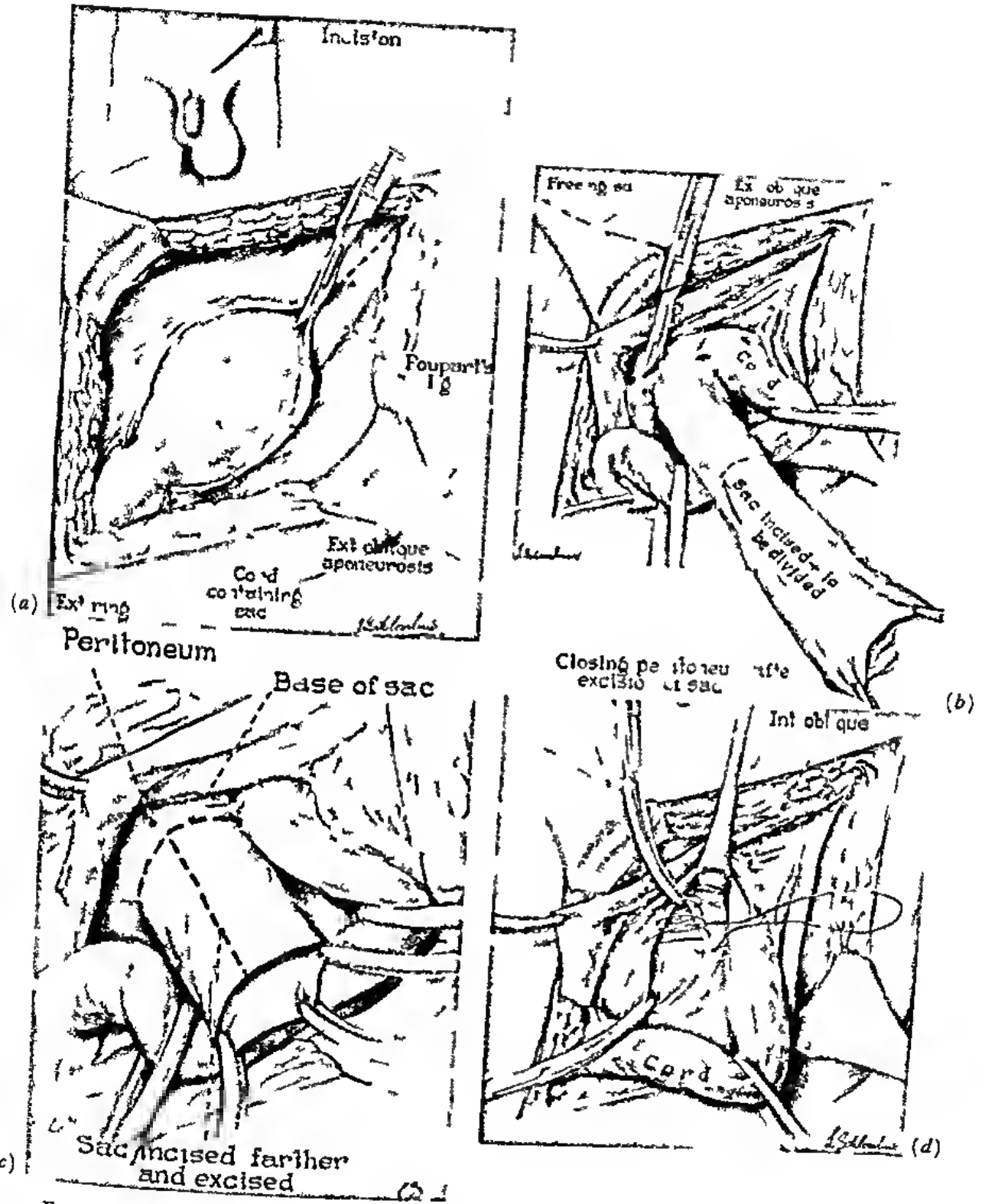


F g 5 4 Repa r of a large scrotal hern a Author s techn que (*a*) The top insert shov s a large scrotal hern a and the location of the inc s on roughly between the spine of the pub s and the anter or superior sp ne of the il um The lov er draw ng shows the incis on through the sk n subcutaneous tissue and the aponeurosis of the external obl que (*b*) The large sac has been d ssected free and part ally excised More easily to free the proximal part of the sac the sac will be aga n divided at the ind cated dotted l ne (*c*) The sac has been freed and will be exc sed at the peritoneal reflection ind cated by the circular dotted l ne (*d*) The sac has been exc sed and the per toneum is being closed w th a running suture of silk The defect is then closed by the technique illustrated in Figure 5 5

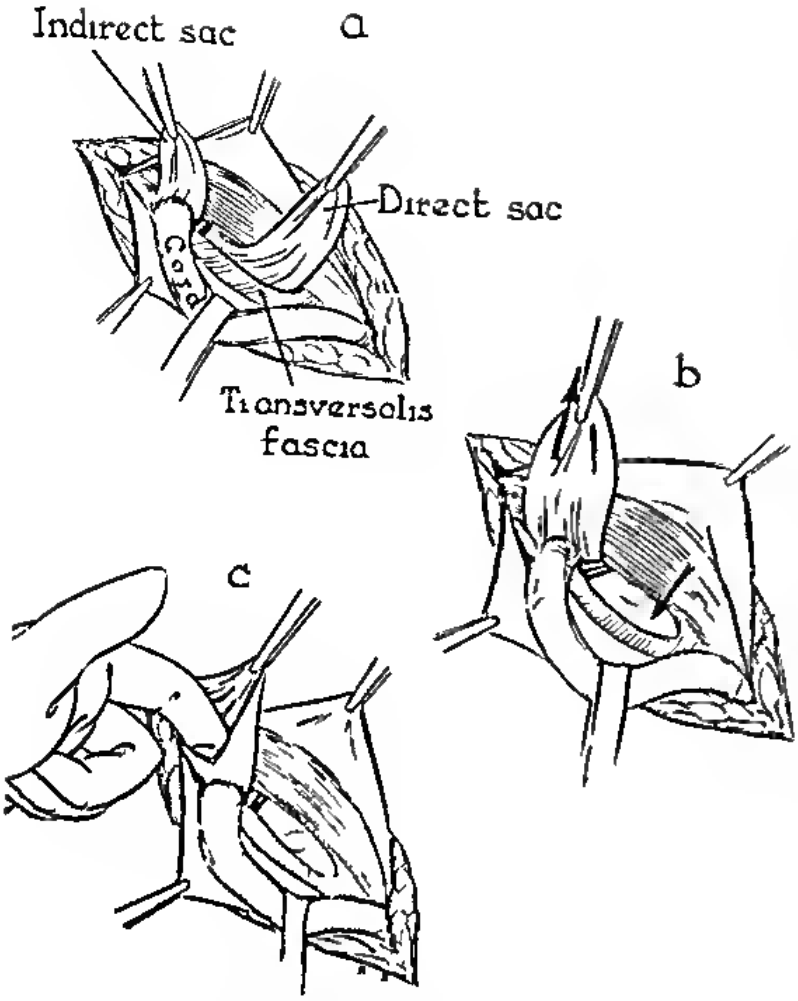


Fig 5 6 Combined indirect and direct (pantaloon) herniaplasty (Hoguet) (*a*) Demonstration of the two hernia sacs (separated by the inferior epigastric vessels) after the indirect sac has been dissected from the cord and the transversalis fascia incised over the direct sac (*b*) Traction upon the indirect sac converts the two sacs into a single one placed lateral to the inferior epigastric vessels (*c*) Demonstration of the now indirect sac which has been opened (*Redrawn from* B C Shackelford, *Surgery of the Alimentary Tract*, vol III 1955 W B Saunders Co *Courtesy* W B Saunders Co )

the base of the sac may be very broad and a simple transfixion and ligation cannot be done Here the sac should be excised and the peritoneum closed with a running suture of silk or cotton

In direct hernias with a small dome shaped sac it is not necessary to open and excise the sac The sac may simply be pushed in and the transversalis fascia closed over it by puckering interrupted or mattress sutures If the sac is large and very little transversalis fascia is present, it is best to open and excise it The opening in the peritoneum is then closed with a running suture of silk or cotton Occasionally instead of the sac being dome shaped owing to a general weakness of the transversalis fascia one finds a small opening in the transversalis fascia through which protrudes a pear shaped sac resembling an indirect sac The opening in such cases is often surrounded by some transversalis fascia Such a sac can be dealt with by transfixion and ligation

In the case of a saddlebag or pantaloon hernia in which there is both an indirect and a direct sac present, the direct sac may be converted into part of the indirect sac by the Hoguet maneuver (Fig 5-6) By this maneuver the direct sac, by exerting traction on the indirect sac with a finger on the inside of it, and by pushing the structures away from it with a piece of gauze may be converted into part of the indirect sac lateral to the deep epigastric vessels The direct sac having been eliminated there is only one sac to be dealt with

In many instances the LaRoque incision is most valuable in dealing with the sac This is true in primary hernias especially direct hernias when it is not certain whether an indirect hernia sac is also present It is also true in recurrent hernias in which the anatomy is greatly distorted and in sliding hernias In such cases the LaRoque incision is a great time saver It consists of a simple muscle splitting inc

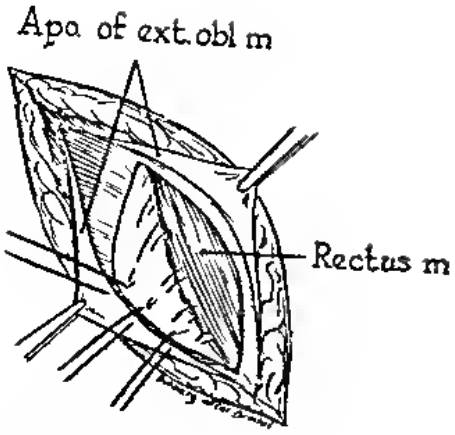


Fig 5 7 Halstead flap operation The aponeurosis of the external oblique has been reflected medially to its insertion into the anterior rectus sheath The remaining fascial covering of the rectus has been incised dissected free from the underlying muscle and turned laterally to be approximated to Poupart's ligament It is in effect a fascial transplant, one end of which is anchored to the rectus sheath (*Redrawn from* Kelly and Noble, *Gynecology and Abdominal Surgery* 1914 W B Saunders Co *Courtesy* W B Saunders Co )

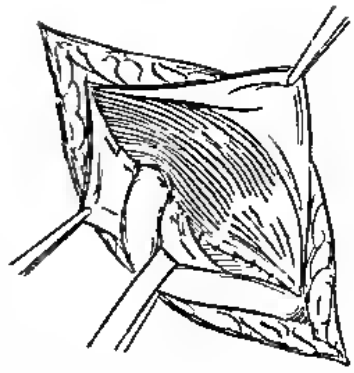

Fig 5 8 Cooper's ligament repair All the structures have been thoroughly cleaned of areolar and adipose tissue, including Cooper s ligament A relaxation incision has been made in the rectus sheath The conjoined tendon has been sutured to Cooper s ligament and the internal ring snugly closed Hesselbach s triangle may be strengthened with a sheet of tantalum mesh if desired Otherwise the operation is completed by approximation of the aponeurosis of the external oblique to Poupart s ligament beneath the cord and the skin and subcutaneous tissues in separate layers above the cord (*From* A R Koontz, *Surgery Gynecology* and *Obstetrics 92* 102, 1951 *By permission of Surgery Gynecology and Obstetrics* )

sion made about one inch above the internal ring, entering the peritoneal cavity at that point With a finger in the peritoneal cavity, the relations of the sac and the presence or absence of other sacs (including femoral) can easily be determined Often an indirect sac is hard to find by simply opening the structures of the cord It is easily found with a finger in the peritoneal cavity (If one suspects a small indirect sac into which the finger cannot be inserted, the site of the internal ring can easily be visualized by lifting the lower edge of the incision in the abdominal wall with a retractor ) Also, the floor of the inguinal canal can readily be palpated and its strength often more exactly ascertained than by examining it from the outside In recurrent hernias the method frequently prevents the injuring of important structures in searching for the sac from the outside through a scrambled anatomy This is especially true of hernias that previously have been operated on a number of times In sliding hernias the method makes the reduction of the bowel much easier and often makes a simple operation out of what would otherwise be a difficult one

CLOSING THE HOLE IN THE TRANSVERSALIS FASCIA In small indirect inguinal hernias, especially in young people, the floor of the inguinal canal often is strong except for the opening in the transversalis fascia through which the sac protrudes With the sac open, the strength of the floor of the canal can be tested before it is excised from both the inside and the outside Zimmerman believes that closing the hole in the transversalis fascia is all that is necessary in these cases After the sac has been disposed of, the transversalis fascia is closed with interrupted sutures, snugly closing the structures around the cord This method will undoubtedly cure a great many hernias, especially in young people with strong fascia, and no further plastic repair is necessary If there is any doubt, however, further repair should be made as indicated below

Some authors advocate simply closing the opening in the transversalis fascia in

this In addition, placing the cord between good layers of supporting abdominal wall interferes with the growing together of such structures as the internal oblique muscle and external oblique aponeurosis, and it seems reasonable to believe that these united structures will form a firmer buttress against intra abdominal pressure than if they have the cord interposed between them

An objection often raised to the subcutaneous transplantation of the cord is that it destroys the obliquity of the canal It is true that the canal is oblique to start with, but if the obliquity of the canal does not prevent the occurrence of a hernia, how can the preservation of its obliquity prevent the recurrence of a hernia? It must be remembered that in order for an indirect hernia to recur, it must emerge through the internal ring Once it has emerged through the internal ring, the hernia is a *fait accompli* and the position of the external ring has no bearing on this already accomplished fact

Another objection that has been raised to the subcutaneous transplantation of the cord is that its presence in this position might cause some tenderness especially in thin people I have never seen this occur and I have not been able to find any other surgeon who has seen it occur Occasionally in operating for bilateral inguinal hernia, I have transplanted the cord into the Bassini position on one side and into the subcutaneous position on the other side None of these patients has noticed any difference in the two sides

REMOVAL OF THE TESTICLE The presence of the spermatic cord is undoubtedly the reason for the far greater number of inguinal hernias found in the male than in the female The presence of the cord is probably the greatest obstacle to the cure of inguinal hernias in the male The only reason for removing the testicle is to get rid of the cord In spite of the presence of this structure penetrating the abdominal wall, I believe that most hernias in the male can be cured without sacrificing the cord This is undoubtedly true of the ordinary run of the mill type, but I believe it to be true also of the more difficult inguinal hernias Some surgeons refuse to operate on difficult recurrent hernias unless the patient agrees to have the testicle removed on that side I no longer ask this question for two reasons In the first place, one cannot tell whether removal of the testicle will be necessary or not until he finds what the anatomical situation is at the time of operation In the second place, most patients flatly refuse to have the testicle removed, or, if they accede to the request, do so with great reluctance In the occasional recurrent hernia the cord is found surrounded by scar tissue of such cartilaginous consistency that it is impossible to secure a satisfactory closure of the surrounding structures about the cord In these cases the presence of the cord would invite another recurrence Burdick and Higinbotham showed years ago that the cord may be resected, leaving the testicle in place Grace and Johnson showed that occasional atrophy of the testicle may be avoided if the testicle is not removed from its bed Removal from its bed destroys the collateral circulation The cord may be simply transfixed and ligated at both the internal and external ring and the intermediate portion resected Care should be exercised not to dissect the cord free too far beyond the external ring or the collateral circulation of the testicle will be interfered with After such an excision of a section of the cord some swelling and tenderness of the testicle occur This condition generally subsides within a few days or weeks A suspensory should be worn in the meantime

REDUCING SIZE OF CORD In a great many hernia cases the cord is very much enlarged in size This may be due to the presence of lipomata in the cord, or to hypertrophy of the cremaster muscle, especially in hernias of long standing In such cases it is highly important to reduce the size of the cord so that only a small structure, instead of a large one, penetrates the abdominal wall at the internal ring This can easily be done by removing lipomata and by excising hypertrophied cremaster muscle (see Fig 5 4)

CLOSING THE INTERNAL RING A great many hernias probably recur because the

it is possible that an indirect hernia was overlooked at the first operation At any rate, the method as depicted in the illustration has proved to be most satisfactory and is used in all cases in which there are either tissue deficiencies or very weak tissues It is especially valuable in recurrent hernias The lower edge of the tantalum gauze is sutured to Poupart's ligament making a V-shaped slit for the cord It is not necessary to suture the other edges of the gauze as the aponeurosis of the external oblique holds it securely in place Tantalum has the advantage over fascia in that it does not cause trouble in the presence of infection Fascia sloughs out if infection is encountered, while tantalum remains in place and the resultant cure is just as strong as if there had been no infection

APONEUROSIS OF EXTERNAL OBLIQUE Overlapping or imbrication of the aponeurosis of the external oblique has been pretty generally used in inguinal hernia repair since Lucas-Championniere and Andrews published their methods I believe that the practice should be abandoned because seldom can the imbrication be made without tension, which is highly undesirable Of course, if the flaps of the aponeurosis are so loose that imbrication can be accomplished without tension, it should be done to take up the slack in the roof of the canal In large hernias with poor tissues the external inguinal ring is large and the aponeurosis of the external oblique is poor in that area so that successful overlapping is difficult or impossible in the area where strength is most needed But the roof of the inguinal canal is not the important part in preventing hernia recurrence It is obvious that the floor is the important part and that if the floor is not strong, a recurrence is invited If a new hernia appears through the floor of the canal, the patient already has his hernia no matter how strong the roof is In those patients with poor tissues the floor of the canal can be strengthened by the use of tantalum gauze, as indicated above, and it does not become highly important to depend upon the overlapping of a weakened aponeurosis of the external oblique to reinforce the repair at its lower end

COOPER S LIGAMENT REPAIR Following the publication of Lotheissen (1898), Cooper s ligament was little, if any, used in this country in inguinal hernia repair Following the publication of McVay and Anson (1942), the operation obtained a vogue in this country for a period of years There is reason to believe that it is not now as widely used as formerly, although a few surgeons use it routinely When the conjoined tendon is strong and there is enough relaxation, it can be brought down to Cooper s ligament very conveniently as shown in Figure 5-8 When this is done, it effectually blocks the point of egress for direct hernias and for femoral hernias However, if the conjoined tendon is weak or has to be brought down to Cooper s ligament under tension separation of those structures will result In deciding whether to use Cooper s ligament in hernia repair the anatomy of the particular case should be studied and then it should be determined what method will give the strongest repair, and that is the method that should be selected If it is believed that the repair will be stronger by the use of Cooper s ligament, it should be used If it is believed that the repair will be stronger by the use of some other method, that by all means should be used

The Cooper s ligament repair is especially valuable in those cases in which the inguinal ligament has been cut at a previous operation or in which it is frayed or weak I believe that its routine use is improper anatomically in spite of the seemingly logical argument of McVay and Anson that to suture the conjoined tendon to Poupart s ligament is to transpose fascia planes, the conjoined tendon being in the same fascia plane as Cooper's ligament while Poupart s ligament is in the same fascia plane as the fascia lata and the aponeurosis of the external oblique Even so, when the fascial structures are strong in Hesselbach's triangle, those structures have to be disrupted in order to expose Cooper's ligament so as to suture the con-

joined tendon to it This is not desirable It is also very undesirable to suture the conjoined tendon to Cooper's ligament without exposing the ligament In the first place, if any intervening structures are left between the conjoined tendon and Cooper's ligament firm healing cannot be expected In the second place, doing, one has to use care in order to avoid injuring the mesenteric vessels After the bowel has been freed, if only a small amount of bowel is involved, it can be easily reduced through the internal ring and the hernia repaired as usual However, if very much bowel is involved in the wall of the sac, it is often difficult

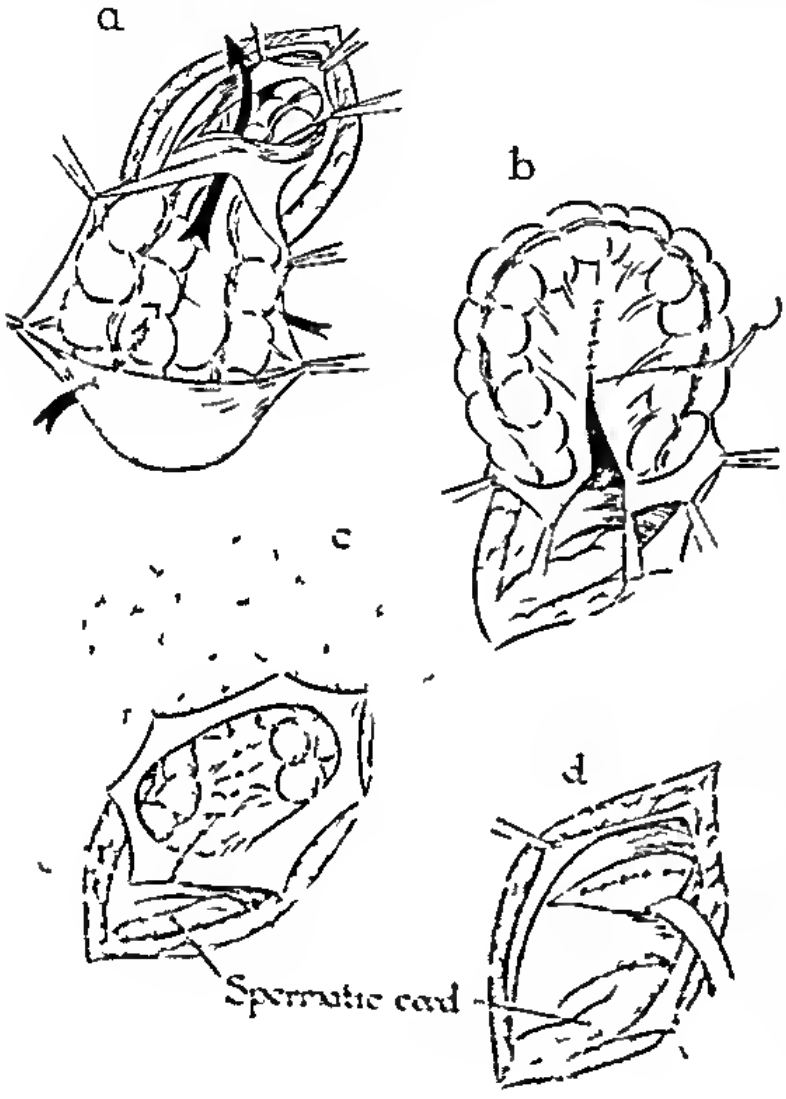


Fig 5 9 The La Roque maneuvers In a sliding hernia the sac must be opened far anteriorly to prevent invasion of the lumen of the bowel The hernia is reduced by separation of the posterior wall of the viscus from the posterior parietal wall and delivery of the viscus through a muscle splitting incision (La Roque) (*a*) made proximal to the internal inguinal ring After the viscus has been delivered through the La Roque incision the hernia sac is pulled behind the viscus (*b*) to give the sliding portion a peritoneal covering and the entire organ is then placed within the peritoneal cavity (*c*) Closure of the peritoneum through the La Roque incision (*d*) is followed by the usual hernia repair (*From C Williams Annals of Surgery 126 613, 1947 Courtesy J B Lippincott Co*)

hernia reduced, but in dealing with the sac after the reduction has taken place The method, as lucidly described by Williams, is illustrated in Figure 5 9

I have had an occasional case of large scrotal sliding hernia in which the mass of herniated bowel was so large that it could not be reduced through the internal ring even when a LaRoque incision had been made, and traction was exerted from above and taxis from below In these cases I have had to cut the internal oblique muscle in order to get the bowel reduced The method used is illustrated in Figure 5 10

*Sliding hernia of the bladder* is not uncommon in inguinal hernias, especially direct hernias In dissecting the sac free the bladder fat is easily recognized and one can easily prevent injuring the bladder wall However I have operated upon three cases in which there was a sliding hernia of a diverticulum of the bladder The diverticulum consisted of only mucosa, which had penetrated all the other coats of the bladder to form the diverticulum In all these cases the diverticulum was entered in dissecting it free from the sac before its presence was recognized The fact that only mucosa formed the wall of the diverticulum made it practically impossible to recognize the condition beforehand In these cases the diverticulum was excised, and the bladder wall closed with catgut in the mucosa and silk in the muscle coats Catgut was used in the mucosa in order to prevent the formation of stones, which might have occurred had a nonabsorbable suture been used A retention catheter was kept in place for a few days

COMBINED RIGHT INGUINAL HERNIOPLASTY AND APPENDECTOMY Patients often inquire if the appendix cannot be taken out at the same time that a right inguinal hernia is repaired My practice is not to do this as a routine procedure because of the possibility (although slight) that an infected wound may complicate the hernia repair However, if the patient has a history of attacks of appendicitis, the appendix should be removed This can usually be done very easily by extending the hernia incision upward only slightly and making a muscle splitting incision at McBurney's point I recently operated on a case in which the patient's appendix

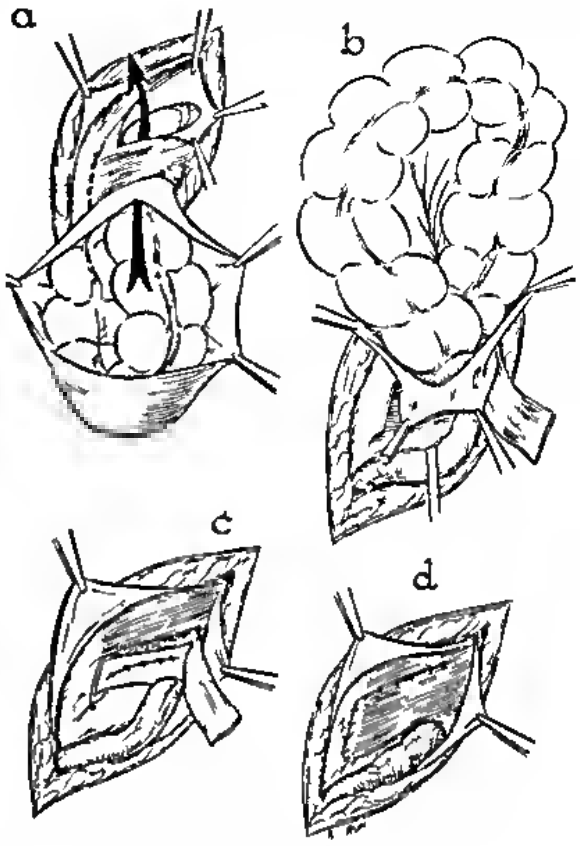


Fig 5 10 Reduction of an incarcerated hernia When reduction of an incarcerated hernia through the original sac seems unlikely without damage to the contents a La Roque incision (*a*) can be made superior to the internal ring When pull push manipulation fails (*b*) incision of the fascia along the rectus sheath (*c*) with release of a flap of muscle between the two incisions permits easy reduction Following removal of excess sac and closure of the peritoneum the muscle fascia flap is reapproximated with interrupted sutures (*d*) and the hernia repaired in the usual manner (*From* A R Koontz *American Surgery 18* 81 1952 *Courtesy* Williams and Wilkins Co )

had been giving him more trouble than his hernia In attempting to get his appendix out through the incision just described I found it impossible because I could not possibly reach the end of his appendix even by enlarging the incision by cutting

across the lateral edge of the rectus sheath I found it necessary to do a right rectus incision and found the appendix reached up to the patient's liver (the longest I had ever seen) and was tightly bound down by adhesions all the way

OPERATION IN INFANTS AND CHILDREN The Ferguson operation seems to be the most popular in children Few surgeons ever transplant the cord A great many simply do a high ligation and incision of the sac without any plastic repair at all My practice is to do this and in addition to close the opening in the transversalis fascia through which the hernia sac has emerged The opening is often fairly large A few interrupted sutures close it effectively This simple precaution prevents the occasional recurrence

SUTURE MATERIALS Nonabsorbable suture materials should always be used in hernia repair The reason for making this categorical statement is that absorbable surgical suture (catgut) is unreliable as to the period of time in which absorption takes place and therefore cannot be depended upon to keep the important structures used in hernia repair in apposition until strong healing occurs This has been proved experimentally many times over and only recently by Madsen The use of the material is therefore only to court disaster and invite recurrence Catgut is unreliable after six days and Harvey has shown us that it takes ten to fourteen days for healing to occur It takes about two months for the wound to become firmly consolidated Parson showed that the recurrence rate at the Presbyterian Hospital in New York was four times as great when catgut was used as when silk was used

Of nonabsorbable sutures silk and cotton are the best now available There is

removed This can often be fished out with a crochet needle or a very small ear curet If this method is not successful the sinus tract can be opened under local anesthesia and the offending suture removed This is undoubtedly a drawback and an inconvenience However, it is much better to be slightly inconvenienced in the occasional case than to run the risk of a large incidence of recurrence by the use of absorbable sutures

In order to obviate the trouble that silk or cotton causes in the presence of infection, some surgeons use wire as suture material in hernia repair If fine wire is used, there is a tendency to cut through the tissues If large wire is used it may cause as much trouble as silk or cotton in the presence of infection

One has occasionally to operate on a recurrent hernia that has had draining sinus tracts, sometimes for years as a result of previous operations In such cases no attempt should be made to cure the hernia until the infection is cleared up The first thing to do is to open the sinus tracts widely, remove any offending foreign body, and thus secure healing After healing has taken place, one should wait at least six months for the infection to subside before definitive repair of the hernia is attempted Even then there may be nidusses of the old infection left in the abundant scar tissue that one finds in these cases To obviate the possibility of further infection, I prefer wire as a suture material in the hernia repair Braided wire sutures do not tend to cut through as much as monofilament wire but they do tend to come untied Alternating sutures of braided wire and monofilament wire are a compromise and fine catgut for ligatures The use of silk or cot

found that the ends of the sutures should be left at least 2 millimeters long

## FEMORAL HERNIA

A femoral hernia (sometimes called crural hernia) is one that protrudes through the femoral canal, emerges below Poupart's ligament, and presents itself at the saphenous opening The femoral canal is bounded laterally by the femoral vein, mesially by the lacunar ligament, below by the pectineus fascia, and above by Poupart's ligament The femoral hernia emerges as a rule in the empty space between the femoral vein and the lacunar ligament Very rarely it may emerge anterior or lateral to the vessels It also has been known rarely to penetrate the lacunar ligament and almost equally rarely to perforate the aponeurosis of the pectineus muscle and present itself between the muscle and its fascia, thus simulating an obturator hernia

The *sac* is empty in the majority of cases Omentum is the most frequent finding in the sac, the next most frequent being ileum The appendix is not infrequently found in the sac Other viscera sometimes found are the colon, cecum, ovary fallopian tube, uterus, testis, etc Sliding hernia of the bladder is common I encountered two cases of sliding hernia of the sigmoid, rare in femoral hernia

Femoral hernias are more frequently found in women than in men, although inguinal hernia is much more common in women than femoral hernia Approximately one third of femoral hernias are in males and the other two thirds in females

The condition is rare before the age of puberty It is definitely a disease of adult life A few cases do occur, however, in children and one case has been reported in a five-month old girl, in which the contents of the sac were strangulated ectopic endometrial tissue in an organized hematoma

Femoral hernia is not infrequently associated with inguinal hernias, either direct indirect or both The incidence is variously reported as from 2 to 11 per cent Bilateral femoral hernias are found not too infrequently Femoral hernia appearing after an operation for inguinal hernia may very well have been overlooked at the time of the primary operation

The incidence of femoral hernias as

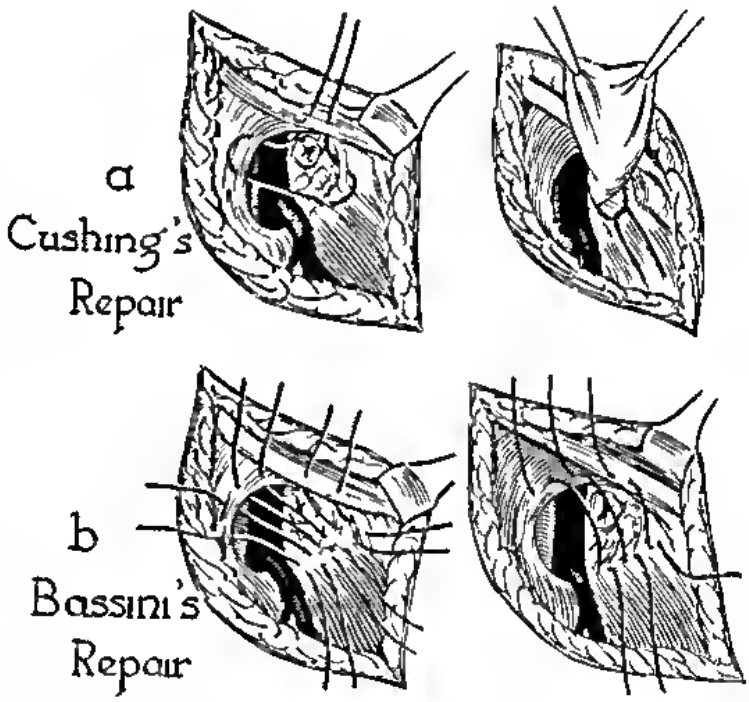


Fig 5 11 Repair of a femoral hernia through a femoral approach Either a longitudinal or transverse incision centered just below Poupart s ligament is satisfactory After isolation of the sac it is opened unless empty, ligated high and the excess removed The defect is closed either with (*a*) a purse string (Cushing) or (*b*) interrupted mattress sutures (Bassini) using pectineus fascia, falciform process and Poupart's ligament (*From* Watson s *Hernia* 3d ed, 1948 The C V Mosby Co *Courtesy* The C V Mosby Co )

compared to inguinal hernias is difficult to arrive at; figures vary from 1 to 31 to 1 to 50. That the incidence of femoral hernia is less than is generally supposed is shown by the fact that only 139 cases were operated upon at the Johns Hopkins Hospital over a 21-year period and only 90 cases at the Henry Ford Hospital over a 20-year period

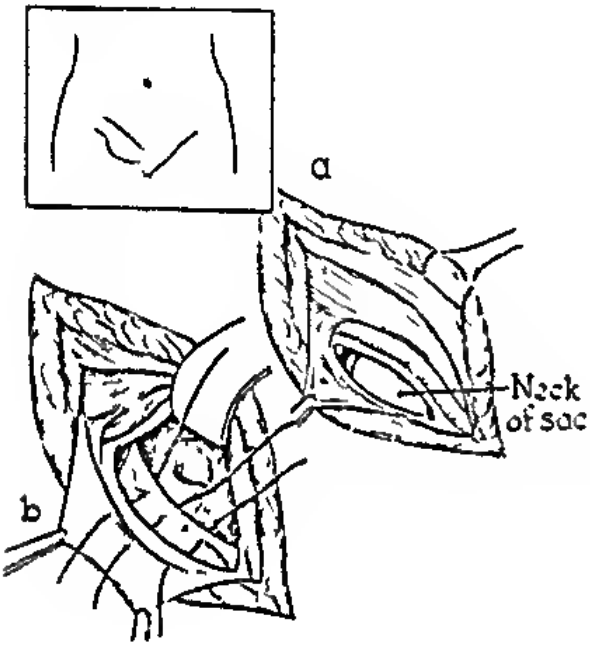


most of the series reported Dean concluded from his high mortality rate and recurrence rate that if a patient with a femoral hernia wanted to be offered better than a 70 per cent chance of remaining alive, and better than a 50 per cent chance of being cured, operation should be performed early. The high mortality rate, of course, is due principally to a delay in the operation after strangulation occurs

The current belief that the recurrence rate for femoral hernias is low is wrong The over-all recurrence rate is around 10 per cent, and is much higher for strangulated hernia. The rate for recurrent femoral hernia is exceedingly high, running as high as 60 per cent in one series

## Symptoms

The symptoms in femoral hernia are generally less pronounced than in inguinal hernia unless the hernia is strangulated Often the only symptom is swelling There may be some dull pain There may be urinary symptoms if the bladder is involved, as frequently it is Even in strangulated femoral hernia the symptoms may be referred entirely to the abdomen without the patient being aware that a hernia is present

diagnosis between inguinal and femoral hernia has been described above Both subinguinal *adenitis* in the region of the saphenous opening and a strangulated femoral hernia are tender and may be confused A *psoas abscess* (now fortunately rare) often points in the femoral region and may be confused with femoral hernia The presence of fluctuation and the general nature of the mass should serve to differentiate the two conditions A saphenous varex can usually be identified by pressing on the vein below the mass in which case the mass empties itself and collapses reappearing when the pressure is released

## Treatment

All femoral hernias should be operated upon as soon as possible owing to the high incidence of strangulation if left alone There are two main approaches the femoral and the inguinal

FEMORAL APPROACH This operation was first described by Bassini in 1894 and like most operations has had many modifications since Figure 5 11 illustrates the various steps in the procedure It may be done either through a vertical incision over the femoral canal or through an oblique inguinal incision The sac is isolated opened and contents reduced Often the contents are tightly wedged in the sac and it is necessary to cut the lacunar ligament in order to reduce them Some surgeons cut Poupart s ligament also but this does not seem necessary After the sac has been ligated and excised repair is made by employing the pectineus fascia falciform process and Poupart s ligament to close the femoral opening,

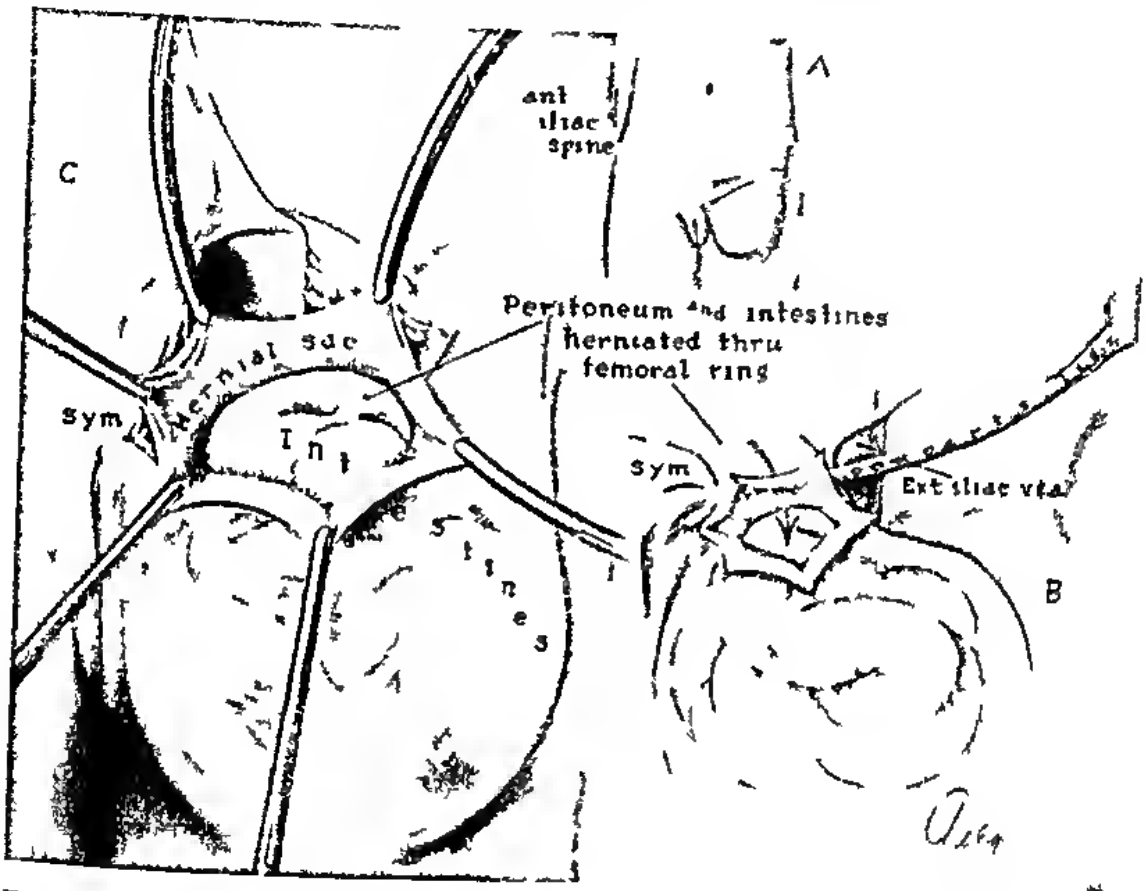


Fig 5 13 Showing skin incision made for a huge recurrent femoral hernia The intestines prolapse through the femoral canal into the large hernial sac and replacement begins with the segment in the ring

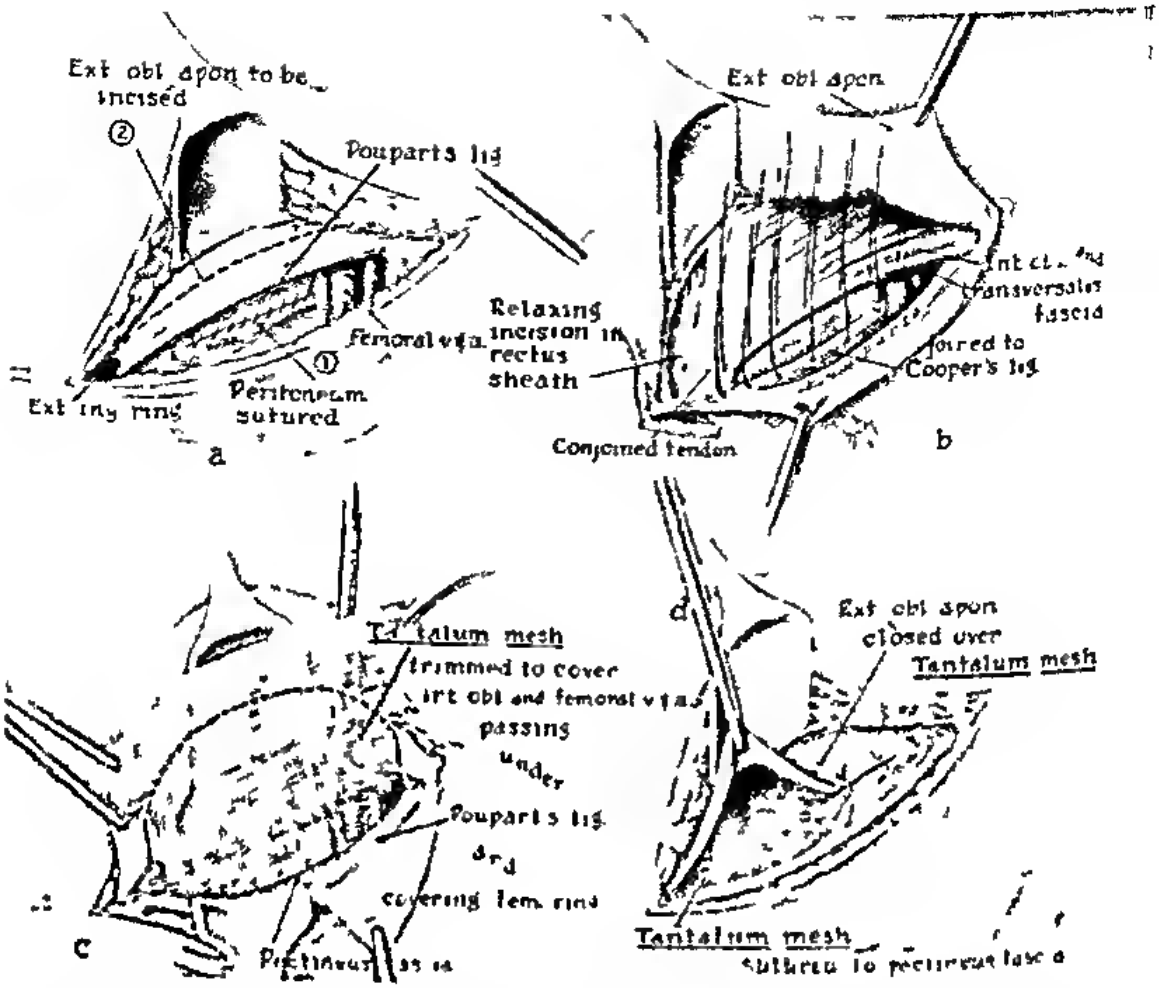


Fig 5 11 *a*) The sac has been excised and the peritoneum closed between the femoral vessels laterally and the lacunar ligament mesially The dotted line shows where the incision will be made in the aponeurosis of the external oblique (*b*) The aponeurosis of the external oblique has been opened exposing the conjoined tendon Sutures have been placed to bring the conjoined tendon and Cooper's ligament together A relaxation incision has been made in the sheath of the rectus muscle to avoid tension when the sutures are tied (*c*) A piece of tantalum gauze has been placed over the suture line uniting the conjoined tendon and Cooper's ligament The lower edge of the tantalum gauze has been sutured to the pectineus fascia lateral to Cooper's ligament A slit has been made in the tantalum just mesial to the femoral vessels so that the gauze in that region may be depressed to fit the contour of the parts The dotted line in the gauze shows where the excess will be trimmed away before it is tucked under the aponeurosis of the external oblique If too much gauze is left, the gauze will buckle as the two leaves of the aponeurosis are sutured over it (*d*) The aponeurosis of the external oblique is being sutured over the tantalum gauze Should there be any dead space (and there usually is) between the aponeurosis and the tantalum it is filled in with Gelfoam From A R Koontz, *Annals of Surgery* 149 627, 1958 *Courtesy* J B Lippincott Co

canal may be blocked off by suturing Poupart's ligament to Cooper's ligament (Ruggi Moschcowitz) Often Poupart's ligament comes down to Cooper's ligament without very much tension The operation does have the drawback however of suturing a semirigid ligament (Poupart's) to a completely rigid ligament (Cooper's) If the sutures are under too much tension they will not hold

Or the femoral canal may be blocked off by bringing the conjoined tendon down to Cooper's ligament (Lotheissen Mc Vay) This method is superior to the Ruggi operation if the conjoined tendon is strong and can be brought down without tension with the aid of a relaxation incision in the sheath of the rectus muscle

The inguinal approach has advantages over the femoral approach in dealing with strangulated or incarcerated hernias Resection is much more easily carried out I consider it the method of choice in recurrent femoral hernias

DIFFICULT RECURRENT FEMORAL HERNIAS Recurrent femoral hernias are more difficult to cure than recurrent inguinal hernias Figure 5 13 illustrates the method used in repairing a large recurrent femoral hernia After the sac has been dealt with (Fig 5 14) the aponeurosis of the external oblique is opened a relaxation incision is made in the sheath of the rectus muscle and the conjoined tendon is sutured to Cooper's ligament A piece of tantalum gauze is then placed over the suture line uniting the conjoined tendon to Cooper's ligament The lower edge of the tantalum is sutured to the pectineus fascia lateral to Cooper's ligament A slit is made in the tantalum just mesial to the femoral vessels so that the gauze in that region may be depressed to fit the contour of the parts Excess gauze is trimmed away The remaining sheet is flattened out and covered with the aponeurosis of the external oblique just as in inguinal hernia repair Should there be any dead space (and there usually is between the aponeurosis and the tantalum) it is filled in with Gelfoam

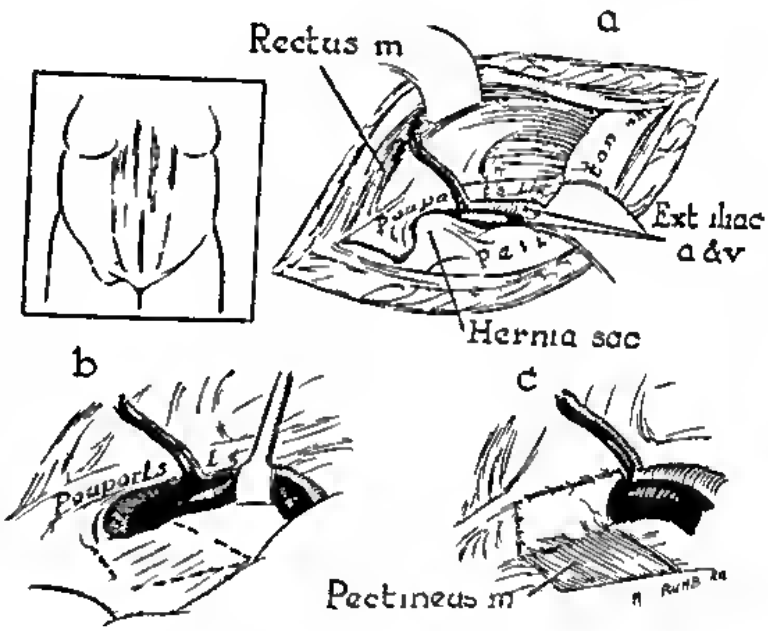


Fig 5 15 Repair of a femoral hernia by the Henry approach (*Inset*) A mid line incision is made from the umbilicus to pubis down to the peritoneum (*a*) The peritoneum and bladder are depressed and stripped away without opening to expose the femoral rings (*b* and *c*) Following excision of the sac recurrence is prohibited by approximation of a flap of fascia elevated from the pectineus muscle to Poupart's ligament (*From* A K Henry *The Lancet* vol I 532 1936 *Courtesy The Lancet*)

HENRY APPROACH This approach is illustrated in Figure 5 15 A mid line incision is made from the umbilicus to the symphysis The unopened peritoneum is stripped from the sides of the bladder and from the pelvic wall This brings into view the neck of the femoral hernia sac and enables it to be withdrawn from the femoral canal and excised A flap of pectineus fascia is then cut from below Cooper's ligament reflected forward and

sutured to Poupart's ligament, thus obstructing the entrance to the femoral canal In the case of bilateral femoral hernia, the method saves making two incisions

ZIMMERMAN APPROACH Another method of repair has been described by Zimmerman and others (Fig 5 16) This

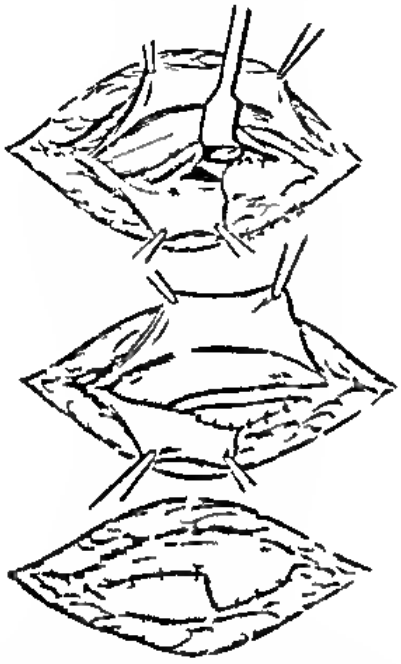

Fig 5-16 Repair of femoral hernia by the method of Zimmerman Following an inguinal approach to the femoral ring the opening is closed with a flap of fascia fashioned from the lower edge of the aponeurosis of the external oblique to Cooper's ligament The aponeurosis of the external oblique is then closed with interrupted sutures (*From Zimmerman and Anson Anatomy and Surgery of Hernia* 1953, The Williams and Wilkins Co Courtesy Williams and Wilkins Co

## UMBILICAL HERNIA

### Definition

An umbilical hernia is a hernia protruding through the umbilical ring It may be congenital, owing to failure of closure of the umbilical ring, or acquired, owing to a ring that has pathologically opened probably because of congenital weakness in infancy, childhood, or adult life Umbilical hernias may conveniently be divided into three varieties (1) congenital hernia of the umbilical cord, (2) umbilical hernia in infants and young children, and (3) umbilical hernia in adult life

### Congenital Hernia of the Umbilical Cord

This condition (Fig 5-17) is, of course, congenital and results from an improper closure of the two opposing sides of the abdominal parietes, leaving a defect at the site of the umbilicus There is a protrusion

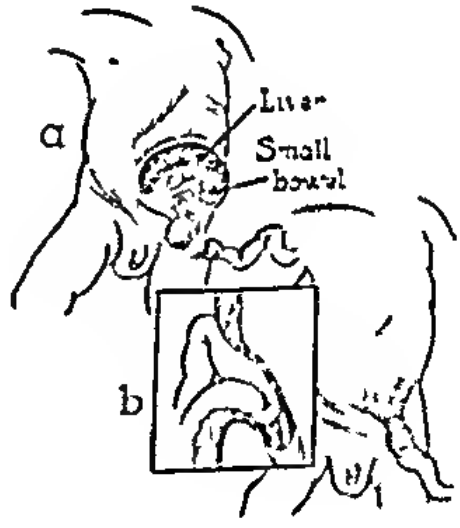

of abdominal viscera into the cord at the site of the umbilicus Strictly speaking this condition should possibly not be called a hernia as the viscera have never entered the abdominal cavity The hernial covering consists of a layer of Wharton s jelly and the peritoneal sac The size varies from that of a hickory nut to that of a child s head or larger The sac may contain loops of large or small intestine or even the liver and spleen including the major portion of the abdominal contents This type of hernia may be associated with other congenital defects such as harelip

## Umbilical Hernia in Infants and Young Children

Such hernias generally appear during the first year of life The condition occurs with about equal frequency in the two sexes The exciting cause is increased intra abdominal pressure This may be due to traumatism such as a fall or to whooping cough flatulence phimosis or constipation A large umbilical cord may act as the predisposing cause of delayed closure of the umbilicus These hernias are small as a rule and the sac is either empty or contains simply omentum Occasionally bowel is found in the sac

## Umbilical Hernia in Adults

These hernias are probably due to a congenital defect Undoubtedly there are contributory causes such as weakening of the abdominal wall from obesity and the relaxation of the abdominal wall that comes from pregnancy A completely closed but thinned-out umbilical scar might yield to increased abdominal pressure under such circumstances The condition is more common in women than in men and is found especially in obese women The hernias vary in size from very small to enormous They may become pendulous and hang down below the pubis As a rule the ring is not very large The sac may be empty but usually contains omentum sometimes almost all the omentum It may also contain large and small bowel and may even contain the stomach liver gallbladder spleen or pancreas As a rule the contents of the sac are densely adherent to the sac and require careful dissection in being freed Large sacs may contain numerous loculi each of which has adherent contents Strangulation is fairly frequent In addition to the umbilical defect there is generally a diastasis of the rectus muscles and in a large hernia the diastasis often amounts to a very wide separation

## Symptoms

Small umbilical hernias are often symptomless However umbilical hernias like epigastric hernias may cause symptoms entirely out of proportion to their anatomic importance This is especially true of small umbilical hernias containing irreducible omentum The constant tug on the omentum or on intestine if present causes various symptoms such as nausea epigastric pain and local pain If bowel is included in the sac symptoms of partial intestinal obstruction may occur Very large umbilical hernias cause discomfort from the sagging of the large sac

## Diagnosis

The fetal umbilical hernia is usually easily diagnosed at a glance However if the hernia into the umbilical ring is small the only indication of it may be a thickening of the cord at the umbilicus In such cases care should be taken to tie off the cord far enough away from the thickening to avoid injuring abdominal contents

The diagnosis in infants and small children is generally made by the parents noticing a bulging in the umbilicus when the child cries In older children and adults the diagnosis is usually easy and is made by the nature of the mass If the sac is small and empty the open umbilical ring can be palpated with the end of the index finger A *sebaceous cyst* of the umbilicus may be confused with umbilical hernia as may also a *urachal cyst* Occasionally a small *epigastric hernia* may occur so close to the umbilicus as to be mistaken for an umbilical hernia

## Treatment

CONGENITAL HERNIA OF THE UMBILICAL CORD. These cases should be operated upon within a few hours after birth. Otherwise, rupture of the sac and spreading peritonitis occurs, or if the sac does not rupture, infection of the abdominal wall soon occurs

*One-stage operations* can be used for small omphaloceles The sac is cut away,

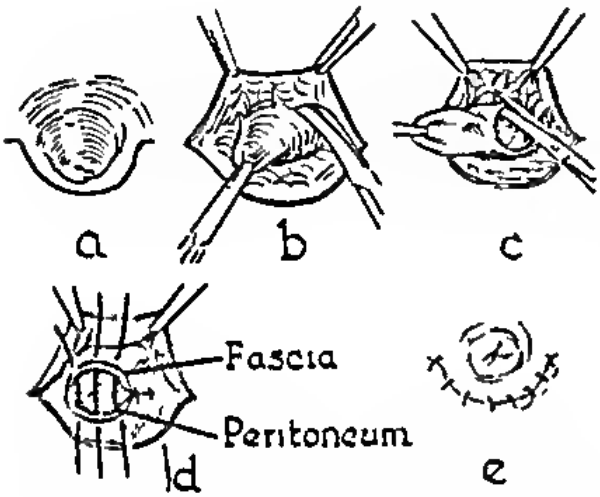


Fig 5-18 Repair of an umbilical hernia in a child in whom retention of the umbilicus is desirable (*a*) A semicircular incision is made beneath the umbilicus (*b* and *c*) The hernia is dissected free and excised (*d*) The defect is closed with interrupted sutures through the peritoneum and fascia Imbrication of the fascia provides a much stronger repair (see below) but is not essential in young children (*e*) The skin is closed with interrupted sutures (*From* Stone and McLanahan, in Lewis, *Practice of Surgery*, vol VII, Chap IX, 1955 W F Prior Co *Courtesy* W F Prior Co )

freshening the edges of the ring in order to obtain better healing The peritoneum and posterior rectus sheath are closed simultaneously with a continuous suture

of the hernia sac, the sac is left intact, the skin flaps are undermined widely, and brought together over the sac. This leaves a protective covering over the hernia contents and prevents handling of the intestines It, of course, does not cure the hernia. It does leave a huge bulge, which is unsightly but compatible with life The mortality rate is high when the defect is large The operation, however, is easier and attended with less mortality the earlier it is done, because then the intestine is not distended with food or air and is more readily reducible. At a much later stage, months or years later, a repair of the huge defect in the abdominal wall can be attempted By this time the abdominal cavity will have enlarged and will possibly receive the abdominal contents Even then the repair of the abdominal wall may be very difficult and may tax the ingenuity of the surgeon to his utmost

UMBILICAL HERNIA IN CHILDREN. Small umbilical hernias in children will often heal spontaneously during the first few years of life. During the first six months they may be kept strapped with adhesive tape, and then the strapping discontinued Strapping is useless after the first year of life In one series of cases in which small umbilical hernias in infants were strapped, and a control series not strapped, the incidence of spontaneous healing was only slightly greater in the strapped cases than in those nonstrapped. It was, therefore, thought that the strapping had probably done the mothers more good than the patients If the hernia has not healed spontaneously by the time the child is three years old, operation is indicated Umbilical hernias in infants and small

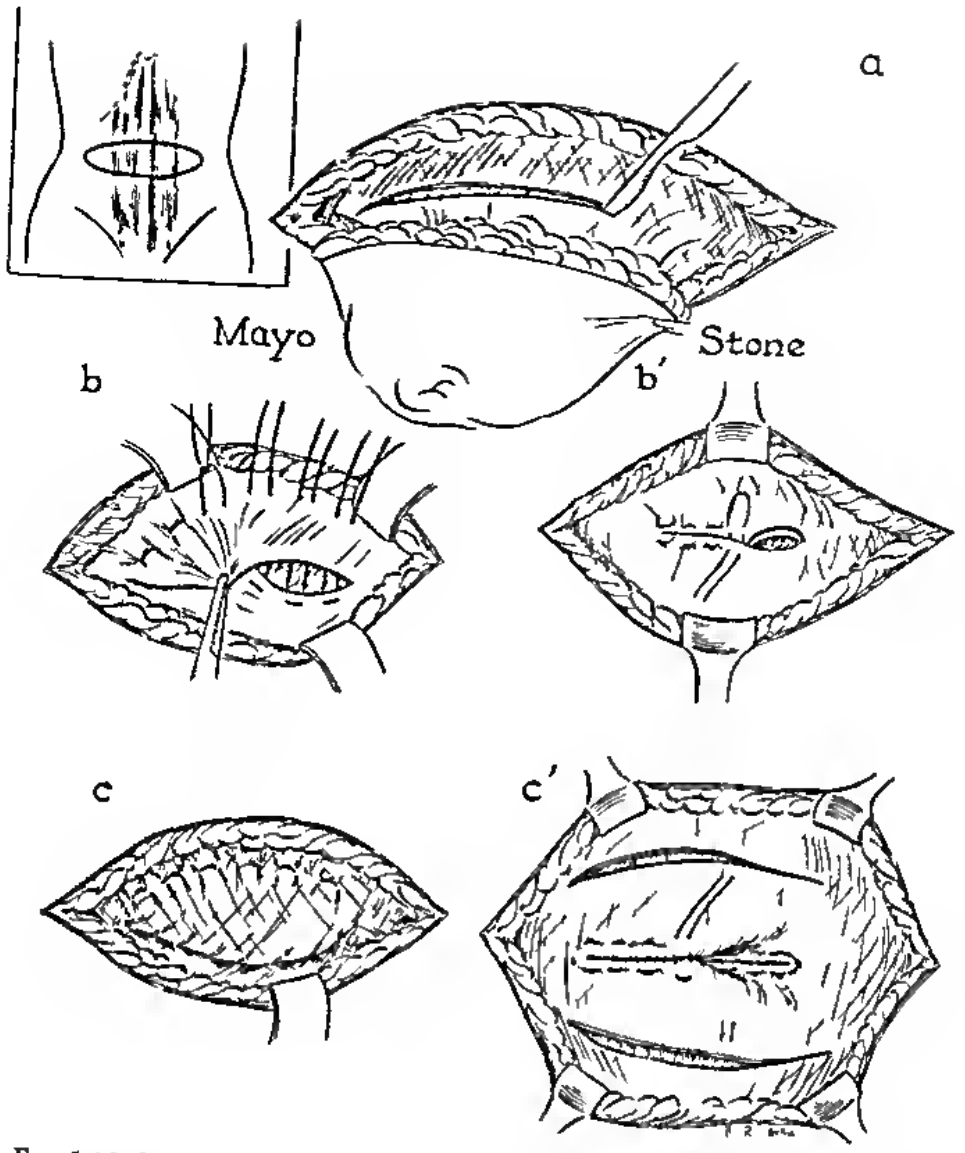


Fig 5 19 Repair of an umbilical hernia in an adult The elliptical incision should extend far beyond the rectus sheath on both sides (*inset*) (*a*) Following dissection of the sac the defect can be closed by the vest over pants technique of Mayo (*b* and *c*) or by two layers of imbricating sutures—Stone (*b* and *c*) Relaxation incisions may facilitate repair by the Stone technique In a very large umbilical hernia temporary subcutaneous drainage and external elastic compression may be provident for a few days (*a b c* from Kelly and Noble *Gynecology and Abdominal Surgery* vol II 1914 W B Saunders Co *Courtesy* W B Saunders Co *b* and *c* from Stone and McLanahan in Lewis *Practice of Surgery* vol VII Chap IX W F Prior Co *Courtesy* W F Prior Co )

certain amount of psychic trauma A semicircular incision is made below the umbilicus (see Fig 5 18) the skin and the umbilicus are dissected free from the sac, the sac is excised and the defect in the abdominal wall sutured with interrupted sutures placed in a transverse direction

UMBILICAL HERNIA IN ADULTS For many years the Mayo operation (1899) has been the popular operation for umbilical hernia This operation greatly improved the results in umbilical hernia repair and also reduced the mortality rate immeasurably In 1926 Stone introduced a new operation for umbilical hernia that has been very successful

*The Mayo Operation* (Fig 5 19) A transverse elliptical incision is made, in

or pancreatitis The usual symptoms are dragging pain in the epigastrium nausea and vomiting These symptoms may be present when there is no true hernia sac but only a small hump of preperitoneal fat protruding through a small opening in the linea alba Apparently any tug on the peritoneum in this region causes exaggerated symptoms

### Diagnosis

The diagnosis depends on a careful examination of the entire linea alba This should be a part of every abdominal examination but especially in those patients who have symptoms referrable to the epigastrium In obese people the hernia is sometimes not easy to find Having the recumbent patient raise his head without support thus putting the abdominal muscles and fascia on tension is an aid If the hernia is not reducible a small mass can generally be palpated If it is reducible a small opening may be felt in the fascia and an impulse on coughing The irreducible hernia is usually tender

While an epigastric hernia may simulate the symptoms of various lesions of the upper abdomen, it should not always be taken for granted that the finding of an epigastric hernia is entirely responsible for all the symptoms Before operation it is sometimes wise to have a gastrointestinal or gallbladder x ray series to rule out lesions of those organs I once operated on a patient with an unusually large epigastric hernia whose symptoms were suggestive of peptic ulcer I had had no gastrointestinal studies before operation but at operation discovered that he had a large gastric ulcer, so I did a partial gastrectomy in addition to repairing his hernia As the epigastric hernia was large it had probably caused very few symptoms and all of the patient s symptoms were probably due to his gastric ulcer

### Treatment

Most primary epigastric hernias are small and easily cured by simple operation A transverse incision is made, the sac dealt with and the fascia closed in a transverse direction as this produces less tension than closing it in a vertical direction

Incisional epigastric hernias especially if large are very difficult to cure because of the rigidity of the adjacent thoracic cage The method of dealing with these hernias will be treated under Incisional Hernia

## INCISIONAL HERNIA

Incisional hernias are the only types of hernias (except traumatic diaphragmatic hernias and a few other rare traumatic hernias) that are not even remotely connected with any developmental defect These hernias occur through surgical incisions They almost never occur through McBurney incisions unless infection has been present and drainage established because in such incisions the contraction of the surrounding muscles tends to close the wound rather than open it They are fairly common in most other types of abdominal incisions including mid line incisions both above and below the umbilicus and high and low rectus incisions They also occur in transverse abdominal incisions However as vertical incisions are much more used in abdominal surgery than transverse incisions more hernias occur in such incisions McVay has presented a strong case for the transverse incision by showing that the majority of the aponeurotic fibers of the transversus abdominis and internal oblique muscles run in the transverse direction and these fibers tend naturally to close a transverse abdominal incision rather than open it which is not the case in vertical rectus incisions On the other hand a recent survey of abdominal incisions showed the percentage of hernias occurring through transverse and vertical incisions to be about the same

Undoubtedly many factors enter into the causation of incisional hernias A sloppy or faulty closure invites herniation Infection plays a prominent part by causing sloughing of the fascia The presence

quire special methods when the operative cure is attempted

Wound disruption comes in an entirely different category from incisional hernias and the causes are more acute Every surgeon has had a certain number of wound disruptions, no matter how carefully he has closed the wound and no matter what the nutritional state of his patient The principal causes are generally conceded to be postoperative coughing, vomiting, and distention

## Symptoms

Usually the first symptoms are the appearance of a mass or a sense of discomfort in the operative scar, or both As a rule these hernias rapidly increase in size The symptoms may be slight or very severe In the large hernias there is an uncomfortable sense of weakness and lack of security in the abdominal wall dragging down pain, digestive disturbances, constipation, and inability to engage in any sort of strenuous work The hernias may be pendulous, hanging down to the knees These cases often cause bladder symptoms owing to the bladder's being carried down over the pubis with the hernia sac In some cases the patients are made complete invalids

## Diagnosis

The presence of a mass or of a defect in the fascia with an impulse on coughing makes the diagnosis easy in early and small cases It is obvious at a glance in the larger cases It is not always easy, however, on physical examination, especially in obese people (in whom these hernias often occur), to determine the exact size of the defect in the abdominal wall Sometimes the hernia has a large sac that burrows subcutaneously and the actual opening in the abdominal wall is not large On the contrary, it is also true that often the surgeon at operation finds the defect much larger than he expected to find it from his physical findings Small hernias are generally reducible Large ones may be irreducible because so much of the abdominal content is in the sac that the right of domicile has been forfeited

## Treatment

The only real treatment is operative, although belts of all sorts may be worn The operation for small incisional hernias is easy and the wounds may be closed in layers as usual The operation for large incisional hernias is more difficult and for the very large ones it is very difficult indeed Many of the large ones occur in obese people and the operation is complicated by the obesity The majority of these obese people will do nothing worth while to reduce their weight

The incision for the large hernias depends upon the location of the hernia In upper right rectus mid line, or left rectus incisions a vertical incision is usually the best For those in the mid line below the umbilicus, a transverse incision is generally the best incision In obese people the transverse incision may be made an elliptical one and often large pendulous masses of fat are removed through this incision For those in McBurney incisions the usual oblique incision is best

Often the defect is so large that it is either impossible to approximate the edges of the defect or they are brought together under great tension after relaxation incisions are made in the fascia in various places First the hernia sac should be exposed and the fascia cleaned well away from it in all directions so as to determine the nature of the muscle and fascia surrounding the defect Often relexation incisions can be made in the sheath of the rectus on each side of the defect, facilitating the approximation of the edges Far and near tension sutures of heavy braided silk (see Fig 5 20) are a great help in approximating the edges of these defects Although they are brought together under tension the far and near sutures distribute the tension so that it is not put in any one place and the usual disadvantages of suturing tissues under tension are minimized In such instances it is well to suture

which a new hernia developed at the edge of the implanted piece of tantalum because of the weakness of the fascia In large hernias large pieces of tantalum should be used In several cases I have used pieces a foot square literally covering the entire abdominal wall Cracks in the tantalum two or three years later have no effect on the fibrosis already produced

In large hernias in which there has been a wide dissection of the skin flaps the circulation of the mesial edge of the flaps (in vertical incisions) may be impaired by the wide undercutting of the flaps In such cases it is well to cut away an inch or two of the skin on each side of the incision in order to make sure that the circulation is good else some sloughing may take place As a rule there is plenty of skin anyway and there is no difficulty in sacrificing this much of it Also in those cases in which there has been a wide undercutting and especially when tantalum or cutis grafts are implanted there is bound to be some dead space and some accumulation of serum in the wound Unless these wounds are drained the serum may have to be aspirated a number of times A convenient method of preventing this is to put from two to four catheters through stab wounds in the lateral edges of the skin flaps and connect them to continuous suction for a few days This keeps the wound dry and promotes healing As a rule suction is discontinued in four days and the catheters shortened They are removed in six or seven days

In large incisional hernias in which the contents of the sac contain large quantities of intestines it is often impossible to get the contents of the sac back into the abdominal cavity because the abdominal cavity has decreased in size and the contents of the hernia sac have forfeited the right of domicile Even in those cases in which the hernia contents can be reduced very often the reduction of the contents increases the intra abdominal pressure and elevates the diaphragm to such an extent that the patient suffers severe circulatory and respiratory embarrassment In such cases the method of Goni Moreno of using artificial pneumoperitoneum preoperatively should be used The air can be very simply injected using a 19 gauge lumbar puncture needle and a large syringe with a two way stopcock It should be injected at several sittings before operation and the amount injected each time should depend on the patient s subjective

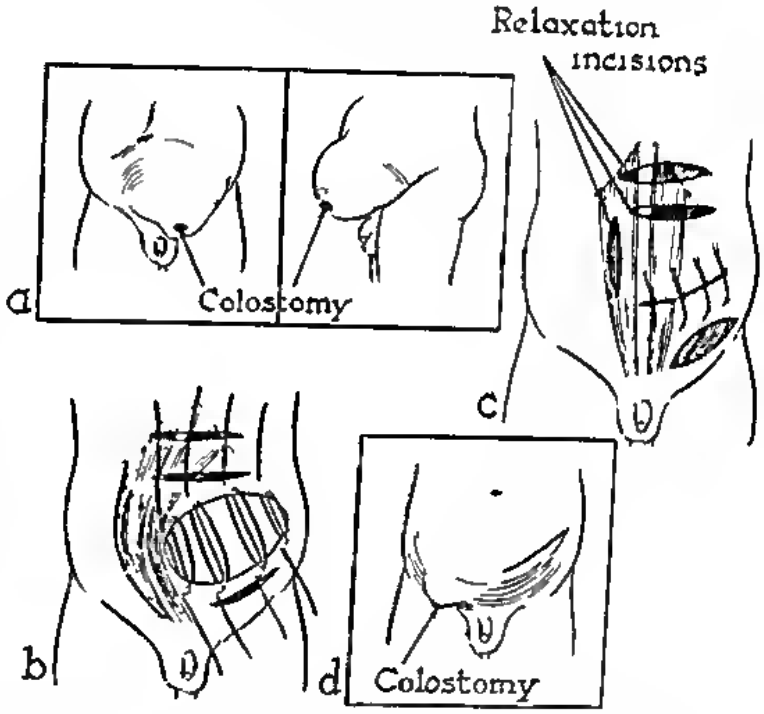


Fig 5 22 Repair of a hernia associated with a colostomy (*a*) by transplantat on of the colostomy through normal ab dominal w all and closure of the defect as one would any other incisional hern a (*b*) Relax ng incis ons in the fasc a over muscles at a d stance may permit closure without tension (*c*) and facilitate firm repa r (*d*) (*From* A R Koontz *J A M A 162* 1156 1956 *Cour tesy The American Med cal Associat on* )

Above the linea semicircularis however, the aponeurosis of the internal oblique splits to enclose the rectus muscle Below the linea semicircularis the posterior sheath of the rectus is absent It is because of this anatomic arrangement that Spigelian hernias occur most frequently at the linea semicircularis While these hernias do occur above this point, they are rare in the upper abdomen

Direct hernias are sometimes classed as hernias in the linea semilunaris I do not believe, however, that the classification is proper anatomically speaking In those cases in which the conjoined tendon has a normal low insertion, namely at the spine of the pubis, a direct hernia occurring lateral to a conjoined tendon so situated could not properly be called a hernia in the linea semilunaris A direct hernia occurring in a patient in which the conjoined tendon has a high attachment that is, enters the linea semilunaris a few centimeters above the spine of the pubis might possibly be called a hernia in the linea semilunaris although even in this case the hernia could hardly be considered as coming through the linea semilunaris but as being situated immediately lateral to it Certainly for all practical purposes direct hernias should be considered as entirely distinct entities from those occurring through the linea semilunaris above the inferior epigastric artery

Hernias in the linea semilunaris are generally small The sac is often empty and preceded by a lipoma as is the case with epigastric hernias The omentum and small intestine are the common findings when the sac is not empty Large intestine is sometimes found

### Symptoms

The symptoms in all the cases I have observed have been localized pain

### Diagnosis

The diagnosis is often difficult as a great many of these hernias are interstitial and therefore masked They come through the linea semilunaris but do not penetrate the aponeurosis of the external oblique muscle This is responsible for the difficulty in diagnosis Some however do come straight through the linea semilunaris and the small mass is readily palpable Larson s case was the largest I have seen reported and the sac measuring 14 × 6 cm contained omentum and sigmoid The fact that it did not penetrate the aponeurosis of the external oblique but was flattened out under it concealed the nature of the condition until it was revealed by operation The condition is probably not as rare as the reported cases would seem to indicate Pain in the region of the linea semilunaris especially in the lower third should make one suspicious of the condition even if a mass cannot be felt

### Treatment

A simple closure of the fascial defect is all that is necessary to cure these hernias

## INTERPARIETAL HERNIA

Interparietal hernias have been classified by Lower and Hicken as follows (1) Properitoneal hernia that type in which the hernial sac lies between the peritoneum and the transversalis fascia (2) interstitial hernia in which the sac lies between the transversalis fascia and the transversalis internal oblique or external oblique muscles and (3) superficial hernia in which the sac is situated between the aponeurosis of the external oblique and the integument

Of these three types the first and third are rare I have never seen one of the first type that I recognized I operated on one of the third type in a huge fat man in which an indirect inguinal hernia had come directly through the abdominal wall including the aponeurosis of the external oblique and presented itself in the subcutaneous fat instead of traversing the inguinal canal and emerging through the external inguinal ring The hernia was large and as it had not followed the

prefer to call it) in which either a part or the whole of the diaphragm is thinned out weakened and displaced upward by the abdominal viscera without there being any actual rupture of the structure itself This condition is probably congenital and might indeed be considered a hernia of the whole diaphragm or of that part which is weakened and thinned out

## Etiology

Diaphragmatic hernias may be divided into four types as follows (1) congenital (2) acquired but owing to a congenital weakness (3) traumatic and (4) inflammatory

CONGENITAL HERNIA Congenital hernias are due to congenital absence of a portion of the diaphragm At times almost the whole of the diaphragm is absent but even in these cases a small vestige of it may be found as a cuff of costal attachment. In these cases there is no sac and the abdominal contents lie naked in the thoracic cavity hernia diaphragmatica spuria

ACQUIRED HERNIA Patients who have a congenital weak spot at birth may develop diaphragmatic hernias (acquired) at various times in later life Most of these hernias have a sac hernia diaphragmatica vera. After the different muscular elements of the diaphragm have closed small gaps not infrequently remain closed only by peritoneum and pleura One of these is constant in front between the costal and sternal portions of the diaphragm and is known as the foramen of Morgagni There is another one behind the costal and lumbar portions known as the foramen of Bochdalek There may also be hernias owing to a not quite complete closure of the muscular or fascial elements of the diaphragm itself The most common type of acquired diaphragmatic hernia is the hiatus hernia which appears through the opening in the diaphragm for the esophagus (Fig 5 25a) Some of these hernias are due to a congenitally short esophagus These have a congenital defect in the diaphragm because of the thoracoabdominal position of the stomach The great majority of them however are not of this type but are acquired and are generally found in people over 50 years of age especially obese females Obesity is probably the most common cause producing the hernia through a congenitally weak spot Hiatus hernias are generally small but may be very large so that the whole stomach is found in the left side of the thoracic cavity I operated on one case in which the entire stomach was in the right side of the thoracic cavity I have heard of only one other such case The sac may be either paraesophageal or sliding (see Fig 5 25) Hernias through the aperture for the aorta and vena cava are also reported but are very rare

TRAUMATIC HERNIA The traumatic variety of diaphragmatic hernia is also of the false type in which there is no sac and the hernial organs lie naked in the thoracic cavity They are due principally to two types of injuries crushing injuries and perforative injuries The types of crushing injuries most frequently encountered are forceful doubling up of a patient with his head between his feet as in a landslide severe concussion of the chest as by a fall from a height fall across some object as a fence or the fender of an automobile striking the lower part of the thorax and being run over by a wagon or automobile The majority of perforative injuries are caused in war by missiles of various sorts going through the diaphragm Perforative injuries are also encountered as a result of gunshot wounds and stab wounds in civil life

INFLAMMATORY HERNIA Inflammatory diaphragmatic hernias may be caused by perforation of the diaphragm consequent to inflammatory processes of the digestive tract gastric or duodenal ulcer, rupture of a subphrenic abscess empyema or carcinoma

The great majority of diaphragmatic hernias (approximately 90 per cent) occur on the left side There are several reasons for this In the first place it is probable that the liver on the right side acts as a buffer to protect the diaphragm from the

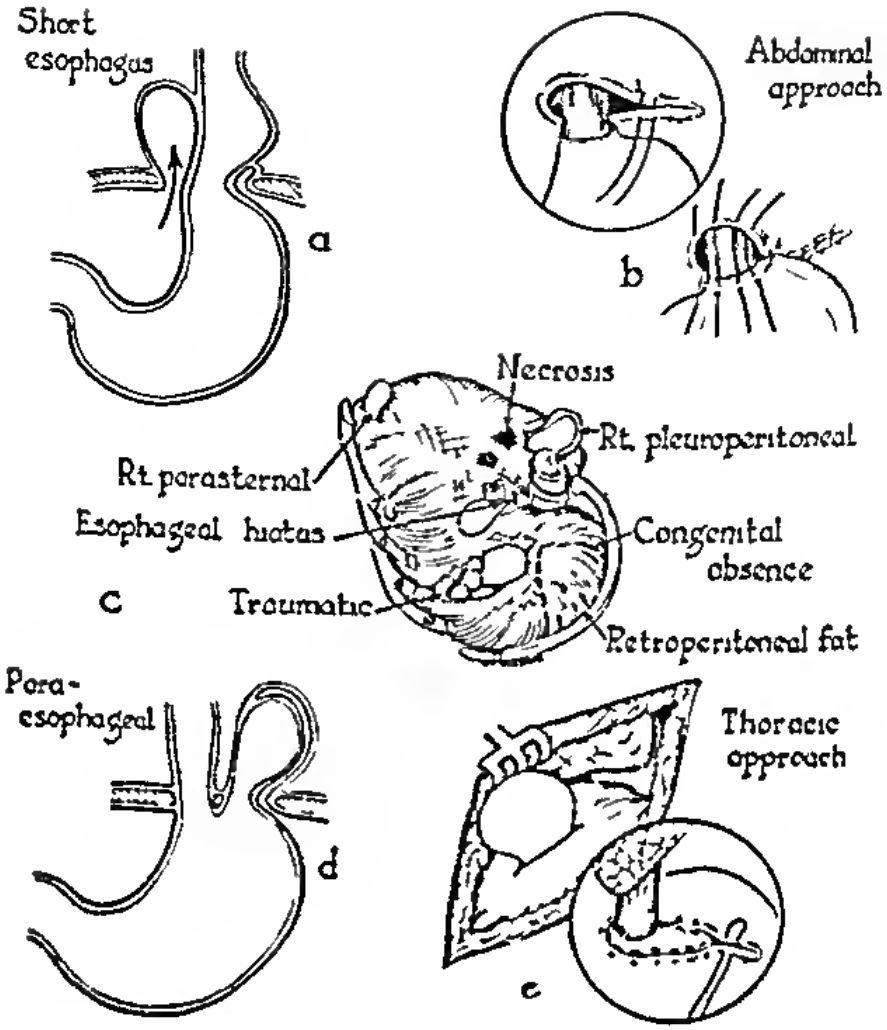
Short esophagus
a
Abdominal approach
b
Necrosis
Rt. pleuroperitoneal
Rt. parasternal
Esophageal hiatus
Congenital absence
c
Traumatic
Retroperitoneal fat
Para-esophageal
d
Thoracic approach
e

impact of the other abdominal viscera Another is the fact that in civil life most gunshot wounds or stab wounds occur on the left side The left side in gunshot wounds can probably be explained by the fact that the assailant is aiming for the heart of his victim In the case of stab wounds the left side is the most convenient location for the thrust of a righthanded assailant Finally, there are developmental reasons for the more frequent occurrence of diaphragmatic hernia on the left side The left side is the last to close and may either not close at all or close imperfectly and therefore be more susceptible to the forces of intra abdominal pressure both because of the weakness in the diaphragm and because there is no buffer on the left side such as the liver

Almost all abdominal organs have been found in the chest in diaphragmatic hernias They are as follows stomach, liver small intestine, colon, duodenum, pancreas, appendix, kidney and spleen In large hernias the herniated mass causes marked mediastinal displacement

In congenital diaphragmatic hernia other congenital defects are sometimes found, such as hare lip, cleft palate hydrocephalus, absence of a kidney, and transposition of viscera

## Symptoms

These hernias may be symptomless The symptoms may be slight and transitory or severe and lasting They may be referred to the chest or abdomen or both The pain often simulates anginal pain and must be differentiated from that There may be dyspnea, which is increased when the patient lies down This is sometimes relieved by the patient lying on the unaffected side Cardiac irregularity is not uncommon

There may be dysphagia, regurgitation heartburn, vomiting hematemesis, and anemia The latter two are caused by erosion of the gastric mucosa and bleeding Vomiting after heavy meals is common Patients with small hiatus hernias are often relieved of their symptoms if they lose weight The most common symptom in these cases is substernal pain, which may radiate down the left arm especially when the stomach is overloaded

## Physical Signs

If the hernia is small no physical signs can be elicited If the hernia is large and there are abdominal organs in the thoracic cavity, the physical signs are variable The heart may be displaced to the right If the herniated organs contain gas, the percussion note will be hyperresonant If not it will be dull or flat On auscultation the breath sounds are suppressed or absent on the affected side Gurgling sounds may be heard There may be signs of hydropneumothorax especially in traumatic cases in which there has been perforation of abdominal viscera

## Diagnosis

While the history and physical findings are an aid in the diagnosis the real diagnosis is made by roentgenogram

## Treatment

Asymptomatic diaphragmatic hernias require no surgical treatment A great many hiatus hernias are symptomless and are found only on routine roentgenogram However the percentage of symptomless ones is questionable and varies in reports of different authors Often patients with hiatus hernias will develop symptoms when they grow fat owing to the increase in intra abdominal pressure and their symptoms will disappear if they lose weight If their symptoms persist, they should be operated upon

There are three methods of approach in the operation for diaphragmatic hernia abdominal thoracic, and thoracoabdominal A Levin tube is always passed into the stomach before operation

The abdominal approach has the disadvantage, especially in people with narrow costal angles, of making the approach to the hernia site difficult. It has the advantage of giving the surgeon ready access

neal, lumbar, obturator, and internal hernias

## Sciatic Hernia

A sciatic hernia is one that emerges through the greater or lesser sacrosciatic foramen Watson in 1948 was able to find only 35 cases in the literature It is the rarest of all hernias I have never seen one All ages are represented Some cases are congenital The sexes are equally represented Predisposing causes are traction owing to tumors in the gluteal region, relaxation of muscles, constipation, strain laborious occupations, and injuries or operations damaging muscle and fascia in the gluteal region

After emerging through the greater or lesser sacrosciatic foramen the hernia arrives under the gluteus maximus muscle (Fig 5 26) As the hernia enlarges, it appears under the lower border of this muscle

DIAGNOSIS The symptoms are obscure unless there is a tumor present There may be pain radiating down the sciatic nerve Sciatic hernia should be considered when ever there is a tumor in the gluteal region Sometimes the diagnosis is not made until strangulation ensues and is then made during the course of laparotomy for intestinal obstruction When the hernia is large, it emerges from under the gluteus muscle and may become a pendulous tumor hanging from the buttocks (Fig 5 26, inset) This may be confused with perineal hernia In my one case of perineal hernia when I first saw the patient I thought she had a sciatic hernia However, on placing her in the recumbent position and reducing the hernia it was found that it went through an opening in the floor of the pelvis instead of through the sacrosciatic notch

TREATMENT The operative route may either be abdominal or gluteal, or both If the diagnosis is made before operation the abdominal route is preferred This is done through a mid line incision The Trendelenberg position aids exposure The hernia is reduced and gangrenous bowel resected if present If there is any difficulty in reducing the hernia, care must be exercised in enlarging the ring because of the danger of injuring the sciatic or gluteal artery or the sciatic nerve The sac is pulled out of the sciatic foramen with a Kelly clamp, inverted and excised The sciatic opening may be closed with a piece of tantalum gauze and the peritoneum sutured over it

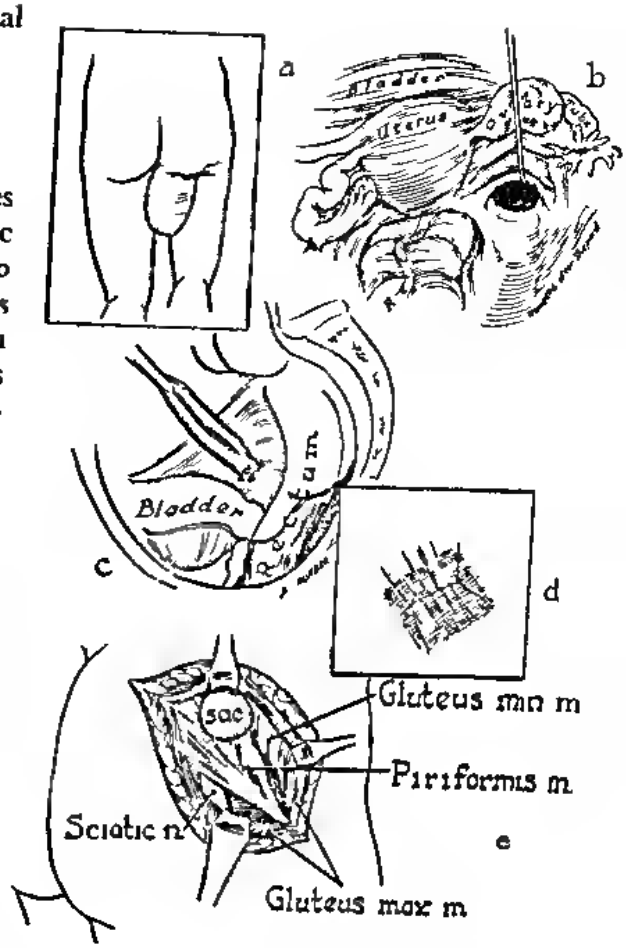


Fig 5 26 Sciatic hernia (*a*) Appearance of the patient (*b*) Intra abdominal opening of a sciatic hernia which in the female is behind the broad ligament (*c*) Inversion of the sac within the peritoneal cavity after reduction of the contents (*d*) Closure of the sciatic opening by suture of the peritoneum over tantalum mesh (The sac can be folded upon itself and sutured as a pad to prevent recurrence ) (*e*) Exposure of the sac of a sciatic hernia through a posterior incision of the skin subcutaneous tissue and gluteus maximus muscle that overlie the sac The hernia may present itself either above or below the piriformis muscle (*From* Watson *Hernia* 3d ed, 1948 The C V Mosby Co *Courtesy* The C V Mosby Co )

ally soft and reducible and their nature is determined by the opening through which they are reduced A labial hernia might be confused with an inguinal hernia but the inguinolabial hernia would appear in the anterior portion of the labium majus and the perineal hernia in the posterior portion In my case of perineal hernia the large pendulous mass was mistaken for a sciatic hernia but on having the patient lie down the hernia was easily reduced through an opening in the pelvic floor about 5 cm in diameter which lay between the tuberosity of the ischium and the rectum Thus the diagnosis was easily established The anterior variety has been confused with vaginal cysts and been incised on the erroneous assumption that a cyst was being dealt with resulting in fatal injury to the bowel Stone has reported a case in which the surgeon supposed he was dealing with simple rectal prolapse the hernia sac was opened small bowel injured and peritonitis resulted

TREATMENT Perineal hernia may also be operated upon through the abdominal or perineal route or both The abdominal route is preferable This is done through a mid line incision with the patient in the Trendelenburg position The contents of the hernia sac are reduced and the hernia sac is pulled up into the abdominal cavity and excised The opening is closed by converting the circular opening into a slit by interrupted mattress sutures If the structures are weak they may be reinforced by a piece of tantalum gauze If there is a large external pouch it should be excised both for cosmetic reasons and to prevent the formation of a hematoma in it

## Lumbar Hernia

### *Primary Lumbar Hernia*

Primary lumbar hernias are the third rarest of all hernias In 1948 Watson was able to collect only 153 cases from the literature I have seen two cases only and these have not been reported

Most primary lumbar hernias come through the inferior lumbar triangle of Petit Some come through the superior lumbar triangle of Grynfeltt Lesshaft A few come through abnormal openings in the muscle or aponeurosis and may appear anywhere in the lumbar region The majority of the reported cases are in males approximately 2 to 1 All ages are represented Some cases are congenital

Primary lumbar hernias are probably due to a congenital weak spot Contributory causes are strains due to coughing or lifting obesity emaciation and the degenerative changes of old age

### *Incisional Lumbar Hernia*

Incisional lumbar hernias are not as rare as the primary type They almost always occur following kidney operations in which there was infection present generally gross infection In the six cases I have operated upon there were no fascial or muscular structures in the area bounded by the crest of the ilium below the lower border of the ribs above the rectus muscle anteriorly and the lumbar muscles posteriorly This left a large rhomboidal area of the lateral abdominal wall in which there were no structures except skin subcutaneous tissue and peritoneum In each instance a huge hernia sac bulged through this large defect

DIAGNOSIS Primary lumbar hernias are easily diagnosed and present themselves as small reducible masses in Petit s triangle The two seen by me were symptomless There may be some local pain Colic and vomiting have been reported There is an impulse on coughing Sometimes a gurgling sound is heard when the hernia is reduced

Incisional lumbar hernias are large and obvious

TREATMENT If primary lumbar hernias are small and symptomless they hardly require operation If they cause symptoms they are easily repaired (Fig 5 28*a*) In this operation a flap of fascia lata is turned up and sutured to the edges of the muscles bordering Hesselbach s triangle the external oblique in front and latissimus dorsi behind Then a flap of the lumbar fascia is reflected forward covering the fascia lata and any part



a

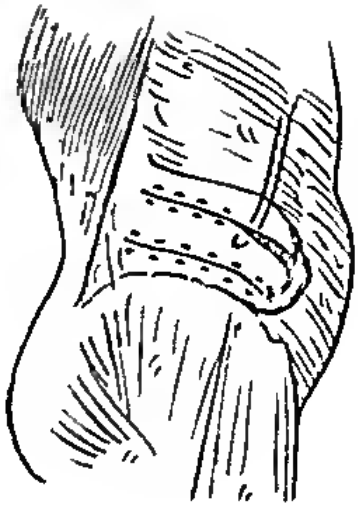

b

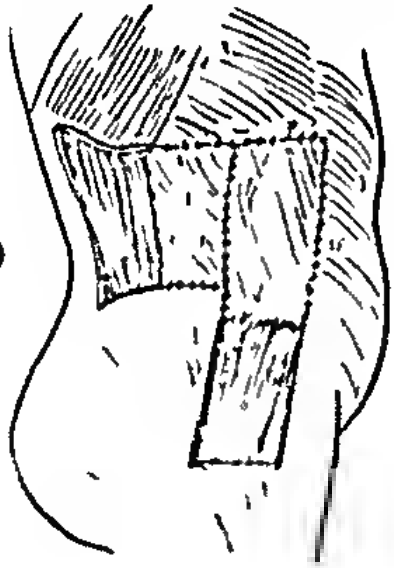

c

of the hernial defect that the fascia lata did not cover

While this small and simple operation is satisfactory for small primary lumbar hernias it is not sufficient for the huge incisional lumbar hernias that are frequently encountered I have described a modification and extension of Dowd s operation for these massive hernias which is depicted in Figure 5 28*b* An oblique incision is made in the kidney region running downward and forward as far as necessary over the hernial sac The sac is dissected free Unless there is some reason for doing so the sac is not opened but is plicated with a couple of rows of inverting mattress sutures Care must be exercised not to puncture any portion of the bowel which may be adherent to the sac or to angulate any adherent loops An other incision is then made from the center of the oblique incision downward over the thigh at a point that will best expose the fascia lata and the fascia covering the gluteus muscle A rectangular piece of this fascia is then dissected free and turned upward Sufficient fascia however cannot be obtained to cover the entire hernial defect Enough can be obtained to cover the anterior half or possibly two thirds of the defect This strip of fascia is sutured to the fascia over the ribs above and to the rectus fascia anteriorly A flap of lumbar fascia is then turned forward and sutured to the flap of fascia lata anteriorly to the rib fascia above and to the crest of the ilium below

I have used this method in six cases all of whom have remained well (except one lost to follow up) over a period of years one for 25 years In two of the cases I reinforced the entire area with a cutis graft and in two others with tantalum gauze I believe that the reinforcement in these four cases was unnecessary as the two unreinforced cases did just as well as those with the reinforcement

## Obturator Hernia

An obturator hernia is one occurring through the obturator foramen It protrudes through the foramen along the course of the obturator vessels and nerves and usually just lateral to them The sac lies internal to the femoral ring and usually presents under the pectineus muscle (Fig 5 29) Although rare obturator hernia is not nearly so rare as sciatic perineal and lumbar hernias I have operated on two cases only Watson in 1946 collected 442 cases from the literature There were about four times as many in women as in men This is probably due to the broader female pelvis larger obturator foramen and to the exigencies of pregnancy and childbirth No cases have been reported under ten years of age All other ages are represented but the majority of cases occur after 50 years of age They frequently occur in thin people in whom there has been a history of recent loss of weight Loss of fat in the obturator canal apparently predisposes to hernia There is probably also a congenital predisposition to the condition Other predisposing causes are coughing straining and other factors that tend to increase intra abdominal pressure

DIAGNOSIS Frequently the patient feels no mass and none can be felt on physical examination A large mass is rare The most characteristic symptom in non strangulated cases is the Howslip Romberg phenomenon which consists of pain and sensory disturbances down the inside of the thigh owing to pressure of the hernial mass on the obturator nerve As the hernia comes through under the pectineus muscle when a mass is palpable it is a slight bulging internal to and just below the femoral ring Rectal or vaginal examination may disclose a fullness or mass in the obturator region In case of strangulation the usual symptoms of intestinal obstruction supervene The diagnosis is often not made until the patient is operated upon for intestinal obstruction

TREATMENT Obturator hernias should be operated upon as soon as discovered because of the danger of strangulation The abdominal approach is the best and of course will necessarily be done if there is evidence of strangulation It is done

through a low mid-line incision with the patient in the Trendelenburg position After the hernia is reduced and the contents of the sac dealt with, the sac is excised It is impossible to close the obturator foramen because its walls are rigid the latter mesially The hernia sac is exposed, being careful not to injure the obturator nerve or artery After the sac and its contents have been dealt with, the obturator opening is closed by a flap of fascia reflected from the pectineus muscle

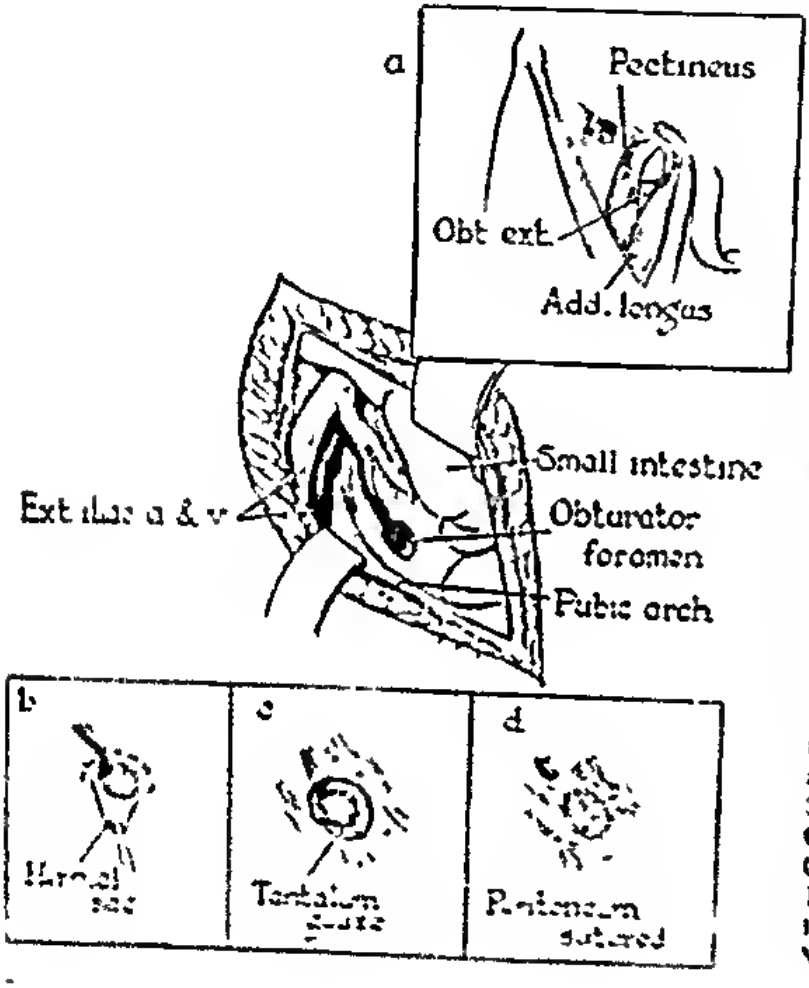


Fig 5-29 (*a*) The sac of an obturator hernia most frequently lies on the obturator externus muscle and is covered by the pectineus. The obturator nerve lies directly behind the sac. (*b*) An obturator hernia is most easily repaired by transabdominal reduction of the contents and removal of the sac (*c*) Recurrence is prevented by tantalum mesh placed over the obturator foramen (*d*) Peritoneum is sutured over it *a*, *b* *c*, and *d* *From* Watson, *Hernia* 3d ed, 1948 The C. V. Mosby Co *Courtesy* The C. V. Mosby Co *Center* *From* T. D. Throckmorton, *Surgery* 27 [illegible] 1950 *Courtesy* The C. V. Mosby Co )

irreducibility, and sometime meaning obstruction I believe that the proper use of the word is to take it literally, which means that the contents of the sac are *incarcerated* in the sac and cannot get out Used in this way, the term is synonymous with irreducibility The condition may be due to adhesions or to a narrow neck of the sac, either of which may not allow the contents of the sac to escape into the abdominal cavity Irreducible hernias may contain omentum or intestine or both The condition is often a prelude to obstruction or strangulation and generally occurs in hernias of long standing

## Obstructed Hernia

An obstructed hernia is one in which there are loops of bowel that are obstructed This of course causes all the symptoms of intestinal obstruction

## Strangulated Hernia

A strangulated hernia is one in which the blood supply of the contents of the sac is obstructed which means that swelling quickly ensues and gangrene of the contents will occur unless the strangulation is promptly relieved The strangulated contents of the sac are generally loops of intestine However omentum only may be strangulated and become gangrenous

Strangulation may occur in almost all types of hernia It is more common in those hernias that have a narrow neck with rigid environs The percentage of strangulated hernia is much higher in femoral hernia than in any other type This is because of the narrow femoral canal with its rather rigid environs Approximately one third of all reported cases of femoral hernia have been strangulated Umbilical hernia is next in the incidence of strangulation the incidence being as high as 15 per cent in some series reported The percentage of strangulation in inguinal hernia is probably 2 to 4 per cent Most of these cases occur in indirect inguinal hernias Owing to the nature of the sac in most direct hernias strangulation is rare in them Strangulation is not uncommon in incisional hernia but is more uncommon than in other types mentioned because as a rule the neck of the sac is wide It is probably not over 2 per cent It is also rather common in diaphragmatic hernia Among the rarer hernias strangulation is common in sciatic and obturator hernias It is of course the rule in Richter s hernia and is probably the rule in internal hernia because the diagnosis is not made until strangulation occurs It is uncommon in epigastric lumbar and perineal hernias I see no reason why the incidence in interparietal hernia should not be the same as that in inguinal hernia

Strangulation frequently occurs in irreducible hernias It may occur in a hernia that has been reducible and suddenly becomes irreducible This may be brought on by some sudden muscular effort such as lifting coughing or sneezing The patient s attention is brought to the new state of irreducibility by pain in the hernia site and he may notice that the protrusion is larger than it was when he was able to reduce it The mass becomes tender on pressure and the pain increases If only omentum is contained in the hernia sac constipation is not complete If however the hernia sac contains bowel constipation is complete and nausea and vomiting soon ensue If not treated the condition becomes progressive just as in any other case of intestinal obstruction If not relieved gangrene ensues The symptoms are the more violent the higher the obstruction of the bowel

Physical signs besides the local tenderness may include abdominal distention and roentgenogram may show distended loops of bowel The leukocyte count is elevated The pulse rate is elevated except in the early stages

TREATMENT The ideal treatment is prophylactic If all hernias were operated upon as soon as they appear strangulation would be practically eliminated

In the past physicians have often made attempts to reduce strangulated hernias soon after the strangulation occurs in the hope that the patient will be relieved and operation obviated This is a mistake for

CHASSIN, J L The subcutaneous inguinal ring A clinical study *Surgery 22* 540, 1947

DAVIS, CARL, JR Use of rectus sheath in repair of inguinal hernia *A M A Arch Surg 68* 557, 1954

DEAN, G O Strangulated femoral hernia *Arch Surg 44* 933, 1942

FERGUSON, L K, and WOLCOTT, M W The significance of relaxed inguinal rings *Ann Surg 131* 484, 1950

GARDNER, F P Inguinal hernia Incidence in civil service employees and relation to relaxed rings *U S Navy Med Bull 39* 270, 1941

GRACE, R V, and JOHNSON, V S Results of herniotomy in patients of more than fifty years of age *Ann Surg 106* 347, 1937

HALSTED, W S Cure of the more difficult as well as the simpler inguinal ruptures *Bull Johns Hopkins Hosp 14* 208, 1903

HOGUET, J P Direct inguinal hernia *Ann Surg 72* 671, 1920

HOWES, E L, SOOY, J W, and HARVEY, S C The healing of wounds as determined by their tensile strength *J A M A 92* 42, 1929

JOHNS, W A Incisional hernia *Amer Surg 23* 1152, 1957

KOONTZ, A R Muscle and fascia suture with relation to hernia repair *Surg Gynec & Obst 42* 222, 1926

KOONTZ, A R Experimental results in the use of dead fascia grafts for hernia repair *Ann Surg 83* 523, 1926

KOONTZ, A R Femoral hernia Operative cases at the Johns Hopkins Hospital during a twenty-one year period *A M A Arch Surg 64* 298, 1952

KOONTZ, A R Hernia in the linea semilunaris *Ann Surg 135* 875, 1952

KOONTZ, A R Tantalum gauze in the presence of infection Clinical experience *Amer Surg 19* 403, 1953

KOONTZ, A R The hernia problem The role of the internist and general practitioner *Maryland State Med J 3* 532, 1954

KOONTZ A R Views on the choice of operation for inguinal hernia repair *Ann Surg 143* 868 1956

KOONTZ, A R, and GRAVES, J W Preoperative pneumoperitoneum as an aid in the handling of gigantic hernias *Ann Surg 140* 759 1954

KOONTZ, A R, and KIMBERLY, R C Tissue reactions to tantalum mesh and wire *Ann Surg 131* 666, 1950

KOONTZ, A R, and KIMBERLY, R C Tissue reactions to tantalum gauze and stainless steel gauze An experimental comparison *Ann Surg 137* 833, 1953

KOONTZ, A R, and STAFFORD, E S Unusual types of interparietal hernia *A M A Arch Surg 71* 723, 1955

LAROQUE, G P The permanent cure of inguinal and femoral hernia A modification of standard operative procedures *Surg Gynec & Obst 29* 507, 1919

LAROQUE, G P The intra-abdominal method of removing inguinal and femoral hernia *Arch Surg 24* 189, 1932

LATTIMORE, T J, and KOONTZ A R Suction drainage after implantation of tantalum gauze sheets *J A M A 155* 1333, 1954

LOWER, W E, and HICKEN, N F Interparietal hernias *Ann Surg 94* 1070, 1931

MCVAY, C B, and ANSON, B J A fundamental error in current methods of inguinal herniorrhaphy *Surg Gynec & Obst 74* 726, 1942

MADSEN, E T An experimental and clinical evaluation of surgical suture materials II *Surg Gynec & Obst 97* 439, 1953

PARSONS, W B Silk sutures in the repair of hernia *Ann Surg 106* 343, 1937

PRICE, P B Stress, strain and sutures *Ann Surg 128* 408, 1948

STONE, H B Umbilical hernia A method of operative treatment *Arch Surg 12* 494, 1926

ZIMMERMAN, L M Recent advances in surgery of inguinal hernia *Surg Clin North America 32* 135, 1952

CHAPTER 6

# NONPENETRATING WOUNDS OF THE ABDOMEN

*John H. Morton, J. Raymond Hunshaw, and John J. Morton, Jr.*

strated, operation for control of hemorrhage is seldom required Although lacerations of the liver are not rare, many such injuries result in death from hemorrhage before the victim reaches the hospital A ruptured spleen is, therefore, the common lesion that requires early diagnosis and operative management

Of nonpenetrating intestinal wounds 80 per cent involve the jejunum and ileum, 10 per cent the duodenum, and the remainder the large bowel and stomach Most of these are tears of the bowel wall, but intramural hemorrhage with secondary intestinal obstruction does occur Even damage to the mesentery may so compromise the blood supply that an uninjured segment of intestine becomes necrotic and perforates Rupture of the uterus following abdominal trauma is rare and has occurred only during pregnancy Damage to the pancreas varies from mild contusion to complete transection, and this organ, though usually protected, is sometimes the only site of injury The gallbladder and extrahepatic bile ducts may also be singled out even when they are not diseased Rupture of the urinary bladder either intraperitoneally or extraperitoneally, is most often associated with a pelvic fracture, and damage to the ureters adrenal glands, and great vessels occurs only in association with other severe lesions

Nonpenetrating trauma may also rupture the diaphragm This injury usually involves the central tendinous portion more commonly on the left side A traumatic diaphragmatic hernia, sometimes occurring as an isolated event frequently accompanies damage to the spleen or kidney When the patient has sustained multiple injuries, involvement of the diaphragm may easily be overlooked until subsequent pulmonary problems or unusual chest films lead to further investigation

## DIAGNOSIS

In evaluating the injured, no diagnostic aid can supplant and none is as rewarding as an accurate history and repeated, thorough physical examinations Unless a diagnosis can be established initially, repetition of the history and physical examination is necessary for several reasons A patient apparently suffering little may develop symptoms and signs only after an interval during which blood or fluid accumulates in the abdomen On the other hand, a patient in shock may exhibit a remarkably negative abdomen until restorative measures bring him to responsiveness Some conditions particularly a retroperitoneal rupture of the duodenum often exhibit an asymptomatic period before the onset of pain Contusion of the spleen may be followed days or months later by frank rupture but this event, which usually occurs during the first two weeks after trauma is ushered in by the sudden onset of severe symptoms Even careful management will not forewarn of this complication

## HISTORY

The history of the accident though occasionally misleading, should be elicited carefully The patient must be questioned about certain specific symptoms that give a clue to the site and type of damage Shoulder pain without shoulder injury suggests diaphragmatic irritation owing to blood or intestinal juice, but this reference of pain can occur with no more than an abdominal wall contusion Abdominal pain, whatever its location, at least warns of a possible surgical emergency Testicular pain and priapism make one suspect a retroperitoneal injury, and the continuous desire to void with inability to do so is almost pathognomonic of bladder or urethral damage Hematemesis, bloody stools, and hematuria each point to one site of injury In the absence of thoracic trauma dyspnea is frequently indicative of splenic or hepatic rupture

## PHYSICAL FINDINGS

The prominent physical findings to be anticipated are those of shock and of peritoneal irritation While either abdominal wall or retroperitoneal trauma can pro-

duce this combination, a lesion necessitating operation is more often responsible. Profound shock can mask all peritoneal signs, but with transfusion an unremarkable abdominal examination may change into the very picture of intraperitoneal hemorrhage. This degree of shock, however, is not usually an early event unless the liver is ruptured. Because branches of the hepatic veins are numerous and valveless, severe hepatic damage produces sudden, massive hemorrhage directly from the inferior vena cava. While the less seriously injured patient is undergoing restorative therapy, a suspicion of an intra-abdominal catastrophe may become a certainty if signs progress. The commonly noted decrease in peristaltic activity is in no way diagnostic of severe injury, nor can continued peristalsis rule out even a ruptured intestine. An entirely negative abdominal examination does not preclude a severe retroperitoneal lesion such as a ruptured duodenum.

## COMMON LABORATORY AIDS

Routine laboratory aids are both helpful and treacherous. Anemia, by no means always present, indicates neither the type of injury nor its proper management. Leukocytosis usually accompanies severe intra-abdominal injuries, particularly if the spleen or liver is ruptured, but a high white count is at times due to no more than an abdominal wall contusion or minor kidney damage. On the other hand, the count may remain normal after intestinal or even splenic rupture.

Some laboratory procedures are less equivocal, though they indicate only a single lesion even if several are present. Gross or microscopic hematuria resulting from damage to the kidneys or bladder is usually noticed soon after the accident. Its appearance is occasionally delayed, and its degree may not reflect the magnitude of injury. Elevation of the serum amylase is a warning of trauma to the pancreas, but it is dangerous to conclude that no other organ has been affected.

## SPECIAL DIAGNOSTIC AIDS

The problem confronting the surgeon in assessing blunt abdominal trauma is to distinguish the trivial injury from the serious one. This is frequently a considerable challenge, and several special procedures have particular merit as diagnostic aids. However, it is important to know that these, too, have their limitations. Abdom-

inal paracentesis may be performed with a No 18 or No 20 needle Perhaps a safer and more often productive procedure is the introduction of a small flexible polyethylene catheter through a No 14 needle which with stylet has been inserted just into the peritoneal cavity Aspiration after introduction of the catheter for a distance of 12 to 18 cm may lead to the recovery of bloody or bile stained fluid urine chyle air or intestinal contents If aspiration yields nothing 20 ml of sterile normal saline should be injected and withdrawn The saline should be examined grossly for discoloration or microscopically for leukocytes One of the few complications of this procedure occurs from accidentally shearing off the plastic tube within the peritoneal cavity This can be prevented by withdrawing the needle before the catheter Positioning the patient to promote the collection of fluid in one area can increase the success of the first tap but if this is not productive the other three quadrants of the abdomen should be needled The novice is often willing to believe he has unwittingly penetrated a blood vessel and to discount a small amount of blood aspirated from the peritoneal cavity but the fact that the fluid does not clot indicates an extravascular source On the other hand a large retroperitoneal hematoma can yield a positive tap It is remarkable that a needle will at times locate an area free of blood when at operation no such area seems to exist The highest percentage of accuracy reported even with taps of the four quadrants is 83 per cent and many recognize their inability to approach this figure Paracentesis is nevertheless an invaluable test when positive and one virtually free from danger

The plain x ray film of the abdomen with an upright or lateral decubitus view aids in diagnosis Haziness of the plain film suggests free abdominal fluid Obliteration of renal outlines or of psoas shadows is seen with retroperitoneal edema or hemorrhage The gas pattern in the gastrointestinal tract can be evaluated and a search should be made for findings frequently associated with intra abdominal injuries These include fractures of the ribs lumbar tranverse processes and the bony pelvis Retroperitoneal gas suggests rupture of the duodenum Enlargement of the splenic outline and less commonly serration of the greater curvature of the stomach point to splenic rupture Free air best seen in the upright or lateral decubitus view indicates perforation of the gastrointestinal tract The upright or chest film may suggest diaphragmatic disruption and if the patient is in good condition repeat films following an induced pneumoperitoneum are indicated to determine whether or not the diaphragm is intact A lipiodol swallow to demonstrate tears of the retroperitoneal duodenum has had limited use but may be of help if a decision for operation can not be reached in some other way Intravenous pyelography occasionally confirms suspected renal damage and demonstration of a contralateral kidney with normal function must precede nephrectomy for control of hemorrhage However nonvisualization of a kidney does not necessarily imply a serious lesion requiring operation

The unremarkable x ray film must not be given undue emphasis Free air is demonstrable in well under half the cases of intestinal rupture and retroperitoneal gas is an inconstant finding with duodenal tears It is said that the presence of a small well outlined splenic shadow on a good plain film practically rules out splenic rupture but the ability to establish an early diagnosis by x ray examination apparently varies greatly from one hospital to another Barium swallow splenoportal venography and intravenous Thorotrast as aids to the diagnosis of splenic and hepatic damage have been reported but their use seems ill advised in the acutely injured

Should the patient be unable to void a soft catheter is inserted gently into the urinary bladder The return of abnormally large quantities of fluid arouses suspicion of bladder rupture A carefully performed gravity cystogram will confirm this diagnosis and the examination is without risk It is generally accepted that this procedure

ment of hepatic lacerations is still practiced by a few, most surgeons advise emergency exploration The prime considerations at operation are the control of hemorrhage and the removal of devitalized liver tissue, but how to stop bleeding with the least morbidity varies with the location and severity of injury Small rents should be closed after necrotic tissue has been removed When a laceration extends almost through the substance of the liver, excision of the partially detached fragment is mandatory to prevent later autolysis of the segment Large lacerations in the dome are approached with greatest safety through a thoracoabdominal incision that permits ligature of bile ducts and bleeding vessels under direct vision Although packing with plain gauze or oxidized cellulose is frequently condemned as a definitive procedure, this may be necessary if hemorrhage cannot be controlled by more desirable means Before resorting to this least satisfactory form of treatment, however, the surgeon should consider the invariable complication of infection and the frequent one of secondary hemorrhage If a foreign substance must be left in the liver or if a large rent has been sutured, subsequent escape of bile can be expected and the area should, therefore, be drained

Hemobilia, i e , periodic secondary hemorrhage through the biliary tree into the gastrointestinal tract, may follow the treatment of hepatic lacerations when bile under pressure produces continued autolysis of liver parenchyma Surgical decompression of the biliary tract, a recommended treatment for this complication, might also prevent its occurrence Close apposition of viable liver tissue with drainage of the potential cavity beneath the sutured surface is also important despite the possibility of secondary hemorrhage after removal of the drain At times even hepatic artery ligation may be required to control hemobilia

BILE DUCTS Injury to the extrahepatic bile ducts usually requires little more than an escape route for the leaking bile and decompression with a catheter in the common duct or gall bladder The usual lesion does not require operative repair either primarily or secondarily, and if the rent is small, primary suturing is inadvisable Removal of the catheter is safe when reconstitution of the duct can be demonstrated by cholangiography, usually within two weeks of operation Cholecystectomy, cholecystostomy, or suture of the tear is required for treatment of traumatic rupture of the gall bladder The procedure depends on the injury but is, in any case, no problem

PANCREAS Isolated pancreatic damage, if the diagnosis can be established, rarely necessitates immediate operation, but the late complications of pseudocyst, abscess, or fistula may occur despite the initial treatment To prevent further bleeding or leakage of pancreatic secretions an obvious rupture, discovered incidentally at operation, should be sutured and the lesser sac drained In the unusual event of complete pancreatic transection early operative intervention is indicated Tears through the neck of the gland should be managed by oversewing the two sides of the laceration When transection occurs to the left of the mid line, the proximal cut end should be closed and the tail removed

GASTROINTESTINAL TRACT AND MESENTERY Injuries to the gastrointestinal tract and mesentery should be managed by suture of lacerations, resection of bowel, side tracking anastomosis, exteriorization, or control of hemorrhage as the individual case demands A search should be made for multiple injuries, most of which will be disclosed by a careful intraperitoneal exploration However, swelling, discoloration with bile and blood, or air cysts beneath the posterior peritoneum or in the ascending and transverse mesocolon should warn against overlooking a ruptured duodenum Tears of the intestine occur anywhere, not only near fixed points, and they most frequently involve the antimesenteric border Lacerations of the stomach are usually along the lesser curvature The chief complications that may be avoided by the choice of the correct operative pro-

SPECTOR, N Ligation of the right hepatic artery in hemobilia *Ann Surg 145* 244, 1957

STRICKLER, J H, ERWIN, P D, and RICE, C O Diagnostic paracentesis *A M A Arch Surg 77* 859, 1958

TERRY, J H, SELF, M M, and HOWARD, J M Injuries of the spleen *Surgery 40* 615, 1956

ULVESTAD, L E Repair of laceration of superior mesenteric artery acquired by nonpenetrating injury to the abdomen *Ann Surg 140* 752, 1954

WANG, C C, and ROBBINS, L L Roentgenologic diagnosis of ruptured spleen *New England J Med 254* 445, 1956

WYMAN, A C Traumatic rupture of the spleen *Am J Roentgenol 72* 51, 1954

wounding among 22,000 casualties * In the Korean conflict, from January 1, 1952, to January 1, 1953, approximately 8 5 per cent of 3,716 general surgical patients admitted to the 46th Surgical Hospital were wounded in the abdomen In the Korean conflict, the incidence of abdominal wounding was subsequently reduced to almost half of the previous level by the acceptance of body armor

## ETIOLOGY

Perforating wounds of the abdomen may be caused by any number of primary or secondary missiles, weapons, or even intrinsic body components, such as ribs The wound of entry may be extensive or minimal, it may be directly into the abdomen, flank, or back, or it may be remote, such as in the thigh, chest, or shoulders It may be obvious or occult In a rare instance, it may be clean, but it must never be assumed to be sterile

Weapons that may be responsible for penetrating wounds are knives, daggers, bayonets, spears, and arrows These produce characteristic wounds, usually of the small puncture variety Bayonet wounds, however are often immediately fatal because they are frequently associated with large vessel injury and evisceration

Primary missiles are projectiles or fragments of projectiles They may consist of small arms fire, bullets of varying velocity, explosive shells, and grenades The wounds made by such missiles or fragments are extremely variable, depending on the size, shape, and velocity of impact, the resistance of tissue initially struck the site of impact and the course of the missile Large, irregular fragments traveling at moderately high velocity tear ragged, dirty, gaping wounds of entry The internal damage is often multivisceral Associated shock is often immediate and profound High velocity rifle and machine gun fire within effective range produces internal damage far greater than would be anticipated by the appearance of the small wound of entry The wound of exit may also be ragged and gaping and shock is often severe

Secondary missiles consist of various types of matter set in motion by explosive force These range in size from small splinters of glass to large pieces of lumber Generally, these are fairly dirty materials The internal injuries they produce, however, are surprisingly few and they may be inconsequential The danger of flying glass plastic and wooden splinters lies in the fact that they may be overlooked because they are radiolucent and the injured person is an excellent candidate for resultant peritoneal infection Secondary intrinsic missiles may be bone fragments of rib, vertebra or pelvic girdle, which may pierce the spleen or liver, rectum bladder or duodenum

From the standpoint of civilian practice, the general incidence of weapon wounding by such things as butcher knives, switchblade knives and icepicks is higher than in the military situation Gunshot wounds are those resulting from low-velocity missiles, such as shotguns, 22 caliber rifles or pistols, 32 caliber pistols, or 45 caliber pistols which are generally fired from a distance Wounds received at close range are frequently the results of suicidal attempts and are often fatal Shotguns fired at close range are most lethal because of the cone of shot that produces an almost avulsion type injury with severe multivisceral damage Some of these woundings are received in hunting accidents, others in suicidal attempts, but

* The most comprehensive and definitive study of abdominal wounds appears in the final report of the Second Auxiliary Surgical Group to The Surgeon General Included in the report is a complete analysis of wounds incurred and treated in the field in 1944–45 This report is the only work of its kind It is a remarkable tribute to the men who with foresight conceived it and through perseverance maintained a system for the collection of records and immediately assembled analyzed and published the reports This remarkable aggregation of outstanding young surgeons achieved the gross salvage rate of 76 per cent for the abdominally wounded The essence of the Second Auxiliary Surgical Group study forms a basis for the recent publication *Medical Department United States Army Surgery in World War II* vol II *General Surgery*

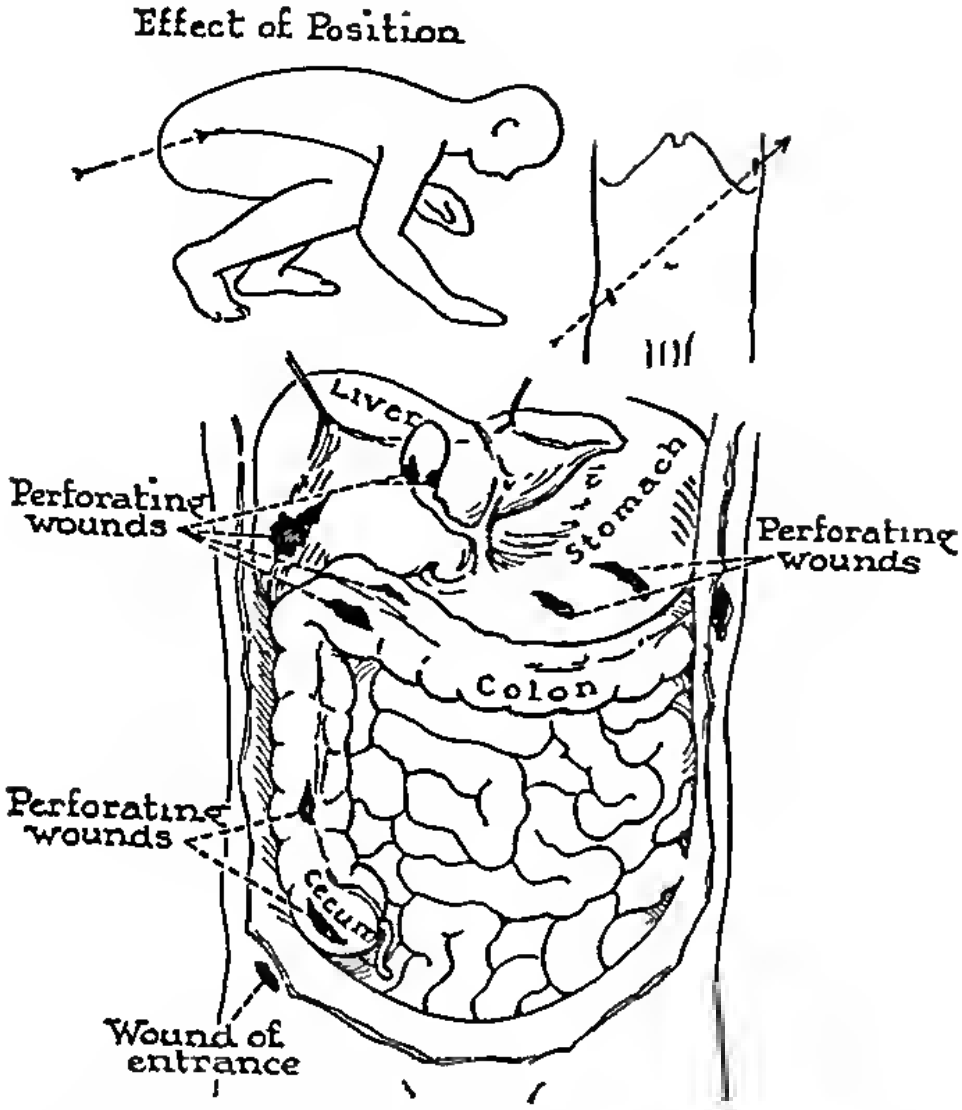


Fig 7 1 Possible effect of position on track of missiles and resulting visceral injuries

emphasized by Makins at the turn of this century It was again observed many times by members of the Second Auxiliary Surgical Group, and Figure 7-1, taken from their report, illustrates this point

Penetrating as well as perforating wounds of the abdomen may occur without injury to the abdominal contents This, however, is unusual, and under no circumstances is it to be assumed Gordon Taylor speaks of the immunity of the intestines and offers the opinion that missiles may actually traverse the intestinal area by traveling parallel to and between loops of coiled intestine He admonishes against reliance upon intestinal immunity in perforating abdominal injuries

Small wounds of entry have been noted in all extremities and on the neck Table 7 2 shows the location of the wound of

TABLE 7 2 WOUNDS OF ENTRY FROM DATA RECORDED BY SECOND AUXILIARY SURGICAL GROUP

| Penetrating wounds 2066 | | Perforating wounds 656 (2722 cases) | |
|---|---|---|---|
| Right versus left | | Equal distribution | |
| Anterior | 47 5% | Midline injuries | 10 1% |
| Posterior | 28 2% | Buttocks or hips | 13 0% |
| Lateral | 23 8% | | |
| Perineum | 4% | | |
| | 99 9% | | |

and, indeed, this was the only lesion in 8 per cent of their patients who had laparotomies

Peritoneoscopy, performed through a subumbilical mid line stab wound with a foreoblique cystoscope, has been useful in the hands of experienced proponents in ruling out or establishing a definite diagnosis of peritoneal disruption in equivocal instances Peritoneoscopy however, has not received general acceptance in such cases As a diagnostic tool in equivocal cases the recovery of blood tinged peritoneal fluid on a sponge inserted through a small subumbilical linea alba incision has been said to be helpful in making the decision for exploratory laparotomy

The failure of these procedures to be widely advocated indicates their limited usefulness Surgeons are willing to accept a 10 to 30 per cent incidence of negative explorations from which the morbidity and mortality are negligible rather than to rely on less precise methods

Precious time should not be wasted on detailed diagnostic efforts at the expense of resuscitation Having been impressed with a specific organ diagnosis or suspicion of visceral damage a thorough exploration should be made

There are characteristics of certain organ injuries, however, which should be kept in mind In 50 to 75 per cent of the cases the perforated hollow viscus will cause free air in the peritoneal cavity which may be demonstrated by a semi reclining or left lateral roentgenogram taken over the right lobe of the liver If the diaphragm has been injured the free peritoneal air may be missed because of its escape into the chest Multiple intestinal wounds or large wounds of the small bowel that permit profuse escape of succus entericus will result in early severe peritoneal irritation just as does the escape of acid gastric content from the perforated stomach This is predominantly chemical, and in time it will not only cause pain but irrespective of blood loss will be responsible for shock Large colon wounds and even small wounds of the colon with bacterial contamination of the peritoneal cavity cause shock that may be profound and irreversible The onset may occur somewhat later or it may be as early as one hour Berry has noted the presence of well established peritonitis occurring as early as three and one half hours after wounding

There is a shock syndrome associated with profound peritoneal contamination which has been described by members of the Second Auxiliary Surgical Group

Before and after operation these patients present the appearance of severe shock The blood pressure tends to be low and can only be sustained by heroic measures The pulse is weak and rapid Pulse deficit has been observed The sensorium may be clouded The color of the skin is pale usually with cyanosis or mottling The temperature is sometimes subnormal and rarely about 100° Fahrenheit Massive transfusions careful surgery constant oxygen inhalation therapy chemotherapy and all other measures fail appreciably to alter the picture and early death ensues

Certain spinal injuries may be confused with abdominal injuries During the Spanish Civil War Mr Douglas Jolly served with a forward surgical unit of the Republican Army and his experience embraces the treatment of some 5 000 gunshot wounds of the abdomen He personally operated on almost 1 000 of this number and was impressed with a particular symptom complex which he designated the retroperitoneal syndrome

This term should not be applied to the clinical picture associated with extraperitoneal wounds involving only such organs as the kidney and bladder It should be reserved for the syndrome in which the dominating injury appears to be sympathetic ganglia and plexuses in the upper retroperitoneal region (Bastos 1928) The characteristic features are pallor and progressive weakness of the pulse without any accompanying peritonitis The pallor begins in the hands and then spreads gradually to all exposed parts of the body The face often cyanotic, is bathed in cold perspiration The pulse grows weaker and weaker and disappears sometime before death supervenes

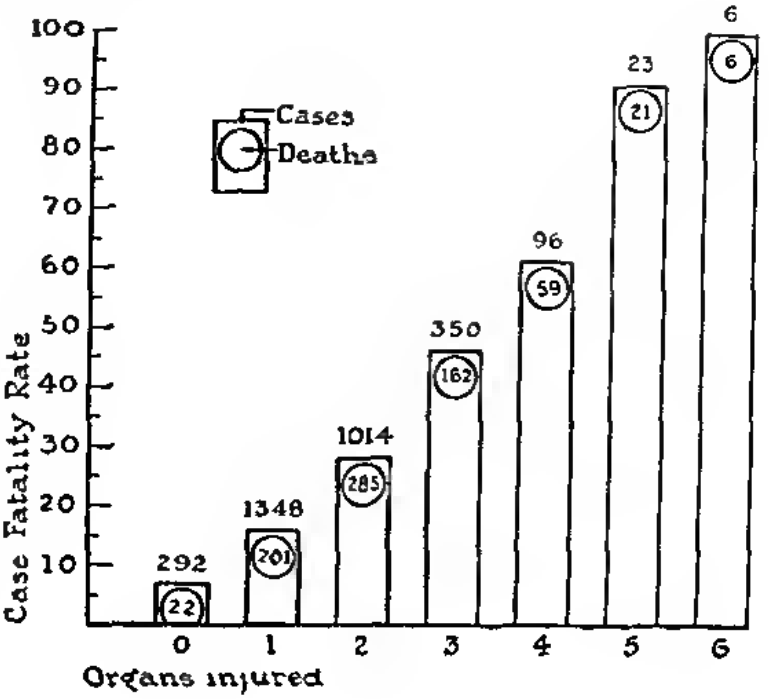


Fig 7 3 Influence of multiplicity factor on case fatality rates in 3,129 recorded abdominal injuries

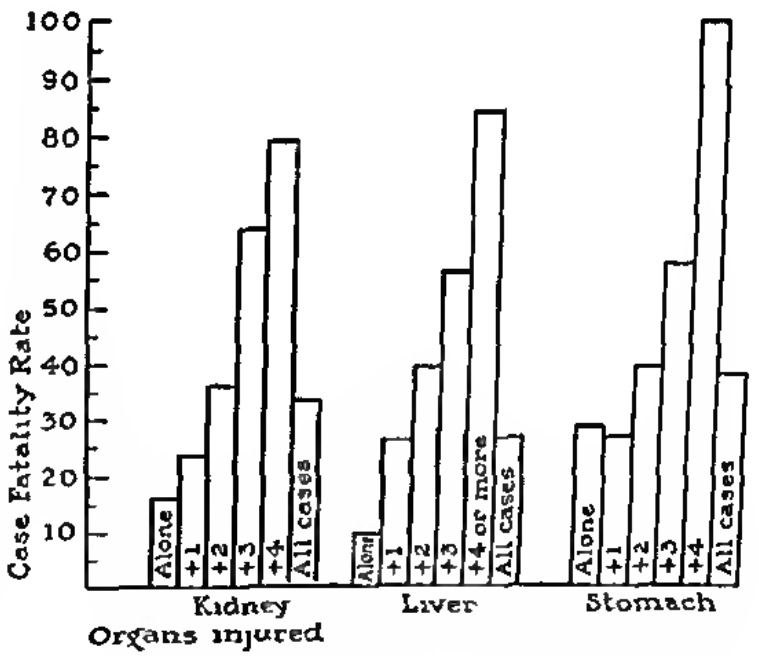


Fig 7 4 Influence of multiplicity factor on case fatality rates in various combinations of abdominal wounds

A shotgun fired at close range is lethal, fired at a distance it may be innocuous Prognosis can be related to the age and state of health of the wounded individual Many studies in civil practice confirm the finding that youth recovers where the middle aged and elderly die It can also be related to treatment When related to treatment, we must consider adequate resuscitation hemorrhage control, and management of shock We must also consider time lag and the many facets of the operation performed Statistics of the Second Auxiliary Surgical Group related to time lag and the multiplicity factor are given in Figures 7 2 to 7 6

In his discussion of the prognosis of abdominal wounds, Jolly states

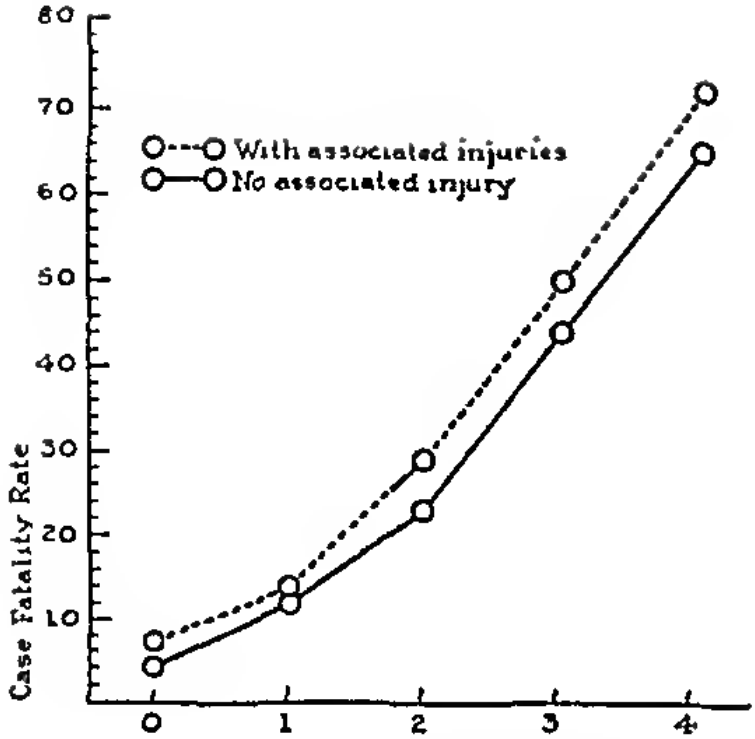


Fig 7-5 Influence of multiplicity factor and presence of associated injuries in 3,154 abdominal injuries

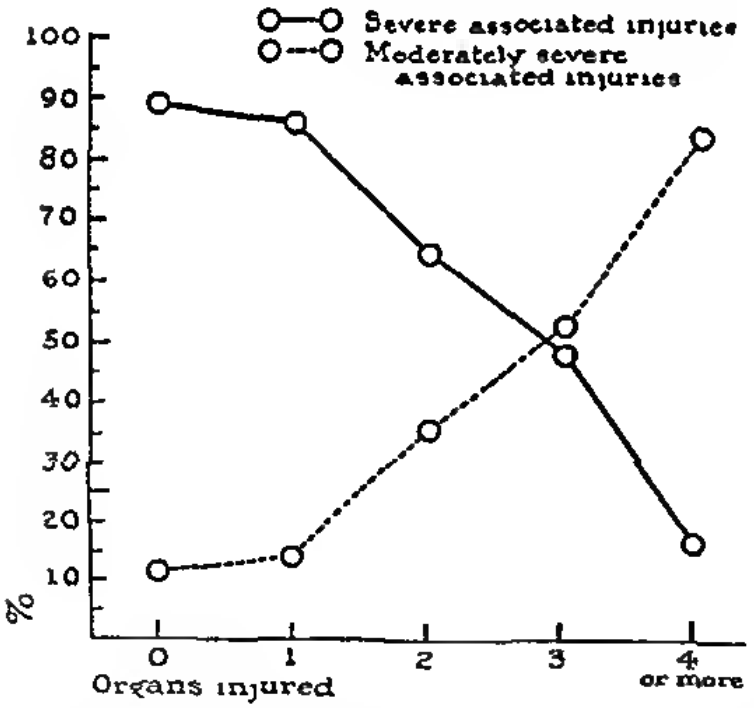


Fig 7 6 Influence of multiplicity factor and gravity of associated injuries in 3,154 abdominal injuries

*In the end the prognosis can only be* determined by the subsequent history of the patient This is a truism, but it serves to draw attention to the fact that a man with a small perforating bullet wound of the peritoneum, which does not involve any vital structure, may die of peritonitis, whereas another may *live, after wounds which seem completely* incompatible with life This fact must always be borne in mind in considering whether or not to operate in apparently hopeless cases *

* *By permission of author and publisher from* D W Jolly, *Field Surgery in Total War* Paul B Hoeber, Inc, 1941

## COMPLICATIONS

Bowers grouped the complications of penetrating wounds of the abdomen under three major headings The majority were either pulmonary or infectious and a small but varied group were of a miscellaneous character

The complications of penetrating wounds of the abdomen are either (1) peculiar to abdominal wounding or surgery, or (2) incidental to wounding in general, or to any surgery They may be acute or chronic, early or remote, major or minor

Complications peculiar to abdominal wounding or surgery include peritonitis, abscess formation (retroperitoneal, pelvic, and subdiaphragmatic), pylephlebitis wound infection, wound dehiscence, ventral hernia, gastrointestinal fistula formation sinus tract formation intestinal obstruction, secondary hemorrhage—of which hemobilia* is a rare but interesting example—traumatic cyst formation and metabolic or nutritional deficiencies

Complications incidental to wounding in general or to any surgery, include pneumonitis, atelectasis, pulmonary edema acute gastric dilatation ileus thrombophlebitis pulmonary embolism drug reaction, transfusion reaction serum hepatitis, urinary suppression, lower nephron nephrosis, osteomyelitis septicemia, fat embolism, acute noncontagious parotitis, acute cholecystitis acute nonspecific orchitis, anaphylactic shock premature delivery, and arteriovenous fistula formation

The peritonitis that occurs following abdominal wounding is always infectious if it is of significant duration Sterile abdominal wounds are not received outside of the surgical theater It is true that early initial chemical peritonitis from upper gastrointestinal tract injuries may be contained and may subside with suction total body rest, and induced gastrointestinal rest by the method of Ochsner This is particularly true in this age of antibiotic coverage The bile, however, is generally chemically irritative and often infective Pancreatic ferments are lethal These substances must be removed by adequate drainage Local drainage is indicated for upper abdominal wounds involving the liver, the biliary tract, or the pancreas or for flank wounds involving the kidney or bladder that have resulted in the collection of urine Extraperitoneal drainage is preferable to transperitoneal drainage The general peritoneal cavity cannot be drained A mixed bacterial flora is responsible for infectious peritonitis and subsequent abscess formation Secondary hemorrhage generally occurs as a result of an infection or an autolytic necrotizing process It may result from technical error, such as slippage of a ligature, failure to treat a lesion that subsequently bleeds, or overlooking a lesion altogether This may occur when the operation has been a part of resuscitation and was begun with the patient in a hypotensive state As recovery progresses, bleeding points in organs checked early in the course of the exploratory operation may become active and go unnoticed

Wound infections including gas infections are frequent in war surgery and play a significant part in subsequent wound dehiscence ventral hernia and sinus tract formation Retained foreign bodies contribute to the formation of abscesses, persistent sinuses and fistulas Small bowel fistulas seldom require operative interference to effect a cure Contrasted to lower bowel fistulas which require at least proximal diversion of the fecal stream if not the direct excision of the fistula tract these small bowel fistulas tend to close spontaneously with or without suction

We know that a temporary ileus is anticipated following penetrating abdominal wounds and surgical exploration and that prolonged and distressing ileus which eventually responds to conservative therapy, is not too rare Significant ileus occurred in the Second Auxiliary Surgical Group Study of 3 090 patients with ab-

* The term "hemobilia" was introduced by Sandblom in 1948 to indicate bleeding into the biliary tree owing to trauma, and is analogous to hematuria

dominal wounds about as frequently as did wound infection, abscess formation gas infections, gastrointestinal fistula, and urinary suppression We have no accurate knowledge of the frequency of late manifestations of intestinal adhesions

Hemobilia is a rare complication, but one not infrequently seen in severe central disruptions of liver substance It may follow puncture wounds severe lacerations or ruptures It may even be a late complication secondary to abscess within the liver substance The central rupture of the liver, which frequently is the cause of this condition is more often a result of the compression phenomenon and therefore more apt to be seen in nonpenetrating abdominal wounds than in penetrating wounds

Both penetrating and blunt abdominal wounding may have been sustained by the same patient, coincidentally, or in rapid or delayed sequence The extension of the central hepatic rupture to or near the portal fissure may readily establish the communication between the vascular tree and one of the larger hepatic ducts Thus blood gains entrance to the duodenum and produces hematemesis and melena The great danger of hepatic rupture is bleeding particularly from the portal vein branches The veins of the liver have little supporting tissue and do not tend to collapse When mixed with bile, the blood shows little tendency to clot In addition to the mere loss of blood the distress of hematemesis and the fright of massive passage of bloody stools distention of the gallbladder and gallbladder pain may result from hemobilia Jaundice may ensue as a result of absorption of pigment from the large liver cysts or as a consequence of the obstruction of bile ducts by a blood clot especially in the common duct

Recently Spector reviewed the literature on hemobilia and pointed to the variety of procedures which have been tried in attempts to control this distressing complication He indicated the frequent futile efforts that characterize the experience of most surgeons who deal with this type of trauma

Literature contains reports of 9 patients operated upon Twenty two laparotomies were performed on these patients including such procedures as exploratory laparotomy (Burnett *et al*, and Hart), common duct drainage (Burnett *et al*, and Hart), cholecystectomy, (Epstein and Lapschutz, Iranius), cholecystectomy (Hawthorne Oaks and Reeve Diegel), jejunostomy (Hermanson and Cabitt) duodenal transection with posterior gastroenterostomy (Hermanson and Cabitt), suture of liver (Burnett, *et al*, Epstein and Lapschutz, Sparkman) packing through an abdominal approach (Bigger, Hermanson and Cabitt Sparkman) and packing through a thoracoabdominal approach (Burnett *et al*) *

As is often the case, the cycle of severe exsanguinating hemorrhages is repeated over the course of days or weeks Spector observed such a case During the original laparotomy, packing was placed and drainage established The initial laparotomy incision was reopened for the second operation The liver cavity was increased in size and repacked with gauze In the third operation, a thoracoabdominal incision was used Bile was present in the pleural cavity The cyst which had increased in size was evacuated Two new cysts were found The entire cyst was interlocked with No 3 chromic catgut suture curetted and Gelfoam and gauze packing were placed A fourth operation was necessary to control the recurrent symptoms The right hepatic artery was dissected out and ligated and cure was the result In all cases mentioned in Spector s report the complication of hemobilia followed blunt trauma

Traumatic or false cyst formation occurs most frequently after injury to the pancreas spleen and liver Metabolic or nutritional deficiencies result from severe damage to the pancreas which deprives the body of its endocrine or exocrine function or both Gastrectomy may cause anemia and weight loss Extensive small intestinal resections may result in absorptive deficiency as may a high enterocolic or enterocutaneous fistula Persistent loss

* *By permission of author and publisher from* Nathan Spector *Annals of Surgery 145* 247 1957 J B Lippincott publisher

of intestinal fluid, if not assiduously attended to and accurately replaced, causes water and electrolyte deficiencies

The complications of wounding in general, or of any surgery, most frequently encountered are pulmonary in nature The remaining miscellaneous complications are infrequently seen

## INITIAL MANAGEMENT

Attempts at diagnosis and resuscitative efforts should proceed simultaneously An over all appraisal of the patient's condition should be made When the patient is brought in, examination should be made under the best lighting obtainable Unnecessary and careless movement of the patient or of any extremity should be avoided Clothing should be cut away and removed If possible, the patient should be carefully placed on a freshly dressed litter This is particularly important if the injury has been sustained by explosion, with the possibility of fragmentation of primary or secondary missile wounding Movement should be kept to a minimum and the patient should remain on this new litter for examination, roentgenograms, and even for the operation, if necessary When the condition is so precarious that movement from the initial litter is not possible prior to examination, metal fragments in the litter or blankets may cause considerable confusion in subsequent x ray examinations The blood pressure should be taken and recorded immediately This should be repeated frequently during the course of the examination and at least every 30 minutes until surgery, as the condition warrants Stopgap measures should be attended to when the patient is first brought in His cardiorespiratory status should be checked, and if found to be inadequate, it should be corrected By this we mean that the patient's airway must be freely open and unobstructed by tissue, secretions blood, or a foreign body His respiratory exchange should be proceeding well No massive pneumothorax, hemothorax or sucking wound of the chest should be present All air and blood in the thoracic cavities should be removed by repeated aspiration Sucking wounds should be tamponed by several layers of flattened vaseline gauze covered by fluffs and taped down with elastic compresses in order to permit flutter-valve action There should be egress but not suction of air Endotracheal catheter suction is most useful If necessary, bronchoscopy should be done Hemorrhage from any source should be controlled by the simplest and most effective means

A Levin tube should be placed in the stomach and the contents aspirated to determine if blood is present Not all stomach wounds will cause blood in the gastric aspirate Constant suction helps prevent aspiration pneumonia and aids in reducing distress from gastric atony and dilatation which commonly accompany low chest or abdominal wounding

Fractures should be splinted if this has not already been done If the patient is conscious while these things are being accomplished he should be questioned as to the time and place of injury He should be asked what, in his opinion is the nature of the injury, what was the cause and at what range was the injury received (the wounded soldier is frequently able to tell what type of agent was responsible for his wound) He should be queried as to whether there has been any intervening aid especially if any drugs for the control of pain have been given, whether tetanus toxoid was given, what he was doing when he was injured, in what position he received his wound, and from what direction Should the patient be unconscious or unable to reply satisfactorily, other attempts should be made to obtain this information Eyewitnesses, or other persons less seriously injured in the same encounter or accident, should be sought and questioned

An intravenous infusion with a large bore needle should have been established after blood was drawn for typing and cross matching Dextran of a molecular weight of 60 000 to 80 000 and run in rapidly enough to keep the intravenous infusion open has been advocated as a

useful preliminary, but experience has shown that certainly no more than 2,000 cc of dextran should be given without also giving whole blood In the absence of a satisfactory colloidal substance, 5 per cent glucose and normal saline or normal saline solution alone can be used for this purpose

Almost without exception, chemical or biologic agents, such as metrazol, caffeine sodium benzoate, coramine, norepinephrine, chlorpromazine, ACTH, and cortisone have no place in the resuscitative efforts of the seriously wounded The physiologic effects of these drugs when used in such cases are variable, and in most situations response is unpredictable The serious physiologic effects on other vital organs may ultimately confuse and compound the seriousness of a situation

In extreme circumstances some of these agents may be useful but they should be given only by one who is familiar with their effects and one who is prepared to watch the patient s every response The dosage should be titrated and the drug administered according to these carefully observed responses When these drugs are used they shoud be based upon individual evaluation and indications, and *their use should never be part of a standard operating procedure*

Perhaps the most useful and least dangerous adjunctive use of a drug in resuscitation is the wet syringe administration' of 0 25 per cent neosynephrine solution The judicious use of neosynephrine by this method may be invaluable in gaining a slight cardiostimulatory response and a slight increase in peripheral vascular tonus A tired circulatory system may thus be rescued from the verge of the vicious cycle of collapse

If a patient's history reveals that he has been given replacement hydrocortisone or hydrocortisone therapy for arthritis before his wounding for example appropriate dosages of this drug should be given It may also be necessary in cases of shock when adrenal failure seems to have supervened

In instances of gram negative bacteremia and toxicity, as is sometimes seen in spreading retroperitoneal infection and complicating colon damage, the early recognition of such a condition and the support obtained from adrenal cortical extract may be lifesaving

The wounded diabetic patient must be given appropriate dosages of insulin to avoid diabetic coma, and because of the stress caused by wounding, increased dosages are generally indicated

When it is obvious, upon first inspection, that the patient is severely wounded, careful and detailed inspection of the wounded areas should be undertaken After removing all previously placed dressings, wounds should be cataloged as to whether they are avulsion, laceration puncture by missile or weapon, penetrating, or perforating All such wounds in the lower thorax, upper thigh and perineal areas, and the lumbar and gluteal areas should be viewed with the utmost suspicion, inasmuch as a direct abdominal wound is apt to be more obvious It is important that maturity of judgment and experience be exercised early in treating the severely wounded, since it becomes increasingly difficult to know where to begin and where to stop in the treatment of the wounded patient Here we should emphasize, however, that all measures described are merely stopgaps to maintain life and to permit bringing the patient to operation for his abdominal wounds as soon as possible As stated elsewhere, after lethality of the wound itself, *the time lag between injury and surgery is the most important element in the recovery rate*

Larrey, Napoleon Bonaparte's surgeon formulated a rule that definitive care for wounds be given in sequence, with the slightest wound being attended first and the most major wound last If the major and severe wound were to be attended first the patient might be exhausted and in no condition to have further attention or he might even refuse further attention altogether In Larrey s day, abdominal wounds were almost uniformly fatal if not from hemorrhage and shock, then from subsequent sepsis The blessing of anes

thesia relieves us from Larrey's plight We must know, however, that certain wounds should be treated first and certain minor or relatively minor wounds should be attended to before major abdominal exploration is begun

In the preliminary evaluation of the abdominally wounded patient, Michels insists that more information can be gained by tracing the course of the missile than by any other means This is invaluable in planning the management of the patient and the operative approach

Shefts reports the following illustrative case

During the Battle for Monte Cassino in World War II, a 23 year-old white male soldier was admitted to a platoon of a field hospital following wounding by a German burp gun (automatic rifle) At the time of wounding, the soldier was moving up and leaning forward in ascending a hill (The wound of entrance was just medial to the nipple line in the left 8th intercostal space and the wound of exit in the left posterior axillary line well below the tip of the 12th rib) *

The patient was operated on on the usual operating table in such circumstances (two wooden sawhorses under the original litter on which he was evacuated from the collecting station) This obviates the necessity for repeated removal of the patient from the litter to the operating table to the litter, to the postoperative cot When desired sawhorses of different heights make the Trendelenberg position readily available The patient was turned on his right side after induction of anesthesia and endotracheal intubation, and so strapped into position A left transdiaphragmatic approach was used The 9th rib was shattered and was removed Blood was removed from the pleural cavity and the diaphragm opened The perforation in the diaphragm was too antero-medial to include in the incision The perforation and hematoma of the tip of the left lower lobe were seen not to be leaking air nor bleeding and were not disturbed The perforations in the stomach were temporarily clamped and a splenectomy was done Purse string and mattress sutures of cotton closed the gastric perforations Further exploration revealed a laceration of the splenic flexure of the colon This was temporarily clamped and in the necessary mobilization for exteriorization of the tom colon the lateral reflection of the peritoneum was incised and a considerable hemorrhage promptly ensued Further exploration revealed the upper portion of the kidney was lacerated and a branch of the renal artery to the upper pole was severed With surprising lack of technical difficulty a nephrectomy was done The small bowel was then inspected and no injuries noted The colon laceration was then exteriorized just inferior to the costal margin, in this particular case as a loop colostomy The diaphragmatic incision and perforation were then closed The pleural cavity was lavaged with warm saline Antero and posterolateral intercostal tubes were inserted and attached to water traps and the thoracic incision closed During the operation the anesthetist maintained the left lung in considerable expansion and fully expanded it during closure At completion of the operation as the patient was taken past the roentgenographic station en route to the postoperative tent a roentgenogram of the chest revealed a fully expanded left lung

The actual details of the pre and post operative phases are lacking in this case (These phases were conducted according to established principles )* That this is correct is shown by the fact that he withstood the necessary surgery and was evacuated to the rear in good condition with a functioning colostomy on the tenth postoperative day It is to be understood that it is not suggested that kidneys be removed in this fashion Had time been taken in the shock tent to grossly examine the urine, involvement of the kidney would probably have been known Having been forewarned, a flank approach, in addition to a transdiaphragmatic approach might have permitted preservation of part of the kidney An approach limited to the abdomen only would in this case, have been technically more difficult, considering all that had to be done Had it been technically difficult through the diaphragmatic approach the entire operative area could have been greatly enlarged by merely extending the thoracic incision through the costal margin diagonally across the upper abdomen The patient's position (lying on his right side) makes this an excellent maneuver The entire operative area is then held open by shifting the rib extractor to the level of the

* Parenthetical sentence ours

costal margin To have made it easier to explore the kidney, the abdominal portion of the incision could have been extended from the costal margin as a left rectus incision *

Questioning should reveal whether the patient has vomited and what the nature of the vomitus was Vomiting is a frequent occurrence with gastrointestinal injuries We agree with Jolly in that the patient with pinched facies and fecal vomiting is in dire straits and that death is imminent although an acute gastrocolic communication may be responsible for such vomiting rather early after injury

The bladder should be catheterized and the urine checked for blood With bladder tears scant amounts of urine or none at all may be recovered If there is suspicion of bladder injury, a small measured amount of normal saline should be easily introduced to assure that the catheter is not plugged If the bladder is torn this saline cannot as a rule be recovered The catheter used for such a procedure should be an indwelling Foley catheter in order to assure that hourly urine samples can be measured and recorded

A digital rectal examination should be made to determine whether rectal tear exists If blood appears on the gloved finger it may indicate rectal or gastrointestinal injury *Proctoscopic examination* may reveal small rectal tears that cannot otherwise be diagnosed

The abdomen should be palpated for foreign bodies or tenderness Peritoneal irritation may be localized around points of obvious injury or it may be diffuse The diffuse and severe tenderness of peritonitis from upper gastrointestinal chemicals is early in onset and is unrelenting That of fecal contamination is just as exquisite but is much later in onset usually occurring within six to eight hours or more The peritoneal irritation from blood alone is variable but frequently the abdomen is soft and doughy rather than rigid, and the signs of peritoneal irritation are diminished in quality or intensity as well as in number Rebound or referred tenderness sometimes points to a locus of internal damage but is not reliable A mass representing a hematoma or a displaced organ or missile may be palpable early In the pouch of Douglas fluctuant mass may be blood urine intestinal fluid or fecal matter Incidental lesions may be discovered Gordon Taylor recounts instances of wounding in the 1940–41 air raids on Britain in which incidental surgery was accomplished for hitherto unsuspected intra abdominal malignant lesions as well as for congenital defects This should not be emphasized but it should be kept in mind

Auscultation of the chest and abdomen must be done The presence of peristalsis is a good indication that the gastrointestinal tract itself is uninvolved While the absence of peristalsis is frequent it does not mean that there is injury to the intestinal tract Most severe wounds of the abdominal lower thoracic or lumbar region will be associated with an adynamic ileus If impelling indications for exploration do not exist judicious observation and resuscitative measures are continued and the bowel sounds will generally reappear in a matter of hours In unusual instances ileus may last for eight or more days but it would be the rare surgeon indeed who could observe a patient through the first six to ten hours without subjecting him to exploratory laparotomy when there is even the most remote possibility of the existence of penetrating wounds especially if the general condition or extra abdominal status of the patient permitted operation

Bowel sounds clearly heard in the chest may denote herniation through a torn diaphragm Signs and symptoms of shock of course must be considered The blood pressure obtained initially and recorded serially if not at shock levels indicates either normalcy or normal readings masking blood volume loss Values may be low for a usually hypertensive patient and thus represent shock level figures or they may be so called normal values obtained early

* *By permission of author and publisher from* L. M Shefts *Initial Management by Thoracic and Thoracoabdominal Surgery* Charles C Thomas 1956

which do not at this point reflect the loss of blood volume These normal blood pressure readings may be maintaind by sympathetic tone and peripheral vascular contraction The pulse in such instances is slow and full rather than thready and rapid This state has been referred to as compensated shock and is a precarious state Decompensation results from (1) failure adequately to replace the blood loss (2) by continued blood loss and (3) by careless handling or turning of the patient Failure to maintain blood pressure in a semirecumbent or in a sitting position has been observed in this condition by physiologists for years Recently a rough estimation of blood volume loss or adequacy of replacement and the ability of the patient to withstand surgery has been gauged by this reaction Artz and others in Korea devised a standard tilt table for use in testing for this condition

We should now recognize the effectiveness of ministrations while observing the nature of blood loss Failure of the external pressure to control visible bleeding as indicated by either continued visible bleeding or failure to recover or maintain blood pressure while transfusion is in progress indicates that bleeding is coming from an internal source and operation becomes a vital part of resuscitation If the blood repeatedly wells up it indicates that blood is being trapped in the abdominal or thoracic cavity

Blood may be introduced into several veins simultaneously No appreciable benefit is achieved by initiating intra arterial transfusions at this stage of resuscitation Blood may be introduced under pressure by manual pumping The use of plastic containers eliminates the hazard of air embolism Patients in whom an operation must be begun while their systolic pressure is below 80 mm Hg have a markedly lowered survival rate *

* In Korea improved mortality figures were thought by many to be due to a great extent to early and ample use of whole blood replacement Low titer type 0 blood was used extensively The amount of blood necessary in each instance must be determined from clinical experience

We must insure that the patient has received proper antitetanus therapy If he has been immunized a 1 cc toxoid booster is sufficient if not 2 500 to 5 000 units of tetanus antitoxin must be given If it is impossible to determine whether the patient has been previously protected against tetanus and there is not sufficient time to test for sensitivity to horse serum or to desensitize prior to surgery toxoid should be given Such a patient should also be protected with desensitization if necessary and with the antitoxin regimen as soon after surgery as possible

The prophylactic use of gas gangrene polyvalent antitoxin is not advised although therapeutic administration in the established case is encouraged

At this point the patient has already received penicillin and streptomycin or broad spectrum antibiotics by vein He has if necessary been given morphine sulphate in 6 to 10 mg doses intravenously for pain and this may have been repeated in four to six hours

## OPERATIVE MANAGEMENT

### Decision for and Timing of Operation

As soon as the diagnosis of penetrating wound of the abdomen has been established the indication for operative intervention is clear After an effort has been made to anticipate the organ damage by plotting the course of the wounding agent and correlating this information with that gained by clinical observation of signs and symptoms and the patient s response to resuscitation the decision is made for operation and the proper approach is determined

The time for operation is as near as possible to that of the accident and should be consistent with proper diagnosis and resuscitation If there is an indication of continued intra abdominal bleeding or difficulty in recovering or maintaining effective blood pressure (70 to 80 mm Hg systolic) during the resuscitative effort the operation should be started immediately In spite of the proper use of

antibiotics the "golden period for operative intervention remains at six hours

## Attributes of the Surgeon

Resolution of purpose technical skill and a thorough knowledge of anatomy should be the attributes of the surgeon who undertakes the exploratory operation Speed should not interdict thoroughness but such surgery should not be performed by an indecisive plodder or one incapable of alacrity Gentleness in handling tissues should not be sacrificed upon the altar of speed

## Principles of Wound Surgery

Good principles of wound surgery demand thorough debridement of soft tissue including that of the abdominal wall back and gluteal wounds Should there be wounds of the buttocks or perineum these wounds must be explored excised or opened extensively and dressed first Then the patient should be turned to the laparotomy position and the abdominal operation performed Should this sequence not be followed severe hypotension that may even fail to respond to rapid transfusion may ensue Where multiple wounds exist the patient s general condition and state of resuscitation may necessitate a laparotomy before general anterior debridement in order to control hemorrhage In general such wounds are debrided and left open Delayed primary closure in 4 to 10 days is practiced

Generally a paramedian incision with retraction of the rectus muscle will prove to be the most satisfactory and will provide ample exposure and more secure closure with less likelihood of complicating ventral hernia A laparotomy incision may include excision of a missile or weapon tract If speed in entry is indicated in order to control hemorrhage adequate exposure may be gained by a linea alba incision There should be no hesitation in making a bold incision from the xiphoid to just above the pubis in perforating wounds where multiple organ damage is anticipated Some experienced surgeons have used transverse incision generally including wound excisions when localized intra abdominal injury is suspected The most important point is that exposure must be adequate for a thorough abdominal exploration

If there is an associated thoracic wound it must be decided whether the chest or the abdomen should be operated on first or whether a thoracicoabdominal incision should be employed Left sided lesions lend themselves to the thoracicoabdominal route far better than do the right sided because of the inability to retract the liver and gain sufficient access for thorough abdominal exploration In general unless it is absolutely necessary that the abdomen be entered to deal with exsanguinating hemorrhage the cardiopulmonary physiology had best be assured by initial thoracotomy Wounds limited to the left hypochondrium in association with left sided chest damage may be dealt with via thoracotomy and the transdiaphragmatic approach

## Anesthesia

Proper and satisfactory anesthesia is one of the most important factors in the survival of the seriously injured patient The surgeon needs the services of a trained anesthesiologist to assist him in this phase of management

Preoperative medication for seriously wounded patients should be limited to the beladonna alkaloid group atropin 0 4 to 0 6 mg intravenously 10 to 15 minutes before surgery Should time permit this dosage may be administered subcutaneously 30 to 60 minutes before induction of anesthesia

Caution is the watchword in the administration of opiates A seriously wounded patient in impending shock generally requires no opiates A patient in shock certainly requires none If he has been given morphine subcutaneously or intramuscularly during first aid treatment he may exhibit signs of an overdose of morphine as resuscitative efforts prove ef

fective and peripheral deposits of morphine are picked up by the recovered circulations If there is great pain or if pain may be contributing to a perpetuation or aggravation of shock morphine should be given intravenously in 5 mg to 10 mg doses 15 to 30 minutes before surgery The patient who is intoxicated and semianesthetized by alcohol should not be given opiates and extra precaution must be observed to guard his airway and prevent aspiration

The choice of anesthetic agent should be left to the anesthesiologist In general the patient will fare better if given a form of anesthesia with which the skilled anesthesiologist is most familiar The least amount of anesthetic agent possible and the greatest amount of oxygen sufficient to maintain depth and provide adequate relaxation are the amounts required for this type of surgery

The severely wounded person does not need and will not tolerate the concentration and dosage of volatile or nonvolatile drugs usually administered to the average patient Administration of such dosage will produce respiratory and circulatory depression and may result in profound shock Paravertebral intercostal and regional abdominal block with procaine hydrochloride or lidocaine may be of great assistance in relieving local pain and providing relaxation that will permit the use of light anesthesia

The various gases and intravenous agents have such marked additional effects on the cardiac action and the peripheral vascular bed that they should be employed only by the expert anesthetist

Beecher in World War II found that the use of intravenous Sodium Pentothal for the laparotomy was associated with a twofold to tenfold increase in the mortality rate

Experience has shown that spinal anesthesia is apt to be lethal when used for a patient in shock or incipient shock and it is definitely contraindicated in the patient with a penetrating abdominal wound

In World War II the majority of anesthetics were administered by doctors who were not primarily trained in anesthesiology Under the circumstances the use of ether and oxygen or ether and air were the most satisfactory An endotracheal tube was inserted in each patient subjected to abdominal exploration and this is still the ideal procedure It is imperative that endotracheal anesthesia be administered if the chest cavity must be opened

## Exploratory Laparotomy

The manner in which we perform our laparotomies is similar in almost all respects to most of the other recorded descriptions It is merely a plan or guide that has proved useful for us as well as for many others who have had extensive experience with trauma

A careful preparation of the abdomen by any acceptable procedure is carried out (shaving Zintel s four cup method pHisoHex soap and water iodine alcohol) After the abdomen has been opened through the indicated incision immediate attention is directed toward controlling any significant bleeding as quickly as possible It should be kept in mind that the most common sources of significant bleeding are the spleen liver mesentery small bowel stomach and kidneys In Madding s series of war wounds only 9 per cent of the injured livers showed persistent hemorrhage at the time of operation which was almost always at least three hours after injury It is quite possible that the instances of persistent bleeding from the liver might be greater as the time lag between injury and operation is shortened This points up the fact however that liver bleeding tends to be controlled of itself and as Madding noted pressure is generally all that is required to stop liver bleeding If there is bleeding from this organ the laceration should be reapproximated and a pack should be placed against the liver and compressed by an assistant s hand or by retractor as a systematic search is being made to exclude other possible persistent bleeding points

A thorough and systematic search is

aided by eviscerating the small bowel Caution should be taken that no loops are brought out when a severe tear in the radix of the mesentery has been found, since such a maneuver might further increase the mesenteric rent The bowel that is brought out should be protected by large warm laparotomy tapes With the small intestine delivered onto the abdominal wall, the spleen and liver are more accessible for examination, and continued spillage of intestinal contents will be outside the peritoneal cavity rather than into the peritoneal cavity One may begin either cephalad or caudad on the small bowel, but the entire small gut should be traversed from end to end, duodenum to cecum, in an orderly fashion, and all openings should be initially tagged closed with Allis forceps or hemostats and their location noted

The tangential wound is rare, and if an odd number of perforations is found efforts should be redoubled to exclude the possibility of a hidden perforation Perforations at the mesenteric border are often obscured by hematomas in the mesentery A wounded Meckel s diverticulum should be removed by wedge excision, a wounded appendix by standard appendectomy The colon is then examined from cecum to rectum, and perforations are closed either by suture or by clamping as they are encountered

Injuries to the bladder and pelvic organs in the female should be noted Some idea of the status of the solid organs, particularly of the liver and the spleen, has already been gained upon initial entrance If these did not require immediate attention then, however they should, at this point in the operation be carefully checked along with the pancreas, kidneys and stomach If there is an upper abdominal injury and the anterior wall of the stomach has been damaged the posterior wall must be checked This is done by opening the lesser sac through the gastrocolic omentum The status of the mesentery is observed as the bowel is being checked The great vessels are checked last for hidden evidence of damage By the time this much of the operation has been accomplished, any vascular lesions of the mesentery that had been cared for earlier by ligature have now produced demarcation or evidence of circulatory embarrassment to a portion of the bowel If 100 per cent oxygen is administered to the patient for approximately two minutes, it will, by contrast, make even more obvious any such line of demarcation, and the necessity for or extent of resection can be better judged

Before passing on to the phase of repair careful attention must be given to the fixed portions of bowel particularly to the duodenum and the colon flexures which, together with the posterior wall of the stomach, are those injuries most frequently missed Another commonly missed injury is the wound of the ureter, and evidence of damage to the ureter should be sought

It is only after an over-all appraisal of the extent of abdominal injury in terms of the degree of damage to each organ and the number of organs involved compared to the general condition of the patient and his tolerance of the procedure that an appropriate plan for restitution can be formulated In general, injuries that are most severe or pose a continuing threat are cared for first. All rents in the mesentery should be repaired All free lying or easily accessible foreign bodies should be removed Retroperitoneal hematomas, if more than moderate in size or questionably associated with retroperitoneal wounding of a hollow viscus should be explored and drained It is usually futile to attempt to evacuate and control points hemorrhaging into a retroperitoneal hematoma Pressure and packing during the operation will suffice

After complete repair a thorough toilet of the peritoneal cavity is accomplished by suction and washing with a saline solution Intraperitoneal antibiotics are not used routinely, although in gross fecal contamination of several hours' duration, 1,000-000 units of crystalline penicillin and 1 Gm of streptomycin might be employed intraperitoneally A neomycin solution may be injected into the lumen of the bowel but should not be given intraperitoneally

The use of various sulfa crystals, dusted intraperitoneally or directly into the wound is no longer acceptable The peritoneal cavity itself is not drained All efforts should be made to close the peritoneum, if closure is not possible, a ventral hernia is assured, and dehiscence is an extreme likelihood In this latter respect, we refer to those cases in which the skin must be mobilized and closed over a large tissue void resulting from an avulsion or necessary extensive debridement The peritoneum is closed with either a running or interrupted suture of chromic catgut This layer should also include the transversalis fascia The second layer should be of muscular aponeurotic fascia or anterior rectus sheath This closure should be made with interrupted catgut If there has been gross contamination, or if the wounding has been extensive, stainless steel wire retention sutures should be used These sutures should pass through skin, subcutaneous tissue, and anterior rectus sheath on one side, and anterior rectus sheath subcutaneous tissue, and skin on the other As these are brought together, the skin margins may be approximated and still allow wound drainage In all instances where retention sutures are not used the skin should be closed with nonabsorbable sutures This may also be accomplished in some instances where retention sutures are used

## TREATMENT OF SPECIFIC ORGAN INJURIES

### Stomach

Stomach injuries are frequent in all types of abdominal wounding These wounds should be closed with minimal marginal debridement Resection is seldom necessary Careful exploration requires careful inspection of the fundal region and the posterior wall where most injuries are overlooked Exposure is limited and observation restricted when approach to the posterior wall is made through the gastrohepatic omentum and this approach is not advised We recommend opening the gastrocolic omentum to allow entrance to the lesser sac Closure advocated for stomach wounds is a simple layer type Small puncture wounds have been successfully closed by purse-string suture, but purse string sutures have a failing in that they are less apt to be hemostatic than the through and through catgut sutures Chromic catgut, No 00 or No 000, should be used, interrupted, running, over and-over or locked Connell's type of closure is preferred Nonabsorbable interrupted sutures are used for a seromuscular second layer When faced with a desperate situation a simple tier closure through all layers of the stomach with nonabsorbable sutures may suffice In rare instances, resection and anastomosis may be necessary

### Duodenum

Injury to the duodenum is infrequent but carries a high mortality rate, principally because the blood supply of the duodenum comes from the vasa recta of the superior and inferior pancreaticoduodenal arteries These vessels are friable and easily compressible They are almost end vessels but unlike end vessels they have a certain degree of anastomosis The duodenum however is highly susceptible to breakdown because (1) the acid peptic juice bile, and pancreatic juice, with their highest concentration in this region, are not conducive to healing, (2) there is a high incidence of associated pancreatic lesions, (3) the retroperitoneal injuries of this organ are frequently missed, and (4) wounds in this area are likely to involve the superior mesenteric vessels, the portal vein or the vena cava or aorta

The second portion of the duodenum is the most frequently wounded, both by direct injury and by explosion Gerwig reported several instances in which duodenal obstruction resulted from a hematoma in the duodenal wall, usually in the third portion Small perforations should be closed by a double tier of sutures in transverse fashion so that undue narrowing of the channel will be avoided Larger rents may require anastomosis Trimming should be minimal

In a recent case of a nonpenetrating injury at Fort Bliss Gants told of being faced with the necessity of performing a duodenopancreatectomy and anastomosis after the fashion of Whipple, because of the severe dissolution of the second portion of the duodenum and pancreas The patient made an uneventful recovery

## Small Bowel

Injuries of the small bowel generally require minimal debridement and transverse two tier closure (one may suffice but it is not recommended if time permits otherwise) Resection of the small bowel is indicated when (1) there are multiple wounds in a loop in which the closure of one would compromise the closure of another or (2) there is a loop in which so many wounds exist that much time can be saved by resection and anastomosis rather than by multiple closure or (3) a large rent exists in which closure cannot be satisfactorily performed without the hazard of compromising the lumen Of course the prime and absolute indication for resection is a nonviable gut Injuries of the gut at the mesenteric border generally require resection Wounds of the mesentery constitute a great percentage of the cases of persistent intraperitoneal hemorrhage

Upon opening the abdomen bleeding is stopped first by compression and then by ligature of the vessels Attempts at repair of the mesenteric vessels have been almost universally unsuccessful and are time consuming the vessels having been ligated early will permit demarcation in time for resection through healthy bowel The small bowel must always be anastomosed primarily and never exteriorized as a fistula An ileostomy or jejunostomy should not be done in a severely wounded person

## Gallbladder

Injury of the gallbladder is very rare The immediate spillage of bile into the peritoneal cavity may be profuse but it does not occur as relentlessly as it does from the common duct Wounds of the gallbladder are generally obvious, those of the common duct, particularly in the retroduodenal and pancreatic portions are sometimes overlooked The common duct should be repaired over a T tube The efferent member of the tube should not be brought out through the anatomosis but through a separate opening in the common duct Injuries to the cystic duct necessitate cholecystectomy Wounding of the common duct below its junction with the cystic duct when extensive and when not permitting satisfactory union over a T tube may be treated by ligature of the stumps of the duct and cholecystoenterostomy Drainage with a soft Penrose drain into Morison s pouch and perhaps another into the foramen of Winslow should always be instituted in wounds of the biliary system These drains should be brought out through a small lateral subcostal incision

## Colon

Colon wounds are best treated according to the precepts developed by Ogilvie and Churchill in World War II According to Andrasov the independently developed Russian policy is identical Such a policy is based on the premise that colon wounding spills highly infectious matter into the peritoneal cavity The time lag in war surgery is seldom less than three hours from injury to surgery and even during this time a virulent local peritonitis may be established The wounds are frequently extensive and may have actually involved greater areas of the bowel than are apparent at the time of inspection The colon is thin walled and does not hold sutures as well as other parts of the gastrointestinal tract The method most successfully used for treating severe colon wounds should be restated today since this method is apt to be forgotten by a generation of surgeons used to extensive colon surgery in an era of bowel preparation and antibiotics

Small cecal wounds may be sutured and bypassed by ileotransverse colostomy or a

cecostomy may be performed Cecostomy or exteriorization of the cecum is to be discouraged inasmuch as it is functionally much the same as an ileostomy an anathema in war surgery, with excoriating discharges and a requirement for assiduous attention to fluid and electrolyte balance and nutrition

In extensive wounding of the cecum resection and end to end ileocolostomy should be performed The right and left colons may be mobilized medially by incising the lateral avascular peritoneal reflections These should be mobilized in this manner in order to exteriorize colon wounds The hepatic and splenic flexures must also be taken down in order to exteriorize in such a way that all openings will discharge externally and to insure that there is no tendency of the bowel to retract beyond the cutaneous margin

Wounds of the rectum and descending colon that have been primarily sutured or anastomosed must be protected by a proximal fecal diversion This may be simply performed by fashioning a loop colostomy that is unattached to the skin The loop is held up without tension over two glass rods or rubber tubes as described by Wangensteen This is easily achieved when a transverse colostomy is being performed but is more difficult when an attempt is being made to bring a sigmoid loop through a left lower quadrant gridiron incision

It may be expedient to perform a spur colostomy after resection of an extended segment of colon because of vascular injury or extensive wounding The ends should be brought out through separate stab wounds and held clamped above the skin in a lax fashion without mesenteric drag in order to prevent retraction when the clamp is removed in 24 to 48 hours A loop colostomy has an advantage in that it can be vented immediately by catheter or if necessary for decompression it can be opened by incision sooner Wounds of entry or exit even though debrided should not be used for purposes of colostomy or drains

We must quote Ogilvie on the exteriorization of colon injuries had repeatedly advocated ning of World War II a haps the greatest single fa improved results in colon injuries conflict The principle that all damaged parts of the large intestine must be excluded until the process of repair is complete applies to all injuries even suspected ones and to all parts of the large bowel and particularly to the extraperitoneal portion of the rectum The following two cases are illustrative

*Case 257* Suture of retroperitoneal tear of the descending colon with drainage of the retroperitoneal space Sulfanilamide powder intraperitoneally Later a fecal fistula developed and the patient died on the ninth day Autopsy showed the wound of the colon to be broken down over a large area fecal matter lying free in the retroperitoneal tissues mild general peritonitis Comment by the surgeon Suture alone with local drainage seemed adequate a proximal colostomy should have been done

*Case 323* CSW buttock Operated upon 44 hours after injury On laparotomy the terminal ileum and ascending colon were only bruised but not perforated Retroperitoneal hematoma drained Patient collapsed and died on the fifth day At autopsy a small recent perforation on the ascending colon was found Exteriorization would have saved this patient *

During World War II Gordon Taylor indicated that perhaps the experienced surgeon should be permitted to treat a patient with colon wounding according to his own estimate of the best treatment for that individual rather than to be bound by directive Cordon Taylor Fruchaud Burbank Imes Tucker and Fey Grattan Creech and DeBakey and most recently Puestow and Gillesby, as well as many others have pleaded for the discriminate closure of or resection and anastomosis of intraperitoneal colon wounds without proximal colostomy

Pontius Creech and DeBakey recently presented their experience with 122 con

** From Surgery Gynecology & Obstetrics 78 275 1944 By permission of Surgery Gynecology & Obstetrics*

secutive cases from Houston, Texas The results indicated to them that the majority of colonic injuries encountered in civilian practice may be treated by primary repair Of 119 patients who survived operation, 83 were treated by primary repair and 36 by a two stage procedure The mortality in the entire series was 15 6 per cent, being three times greater for a two stage procedure than for the primary repair This might seem paradoxical in view of war time experience, if it were not for the fact that wounds of the colon were closed primarily only when the surgeons felt this was a reasonable thing to do Exteriorization proximal colostomy, or both were undertaken when (1) there was extensive fecal contamination, (2) when there was complete destruction of a segment of bowel and (3) when there were injuries to the rectum

The economic factor weighs heavily in civilian practice and it should be noted that the average hospital stay of those injured patients with primary closure without colostomy was 13 days as compared to 37 days for those with two stage procedures The time lag in this series was less than six hours in 97 per cent of the cases and the majority of this time was consumed in resuscitative effort

Grattan in his experience in the 1952–53 Mau Mau uprising in Kenya reported a 22 3 per cent mortality rate for eight large gut and one rectal perforation (four of these were multivisceral two with associated lung injury) He emphasized the time lag factor stating that most of the injured were admitted for treatment within two to three hours after wounding All the injuries treated were inflicted by gun shot Careful interrupted suturing of colonic lacerations in two layers or resection with colostomy (in only one case) was the treatment rendered in this group Penicillin and streptomycin cover was used Where injury was extraperitoneal drains were placed His case 7490 is remarkable

*Case 749* A very shocked patient with obvious intraperitoneal hemorrhage Admitted 14 July discharged 17 August Immediate laparotomy showed a large tear of the splenic flexure of the colon, two large holes in the jejunum, a perforation in the mesentery of the sigmoid colon, and retroperitoneally, the lacerated upper pole of the left kidney The tears in the large and small gut were repaired with interrupted cotton, the sigmoid mesentery closed the left kidney removed and the peritoneum closed three pints of fecal contaminated intraperitoneal blood were retransfused to the patient after filtering through 12 thicknesses of gauze during the operation No colostomy was performed Recovery, uneventful except for some mild abdominal distention on the first few days Culture of the contaminated blood showed coliform and other organisms *

In general, we stand by the time tested principles of Ogilvie and Churchill Taylor and Thompson elaborated upon these principles, and we are in complete agreement with their position We would re emphasize that exteriorization and diversion of the fecal stream are principles to be practiced (1) when dealing with severe gunshot wounds, (2) in a less well controlled situation than exists when dealing with a solitary patient in a stationary hospital in peacetime (3) when the surgeon s time is necessarily divided among many different patients (4) when close observation of the patient is not possible (5) when antibiotics are not available (6) when there has been injury to an unprepared bowel, or (7) when the time lag exceeds three hours

The foregoing trenchant remarks might be modified to the extent that there may be an individual patient in whom repair of a severely lacerated colon is less traumatic and less time consuming than mobilization of the segment for exteriorization would be One might also get away with primary closure of colon wounds in the three hour to six hour time period but this is generally not advisable The doctor takes the chance and the patient the risk Undoubtedly there are many other patients beyond the six hour time limit in

* *By permission of author and publisher from* F Grattan *Brit J Surg 43* 279 1955 John Wright & Sons Ltd publisher

whom healing without complication will be accomplished following primary suture but in such rare instances there should be definite contraindications against colostomy as well as indications for the performance of primary closure

### Extraperitoneal Rectum

Wounds of the extraperitoneal rectum should be closed if at all possible This closure is accomplished best from the posterior approach The fascia propria must be incised and drained and if done from this approach, it can be accomplished with utmost facility Fecal drainage into the retroperitoneal sacral hollow must be prevented by a complete diversion of the fecal stream by proximal colostomy

### Buttocks

Extensive wounds of the buttocks should be debrided initially, and even though it has been ascertained by the surgeon that there is no rectal or colon damage a proximal diverting colostomy should be performed

### Kidney

Renal injuries should be treated expectantly if possible with every effort being made to conserve the kidney If time and the condition of the patient permit excretory urography should be done before surgery to determine renal function status as well as to confirm the presence of two kidneys in a patient in whom renal damage is suspected When the kidney is found to be damaged at the time of exploration whether previously suspected or not every effort should be made to conserve this organ It may be cleaned reapproximated and sutured The perirenal space should be drained through the flank Severe damage to the renal pedicle may necessitate nephrectomy Early repair of a damaged renal pelvis may be performed at the same time nephrostomy is done External drainage of a perforated kidney may be all that is necessary but an effort should be made to obtain hemostasis by packing or by suture Repair should be made with catgut suture If upon abdominal exploration discoveries are made that would usually warrant nephrectomy the presence of a second kidney should be established before the procedure is undertaken

### Ureter

Injury to the ureter is frequently overlooked The incidence of injury is rare and solitary injury is exceedingly so The injured ureter is best repaired over a splint a regular ureteral catheter passed through the proximal end into the renal pelvis and into the distal end This should lie free in the bladder and be removed at a later date via the cystoscope The ureter may also be repaired over a T tube with the end of the tube brought out through the flank In dire emergency both ends may be catheterized in situ and the catheters brought out through the flank This maneuver will prevent the urine from being discharged directly into the abdominal cavity and will serve as a guide to the surgeons responsible for reconstruction Catgut suture material should be used to repair the ureter

### Bladder

The urinary bladder when damaged may be repaired by simple catgut suture through full thickness avoiding the mucosa if possible A suprapubic cystostomy should accompany repair and soft rubber drains should be placed in the perivesical openings and into the space of Retzius The bladder may be wounded extraperitoneally in which case it may be sutured from below at the time of associated rectal repair or a posterior wall rent may be sutured from the inside through the opened bladder With regard to the suprapubic cystostomy a Foley de Pezzer or Malecot catheter should be placed as high in the fundus of the bladder as possible and brought up straight through the wound well away from the symphysis pubis This procedure avoids pressure on the pubic bone and subsequent periostitis

and osteomyelitis If the continuity of the bladder and urethra have been interrupted a Foley catheter must be passed through the urethra and into the bladder The bag should be inflated and the neck of the bladder pulled down A suprapubic cystostomy should be performed whenever the bladder has been wounded

## Ovaries and Tubes

If possible the ovaries and tubes should be preserved in the young female Only simple reparative processes should therefore be resorted to When more elaborate plastic repair is indicated there are generally other wounds that would dissuade one from this time consuming type of procedure

## Uterus

The uterus may be the source of continued hemorrhage Small wounds can generally be closed with through and through interrupted chromic catgut sutures More than a simple wound may require hysterectomy

## Liver

The liver is one of the most frequently injured organs within the abdomen and is the most frequently injured of all the solid viscera Most liver wounds if unassociated with other injury can be treated expectantly This means that the patient who is thought to have only a liver wound may be observed for a little longer than if he were known to have a perforated hollow viscus

Madding has shown that only about 1 in 10 injured patients will show persistent bleeding from the liver at the time of celiotomy This also means that conservative methods may be employed in stopping liver hemorrhage Mere pressure will generally suffice Fractured fragments of the liver should be removed When possible the intrahepatic bile ducts and vessels on the margin of the fractured segment should be ligated separately as is done in resection of the liver Moderately sized lacerations after being reapproximated may be sutured with a large blunt needle and coarse suture material tied over Gelfoam or omental tags

If it is apparent that vessels to the liver have been injured and reconstruction by suture is not possible the vessels should then be ligated Whether these vessels are reconstructed or ligated patients who have liver injury or damage to a major branch of the hepatic artery should be given a broad spectrum antibiotic Chlortetracycline has been most effective We would discourage packing Gelfoam muscle stamps and particularly, gauze packing into the liver since such materials contribute to intrahepatic abscess cyst formation and secondary hemorrhage A soft rubber drain placed into liver substance is preferred It is imperative that all wounds of the liver be drained with sufficient large wide soft Penrose drains over the dome of the liver in the subphrenic and subhepatic spaces to prevent collection of fluid (bile and peritoneal exudate) which may cause abscess formation

The hemorrhage associated with liver injury while frequently self controlled is also one of the most common sources of hemorrhage among patients who have continued intra abdominal bleeding These patients may require a great amount of blood and if blood is not readily available intraperitoneal blood even though it may be mixed with bile is satisfactory for reinfusion after proper filtering

Penetrating wounds of the liver are associated with a high incidence of wounds of the stomach and particularly of the diaphragm and lungs These additional injuries must be carefully searched for and wounds of the diaphragm especially on the left side must be sutured to prevent herniation of abdominal contents into the chest cavity Wounds of the bare area of the liver whether they involve the diaphragm or not and regardless of whether the diaphragm is repaired or not are frequently accompanied by a bile tinged pleural effusion A biliary pleural effusion is a fairly frequent consequence of wound

ing of the pleural cavity diaphragm and liver

## Spleen

In penetrating wounds of the abdomen the spleen may be ruptured by contusion or it may actually be penetrated by the missile or the weapon There is a high incidence of injury to the splenic flexure of the colon pancreas stomach diaphragm and left pleura and a not infrequent concomitant injury to the liver A wounded or bruised spleen must be removed inasmuch as delayed rupture of the injured spleen is apt to occur The hemorrhage from the torn spleen may be massive Wherever possible the injured spleen should be removed after the fashion of Dunphy This is done by incising the posterior peritoneal reflection in the fused lienorenal ligament and by bringing the spleen up into the abdominal wound The hilum is then approached from behind better to protect the tail of the pancreas and the greater curvature of the stomach If it is thought that the pancreas has been damaged during splenectomy it is imperative that a drain be placed down to this area

## Pancreas

In perforating abdominal wounds trauma to the pancreas may be direct or indirect Direct trauma is certainly rare and is almost always associated with wounding of other organs Pancreatic wounds are lethal for essentially the same reason as are duodenal wounds Pancreatic ferments which are released almost invariably cause severe chemical peritonitis Such a response may be at least initially confined to the lesser peritoneal sac and may lead to delayed diagnostic difficulties Characteristic pancreatic wounding in which severe damage to that organ results is a secondary pancreatitis This may be acute and hemorrhagic or it may appear at a later date as chronic pancreatitis cyst or pseudocyst of the pancreas The pancreas is well supplied with blood in addition to its intrinsic supply there is the proximity of this organ to major vascular structures such as the aorta the vena cava and the splenic artery and vein the inferior mesenteric vein and the superior mesenteric artery and vein It is this particular anatomical situation that makes the mortality rate high

Pancreatic parenchyma holds sutures poorly The capsule must be utilized for suturing and nonabsorbable suture material is advocated Wounds of the head of the pancreas are almost invariably fatal In such cases it is wise to attempt to suture only the capsule or to control hemorrhage by *deep suturing* Penrose drains should be placed in the same manner as they are for biliary tract surgery Sump drains can be used to good advantage on both sides of the abdomen near the head and tail of the pancreas

Pancreatic tail and body lesions are best treated by resection of the affected part together with splenectomy Bilateral flank drainage should be established More common complications of pancreatic wounding are pancreatic abscess pancreatic fistulas and the formation of pseudocysts External pancreatic fistulas should be treated conservatively in the hope that the fistula will close Continuous suction usually permits closure within the course of several weeks Great difficulty is experienced with autolysis of tissue with excoriation of skin and with maintenance of adequate fluid balance If the fistula is still unremitting after several months of antibiotic protection it may be excised or implanted in the jejunum Pseudocysts are best treated by internal drainage and abscesses are treated with antibiotics and surgical drainage followed by aspiration of the drainage tract Diabetes may be another late manifestation of severe pancreatic wounding

## Adrenal Glands

The adrenal glands fortunately are placed bilaterally with the spinal column intervening If one adrenal is damaged bleeding can be controlled by packing and no functional loss will be observed

When the adrenal gland is involved in penetrating wounds of the abdomen there frequently is damage to the great vessels, with early mortality or associated injury to the duodenum or the kidneys

### Great Vessels

Any damage to the abdominal aorta is almost uniformly fatal When damage has not produced injury to all coats of the aorta, aneurysms or arteriovenous fistula formation may be a late manifestation If there has been severe damage to the inferior vena cava or portal vein, fatal and rapid hemorrhage is likely to ensue Some injuries of the vena cava, however, tamponade themselves by formation of a retroperitoneal hematoma Suture repair of the injured vessels is advocated over ligation when such rare cases are discovered Massive bleeding has generally ceased by the time of celiotomy, and is not apt to recur until the hematoma is disturbed

Starzl *et al* have reported their experiences with vena caval injuries They suggest that when a retroperitoneal hematoma is discovered in the proximity of the great vessels, a methodical program for exploration of the retroperitoneal space should be accomplished before the hematoma is manipulated This should include procurement of a large quantity of blood, adjustment of lighting, preparation of necessary vascular instruments, and planned wide exposure

For caval injuries at or below the transverse mesocolon, one may approach the retroperitoneal space by reflection of the small bowel and its mesentery to the right, or by reflection of the right side of the colon to the left The ultimate in exposure is gained by a combination of these two maneuvers, reflecting the small bowel, right colon and related mesenteries in a cephalad direction For injuries above the transverse mesocolon, the hepatic and transverse colon, as well as the transverse mesocolon, are swept inferiorly The retroperitoneal area can then be entered with wide exposure with the Kocher maneuver *

* *By permission of author and publisher from* E T Starzl *et al*, *The American Surgeon 23* 455, 1957, Williams & Wilkins Company publishers

## POSTOPERATIVE MANAGEMENT

### Movement and Handling of Patients

Rarely does postoperative management for these patients vary from the ordinary postoperative care administered on well-run recovery wards After return to the recovery ward from the operating room, the patient must be handled as gently as he has been throughout the entire period of management Those who have been severely wounded and who have undergone laparotomy are subject to acute loss of vascular tone and to profound shock upon slight provocation Shock at this stage of management is often the result of rough handling or movement A patient in this condition should not be transported before 8 to 10 days after operation Less seriously wounded patients who have had a laparotomy may be ambulatory early and transported sooner

### Gastric Decoropression

The nasogastric tube should be checked frequently to assure its proper function in maintaining gastric decompression A satisfactory suction device can be improvised with two liter bottles, stoppers, and glass tubing, or simple siphonage may be used For many years, Matas found the latter practice to be reasonably successful While many modern suction machines are distinct improvements over the makeshift suction apparatus or simple siphonage, the importance of gastric decompression in the early management of the problems under consideration is to be emphasized, and any available method that will insure constant decompression must be used

If unchecked, gastric dilatation may be great enough to perpetuate shock by reflex neurogenic mechanisms or direct mechanical pressure It may also embarrass respirations, or cause breakdown and leakage of a gastric suture line

The nasogastric suction is discontinued upon failure to recover anything but a clear aspirate, and upon resumption of normal intestinal activity as manifested by good bowel sounds, passage of gas from

rectum or colostomy or actual passage of stool This generally is possible by the second or third day

### Intravenous Alimentation

Intravenous alimentation is necessary until intestinal activity has been resumed but supplemental intravenous feedings may be carried on for a few additional days The daily fluid intake should be gauged to approximately 3 000 cc It is better however if this is based upon measured losses of urine gastric suction and enteric discharges Fluid and electrolyte balance can be maintained In the immediate postoperative period it will be impossible to maintain adequate caloric intake and nitrogen balance A reasonably healthy person however even though he may be seriously injured will if well handled and particularly if he is young be able to withstand this temporary privation and will recover

Saline solution should be used to replace measured gastric losses If enteric losses are indicated potassium may have to be given but salt and particularly potassium should be given with caution to a severely wounded person since he may be a candidate for renal shutdown between the second and eighth postoperative day

The hourly urinary output must be carefully measured in the critically wounded person and maintained at hourly levels of at least 20 cc In two or three days if the patient appears to be recovering well and there is no reason why he should not be able to void with ease the indwelling catheter may be removed

### Antibiotic Coverage

Antibiotic coverage should be employed At present the broad spectrum antibiotics such as tetracycline hydrochloride appear to be most useful Penicillin and streptomycin in combination are still effective agents in preventing peritonitis in most instances of abdominal wounding The usual safeguards and management of antibiotic therapy apply as to the type of antibiotic the dosage, and the duration of treatment

### Nursing Care

Proper nursing care for colostomy and fistula discharges must be afforded to protect the patient s skin and to preserve a pleasant atmosphere particularly in conditions of crowding A clean and orderly recovery area for these patients is conducive to their feeling of well being and to a good mental attitude for recovery

Drains should be shortened generally on the fourth to sixth day and removed altogether by the seventh This permits a tract to be established that will function if necessary and gradually close when the need no longer exists

Skin sutures should be removed in 7 to 10 days if the healing has progressed well If wound inflammation is present sutures may be removed sooner but if at all possible this should be done before the patient s transport Wire retention sutures may be allowed to remain as long as deemed necessary usually for 10 days to 4 weeks and even in the presence of suppuration

Delayed primary wound closure must be accomplished some time between the fourth and tenth days Under any circumstances this closure is best done with stainless steel wire sutures but the use of stainless steel wire is especially desirable if the patient is to be transferred to another hospital for recuperation or reconstructive surgery

The patient s open wounds should be dressed in a sterile manner at all times to prevent external contamination and secondary infection

## MASS CASUALTIES

Because of the great skill and amount of time required to observe prepare and operate upon persons receiving abdominal wounds in a mass casualty situation there must be a deviation from the priority concept as normally applied to abdominal wounding The person wounded in the

abdomen in such circumstances must almost invariably be set aside in order that necessary treatment for a greater number of sufferers can be undertaken When a decision is made for operation upon a patient with this type of wound however, under no circumstances should such an operation be haphazard or devoid of any of the compelling thoroughness that should characterize every abdominal exploration nor should insufficient postoperative management be permitted

All positive steps for the care of these patients should be instituted and carried out in the hope that outside surgical assistance will arrive or that the case load will be cleared and thus permit a return to treatment priorities acceptable under normal circumstances

Abdominally wounded patients awaiting normal priority care in a mass casualty situation should be given antibiotics preferably by injection A nasogastric tube should be placed to act as a siphon and attached to a suction device whenever available Small intravenous dosages of morphia may be administered to control pain Intravenous barbiturates should be used to allay apprehension when necessary Feeding should be by the intravenous route and water may be given in small sips merely to keep the mouth moist

## CONCLUSIONS

In the treatment of penetrating abdominal wounds the factor of the severity of the injury itself is the most important from the standpoint of survival Subfactors involved in this concept are (1) the type of agent responsible for wounding (2) specific organ or organs involved (patients with great vessel injuries rarely survive to come to operation) and (3) the multiplicity factor as it applies to multiple abdominal organs and to associated injuries In general there is an arithmetical increase in mortality corresponding with the increased number of organs involved This also holds true for associated injuries that is extra abdominal injuries in conjunction with abdominal wounds Patients with severe associated wounds but with relatively minor abdominal wounds are statistically in as great jeopardy as when the reverse is true From the statistical standpoint of survival, every wound compounds the importance of another

Time lag is the second most important factor related to mortality from abdominal wounds It is immediately apparent from a review of the thousands of cases of abdominal wounding presented in the literature that with rare exception patients dying within 24 hours of wounding, do so from acute hemorrhage Those who die within 48 hours from hypovolemic shock (acute persistent delayed or uncorrected hemorrhage) as well as the majority who die after three days do so from the infection generally peritonitis The early use of antibiotics has reduced the number of infections

A change has been witnessed in the concept of time lag Initially its importance was realized as the time from injury to surgery Now its importance is reckoned in the time between wounding and the institution of resuscitative measures that may include surgery and do include attention to the whole wound and the whole body The factor of time lag is the basis of the concept of forward surgery for the severely wounded It is the basis for reduced mortality figures from civil institutions where a large volume of surgery for trauma is practiced

The importance of the time factor as it relates to survival cannot be measured in terms of hours alone for an obvious corollary exists in the salvage by early resuscitation of the increased numbers of patients who would otherwise die The corollary is a balancing factor in the opposite direction The mortality figures indeed will even show an increase as earlier resuscitative efforts are made This is especially true in the group of patients with extensive wounds who require operation as part of resuscitation in order to control continuing hemorrhage If the patients in this category had not been brought to the emergency room or to the forward surgical hospital they would have succumbed

to the severity of the wound and would not weigh in the final operative statistics

Resuscitation and diagnosis should proceed concomitantly

Reasonable suspicion that a penetrating wound of the abdomen exists is indication for exploratory laparotomy

Every operation must be thorough and precise, hidden visceral lesions in the retroperitoneal areas must not be overlooked Each operation must proceed according to a preconceived plan, to assure attention to all possible sites of wounding

The safest treatment for colon wounding is that of closure with proximal diversion of the fecal stream by colostomy or by exteriorization of the wound

Postoperative management must be given as much attention as is given to the phases of resuscitation, diagnosis, and operation

## REFERENCES


ANDRASOV, P I *Personal communication*

ARTZ, C P Evaluation of the use of a standard tilt test table Surgical Forum *Proceedings of the Fortieth Clinical Congress of the American College of Surgeons* Philadelphia, W B Saunders Co, 1955, p 803

BERRY, F B Surgery in the field for wounds of the abdomen *Bull U S Army M Dept 6* 140, 1946

BOWERS, W F Surgical treatment in abdominal trauma A comparison of results in war and peace *Mil Med 118* 9, 1956

CHURCHILL, E D Theater experiences in wounds of the abdomen *M Bull North African Theater Op (No 3) 1* 2, 1944

DUNPHY, J E Splenectomy for trauma *Am J Surg 71* 450, 1946

EISBERG, H B The diagnosis and treatment of penetrating abdominal wounds *Am J Surg 5* 145, 1928

Forward Surgery of the Severely Wounded A history of the activities of the Second Auxiliary Surgical Group, 1942–1945 *Report to The Surgeon General, U S Army, 27 Aug 1945*

GANTS, R T *Personal communication*

GERWIG, W *Personal communication*

GORDON-TAYLOR, G Second thoughts on the abdominal surgery of the total war—a review of over 1,300 cases *Brit J Surg 32* 126, 247, 1944

GORDON TAYLOR, G "The Management of Abdominal Injuries in Warfare and in Civil Life" (Chap 43), in MAINGOT, *The Management of Abdominal Operations* New York, The Macmillan Co, 1953

GRATTAN, E Gunshot and sword wounds of thorax and abdomen *Brit J Surg 43* 279, 1955

HAMILTON, J E Peritoneoscopy in gunshot and stab wounds of the abdomen *Surgery 7* 582, 1940

IMES, P R War surgery of the abdomen *Surg Gynec & Obst 18* 608, 1945

IMES, P R Abdominal trauma *Ann J Surg 73* 199, 1947

IMES, P R Emergency management of abdominal trauma *S Clin North America*, Oct 1956, p 1289

JOLLY, D W *Field Surgery in Total War* New York, Paul B Hoeber, Inc, 1941

JONES, H, FALOR, W, and BURBANK, C B 524 abdominal wounds on the Western Front *Bull Johns Hopkins Hosp*, 79 283, 1946

LAGARDE, L A *Gunshot Injuries*, 2d ed (rev) New York, Wm Woods Co, 1916

LEE, BURTON J Wounds in the Abdomen' *The Medical Department of the United States Army in the World War*, vol XI, part I, chap XV, p 443 Washington, U S Government Printing Office, 1927

MADDING, G, *et al* War wounds of the liver *Texas State J Med 42* 267, 1946

MATAS, R Discussion of paper by Loria Abdomino thoracic gunshot wounds *New Orleans M & S J 95* 195, 1942

MEDICAL DEPARTMENT, UNITED STATES ARMY *Surgery in World War II*, vol II, *General Surgery* Washington, U S Government Printing Office, 1955

MICHAELS, L M Preoperative diagnosis of recent wounds of abdomen *Arch Surg 52* 135, 1946

MITCHINER, P H, and COWELL, E M *Medical Organization and Surgical Practice in Air Raids*, 2d ed New York, Blakiston Co, 1939, p 172

OBERHELMAN, H A, and LECOUNT, E R Peacetime bullet wounds of the abdomen *Arch Surg 32* 373, 1936

OGILVIE, W H Abdominal wounds in the Western Desert *Surg Gynec & Obst 78* 225, 1944

POER, D H Penetrating abdominal injuries,

comparative military and civilian experience *Ann Surg 127* 1092, 1948

PONTIUS, R G, CREECH, O, JR, and DE BAKEY, M E Management of large bowel injuries in civilian practice *Ann Surg 146* 291, 1957

PUESTOW, C G, and GILLESBY, W J Pitfalls of abdominal trauma *S Clin North America*, Feb 1958, p 131

SAKO, Y, ARTZ, C P, HOWARD, J M, BRONWELL, A W, and INUI, F K A Survey of evacuation, resuscitation, and mortality in a forward surgical hospital *Surgery 37* 602, 1955

SANDBLOM, P Hemorrhage into the biliary tract following trauma "Traumatic hemobilia," *Surgery 24* 571, 1948

SHEFTS, L M *Initial Management of Thoracic and Thoracoabdominal Trauma* Springfield, Ill Charles C Thomas, 1956

SPECTOR, N Ligation of the right hepatic artery in hemobilia, report of a case with recovery *Ann Surg 145* 244, 1957

SLOCUM, H, and JENICEK, J Anesthetic considerations of the acutely injured patient *Illinois M J 110* 6-281, 1956

STARZI, T L, BROADWAY, R K, DEVER, R C, and REAMS, G B The management of penetrating wounds of the inferior vena cava *Am Surgeon 23*-455, 1957

TAYLOR, E R, and THOMPSON, J E The early treatment, and results thereof, of injuries of the colon and rectum, with 70 additional cases *Internat Abstr Surg 87* 105, 209, 1948, in *Surg Gynec & Obst*, Aug, Sept, 1948

TUCKER, J W, and FEY, W P Management of perforating injuries of the colon and rectum in civilian practice *Surgery 35* 213 1954

WANGENSTEEN, O H Complete fecal diversion achieved by simple loop colostomy *Surg Gynec & Obst 84*-409, 1947

WILKINSON, R S, HILL, L M, and WRIGHT, L T Gunshot wounds of the abdomen *Surgery 19*-415, 1946

WILLIS, B C Shotgun wounds of the abdomen *Am J Surg 28*-407, 1935

longer intervals and then the vomiting becomes projectile In the final stages, the stomach becomes flabby and atonic and projectile vomiting ceases, being replaced by the effortless overflow of gastric content Blood or bile is rarely seen in the vomitus The attacks of vomiting are not preceded or accompanied by pain, but constipation is very common.

### *Diagnosis*

Four fifths of the patients are males, generally ranging from four to six weeks of age Some degree of dehydration is manifest clinically Signs of weight loss, shrinking of skin, sunken appearance of the eyes, and a decrease of subcutaneous fat are more characteristic of the advanced stages of the disease

When the abdomen is examined, it will be seen that the upper half is bulging and domelike, while the lower half is empty and flaccid. Visible waves of peristalsis will be observed in most cases, these waves will outline the position of the stomach, and the point where they disappear will indicate the position of the pylorus. The visible peristalsis is specially marked after a feeding or after stimulating the skin over the upper part of the abdomen

The tumor may be discovered by careful and repeated abdominal palpation in 95 to 100 per cent of cases The examiner should be careful not to confuse the lower pole of the right kidney with the tumor.

### *Differential Diagnosis*

Pylorospasm must be distinguished from pyloric stenosis In the former condition, medical treatment generally elicits a quick response and no palpable tumor is present. In cases of congenital duodenal atresia and malrotation of the colon, the agent of obstruction is present at birth and the infant begins vomiting shortly thereafter Bile is usually noted in the vomitus and again no tumor is palpable

Intracranial injury, hemorrhage from birth trauma, and hemorrhagic disease are frequent causes of vomiting and must be considered in the differential diagnosis. Chalasia of the cardia is associated with persistent vomiting but lacks the other signs of pyloric stenosis, this condition can be differentiated from pyloric stenosis by roentgenologic examination

A poor feeding program can induce vomiting with clinical symptoms and signs that often simulate those of pyloric stenosis

Since the signs and symptoms of pyloric stenosis are sufficiently well defined to establish conclusively the proper diagnosis, roentgenologic examination is not necessary in the average case In the atypical case or when the physical findings are inconclusive, however, it is best to obtain additional information by roentgenologic study These findings include (1) an enlarged stomach with a rounded end, (2) greatly increased gastric peristalsis, (3) passage of the barium to the pylorus but escape of only tiny amounts into the duodenum, (4) an elongated and greatly narrowed, threadlike pyloric lumen, and (5) abnormal retention of barium in the stomach

### *Treatment*

To obtain good surgical results and low mortality rates, it is essential that preoperative support be given to babies who are dehydrated or in whom poor electrolyte balance is present Attention must be directed toward the treatment of ketosis and replacement of body fluids, electrolytes, and carbohydrate stores. As long as three to four days should be spent in preparing these patients carefully Such cases do not constitute surgical emergencies and operation should not be performed without due preparation

In 1912 Ramstedt described the operation that is now universally employed in the treatment of pyloric stenosis in infants This procedure consists of splitting the hypertrophied circular muscle in its longitudinal axis but not incising the mucosa. The mucosa is allowed to pout out into the slit in the muscle No attempt is made to cover over the muscular defect.

The greatest danger in this operation is the possibility of perforating the mucosa,

this accident generally occurs at the duodenal end of the pylorus Any small opening can be closed with one or two mucosal inverting sutures It is a good practice to tie a wad of omentum into these sutures to help seal any subsequent leak

The postoperative tolerance of these patients for feedings varies considerably It is important that the amount of each feeding be kept reasonably small Occasional vomiting may occur for a few days after operation, but this gradually subsides Supplemental parenteral fluids are usually given during the first 48 hours

*Results*

A review of the surgical results at the Children's Hospital in Boston from 1946 to 1952 shows that 642 infants were treated with a 0 7 per cent mortality from all causes For babies who had only pyloric stenosis (and no other abnormality) the mortality was 0 3 per cent

Patients who have recovered from the operative procedures have had excellent and lasting relief of symptoms Some of these individuals have had follow ups lasting well into adult life without developing any subsequent gastric disability

## Gastric Diverticula

Gastric diverticula are rounded pouch-shaped, or sachke protrusions from the stomach They may be true diverticula or false diverticula that are caused by intrinsic lesions of the gastric wall such as peptic ulcer and neoplasms The true diverticula are probably congenital and all the layers of the gastric wall are present in the pouch

*Etiology*

These diverticula have been found in patients of all ages, but most have been discovered in those ranging from 30 to 60 years Some authors feel that true diverticula are caused by malformation or arrested development during fetal life There is no convincing evidence that organic disease is a causative factor

*Pathology*

Gastric diverticula occur most often in the region of the cardia, close to the esophageal opening on the lesser curvature. The sites next in order of frequency are the anterior wall, the pyloric region, and the posterior wall of the stomach Size and shape vary from 1 to 6 cm at the point of greatest diameter The diameter of the opening varies considerably and this bears an important relationship to the presence or absence of symptoms and to the ability to visualize the lesions by x ray

*Signs and Symptoms*

True diverticula may cause no symptoms although in some instances when the pouch has failed to empty normally, epigastric fullness and distress flatulent dyspepsia, and gnawing pain have resulted In rare instances the local stasis is followed by diverticulitis and peridiverticulitis, when this occurs, the pain is accentuated Ulceration of the mucous membrane of the sac may likewise produce pain, but this is uncommon

*Diagnosis*

Gastric diverticula present no typical clinical picture and they can be diagnosed only by means of roentgenologic examination, gastroscopy, or operation

Diverticula are frequently found in association with some other symptom producing lesion Those that arise from the anterior or posterior wall may be easily overlooked on routine roentgenologic studies The commonest mistake in interpretation is to confuse the diverticulum with a large, penetrating ulcer Diverticula however, usually occur in those portions of the stomach where ulcers are rarely seen that is, the cardia, the fundus, and along the greater curvature

Gastroscopy may help in diagnosis Tracey doubts the value of the procedure in the diagnosis of gastric diverticula, and gives an explicit warning about the possibility of perforating a diverticulum with a wide opening in the cardial region, which is rather inaccessible to the

gastroscope Tanner, on the other hand, notes that diverticula can usually be differentiated from penetrating ulcer by gastroscopic examination

*Treatment*

When diverticula causing no distress and not associated with any concomitant gastric lesion are discovered incidentally on roentgenological examination, operation should not be performed Medical treatment is advised for those patients who have only mild symptoms Operation is advised (1) when symptoms are severe and when medical therapy fails to control them (2) when complications such as perforation or hemorrhage have occurred, (3) when the diagnosis is uncertain and the presence of malignant disease cannot be excluded, (4) when an associated lesion (gastric ulcer) is present, (5) in cases of prepyloric diverticula, and (6) when the pedicle is narrow and the fundus of the diverticulum is large, in which case diverticulitis is likely to develop

The best approach to diverticula of the cardia is that devised by Walters This consists of dividing the gastrosplenic omentum and turning the fundus upward and inward When the stomach is fully rotated, the sac will readily come into view and after the neck is exposed by gauze dissection it will be seen to arise from the posterior wall of the stomach close to the cardiac orifice Lesions in this location can best be approached by the transthoracic route

In some instances, especially when the sac appears to be somewhat inaccessible, it may be wise merely to invert it rather than excise it Diverticula of the greater curvature should be removed by V excision of the diverticulum and adjacent gastric wall Diverticula of the pyloric region or diverticula with an associated gastric lesion are best handled by the performance of subtotal gastrectomy

*Results*

The immediate and late results of excision of gastric diverticula are highly satisfactory In a series of 114 planned procedures reported by Palmer, simple amputation was carried out in 86 instances, invagination in 12, and subtotal gastric resection in 16

## VOLVULUS

Volvulus of the stomach was first described by Berti in 1866 and has been recognized with increasing frequency since Rosselet and Gilbert reported the first case observed roentgenographically in 1922 It is probable that this condition occurs even more commonly than the literature would indicate

*Etiology*

The topographic classification of von Haberer and the etiologic classification of Payer are useful in establishing the cause and nature of the volvulus in any given case

I Type
- A Organoaxial rotation of the stomach upward around the long axis of the stomach (that is, around the coronal plane)
  - 1 Supracolic
  - 2 Infracolic
- B Mesenteroaxial rotation of the stomach from right to left or left to right around the long axis of the gastrohepatic omentum

II Extent
- A Total the whole stomach except the diaphragmatic attachment is rotated
- B Partial the rotation is limited to a segment of the stomach, usually the pyloric end

III Direction
- A Anterior the rotating part passes forward
- B Posterior the rotating part passes backward

IV Etiology
- A Secondary to disease in the stomach or adjoining organs (Payer)

1 Hernia or eventration of the diaphragm
2 Tumors of the stomach
3 Inflammatory process
4 Peptic ulcer and/or hourglass stomach
5 Postoperative conditions
6 Displacement by neighboring organs including the gravid uterus

B Idiopathic

V Severity

A Acute presenting the picture of an acute abdominal condition

B Chronic asymptomatic, or causing constant or recurrent milder symptoms

Many cases of gastric volvulus are associated with a pronounced degree of gastroptosis combined with congenital lengthening of the gastrohepatic omentum and gastrocolic ligament Normally, the gastrophrenic and gastrolienal ligaments are sufficiently firm and strong in their normal positions that they serve to anchor and support the upper portion of the fundus of the stomach, as well as the splenic flexure of the colon, in such a position as to prevent extreme torsion It would appear that any factor precipitating volvulus must include laxness of these structures The etiologic relationship of the colon should be investigated in all cases Faulty peritoneal attachment of the duodenum should also be considered

*Pathology*

Rotation of the stomach upward around the longitudinal axis is known as organo axial volvulus, the stomach twists from left to right and from below upward When volvulus is complete, the anterior surface faces backward while the posterior surface will be seen under the abdominal wall, sometimes veiled by the gastrocolic omentum Rotation of the stomach from left to right or vice versa around the sagittal plane is known as mesenteroaxial volvulus

*Signs and Symptoms*

The changes associated with distention of the transverse colon secondary to volvulus of the stomach produce relatively minor symptoms In severe cases of distention and displacement, the symptoms of gastrointestinal obstruction may be pronounced The extent, direction, and severity of the volvulus account for a variable pattern of symptoms that may be noted in the same patient The Borchardt-Lenormont triad is frequently encountered in acute cases and is a useful diagnostic sign

1 Severe retching without vomiting
2 Circumscribed epigastric pain
3 Impossibility of passing a stomach tube

*Diagnosis*

Volvulus should be considered in all patients with upper abdominal symptoms particularly when these are acute, and when a definite diagnosis cannot be made The diagnosis of acute gastric volvulus with extreme torsion is rarely made preoperatively

The abdominal survey film leads to a differential diagnosis that includes the presence of free air under the diaphragm from a perforated viscus or pneumoperitoneum, air containing subphrenic abscess, and hepatodiaphragmatic interposition of the colon The latter condition is not uncommonly associated with a biloculated appearance of the gas filled stomach

Barium studies are necessary to differentiate volvulus and cascade stomach The differential points include (1) one fluid level in cascade action and two in volvulus, (2) the greater curvature is not apparent in cascade stomach, whereas it is seen in volvulus, (3) in volvulus the uppermost rotated greater curvature forms a convex curve continuous with the duodenum and resembling an apparent, enlarged duodenal sweep In cascade action the relationships are normal, with the greater curvature being lowermost and not forming a continuous convex curve;

the duodenal loop is also normal (4) In cascade action the entrance of the esophagus is in the normal position just below the diaphragm The unusual and low position of the cardiac orifice will be noted in cases of volvulus

### *Treatment*

The treatment of gastric volvulus is surgical When the usual picture of acute dilatation of the stomach is present and when the Levin tube cannot be passed, laparotomy is indicated Simple untwisting, detorsion, and replacement of the stomach and bowel into normal abdominal position appear to be inadequate methods of treatment except in the seriously ill patient who has no associated lesion requiring immediate surgical correction

The surgical procedures to be employed depend upon the etiology of the volvulus and upon the condition of the stomach and contiguous structures at the time of operation If the stomach is extremely mobile, posterior gastrojejunostomy is a useful and easily performed procedure Repair of concomitant hiatus hernia or eventration of the diaphragm is essential in elective cases In recurrent cases associated with hepatodiaphragmatic interposition of the colon, primary resection of the transverse colon is sometimes necessary to effect a cure

It is a good general plan to limit the extent of any corrective surgical measures to a minimum More radical procedures such as gastric resection should be reserved for a second procedure if necessary when the patient's general condition will be improved

### *Results*

Scattered reports in the literature indicate good results in the surgical management of gastric volvulus when a readily identifiable cause can be recognized and corrected Obstructing gastric volvulus occurring postoperatively presents a more difficult problem, and early diagnosis is important to assure a satisfactory result

## GASTRITIS

The problems associated with the several varieties of gastritis are related largely to difficulties in establishing the diagnosis and differentiation of these chronic lesions from malignant tumors of the stomach The following classification of gastritis is helpful clinically

A Acute gastritis
B Chronic gastritis
  1 Atrophic gastritis
  2 Hypertrophic gastritis

### Acute Gastritis

There are several clearly defined forms of acute gastritis (1) simple, (2) corrosive, (3) infectious, (4) phlegmonous, and (5) necrotizing

*Simple gastritis* is caused by alcohol, drugs, allergens, or it may occur postoperatively It is usually possible to determine the causative agent Medical therapy is indicated for this condition

*Corrosive gastritis* is caused by strong caustics, acids, or other chemicals Associated damage to the esophagus frequently constitutes a greater hazard to the life of the patient Conservative therapy is again indicated, reserving surgery for complications

*Infectious gastritis* is associated with the common contagious diseases such as influenza and scarlet fever It is probably a self limiting disease process

*Phlegmonous gastritis* may occur at any age It is a severe inflammatory process involving chiefly the submucosa and progressing to cause purulent infiltration and even necrosis of the stomach wall In about 70 to 80 per cent of cases, streptococci are the offending organisms The clinical picture presented by this disease may be indistinguishable from acute perforated peptic ulcer acute pancreatic necrosis, fulminating cholecystitis, peritonitis, and pyogenic liver abscess

When the condition is recognized at laparotomy, it is best left alone Drainage of an associated subphrenic or subhepatic abscess, if present, is indicated Gastric

resection has been advised for the more chronic type of phlegmonous gastritis, if the pathologic process is sufficiently localized in the distal stomach

*Necrotizing gastritis* is a synergistic infection caused by spirochetes and fusiform bacilli It is usually associated with dental sepsis and may follow dental extractions Frequently no apparent cause can be found The treatment is medical and fatalities are common

## Chronic Gastritis

Chronic gastritis is a labile condition that may regress and need not necessarily progress It may represent a late stage of acute hypertrophic gastritis This type of gastritis is frequently reactivated by intra abdominal operations

It is important to realize that interpretations of the normal by the gastroscopist and the pathologist may differ greatly When the gastroscopist recognizes gastric mucosal disease a biopsy will usually confirm his findings (91 per cent of cases) However when the mucosa appears normal on gross examination biopsy will be confirmatory in only about 56 per cent of cases

Pathologic classification of chronic gastritis should give proper emphasis to the epithelial as well as the exudative factors since the former in all probability have precancerous significance Not all stages or types of chronic gastritis can be considered precancerous When epithelial changes become severe, they may be comparable to well recognized premalignant lesions in other parts of the body These changes are often seen in cases of atrophic gastritis but are not restricted to this condition There is little doubt that some gastric cancers arise from the epithelial changes seen in severe chronic gastritis

## Atrophic Gastritis

Atrophic gastritis may be the result of a deficiency disease such as pernicious anemia, sprue, scurvy, or pellagra, or it may be the late stage of acute or chronic gastritis The frequency of gastric polyps and carcinoma is higher in cases of atrophic gastritis

Pathologically, this lesion is characterized by the progressive diminution of epithelial elements, particularly the differentiated elements at the base of the glands Metaplasia of the intestinal type appears in more and more numerous foci and eventually may entirely replace all normal gastric elements

Several interesting facts are revealed by a review of 94 cases in which pernicious anemia and gastric carcinoma occurred simultaneously A greater predominance of fundic lesions showed multicentric foci of cancer formation, thus raising a question as to the adequacy of standard subtotal gastric resection in such cases In cases of pernicious anemia gastrotomy thorough inspection and perhaps biopsy should be carried out at an exploratory operation if a tumor is not apparent on gross examination The diagnosis of pernicious anemia alone is ample justification for initial and follow up roentgenographic examination of the stomach

Subacute gastritis may well be one of the stages through which the gastric mucosa passes before assuming the appearance of atrophic gastritis

## Hypertrophic Gastritis

Hypertrophic gastritis is a disease of unknown etiology characterized by enormous enlargement of the gastric folds and associated with rather characteristic histologic changes involving the inner layers of the stomach wall It usually occurs in the fourth to sixth decades of life Gastric involvement is diffuse from cardia to pylorus but the maximum change is usually encountered in the distal stomach

The disease tends to run a protracted clinical course and the common symptoms are pain (74 per cent of cases), weight loss (60 per cent), vomiting (40 per cent) and hemorrhage (20 per cent), according to Fieber The pain resembles that of peptic ulcer, being characterized by periodicity and moderate severity with local

ization in the epigastrium Examination frequently discloses upper abdominal tenderness localized in the epigastrium Gastroscopy reveals a velvety, swollen, spongelike mucous membrane Multicentric erosions or ulcerations may be present Roentgenographic examination shows exaggerated rugae that are widened and sharply contoured Peristalsis may be irregular in depth and timing and become sluggish and ineffective, peristaltic waves may fail to compress the larger rugae Pylorospasm is common and varying degrees of antral narrowing may be seen

The diagnosis is made by suspecting the disease in all patients with ulcer diathesis The major diagnostic problem centers around differentiation of the hypertrophic lesion from carcinoma The indications for surgery are similar to those in cases of chronic peptic ulcer

The results of medical therapy are unpredictable since the disease tends to run a chronic course despite adequate medical therapy Several reports in the recent literature indicate that gastric resection has a place in the total management of this problem

## PROLAPSE OF GASTRIC MUCOSA

Prolapse of gastric mucosa was first described by Schmieden in 1911 Interest in it as a pathologic entity was revived by Eliason, Pendergrass, and Wright in 1926 when they presented the first clear cut description of the roentgen signs produced by prolapse of gastric mucosa into the duodenum Since Scott's excellent review in 1946 numerous additional cases have been reported in the literature

### *Etiology*

The etiology of this disease is obscure The common denominator in the several theories of its pathogenesis is an abnormal disturbance of gastric peristalsis and function.

### *Pathology*

Patients with prolapse of redundant gastric mucosa have a variety of symptoms that usually are influenced by the extent and condition of the prolapsed mucosa These symptoms are never characteristic and thus a clinical diagnosis of the disorder cannot be made As a general rule, the diagnosis must be made on the basis of roentgenologic findings after eliminating the possibility of all other gastrointestinal lesions Pathologically, the lesion appears as hypertrophic folds of mucous membrane showing varying degrees of edema and inflammation with areas of ulceration Antral gastritis is commonly found in association Hiatus hernia, peptic ulcer, and gallbladder disease are usually the major sources of symptoms in patients with prolapsed gastric mucosa

### *Signs and Symptoms*

The symptoms commonly attributed to prolapsed gastric mucosa include abdominal pain, epigastric distress or discomfort, gas, belching, fullness, burning, regurgitation, nausea, vomiting, bleeding, weakness, and weight loss Associated gastrointestinal lesions with or without symptoms are very common and many instances of asymptomatic prolapse have been reported in patients with complaints caused by other lesions

### *Diagnosis*

This disorder should be suspected in any patient with an atypical ulcer history who does not respond satisfactorily to an ulcer regimen It should also be considered in those with repeated recurrences when placed on a diet of solid foods as well as in those patients with recurrent functional complaints or recurrent gastrointestinal bleeding that cannot be explained on any other basis A variety of roentgenologic findings are characteristic or suggestive of this condition

### *Treatment*

When all other gastrointestinal sources for the symptoms have been ruled out or controlled by medical or surgical therapy, a small number of patients will require operation for intractable symptoms or complications. Some authors recommend

the simplest procedure that will correct the lesion that is, antrotomy with removal of redundant gastric mucous membrane combined with some type of pyloroplasty More recently, enthusiasm for subtotal gastric resection has increased, especially if gastrointestinal bleeding has occurred or if concomitant gastric or duodenal disease is present We favor this latter method of surgical management

*Results*

The end results in carefully selected patients subjected to gastrectomy have been satisfactory Numerous case reports describe recurrence of symptoms after operation, which suggests a neurogenic basis for both the original and recurrent symptoms In atypical cases, it is sometimes necessary to perform an antrotomy and duodenotomy to confirm the diagnosis before proceeding with gastric resection Varying degrees of chronic gastritis are usually present in the resected specimen

## ULCERS OF THE STOMACH

### Incidence

The rate of occurrence of gastric ulcer has been based in the past on autopsy material and in the early reports on peptic ulcer, duodenal ulcer was rarely noted The ratio of duodenal to gastric ulcer, based on studies made at necropsy on autopsy material is said to be 2 to 5, but based on the diagnosis of gastric ulcer from roentgenologic and clinical evidence, ratios as low as 3 2 to 1 to as high as 9 to 1 have been reported Eusterman estimated from evidence obtained at necropsy and x-ray examinations that 10 to 12 per cent of all persons at some time in their lives have a chronic gastric or duodenal ulcer Such a diagnosis can be made accurately only in cases proved by operation or at necropsy Reports in the literature based on clinical and surgical observations of large groups of cases noted at medical and surgical clinics indicate that duodenal ulcer occurs more frequently than gastric ulcer whereas, as stated above, autopsy findings indicate that they occur with almost equal frequency Gordon and Manning reported from Philadelphia General Hospital that the ratio of duodenal to gastric ulcer found at necropsy was 1 to 1 1, which is exactly the same as White's ratio Over a period of twenty years (1935–54) at the Lahey Clinic a diagnosis of duodenal ulcer was made in 9,598 patients and of gastric ulcer in 1,848 patients, a ratio of 5 2 to 1 These diagnoses were based on clinical and roentgenologic evidence and in many cases were proved by surgical resection This ratio is very similar to that reported by Eusterman from the Mayo Clinic, in a series of 2,299 patients with ulcer, the ratio of duodenal to gastric ulcer was 6 4 to 1 Palmer reported a high ratio of 17 to 1 in a series of 830 private cases It is apparent that duodenal ulcer is found more commonly during life than at necropsy Palmer emphasized that sex has no significant correlation with the frequency of gastric ulcer In a study of 600 gastric ulcer cases, operated and unoperated, at the Lahey Clinic, the ratio of males to females was 2 3 to 1 In a series of 346 consecutive resections for gastric ulcer (microscopically proved benign), the ratio was 2 6 to 1 Benign gastric ulcer may occur at any age and is not uncommon in the aged The average age of patients with benign gastric ulcer found at operation was 53 years, whereas in a series of 1,600 cases of gastric carcinoma the average age was 57 years

*Etiology*

The true cause of peptic ulcer is not definitely known Early investigators in this field found that peptic ulceration could easily be produced in experimental animals by a wide variety of agents and procedures However, these gastric mucosal ulcerations were acute and if the animals survived long enough, healed with great rapidity Many theories have been propounded with regard to the cause of peptic ulcer, but it is now generally accepted that the presence of acid gastric juice is indispensable in the formation of chronic peptic ulcer Thus, medical

therapy is based upon the control of high acid values On the other hand excessive acid secretion need not be present for ulcer formation in the stomach As a matter of fact acid secretion is likely to be much lower in cases of gastric ulcer than in duodenal ulcer Selye states that shock and alarm reactions may lead to congestion or even hemorrhage and often

Fig 8 1 Ulcer of greater curvature of stomach in a man aged 68 years Many such ulcers are malignant Microscopic examination of the resected specimen proved this ulcer to be benign

to necrosis of the gastrointestinal membrane Arteriosclerosis may be a factor in hemorrhage from ulcers in older individuals That gastric mucus serves a protective function is also recognized and some evidence does indicate that deficiency of mucous secretion may lead to ulceration Functional distress and nervous disorders may serve as excitatory causes for the development of gastric or duodenal ulcer Allergic or hypersensitivity reactions have also been thought to account for some ulcerations of the gastric mucosa

*Pathology*

The location of gastric ulcers is well known Eighty five per cent of these ulcers are found in the lesser curvature and adjacent areas of the stomach and about 65 per cent are located within an area 6 to 8 cm proximal to the pylorus The importance of the size of gastric ulcers in relation to carcinoma has been overstressed Gastric ulcers range from 1 5 to 2 cm in diameter However, the large size of a gastric ulcer is no proof that cancer is present since we have seen benign ulcers as large as 10 to 20 cm in diameter (Table 8 1) Conversely malig

TABLE 8 1 RELATION OF SIZE OF GASTRIC ULCER TO CANCER (411 Operated Cases)

| | *Malignant* | *Benign* |
|---|---|---|
| Larger than 2 5 cm | 49 2% | 22 0% |
| Largest | 6 0 cm | 8 0 cm |
| Smallest | 0 75 cm | 0 8 cm |

nancy has been found in many small ulcers that average much less than 2 5 cm in diameter Gastric ulcers occurring on the lesser curvature in individuals under 30 years of age have one chance in 30 of being malignant whereas gastric ulcers occurring in the antral area in the cardia and on the greater curvature are likely to be malignant (Fig 8 1) Therefore, patients with ulcers in these latter areas are usually submitted to surgical treatment

When chronic gastric ulcer is present the margins of the ulcer are sharp and graduate toward the base, the crater walls may be cartilagelike in consistency The base of the ulcer consists of partially digested fibrous scar tissue that appears dirty brown and ragged in the early stages but smooth and clean as though curetted out in the later stages The ulcer measures 1 cm deeper in some instances because of the thickened gastric wall and the hypertrophy of the overhanging mucosa about the margin

*Signs and Symptoms*

Pain is by far the commonest symptom of peptic ulcer and is often one of the most important signs leading to the diagnosis One of the outstanding characteristics is the striking relief that occurs following ingestion of food or alkaline substance, with pain often subsiding after vomiting However, in some instances the pain of early gastric cancer may be indistinguishable from that associated with gastric ulcer When gastric ulcer is present the pain is likely to be felt in the mid line in the epigastrium and usually begins about an hour after eating This pain is frequently associated with nausea, and vomiting will often give relief Pain in duodenal ulcer, on the other hand, tends to begin two or more hours after food has been taken and continue up to the next meal, when it is quickly relieved

As Bockus has pointed out the peptic ulcer syndrome has four characteristics He notes (1) the character and intensity of pain (2) the location and radiation of pain, (3) the rhythm of peptic ulcer pain, and (4) periodicity and recurrence of ulcer attacks Moynihan has emphasized the typical rhythmic occurrence and disappearance of pain in uncomplicated cases of duodenal and gastric ulcer Many factors, however, may modify this typical rhythm Very few physical signs are of great help in the diagnosis of chronic ulcer except the presence of epigastric pain and tenderness If a larger ulcer is present with pain extending to the back, tenderness may be noted over the ulcer niche Muscle spasm of the abdominal wall is not usually present in cases of uncomplicated peptic ulcer Severe back pain when x ray examination shows evidence of a gastric ulcer is often an indication of penetrating ulcer with perforation against adjacent viscera such as the pancreas and liver Gastric ulcers are often associated with considerable spasm in the pyloric area, and when gastric retention is the result of pyloric spasm the finding of a succussion splash or a greatly dilated stomach may be evidence of either duodenal or gastric ulcer In most instances careful roentgenologic examination will show the location of the ulcer niche or deformity

*Diagnosis*

The diagnosis of gastric ulcer is important to the surgeon since the differentiation of benign and malignant ulcer is often difficult and at times impossible without microscopic examination of the excised ulcer This does not mean that all patients with gastric ulcers should be submitted to gastric resection However, gastric ulcer must definitely be considered as a potential precursor of malignancy, since it is possible in a few cases for a benign ulcer to show malignant degeneration and since the possibility of error in such differentiation is acknowledged In a consecutive series of 411 surgical cases of gastric ulcer, 65 were proved to be malignant by microscopic examination Reports in the literature indicate that the incidence of malignant degeneration in ulcers thought to be benign before resection varied from 10 to 20 per cent (Table 8 2)

TABLE 8 2 OCCURRENCE OF CANCER IN GASTRIC ULCER OPERATION PERFORMED BECAUSE DIAGNOSIS IN DOUBT

| | *Per cent* |
|---|---|
| Finsterer (1939) | 20 9 |
| Allen and Welch (1941) | 14 0 |
| Eusterman (1947) | 13 4 |
| Marshall and Welch (1948) | 19 8 |
| Smith and Jordan (1948) | 16 3 |
| Lampert, Waugh and Dockerty (1950) | 13 0 |
| Ekstrom (1952) | 11 6 |
| Marshall (1953) | 15 8 |

X RAY EVIDENCE The diagnosis of gastric ulcer must be based on roentgenologic findings usually the presence of a niche or crater that can be demonstrated when the stomach is filled with a barium mixture The common site of gastric ulcers is near the lesser curvature (Fig 8 2) in the vicinity of the re-entrant angle of the stomach, this area should be carefully

Fig 8-2 (a) Large gastric ulcer on lesser curvature in media of stomach in a man 54 years of age ulcer healed under medical management (b) Recurrent ulcer 11 months later which proved to be benign on microscopic study

examined at the time of fluoroscopy Ulcers may be found in any part of the stomach but it may be difficult to demonstrate an ulcer in the prepyloric segment (Fig 8 3) When ulcers are located in this area antral spasm may be severe and pyloric cancer cannot be ruled out In benign ulcers, the ulcer niche projects beyond the normal boundary of the gastric

Fig 8 3 Benign gastric ulcer in prepyloric area

wall The rugae about the ulcer are often prominent and show convergence toward the crater

### *Differential Diagnosis*

As stated above it may be difficult to differentiate benign from malignant lesions The examiner cannot place too much dependence upon the size and location of the ulcer in making such a diagnosis At x ray examination carcinomatous ulcers do not extend into the gastric wall and the ulcer niche does not appear to extend beyond the normal limit of the lumen If pressure is applied over the barium in the stomach at the site of an ulcer the crater may assume a crescentic shape, the meniscus sign as described by Carman Therefore it is important to at-

tempt to make this distinction between benign and malignant ulcers in the differential diagnosis Roentgenologic evidence is of the utmost importance in making such a diagnosis

The difficulty of excluding cancer in cases of gastric ulcer is further evidence that a definite diagnosis of a carcinomatous ulcer can be made only on the basis of microscopic differentiation established by pathologic examination after removal of the ulcer The only safe course to follow in the medical treatment of gastric ulcer is to insist upon complete healing of the ulcer at the completion of an adequate period of controlled medical therapy If the lesion should fail to heal immediate surgical treatment should be carried out It has been estimated from the literature that 10 to 20 per cent of ulcers that appeared grossly benign on x ray and clinical evidence proved to be malignant when examined microscopically

### *Prognosis*

Because malignant ulceration is frequently present in the stomach about 50 per cent of our patients with gastric ulcers have come to surgery These patients are admitted to the hospital and if the ulcers fail to show evidence of beginning to heal within a period of ten days to two weeks operation should be carried out at once The necessity for surgical treatment can usually be established after about two weeks of medical therapy The prognosis after gastric resection is excellent and in a series of 411 cases we have had no recurrence of gastric ulcer as indicated by the clinical course or proved by x ray examination An occasional patient may have a late hemorrhage after resection and this is reasonably good clinical evidence of recurrent ulcer However we have not been able to demonstrate the presence of an ulcer niche by roentgenograms in any of these cases Under conservative medical management all these patients will be relieved of their symptoms and, to all intents and purposes will be well without further surgical therapy

### *Complications*

The complications of gastric ulcer consist of hemorrhage perforation pyloric obstruction malignant degeneration and the occasional development of an hour glass stomach Although malignant degeneration of gastric ulcer does occasionally occur it must be infrequent and probably accounts for a relatively small percentage of malignant ulcers Most pathologists agree that the majority of malignant ulcers are malignant from the onset These lesions arise as superficial gastric carcinomas undergo central peptic acid ulceration and often present the same picture as benign ulcer The diagnosis of cancer arising from a benign chronic peptic ulcer must be made with great caution and based on the pathologic observations

Hemorrhage is a fairly common complication of gastric ulcer and is reported to occur more frequently in cases of gastric ulcer than in duodenal ulcer Eusterman reported from the Mayo Clinic gross hemorrhage in 25 per cent of surgically treated gastric ulcer patients whereas bleeding occurred in 17 per cent of those with duodenal ulcers Eliason and Ebeling stated that massive hemorrhage occurred in 39 1 per cent of 92 cases of gastric ulcer and in 19 5 per cent of 546 cases of duodenal ulcer

Surgical intervention is demanded in the treatment of massive hemorrhage if the evidence indicates persistent bleeding with falling blood pressure and increased pulse rate Aggressive surgical treatment will save many lives if performed without delay before vital organs such as the liver and kidneys are severely damaged by long continued hypotension Should hemorrhage recur before recovery from the initial massive hemorrhage operation should be performed as an emergency measure immediately after blood transfusion

Perforation of a gastric ulcer demands immediate surgical intervention which in most cases consists of simple closure of the ulcer If surgery is carried out within six

hours after perforation and if the abdominal cavity is not greatly soiled with gastric contents resection can be performed safely Free perforation into the peritoneal cavity is uncommon as most gastric ulcers early become adherent and perforate against the adjacent viscera As a rule pyloric obstruction will occur only in the presence of an antral or prepyloric lesion This condition also demands surgical intervention, as does an obstruction occurring with a duodenal lesion Severe pyloric spasm is not uncommon in cases of gastric ulcer and if gastric retention occurs when duodenal ulcer is not present the surgeon must look carefully for an unrecognized gastric ulceration

Hourglass stomach is caused by the cicatricial contraction of a chronic gastric ulcer with the greater curvature drawn toward the ulcer which in most cases is on the lesser curvature It probably results from scar tissue contraction of mucosa submucosa and muscularis mucosa and is considered pathognomonic of a healed chronic gastric ulcer Hourglass stomach occurs more frequently in females but this deformity is not commonly seen with gastric carcinoma

Surgical treatment is employed if gastric ulcers fail to heal recur after treatment or have characteristics that strongly suggest malignant degeneration such as size location and configuration Nothing short of gastric resection should be carried out because malignancy must be excluded by pathologic examination of the excised ulcer For this reason gastroenterostomy and vagotomy should never be used nor should the Madlener operation be employed in these cases. Practically all ulcers situated high on the lesser curvature can be removed surgically and we agree with Aird that no matter how high a gastric ulcer is located it can usually be removed by gastrectomy

### *Treatment*

About 50 per cent of the patients with gastric ulcers will require surgical treatment and all patients with gastric ulcers should be hospitalized The majority of these patients may be treated by conservative medical measures and in the event of healing surgery is not indicated In the average case benign ulcer will show evidence of healing within ten days to two weeks and most will heal within six weeks A large ulcer may be completely healed in eight weeks if healing is to be obtained under a medical regimen Should a gastric ulcer show no evidence of healing (this can be determined in most cases within ten days or two weeks) surgical treatment should be carried out promptly Using such criteria for selection of surgical cases we found 65 pathologically proved carcinomas in a series of 411 patients submitted to surgery a frequency of 15 8 per cent of malignancy For all patients thus conservatively treated and in whom the ulcers were demonstrated to heal under medical management gastroscopic and roentgenographic examinations are repeated at three month to six month intervals If pain should recur with recurrence of the ulcer niche or evidence of occult blood in the stools, gastric resection should be performed immediately because of the possibility that the ulcer may be malignant

## BENIGN TUMORS OF THE STOMACH

Benign tumors of the stomach constitute a small percentage of the neoplasms that are found in the stomach In a consecutive series of 1 700 patients operated on for gastric tumors at the Lahey Clinic, 82 benign tumors (1 8 per cent) were removed at operation and examined by the pathologist Balfour and Waugh at the Mayo Clinic found 92 benign tumors in a series of 2,505 gastric tumors, an incidence of 3 6 per cent

Benign tumors may be classified as adenomas lymphomas single or multiple polyps lipomas leiomyomas, or aberrant pancreatic tumors a very small group of miscellaneous tumors such as angiomas myxomas neuroblastomas, and cysts is

also included in this classification Statistics in the literature indicate that benign tumors constitute less than 2 per cent of all gastric tumors However, these tumors occur more frequently than the operative statistics would indicate They rarely produce symptoms and in many cases are not recognized clinically They are more often found at exploratory laparotomy performed for other reasons Rigler noted a 6 to 1 ratio of malignant to benign tumors, these tumors being classified on the basis of roentgenologic studies Eusterman and Senty reported that 1 3 per cent of all gastric tumors were benign Hillstrom, however, stated that 5 per cent of all tumors noted at autopsy or at operation were benign

The term polyp' refers to the gross form of the gastric neoplasm rather than its histologic pattern Almost any tumor may be polypoid as for example adenomas, lipomas, myomas, and papillomas Multiple polyposis may be multiple adenomas of the stomach (Fig 8 4) We have seen two patients with such multiple tumors, one of whom was later operated on because of malignant degeneration in one of these polyps On the other hand multiple polyposis may simply be hypertrophy and hyperplasia of the gastric mucosa not true adenoma

Table 8 3 shows the rate of occurrence

TABLE 8 3 BENIGN GASTRIC TUMORS

| | Number |
|---|---|
| Leiomyoma | 36 |
| Polyps single and multiple | 41 |
| Lipoma | 5 |
| Adenoma | 10 |
| Aberrant pancreas | 12 |
| Miscellaneous tumors | 5 |
| | 109 |

and pathologic classification of 109 benign tumors, found and removed at operation in this clinic.

Leiomyomas or smooth muscle tumors are probably the most common type found at operation Meissner noted 46 per cent in a series of 50 necropsies Rienets also found a high incidence and stated that in a series of 200 necropsies, one or more leiomyomas were present in 32 cases These tumors are usually small and have no clinical significance until they become large enough to produce symptoms, usually bleeding from ulceration of the mucosa over the enlarging tumor According to Eliason and Wright,

Fig 8 4 Multiple polyps of stomach

myomas outnumber all other types of benign tumors In a collected series of 560 benign tumors, 321 myomas were found (57 3 per cent)

Most benign tumors arise in the pyloric area or middle third of the stomach, however, they may be found in any part of the stomach Adenomas or adenomatous polyps are considered precancerous lesions Since the histologic nature of tumors cannot be recognized by roentgenologic examination, all gastric neoplasms should be removed surgically, either by local excision or by resection.

In our experience, 30 per cent of adenomas or adenomatous polyps have

nges gastric resection should be ied out

## IALIGNANT TUMORS OF THE STOMACH

### stric Carcinoma

*Incidence*

Gastric carcinoma occurs frequently id this neoplasm is the most common of e malignant tumors found in the omach In our series of 1 700 cases of astric tumor carcinoma accounted for 2 per cent of all neoplasms benign and ialignant so that a gastric neoplasm isualized on the roentgenogram is very kely to be cancer

Other malignant tumors belong to the arcoma group which comprised 3 per ent of all malignant gastric tumors Guiss found 31 sarcomas in 1 334 malig nancies of the stomach an incidence of 2 3 per cent Sarcomas may arise from any of the mesenchymal elements of the stomach but more frequently arise from the lymphoid and smooth muscle tissues thus forming malignant lymphomas and leiomyosarcomas Tumors of vascular nerve or fibrous tissue origin are so rare that for purposes of review they may be ignored In a group of 1 700 consecutive surgically treated gastric tumors we found that 35 neoplasms originated in lymphoid tissue and 16 were leiomyo sarcomas no tumors arising from other tissue elements of the stomach were noted in the group

Of all deaths from neoplastic disease the most common cause in the male is gastric cancer In 1952 the U S Bureau of Vital Statistics reported 23 019 deaths caused by gastric malignancy Of this number 62 9 per cent were males and 37 1 per cent females 9 8 per cent of all deaths from mal gnant disease in this country were caused by malignant gastric neoplasm In a series of 1 708 consecutive patients with proved gastric cancer seen at the Lahey Clinic 67 4 per cent were males and 90 per cent of the entire group were 50 years of age or older

*Etiology*

The cause of gastric cancer is un known but various factors have been suggested as etiologic agents for example a familial tendency excessive use of strong alcoholic drinks condiments or very hot foods and drinks The difference in reported frequency of gastric cancer in various countries suggests that such ex trinsic factors may possibly influence the development of gastric malignant disease

Certain benign neoplasms of the stom ach gastric ulcers or alteration in func tion of the gastric mucosa may well be precursors of cancer These conditions should be regarded seriously and treated to avoid the development of cancer We have already emphasized the danger of malignant degeneration in benign tumors and in gastric ulcers The presence of achlorhydria should indicate the necess ty for close observation of such patients and the higher rate of occurrence of neo plasms in patients with pernicious anemia should demand careful gastric examina tion including gastroscopy Rigler and Kaplan in a series of 293 patients who died of pernicious anemia found 45 cases (15 per cent) of gastric carcinoma In a group of 212 patients with pernicious anemia coexisting gastric carcinoma was noted in 8 per cent and gastric polyps in about the same percentage Mosbeck and Videback reported 14 deaths from gastric carcinoma in a group of 301 patients with pernicious anemia a death rate three times as high as that of gastric carcinoma in patients without pernicious anemia Some evidence does suggest that atrophic antral gastritis may favor the develop ment of carcinoma and indeed epithelial alterations and exudating changes occur ring with chronic gastritis form lesions that take on the histologic appearance of a precancerous lesion

*Pathology*

Shields Warren has suggested a useful and practical classification of malignant gastric tumors which is shown in Table 8-4

TABLE 8 4 CLASSIFICATION OF MALIGNANT GASTRIC TUMORS

A Carcinoma
  1 Adenocarcinoma
  2 Carcinoma simplex
  3 Mucinous carcinoma
  4 Adenoacanthoma
  5 Carcinoma in polyp
B Sarcoma
  1 Lymphoma
    a Hodgkin s disease
    b Reticulum cell sarcoma
    c Lymphosarcoma
    d Lymphocytoma
    e Macrofollicular sarcoma
  2 Leiomyosarcoma

In a consecutive series of 653 patients who were submitted to resection with the possibility of cure, carcinoma simplex was found in 46 6 per cent, adenocarcinoma in 42 6 per cent and mucinous carcinoma in 7 per cent Malignant adenoma or carcinoma in polyps and adenoacanthoma accounted for the rest of the tumors In most cases, adenocarcinomas are large, bulky tumors projecting into the lumen, while carcinoma simplex is an infiltrating tumor, the infiltration being local or widespread Either type of tumor may ulcerate and bleed The average age for the occurrence of adenocarcinoma is about ten years later than that for tumors classified as carcinoma simplex However, the histologic pattern does not appear to alter the degree of malignancy of these tumors The five year survival rate in each group is similar 25 5 per cent for patients with adenocarcinoma and 24 3 per cent for those with carcinoma simplex

All carcinomas show much the same tendency to spread through vascular and lymphatic channels In a group of 856 cases of resected gastric carcinomas, nodal involvement was found in 61 8 per cent Carcinoma may occur in any part of the stomach but is most frequently found in the prepyloric area Ewing stated that three fifths of all gastric cancers originate in the pyloric region, while another 20 per cent arise along the lesser curvature and cardia Therefore tumors of the pyloric area have considerable chance of being malignant

*Signs and Symptoms*

The initial symptoms of malignant disease are often vague and variable Unless a tumor causes obstruction the carcinoma may be well developed and past surgical treatment before the patient consults a physician

The probability of gastric cancer should be considered in every individual past 45 years of age who develops vague gastrointestinal distress, especially if the symptoms are not relieved promptly by conservative medical measures Epigastric discomfort or pain accompanied by anorexia and nausea is likely to be the earliest evidence of gastric malignant disease, and such a history was noted in half of our cases Varying degrees of weight loss occurred in over 90 per cent of our patients Normal acid values were found in half of the cases, in 17 per cent of the patients with hypoacidity the free acid value was less than 20 Achlorhydria was noted in only 36 per cent The presence of blood and coffee ground material in gastric contents is of great significance Pronounced vomiting, anemia, emaciation, and great weight loss are late signs and usually indicate advanced carcinoma when surgical treatment by radical resection is not possible

In a group of 1 708 patients with gastric cancer, only 20 9 per cent had had symptoms for three months or less and procrastination by the patient accounted for delay of treatment in 37 5 per cent In another 50 4 per cent of cases delay of more than three months up to three years could be directly ascribed to the referring physician who did not even consider the possibility of gastric cancer and who failed in many instances to obtain x ray and laboratory studies

*Diagnosis*

Roentgenologic examinations and laboratory studies such as gastric analysis blood studies gastroscopic and cytologi

cal tests should be performed to determine whether or not gastric malignant disease is present If the physician is always cognizant of the frequency of gastric cancer and is constantly on the lookout for this disease, many of these tumors could be found at a time when gastric resection would be possible

In early cases of cancer of the stomach few physical findings are significant in diagnosis It is important to look for palpable tumors, fluid in the abdomen, enlargement of supraclavicular nodes, and cul de-sac implantation as noted on rectal examination with the patient in the knee-chest position These signs, however, are evidence of advanced cancer, when curative resection is not possible In a series of 1,708 patients with cancer of the stomach, gastric tumors were palpable in 30 2 per cent (Fig 8 7)

Fig 8 7 Inoperable gastric carcinoma A large irregular, rigid filling defect is present in the antrum and media of stomach Tumor was palpable upon abdominal examination

The presence of gastric cancer must be established by x ray examination A filling defect caused by the tumor is the most characteristic and reliable laboratory sign and has indicated the presence of carcinoma in 88 per cent of our cases (Fig 8 8) X ray examination by a competent roentgenologist has also revealed gastric defects in another 5 to 6 per cent of patients in whom laparotomy was required to determine whether or not the x ray defect was produced by a malignant tumor In a collective review of a large series of cases, Guiss found that x ray examination led to an accurate diagnosis in 90 per cent of patients and indicated the presence of gastric abnormality in another 5 per cent Gastric cytologic examination will reduce the error in diagnostic study in a considerable number of doubtful cases and may assist materially in the earlier accurate diagnosis of gastric cancer

Fig 8 8 Operable carcinoma of stomach Note irregular filling defect involving the lesser curvature of the stomach from a point just beyond the incisura angularis to the pylorus Pathologist s report was adenocarcinoma, with negative lymph nodes

### *Differential Diagnosis*

A filling defect in the stomach visualized by x ray study must be considered to be carcinoma, as 90 to 95 per cent of all gastric neoplasms prove to be malignant Therefore, an exact diagnosis is not of great importance since all gastric tumors found by x ray study require immediate surgical removal

Patients showing x ray defects in the

stomach that cannot be recognized by careful laboratory studies should have an early exploratory laparotomy to rule out carcinoma, since the cure rate in surgical treatment depends greatly upon early recognition and prompt surgical extirpation

Gastric ulcer presents the greatest problem in differential diagnosis, and it may be difficult to decide whether the ulcer is benign or malignant, as discussed in the preceding section on gastric ulceration Certain roentgenologic characteristics such as location, size of the ulcer, mucosal pattern, as well as the age of the patient and length of time the ulcer has been present may indicate the probability of benignancy or malignancy However, the most practical consideration is whether an ulcer shows evidence of healing or fails to heal under a conservative medical regimen Should an ulcer show no tendency to heal during treatment or recur after medical treatment, if gastroscopic examination shows nonhealing or if occult blood persists in the stools, early surgical intervention is mandatory

### *Prognosis*

The results of surgical treatment of gastric malignant disease vary considerably in numerous reports in the literature If a series includes a large percentage of cases in which diagnosis was delayed, the five year survival rate is poor This is likely to be true in large hospitals with high percentages of charity ward cases Conversely, reports of series of cases observed in private practice show considerable improvement in the five year survival rate following surgical management The results of surgical treatment have shown great improvement during the last twenty to twenty five years because of earlier diagnosis, better preoperative and postoperative care better operative technique, adequate replacement of blood volume and electrolytes, and the use of antibiotic therapy

In a series of 1 708 consecutive cases of malignant gastric tumors observed at the Lahey Clinic over a period of twenty-three years, we have been able to obtain accurate information on the results of surgical treatment in all but seven cases In the period 1932 through 1934 the five-year survival rate after resection was 15 4 per cent (Table 8-5) This rate has gradually increased over the years to 39 5 per cent (1950 and 1951)

TABLE 8 5 CARCINOMA OF THE STOMACH FIVE YEAR SURVIVAL AFTER CURATIVE RESECTION

| Period | Total cases | Five year survival | |
|---|---|---|---|
| | | Cases | Per cent |
| 1932 1934 | 26 | 4 | 15 4 |
| 1935–1939 | 93 | 11 | 11 8 |
| 1940–1944 | 175 | 51 | 29 1 |
| 1945 1949 | 188 | 56 | 29 7 |
| 1950–1951 | 76 | 30 | 39 5 |
| Total | 558 | 152 | Average 27 2 |

Guiss reported a five-year cure rate of 27 7 per cent based on the survivors of resection but the five year survival rate based on all patients admitted because of gastric cancer was 4 3 per cent The five year survival rate after total gastrectomy in our hands was 14 1 per cent, while 26 2 per cent of our patients lived three years or longer after this operation Pack reported that a five year cure may be anticipated in 29 8 per cent of patients undergoing subtotal gastrectomy and in 10 5 per cent of the survivors of total gastrectomy Jeremin and Colp reported a five year survival after resection of 27 3 per cent (1943–47)

Operative mortality in our own experience for the entire group of 1,708 cases has steadily decreased from 27 1 per cent (1932 to 1934) to 5 7 per cent (1950 to 1951) This is the over-all mortality figure following all types of surgical procedures, including exploration only, palliative operations, and curative resections Over the last five years, the operative mortality for partial resection in the Lahey Clinic was 3 2 per cent Likewise, the operative mortality for total gastrectomy has been reduced from 34 6 per cent

to 7 per cent during the past five years (1950 to 1954) Pack reported an operative mortality of 27 6 per cent for total gastrectomy (1948 to 1952) In our group of patients submitted to laparotomy, the absolute five-year survival rate for all cases (1,404) of carcinoma of the stomach, resected and unresected, was 10 8 per cent The prognosis for patients with sarcoma of the stomach is somewhat better, 44 per cent survived five years or longer

Lipp reported a collected series of 9,177 cases over a ten-year period (1940 to 1950) and stated that 466 of these patients were alive at the end of five years, an absolute survivorship the mean of which is 5 7 per cent Nodal involvement significantly affects the prognosis in our series of 856 patients undergoing resection, in 529 cases (61 8 per cent) nodal involvement was present, with a five year survival of only 7 2 per cent, whereas in 327 cases the lymph nodes were not involved The five year survival in this latter group was 34 8 per cent

The outlook for patients with inoperable carcinoma of the stomach is, as expected, very poor, 74 1 per cent of our series of 1,708 patients were dead within six months after exploration and 94 1 per cent were dead within the first year

### *Complications*

The late complications of carcinoma of the stomach are perforation, obstruction, and hemorrhage

Guiss reported that perforation occurred in 3 per cent of cases in a collected series Perforation is therefore uncommon and usually takes place in later stages of the disease Occasionally gastric cancer invades the colon, with resulting perforation into this structure We have had nine such cases Pyloric obstruction is common since over 60 per cent of gastric cancers arise in the prepyloric area In many instances, pyloric obstruction caused by carcinoma gives rise to symptoms much earlier and, in a number of these cases, resection can be performed before widespread metastasis occurs. Bulky tumors arising in the body of the stomach may reach good size and give few indications of their presence, unfortunately, these tumors rarely cause obstructive symptoms Tumors in the cardia often produce esophageal obstruction, and dysphagia may be the first symptom of a carcinoma in that area In such cases esophagoscopy is essential before resection is attempted

Gastric hemorrhage is not uncommon in cancer of the stomach This is not surprising in view of the tendency of gastric tumors to ulcerate At this clinic, a study of causes of gastric bleeding showed that peptic ulcer accounted for hemorrhage in 59 per cent of cases, gastric cancer in 18 per cent, and esophageal varices in 16 per cent In most cases of gastric cancer, however, the hemorrhage is not massive in contrast to hemorrhage that occurs with ulcer

### *Treatment*

The treatment of gastric cancer is entirely surgical and consists of resection of the tumor the omentum, and all avenues of vascular and lymphatic spread The operation consists of high partial resection or total gastrectomy with removal of the spleen resection of the duodenum almost to the ampulla of Vater, and removal of all regional lymph nodes The majority of gastric cancers can best be surgically treated by high subtotal gastrectomy and we believe that this operation offers the greatest chance of survival with the lowest operative risk and the minimum number of postoperative problems From 1945 to 1954, 16 6 to 36 6 per cent of all our patients with gastric cancer were submitted to total gastrectomy Total gastrectomy is employed when a less extensive technical procedure cannot remove all evidence of gross tumor

Allen has very properly emphasized that, in the surgical treatment of gastric cancer, the primary object is cure but that two other factors are equally important in choosing an ultraradical procedure such as total gastrectomy that is, mortality and morbidity If the cure rate is not increased by total gastrectomy,

little is to be gained and much may be lost

If adjacent organs such as liver, colon, or pancreas are directly invaded, resection should be performed and indeed is justifiable provided the tumor is technically resectable Resection of the left lobe of the liver, the pancreas, and colon have been added to gastric resection in 54 of the cases in our series without appreciable increase in operative mortality However, the prognosis for five-year survival in most cases in which other organs are resected has been poor

Obviously, metastases to the liver, the peritoneum, and retroperitoneal nodes preclude any chance of cure and in most cases resection is not justifiable except as a palliative measure Partial resection of the stomach is justifiable for palliation in selected cases and offers more chance of relief than does gastroenterostomy, since the removal of an ulcerating, bleeding tumor materially improves the patient's condition even though life is not prolonged Blood loss is thus prevented, distressing vomiting of retained undigested food is prevented, and the patient's death is much less distressing Death is usually caused by inanition owing to extragastric progression of the tumor Total gastrectomy is never justifiable as a palliative procedure and is to be condemned as such

## Gastric Sarcoma

As noted above, sarcomas of the stomach constituted 2 to 3 per cent of all gastric neoplasms Sarcomas most commonly arise from lymphoid and smooth muscle tissue (see Table 8-1) Sarcomas arising from nerve, vascular, and fibrous tissue are very rarely encountered and we had none in our series of cases Thus, the gastric sarcomas encountered in our series of cases were malignant lymphomas (35 cases) and leiomyosarcomas (16 cases) (see pathological classification, Table 8-1 Our series does not include any fibrosarcomas, angiosarcoma or malignant endotheliomas Balfour and Waugh noted 52 sarcomas in a group of 2,398 malignant gastric tumors, an incidence of 2 2 per cent Gastric sarcomas of lymphoid origin occur infrequently but the surgeon should be aware of their possibility

Malignant lymphomas may occur in patients of any age It is thought that these tumors occur more commonly in younger individuals, but we have not found this to be true The average age of these patients is 53 years, whereas the average age for patients with carcinoma is 57 years Holmes believes also that gastric sarcomas are usually found in patients of the "cancer age" The sex ratio is about the same as in cases of cancer, in our series the ratio of males to females was 1 9 to 1

Malignant lymphomas present no characteristic x ray picture and in most cases are indistinguishable from carcinoma (Fig 8-9) An x ray defect may be rounded and smooth or indicate the presence of multiple tumors or ulcers, these findings are suggestive of sarcoma

A correct preoperative diagnosis is rarely made, as these tumors present no clinical signs that are distinguishable from those of carcinoma Large, bulky tumors occurring in younger age groups than those in whom cancer is found should make the surgeon at least consider the possibility of sarcoma Pack and McNeer emphasized that these tumors are more easily palpated and more movable than in the average case of carcinoma

Indications for resection are the same as for carcinoma However if the tumor is inoperable, postoperative irradiation should be carried out as many patients respond favorably to x ray treatment If resection is feasible, we believe that postoperative x ray treatment is also of value The results of surgery in these cases are somewhat better than in carcinoma as 38 per cent of the patients survived five years or longer

Leiomyosarcomas are a well recognized group of tumors. A solid tumor forms projecting from the wall of the stomach

into the peritoneal cavity or protruding into the lumen of the stomach where ulceration and necrosis of mucosa over the tumor occur In most instances these tumors are small but they may become very large One tumor in our series was as large as a head and filled the lumen of the stomach Upon admission this patient had a hemoglobin of 20 per cent as a result of ulceration of the mucosa with massive hemorrhage Another leiomyosarcoma recently removed weighed 2 050 Gm Hemorrhage may be the first and only symptom even though the tumor is large these patients rarely have pain and at most only mild indigestion The course of leiomyosarcoma is usually slow, the tumors grow locally and rarely metastasize early We have had two instances of metastasis one to the liver and one to the lungs The metastasis into the liver in this case developed rapidly with notable enlargement of the liver caused by the infiltrating tumor Meissner believes that sarcoma has no relation to benign myoma as malignant degeneration could not be found in benign tumors in any instance

In most cases the x ray defect produced by these tumors is characteristic and the diagnosis is often suggested

Leiomyomas frequently produce circumscribed rounded filling defects which are in most cases intraluminal they are often palpable and movable Benign leiomyomas however cannot be distinguished from sarcomatous myomas by roentgenographic study Malignancy or benignancy can be determined only by microscopic examination of the resected tumor

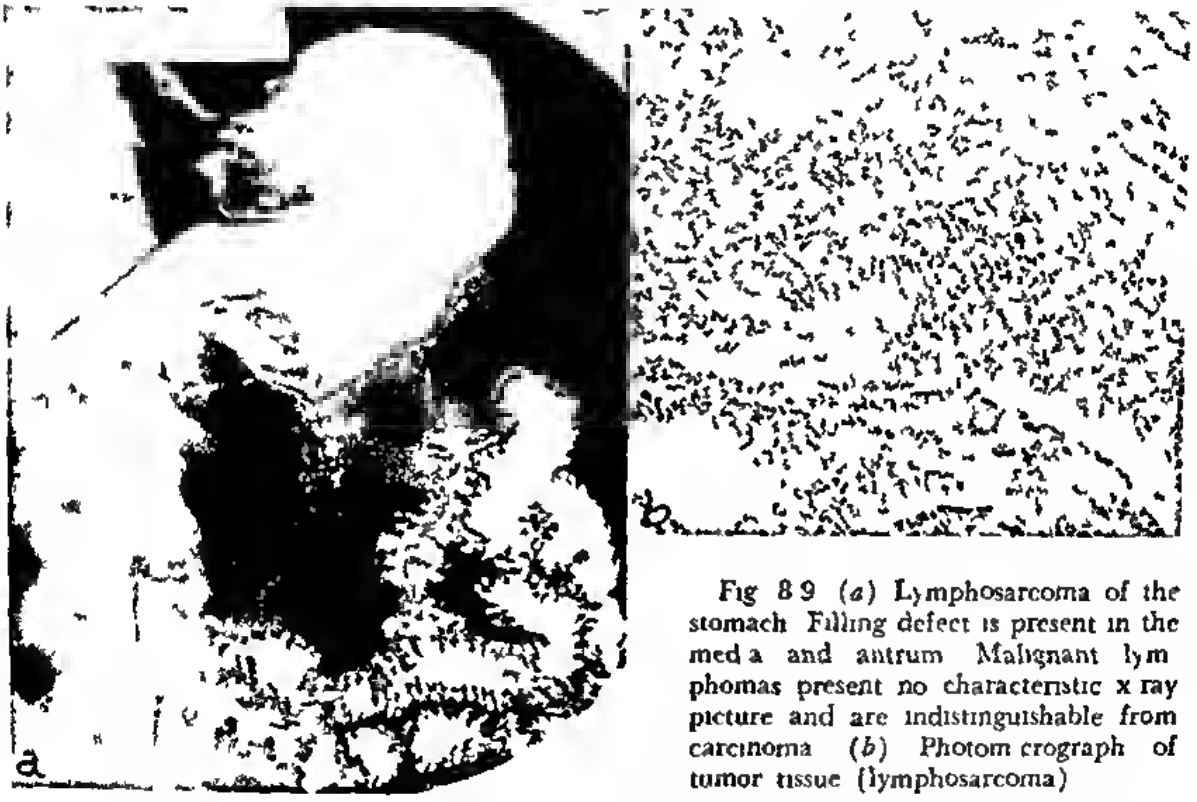


Fig 8 9 (*a*) Lymphosarcoma of the stomach Filling defect is present in the media and antrum Malignant lymphomas present no characteristic x ray picture and are indistinguishable from carcinoma (*b*) Photomicrograph of tumor tissue (lymphosarcoma)

Treatment consists of resection in most cases If the tumor is small local excision is justifiable in a few instances provided microscopic examination is carried out at once to determine whether the tumor is benign or malignant. No gross characteristic differentiates the benign tumor from the malignant and if the tumor is sarcomatous resection should always be performed. Prognosis is excellent in most of these cases, six of nine patients lived five years or more after resection four over ten years

## SURGICAL TECHNIQUE

### Gastrectomy

The operative technique of gastrectomy is basically the same in cases of peptic ulcer duodenal or gastric, and in carcinoma unless total gastrectomy is deemed necessary for removal of a malignant tumor

beyond the pyloric area The omentum may be removed with the duodenal ulcer or gastric carcinoma, and in fact one of us (S F M) always excises the omentum when resection is performed for peptic ulcer (Fig 8 10) Mobilization of the stomach is made much easier, fewer vessels have to be clamped and ligated and the approach to the retropyloric area becomes a much simpler procedure

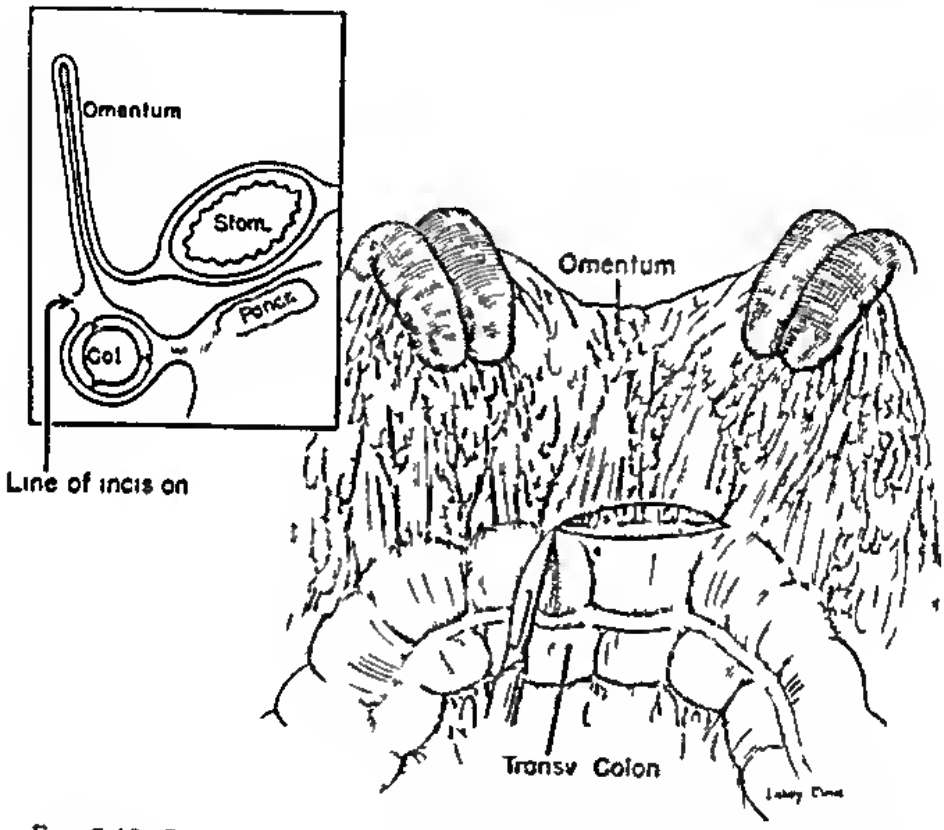


Fig 8-10 Detachment of omentum from the transverse colon is shown *Inset*) Relation of peritoneal layer in lesser sac to the colon stomach and pancreas

The only essential difference in such a resection for ulcer or for gastric cancer is the scope of the operative procedure In the case of a malignant tumor of the stomach in addition to the classical high resection that would be performed for duodenal or gastric ulcer attention is directed toward removal of the duodenum well past the pyloric vessels and almost down to the ampulla of Vater since the duodenum will frequently be involved with extension of the cancer

When carcinoma is present gastric resection should always include excision of the gastrohepatic and gastrocolic omentum Although in most cases of peptic ulcer 70 per cent of the stomach is removed, a somewhat more radical procedure is employed for carcinoma of the stomach since we believe that only a small remnant of stomach should be allowed to remain This is particularly true when total gastrectomy is not considered necessary for removal of all the

malignant tumor Furthermore, with carcinoma of the stomach the spleen is always removed and great attention is paid to the lymph node groups in the subpyloric and retropyloric areas and the nodes extending along the gastrohepatic omentum about the hepatic artery and portal vein, all nodes around the celiac axis are also included in the dissection

In short, a high radical resection of the stomach for malignant tumor includes removal of a considerable portion of the duodenum, all the gastrohepatic and gastrocolic omentum, and all the nodes around the pyloric area and the celiac axis The nodes in the splenic hilum are removed by splenectomy, since in a high percentage of cases these nodes are involved when carcinoma arises in the body and the cardia of the stomach Ligation of the splenic vessels along the upper border of the pancreas controls all the bleeding along the upper portion of the greater curvature of the stomach and only a few short gastric vessels must be ligated (Fig 8-11)

The technique of gastric resection with these few modifications is as follows The abdomen is opened, usually through a left transrectus muscle-splitting incision extending from the left costal margin to below the level of the umbilicus This permits approach to the duodenum, which is situated only slightly to the right of the mid line, and also permits the surgeon to mobilize the entire stomach easily and make his transection as high as necessary either for partial or total removal of the stomach After exploration of the abdominal cavity and stomach to determine the nature and character of the peptic ulcer or the extent of the gastric tumor, resection is carried out. As stated above, operative dissection progresses much more readily if the gastrocolic omentum is detached from the

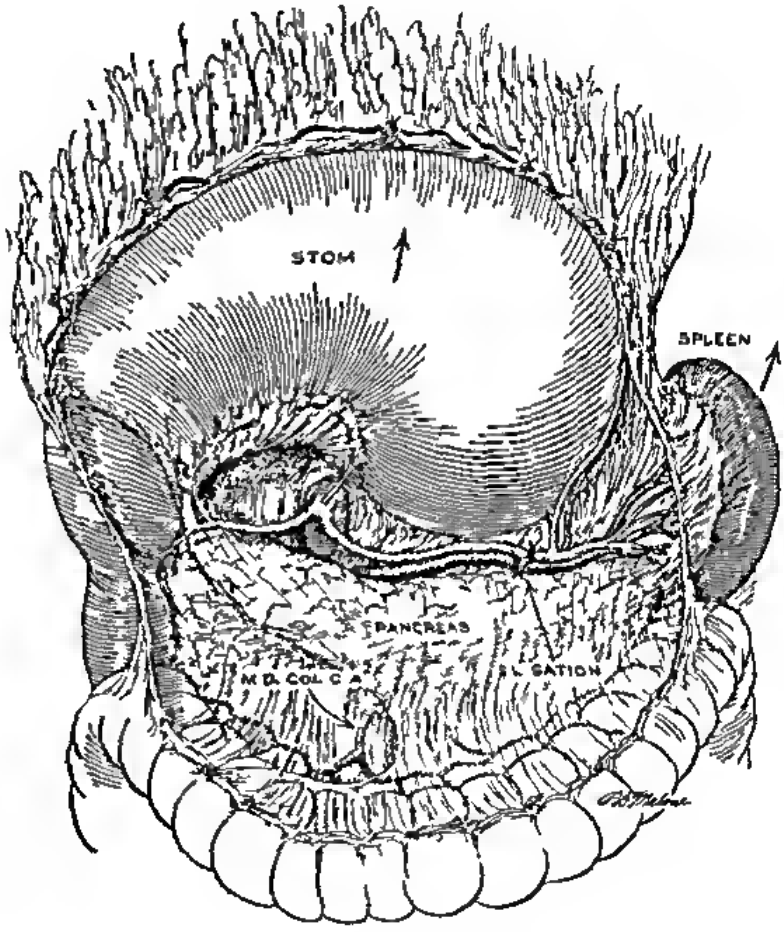


Fig 8 11 Omentum has been detached from transverse colon, and stomach (with omentum) is turned upward Drawing illustrates relationship of stomach to blood supply from the celiac axis and also the location of the middle colic artery If total gastrectomy with splenectomy is necessary, the point of ligation of the splenic vessels is indicated

transverse colon The omentum is put on a stretch and an incision made along the upper border of the colon, toward the left side of the transverse colon, opening into the lesser omental cavity The omentum can thus be easily detached from the colon and very few vessels will need to be clamped and ligated After the lesser omental cavity has been opened, traction is made upon the stomach by the introduction of a moist gauze strip through the filmy gastrohepatic ligament above the lesser curvature of the stomach, this is carried posterior to the stomach and brought out below the stomach under the greater omentum When ulcer is present, we ligate a few of the short gastric vessels, thus cleaning the greater curvature to the level at which the stomach is to be transected The stomach is then lifted cephalad and toward the left costal margin, and at the same time traction is continued as the omentum is detached from the right side of the transverse colon (Fig 8-11) Here also very few bleeding points must be clamped and ligated as the omentum is dissected from the right half of the transverse colon It is well to remember that the lesser omental cavity is lined with peritoneum, and that laterally toward the duodenum the peritoneum covering the pancreas is reflected onto the posterior part of the stomach at the level of the middle colic vessels in the mesocolon If at this point the area of reflection of the peritoneum is divided, the middle colic artery will fall out of the way with the mesocolon, thus eliminating the danger of injury to this important vessel The relatively bloodless areolar tissue below and posterior to the pylorus can then be divided and the duodenum dissected off the head of the pancreas, with the dissection carried down along the inferior border of the duodenum At this stage, the right gastroepiploic artery can also be divided and ligated at the inferior border of the pancreas where it arises from the gastroduodenal artery The superior pancreatoduodenal artery can be ligated and the lower border of the duodenum is thus completely mobilized The right gastric artery above the duodenum is now clamped, divided, and ligated In many cases, the ulcer may adhere to the pancreas and even penetrate into the pancreas The majority of duodenal ulcers requiring surgical treatment are posterior ulcers with posterior wall perforation, penetrating into the pancreas, the actual base of the ulcer consists of scar and granulation tissue in the pancreas

The technique of resection for gastric ulcers is the same as described above Gastric ulcers frequently adhere to adjacent viscera and often penetrate the pancreas The ulcer base may be fixed to the liver, or if anterior to the abdominal wall, the gastric ulcer may be detached as in duodenal ulcer If the ulcer base is the pancreas as in duodenal ulcer, it should be allowed to remain, detaching only the gastric wall from the periphery of the ulcer base If the duodenal or gastric wall in which the ulcer has arisen is no longer present, the visceral margin of this ulcer can usually be detached from the base of the ulcer in the pancreas allowing the base to remain undisturbed Great care should be exercised to avoid injury to the pancreas The duodenum is then carefully mobilized posteriorly until a pliable wall is obtained distal to the ulcer, which will permit satisfactory closure of the divided duodenum

If the first portion of the duodenum is not foreshortened by a great amount of scar tissue, it can be divided between clamps, either with the knife or the actual cautery If, however, the duodenum is shortened by scar tissue so that the ampulla of Vater would be endangered during inversion by sutures further shortening can be avoided by dividing the duodenum with a clamp only on the pylorus or proximal end omitting the duodenal clamp The open tube of the duodenum can then be closed with an inverting Connell suture, and reinforced with a second row of interrupted black silk sutures When the clamp technique is employed, the duodenum is usually closed by means of a

running stitch of fine chromic catgut over the clamp and inversion accomplished with interrupted sutures of fine black silk The gastrohepatic and gastrocolic ligaments in this area are then tied into the corners of the duodenal stump for reinforcement of the suture line If the duodenum is closed with meticulous care, there is very little chance of leakage and in our experience duodenal fistulas have occurred infrequently

The gastric dissection is continued along the lesser curvature, ligating the left gastroepiploic vessels as they come off the left gastric artery If peptic ulcer is present, about 70 per cent of the stomach is removed and in the majority of cases a von Petz clamp can be very easily applied at a high level If the clamp cannot be applied satisfactorily at the high level, the stomach can be divided without using clamps In order to obtain adequate hemostasis, the serosal and muscularis layers of the stomach are carefully incised transversely at the point of transection, thus exposing the vessels that lie in the submucous layer These vessels are then ligated individually with fine silk sutures on both the anterior and posterior gastric wall, this will effectively control the major portion of the bleeding from the transected end of the stomach The final submucosal and mucosal layers are then divided, thus completing the severance of the portion of the stomach to be removed

When the von Petz clamp is employed, the stomach can be divided between the double row of silver clips with the actual cautery (Fig 8-12), this measure not only prevents contamination from the end of the stomach but also aids in control of bleeding The use of the von Petz clamp makes it possible to accomplish the major part of the gastrojejunal anastomosis with the divided stomach still closed by the clips, thus reducing the chances of contamination

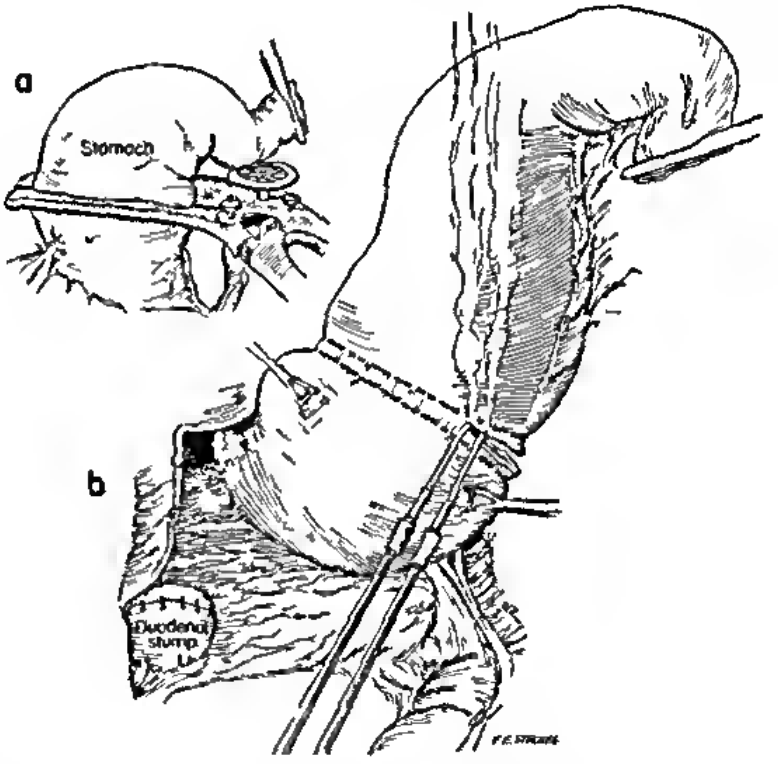


Fig 8 12 (*a*) The von Petz clamp is applied to the mobilized stomach at the level selected for transection (*b*) The stomach is divided between a double row of clips by the actual cautery

Following division of the stomach between the double row of clips, the distal part containing the ulcer is removed A continuous running stitch of chromic catgut is used to invert the upper two thirds of the transected end of the stomach with clips intact, this area is reinforced with interrupted black silk

sutures Only the lower third of the transected end of the stomach on the greater curvature is left for formation of the stoma The stomach remnant is then anastomosed to the jejunum The terms "antiperistaltically" and 'isoperistaltically' are rather confusing and we prefer to use the more definite anatomical terminology, that is the distal end of the jejunal loop to the lesser or greater curvature and vice versa As far as function is concerned, placing the loop in either direction has been entirely satisfactory and has caused no difficulty One of us (S F M ) always places the distal end of the jejunal loop on the lesser curvature and the other author (H D A ) prefers the distal loop placed on the greater curvature

When the anastomosis has been completed the retained portion of the stomach lies high under the left costal margin, and when the level of the division is made high on the greater curvature the gastrojejunal anastomosis will be in the transverse position With the distal loop at the lesser curvature the mesentery is not twisted since the natural configuration of the mesentery runs obliquely from the left costal margin across the peritoneal cavity to the right colonic gutter With such a high resection the anastomosis will function satisfactorily

Before the stomach is mobilized, the first jejunal loop is picked up and marked with a fine silk suture, which is left long A clamp is applied to this suture to identify the jejunal segment required and to deliver the jejunum from the abdomen when needed, thus the operator may avoid searching the proper jejunal loop when his hands may have become contaminated at the time of division of the stomach and duodenum After division of the stomach at the selected level, the jejunum is attached with a row of interrupted black silk sutures across the divided end of the stomach the anastomotic orifice being made between the side of the jejunum and the end of the stomach toward the border of the greater curvature (Fig 8-13) This is often referred to as a Hofmeister modification of the Billroth II, but actually it is a von Eiselberg resection, described in 1889 von Eiselberg closed the lesser curvature end of the transected end of the stomach, thus reducing the size of the gastric stomal orifice He then anastomosed part of the divided stomach to the side with the jejunum, von Eiselberg also brought the jejunum anterior to the colon as we do

After the posterior row of interrupted black silk sutures has been inserted, an incision is made into the jejunum opening into the lumen and a similar incision is made into the stomach, cutting away the clips along the stomal orifice A continuous suture of No 0 chromic catgut is then started at the lesser curvature side of the stoma and carried posteriorly toward the greater curvature, uniting the muscularis and mucosal layers It is then continued on the anterior wall to form the mucosal stitch of the anterior layer of the stomal orifice, thus closing the anastomosis This anterior suture layer is further reinforced with interrupted sutures of black silk The jejunal loop is further attached by the sutures across the entire inverted end of the stomach so that the jejunal loop forming the anastomosis does not hang by its stoma alone but has a broad attachment to the transected end of the stomach This completes the anastomosis

As stated above with resection of the stomach for carcinoma the gastrocolic and gastrohepatic omenta are removed also When the lesser peritoneal cavity is opened, the dissection is carried laterally toward the duodenum and at the site of the middle colic artery the reflected peritoneum is divided, continuing the dissection posterior to the duodenum All the lymphatic tissue adjacent to the pylorus is detached from the mesocolon to make sure that all nodes in this area are very carefully dissected out The duodenum is transected at a very low point almost down to the level of the ampulla of Vater Above the convexity of the duodenum all nodes along the common

bile duct, hepatic artery, and portal vein are included in the dissection Mobilization is proceeded well along the lesser curvature, removing all the gastrohepatic omentum The duodenum is divided and closure made in a manner similar to that of closure for ulcer The stomach is then turned cephalad and the blood supply of the lesser curvature, the left gastric artery off the celiac axis, easily visualized, this is divided and ligated The splenic artery and vein can be ligated just medial to the left gastroepiploic artery directly above the superior border of the pancreas, the spleen may be elevated out of its bed and only a few short gastric arteries must be ligated above, along the convexity of the stomach The stomach is transected high and only a small gastric remnant (15 to 20 per cent) is left in a radical removal for malignant tumor This type of high radical partial gastrectomy is an effective operation for cancer The jejunal anastomosis is more easily performed than an esophagojejunal anastomosis, and problems of diet and nutrition are much less than with total gastrectomy Moreover, patients undergoing this type of operation are not likely to develop a primary anemia, as the stomach remnant is still

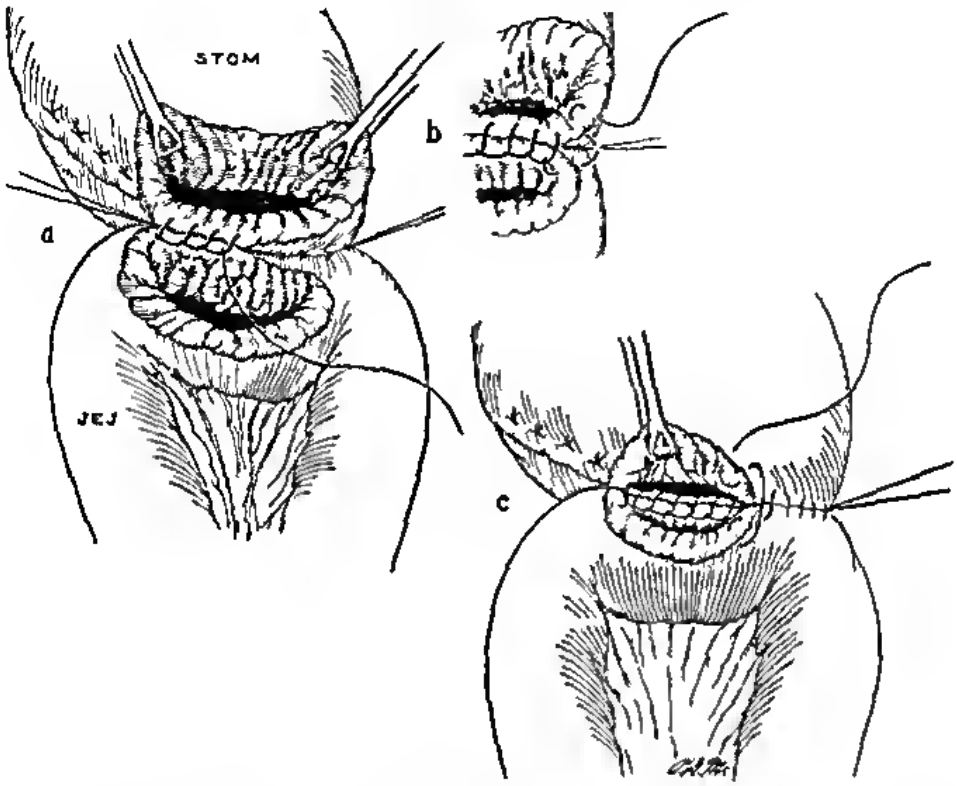


Fig 8 13 Formation of the gastrojejunal stoma The stoma is placed at the greater curvature third of the transected end of the stomach (*a*) The lesser curvature end of the transected stomach has been closed by a continuous mucosal suture of No 0 chromic catgut reinforced with interrupted sutures of fine silk A running interlocking suture of chromic catgut is started at the lesser curvature end of the stomal orifice and continued toward the greater curvature (*b*) and (*c*) Suture is continued anteriorly as a running Lembert s *suture to complete closure of incision in the stomach and jejunum thus* forming the stomal orifice A second layer of interrupted fine black silk is used to reinforce the gastrojejunal anastomosis The distal jejunal loop on the lesser curvature side is attached to the closed end of the stomach with three or four interrupted sutures of silk this supports the jejunum and avoids undue tension on the gastrojejunal stoma

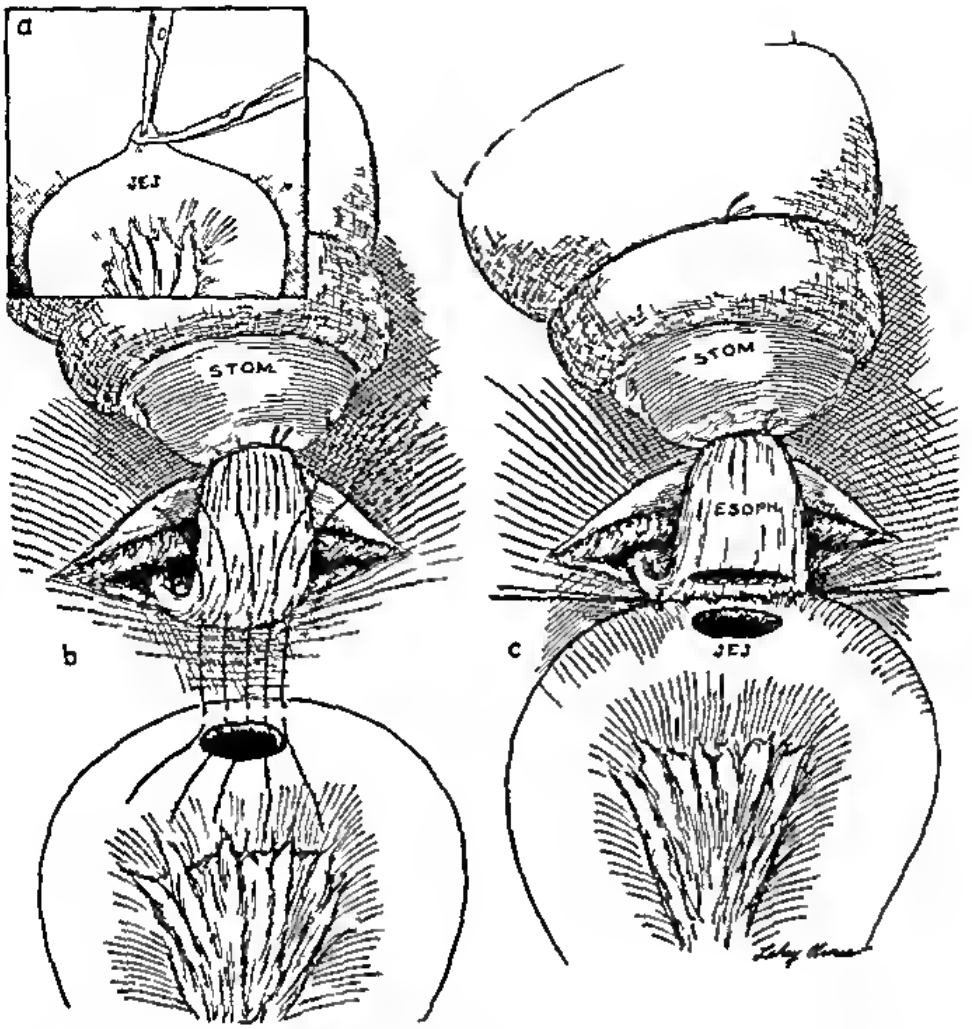


Fig 8 15 Esophagojejunal anastomosis (*a*) The stomach has been completely mobilized and turned cephalad over the left costal margin (*b*) To form the first posterior suture line interrupted silk sutures are placed before the jejunum is approximated to the esophageal wall Note also that the jejunal lumen is opened before the posterior silk sutures are tied this permits trimming away excessive mucosal tissue and more ready control of bleeding from the jejunal incision (*c*) Posterior silk sutures are tied and an incision is made into the lumen of the esophagus Esophageal contents can then be aspirated, preventing contamination A running suture of No 0 chromic catgut is started posteriorly on the left side and continued to the right and anteriorly right to left to form the anterior suture line The esophagus is completely divided as the anterior suture line progresses to complete the closure of the esophagojejunal anastomosis A second suture line of interrupted black silk reinforces the anastomosis Interrupted silk sutures are used to attach the peritoneum of the diaphragm to the jejunum and thus support the esophagojejunal anastomosis to the diaphragm

cephalad and the major blood vessels supplying the stomach may be ligated The left gastric artery is clamped and ligated as it branches from the exposed celiac axis The loose areolar tissue about the celiac axis, together with any remaining nodes, may be stripped readily The splenic artery directly above the upper border of the pancreas is followed to the hilus of the spleen, and splenic artery together with the vein is ligated just proximal to the left gastroepiploic artery (see Fig 8 11) This maneuver will divide the splenic blood supply and

the vessels to the upper half of the greater curvature, permit removal of the spleen, and control the bleeding from the short gastric vessels The major blood supply of the stomach is thus controlled and the stomach will then be attached only to the esophagus, which has previously been exposed Esophagointestinal continuity is re established by anastomosis of the divided end of the esophagus to the side of a loop of jejunum (Fig 8-15) Following completion of the esophagojejunostomy, an enteroenterostomy is always advisable and is usually carried out This is a simple, effective method of anastomosis that provides an adequate pouch for food and does not involve the risk of

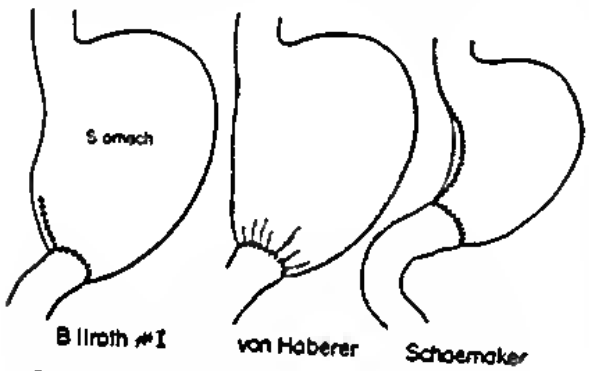


Fig 8 16 Billroth I resection. Types of gastrojejunal anastomoses are shown

contamination associated with a pouch made from a portion of the colon Needless to say, any such pouch, no matter how established, acts only as a reservoir, has no digestive function, and does not serve to increase the comminution or mixing of food with pancreatic and biliary secretions A food pouch formed by anastomosing two loops of the jejunum as an enteroenterostomy has proved very satisfactory

The technique of the Billroth I operation (Fig 8-16) is very similar to that used in the modification of the Billroth II Gastric mobilization is accomplished in a similar manner and the open end of the duodenum can then be attached to the divided end of the stomach at the point where the stomal orifice is to be made A Billroth I anastomosis should be made without tension and this can be done readily in most cases The only important technical change in the dissection is the thorough mobilization of the duodenum so that it can be anastomosed to the end of the stomach remnant without tension We believe that the Billroth II operation can be employed more readily in most resections for carcinoma or duodenal ulcer The Billroth I procedure is an excellent method in many cases of gastric ulcer when a very radical gastric resection is not necessary This is particularly true if the patient is a woman or is thin and undernourished We do not advocate routine use of the Billroth I operation for duodenal ulcers, but prefer to utilize the conventional Billroth II procedure that permits a higher resection for the average duodenal ulcer We do not believe that Billroth I will allow adequate resection for carcinoma of the stomach only in a few instances can the duodenum be anastomosed without tension to the remnant of a stomach that has been resected high, as is necessary in cases of gastric carcinoma We have not employed the procedure in establishing esophagoduodenal anastomosis following total gastrectomy

## Gastroenterostomy

Gastroenterostomy was first performed by Anton Wolfler (1881), an assistant in Billroth's Clinic In 1885 von Hacker utilized the method of making the opening in the transverse mesocolon and making the gastrojejunostomy retrocolic. Many modifications of gastroenterostomy have been employed over the years, most of them concerning the position and application of the jejunal loop

Gastroenterostomy is still a very useful operation and is often employed as a conservative procedure in cases of peptic ulcer, for those patients in whom the stomach is chronically obstructed because of an old scarred ulcer in the duodenum or in the pylorus, or an ulcer that is inactive and in which gastric analysis shows low acid values Gastrojejunal ulcers may

follow gastroenterostomy, especially when it is performed because of nonobstructing ulcers in the duodenum or stomach It is often used as a conservative operation if the patient s general condition will not permit a more radical procedure such as a gastric resection Gastroenterostomy has frequently been combined with vagotomy

Gastric resection has replaced gastro enterostomy as a surgical procedure in the majority of cases of peptic ulcer because of the fairly frequent occurrence of gastrojejunal ulcers after gastroenteros tomy

the base of the mesocolon The stomach is pushed downward and directed toward the mesocolic opening by the Babcock forceps, which has been previously applied on the anterior wall of the stomach The edge of the stomach is grasped with a second Babcock forceps applied alongside the first Babcock forceps, the posterior gastric wall can now be delivered through the rent in the transverse mesocolon and the colon allowed to fall back into the abdomen above the clamp so that it is out of the operative field The gastric stoma should open from above downward

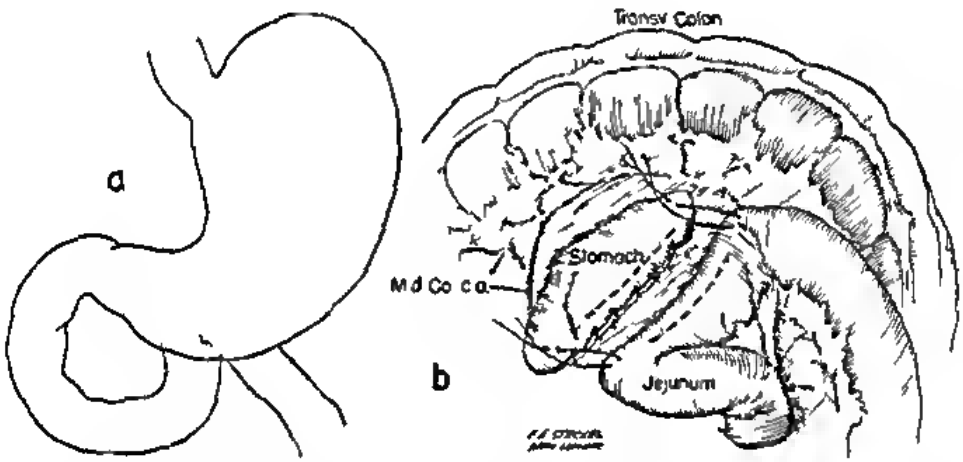


Fig 8 17 Posterior gastroenterostomy Note that edge of incision in meso colon is sutured to stomach jejunum is then sutured to stomach wall and an incision is made into the stomach and jejunum to form the stomal orifice

Gastroenterostomy is preferably per formed without clamps The site of the gastric stoma is marked by grasping the greater curvature border opposite the in cisura angularis with a Babcock forceps This is done on the anterior wall of the stomach before the transverse colon is turned cephalad and before the rent is made in the mesocolon The first loop of the jejunum is exposed by elevating the transverse colon cephalad, exposing the duodenojejunal angle at the ligament of Treitz The jejunal loop 10 to 15 cm. from the ligament of Treitz is grasped with a Babcock forceps and elevated into the operative field An incision is made in the transverse mesocolon to the left of the middle colic vessels and near

and to the left with the lower end of the anastomosis just above the greater curvature A single suture of silk unites the jejunal wall to the selected part of the stomach wall, which will form the upper limit of the stomal orifice A second silk suture is placed 6 to 15 cm. distal on the jejunum and unites the jejunum to the stomach near the greater curvature, this will form the lower end of the gastrojejunal stoma (Fig 8 17) These two silk sutures act as stays and mark the limit of the stomal orifice The portion of jejunum between these stay sutures is now united with interrupted fine silk sutures to form the posterior suture line An incision is made into the jejunum and also into the stomach A

running suture of No 0 chromic catgut is used to unite the mucosa and muscularis of the jejunum and stomach The suture is started at the posterior edge of the incision and carried anteriorly to form the stomal orifice and thus close the incision in the jejunum and stomach A second anterior suture line is completed by interrupted sutures of fine silk The rent in the mesocolon may now be closed about the gastrojejunal stoma by suturing the edges of this rent to the stomach wall The mesocolic rent may be closed by suturing the edges to the stomach before starting the anastomosis, provided the position and application of the jejunal loop have been determined The mesocolic rent may be more readily sutured before the jejunum is attached to the stomach However, it may be done in either way

## Vagotomy

In 1943, Dragstedt and Owens reported on the use of vagotomy in the surgical treatment of duodenal ulcer Vagotomy (division of the vagus nerves) prevents the cephalic phase of acid formation in the stomach Vagotomy is often employed in combination with gastroenterostomy or pyloroplasty, and more recently with hemiresection of the stomach The left lobe of the liver is detached from the diaphragm by division of the triangular ligament and retracted to the right An incision is made through the peritoneum and over the esophagus and the right index finger introduced into the mediastinum posterior to the esophagus. After the vagus nerves have been gently separated from loose areolar tissue by blunt dissection with finger and by traction 6 to 8 cm of esophagus may be exposed A soft rubber catheter is carried posterior to the esophagus and traction exerted on the esophagus The vagus nerves are easily identified and separated from the esophagus and a segment is excised from the right or posterior and left or anterior vagus nerve All branches of the vagus nerves may be readily palpated by continued traction on the catheter All strands of the vagus nerves should be divided carefully and ligated, and all bleeding points ligated about the esophagus

## Complications of Gastrectomy

This discussion applies to the immediate complications occurring after resection These complications are primarily as follows leakage of the duodenal stump with the development of a duodenal fistula, postoperative bleeding obstruction of an efferent loop, and the possibility of acute pancreatitis caused by injury to the pancreas during gastric resection

With careful mobilization of a pliable wall of the duodenum beyond the duodenal ulcer, the mucosa and muscularis may be inverted very accurately, and the closed end of the duodenum carefully reenforced with interrupted sutures of black silk When the inversion has been completed, the duodenal stump may be covered with adjacent mesentery by a few interrupted sutures of fine black silk. If it is suspected that the inversion is insecure and that the pancreas may have been injured, a cigaret drain may be placed down to the head of the pancreas, near the inverted end of the duodenum, and brought out laterally through a stab wound in the right side of the abdomen This drain can be removed in five to seven days If a duodenal fistula develops, continuous suction with a catheter in the drainage tract will effectively control drainage and will result in rapid closure of the fistula

It is possible for biliary obstruction to occur in an occasional case, but with accurate visualization of the common bile duct, inversion sutures of the duodenum are not likely to impinge upon the duct or the ampulla of Vater If the level of the common bile duct is in doubt the duct may be opened, and a No 14 to 16 rubber catheter threaded through into the duodenum Further mobilization of the duodenum can then be effected without danger of injury to the common bile

duct or ampulla and closure can be made above the catheter, which may be palpated very readily

Acute pancreatic necrosis following gastric surgery is a relatively rare occurrence As Warren has pointed out, disturbances in blood and urinary diastatic activities are probably more common than is generally recognized Except for direct injury to the pancreatic ducts, which may be observed at the time of operation or at autopsy, acute pancreatic necrosis secondary to gastric resection is infrequent, but does occasionally occur

Pancreatic fistulas very seldom occur if the possibility of injury to the pancreas is kept in mind If such injury should occur, a drain can be inserted and in many instances a subhepatic or subdiaphragmatic abscess can be avoided Subhepatic and subdiaphragmatic abscesses rarely occur if meticulous attention is paid to the dissection, avoidance of contamination, prevention of injury to the pancreas, and to the closure of the duodenal stump

Obstruction or leakage of the gastrojejunal anastomosis is also uncommon, as is obstruction of the efferent loop Obstruction of the proximal or afferent loop at the stomal orifice is extremely uncommon and in most cases such obstruction is caused by edema One of us (H D A ) has emphasized that meticulous attention must be paid to the control of hemorrhage at the stomal orifice to prevent the formation of a hematoma and the development of obstruction of either loop by impingement upon the stomal orifice Such obstruction, however, occurs very rarely When gastrojejunal obstruction does occur it is transient and surgical intervention is rarely required, dependent drainage with a Levin tube is sufficient and gastrojejunal drainage is resumed early Any malfunction of the stoma will be caused by the development of edema and obstruction of the afferent or efferent loop at the site of the stoma

Postoperative anemia and massive hemorrhage are likewise extremely uncommon if meticulous attention is paid to the ligation of all bleeding points When the clips inserted by the von Petz clamp are trimmed away at the site of the stomal orifice all bleeding points should be grasped with a small mosquito forceps and ligated individually When the von Petz clamp is not employed, vessels in the submucosal layer may be ligated as described above after division of the seromuscular layer and before the mucosa is divided

Late Complications Anemia occasionally develops after partial gastrectomy, but is always of a hypochromic type caused by iron deficiency Secondary anemia will respond readily to doses of ferrous sulfate

Iron deficiency anemia also develops early after total gastrectomy Hematopoiesis is dependent upon a normal stomach therefore, following any total removal of the stomach a macrocytic, megaloblastic or primary type of anemia will manifest itself in all cases if the patient lives long enough Secondary anemia is first to be noted, but a primary type of anemia will develop at a much later period more often two to three years or more after total gastrectomy Total gastrectomy should be followed permanently by monthly injections of vitamin $B_{12}$ to prevent this

Appropriate blood studies should be carried out at regular intervals after operation so that the development of anemia of any type may be recognized early and treatment promptly instituted Some patients who have neglected to see their physician regularly after undergoing total gastrectomy have developed severe anemia with very low hemoglobin and red blood cell count When finally they do go for a check up examination, the chief complaints are weakness, dyspnea, and malaise Either type of anemia responds well to the proper therapy

Gastroileostomy should be an uncommon complication of gastric surgery The main interest in this complication lies not in the numbers encountered but in its supreme preventability and remediability

Many instances were reported during the heyday of gastroenterostomy but the complication was not serious when a short circuit procedure was employed as some of the gastric contents drained through the pylorus The error continues to be made during gastric operations and is a much more serious matter in gastric resection since the gastric remnant is anastomosed to the lower ileal loop and weight loss is most pronounced in these cases Classical symptoms are diarrhea and weight loss severe anemia develops in some cases but pain is not a notable feature We have seen ten instances of this complication during the past twenty eight years four occurring in patients who had undergone partial resection the remainder occurred in an attempted performance of gastroenterostomy All these operations were done prior to coming to this clinic for treatment Diagnosis is usually readily made by x ray examination and both barium meal and barium enema studies should be carried out In most instances the clinical course is characteristic and surgical treatment is required When this complication follows gastroenterostomy simple disconnection may suffice but if an ulcer or scar of a previous ulcer is present gastric resection is the best treatment When it occurs after resection the ileum should be detached from the stomach and the gastric remnant anastomosed to the proper jejunal segment.

Gastroileostomy should not occur if the proper jejunal loop is identified and marked before resection is begun It is safe practice to have the assistant as well as the surgeon always identify the ligament of Treitz and the correct segment of jejunum

## SURGICAL ASPECTS OF LESIONS OF THE PROXIMAL STOMACH

tremely important Gastric ulcers located near the cardia or in the fundus of the stomach usually produce very acute symptoms with pain located high in the epigastrium and in the lower sternal region frequently associated with vomiting Proximal lesions also may present another important symptom that is, dysphagia that is not associated with lesions occurring in lower areas of the stomach Since many of these proximal lesions prove to be carcinomatous, they must be handled with extreme care Resection should be carried out in most cases It is neither safe nor dependable to evaluate such proximal lesions by gastroscopy because of the danger of possible perforation of the lower esophagus and the inability to obtain a satisfactory biopsy specimen by this method If endoscopy and biopsy are desirable they should be carried out with direct visualization through the esophagoscope Unfortunately, barium studies may not indicate the presence of a carcinoma of the cardia or fundus until the lesion is advanced and in our experience the lesion is always more extensive than the roentgenogram suggests Because of these well known difficulties in making an early diagnosis of proximal gastric lesions it is advisable that the patients have careful and repeated barium examinations of the proximal stomach at short intervals whenever classical clinical symptomatology is present This symptomatology consists of epigastric or substernal distress or pain anorexia nausea vomiting and weight loss and especially any degree of dysphagia Esophagoscopy and exploration should be advised if constant abnormalities are demonstrated in the proximal third of the stomach by any of the methods of investigation outlined above

### Surgical Approach to the Proximal

be exposed for adequate resection by utilizing either an abdominothoracic or a transthoracic transdiaphragmatic incision We prefer the abdominothoracic incision for benign lesions of the proximal stomach that require less radical resection In addition, it is a good incision for debilitated patients in whom roentgenograms reveal an extensive lesion of the upper end of the stomach Since these cases are very likely to be inoperable, it is better to determine resectability through the abdominal part of an abdominothoracic incision, thereby avoiding a more extensive procedure if the tumor is inoperable For this approach, the patient should be positioned on the operating table on his back with the left side slightly elevated and the left arm suspended from the anesthetist s screen The abdominal part of the incision may be either a vertical rectus-splitting or retracting incision, or an oblique or transverse rectus incision across the epigastrium (Fig 8 18), either type of incision should terminate on the costal margin opposite the anterior end of the seventh or eighth rib so that it may be extended into the chest at this level if the lesion proves to be resectable

If the carcinoma appears to be resectable by preoperative evaluation and studies, we prefer to use a transthoracic-transdiaphragmatic incision (Fig 8 19), placing the patient in the lateral position with the left side up The eighth rib is resected from its periosteal bed, the ninth is transected posteriorly, and the diaphragm opened widely in the line of this incision from the esophageal hiatus to the anterior margin of the chest Utilizing this procedure, carcinoma of the cardia and fundus can be well exposed on all sides, especially the important posterolateral aspect This will allow the widest possible block dissection of the proximal portion of the stomach, including the spleen and the entire gastrosplenic and gastrohepatic mesentery and the celiac

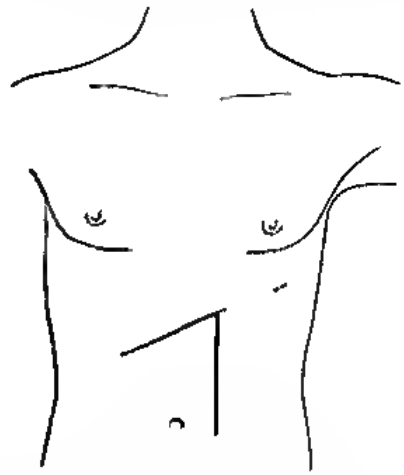

Fig 8 18 The abdominothoracic incision for exposure of the proximal third of the stomach

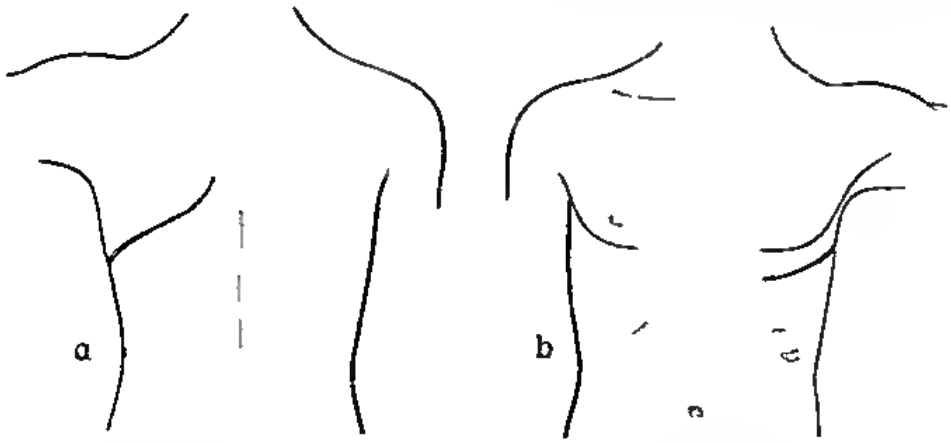


Fig 8 19 The transthoracic transdiaphragmatic incision for exposure of the proximal stomach

and perigastric nodes, if necessary, the distal pancreas, portions of the diaphragmatic crura, and any amount of the esophagus may be resected This optimum exposure of the lower esophagus is of extreme importance since cardial carcinoma can often extend microscopically or grossly for some distance intramurally in the lower esophagus Since it is often difficult to estimate the exact area of such extension, frozen section studies must be carried out to make certain that the margins of the resection are free of microscopic carcinoma Considerably greater flexibility in radical resection under the very best direct vision at all times, is possible with this approach as compared with the abdominothoracic incision which limits exposure to some extent to the anterior and lateral visualization of this region

## Surgical Management of Lesions of the Proximal Stomach

If a benign ulcer or tumor is encountered in the proximal portion of the stomach much less radical resection is advisable If technically feasible a wedge or sleeve resection is a good procedure in such cases However frozen sections should again be employed to make certain that the lesion is truly benign since the surgeon cannot depend on gross characteristics to make this important decision If frozen section shows that an ulcer that appears benign is actually malignant a wide proximal resection of the stomach should be carried out If local excision is not feasible and the lesion has proved benign a less radical proximal resection should be done tailoring the transected proximal end of the [illegible]

tensive proximal resection for carcinoma, since in these cases we have not felt that any important factor of ulcer diathesis was associated However, Smith, Moulder, and Adams report that even these patients may eventually have difficulty from antral stasis and pylorospasm if they survive for many years

### *Technique of Proximal Subtotal Gastrectomy*

An adequate exposure by one of the two approaches described is essential in order to visualize the proximal stomach for the required amount of resection, depending upon the type and extent of the lesion encountered Even more important than this, perfect visualization and technical maneuverability are absolutely necessary for making the esophagogastric anastomosis The morbidity, mortality, and the late functional results of this operation depend to a large degree upon the success of this anastomosis After the diaphragm has been opened and the crura divided down to the esophagus as it lies in the hiatus, the lower end of the esophagus is retracted from behind the aorta and freed from the pericardium and the contralateral pleura A length of Penrose rubber tubing is passed around the lower end of the esophagus to provide traction The gastrocolic mesentery is divided and the lesser omental sac opened widely The gastrohepatic mesentery is divided in the thin avascular area above the antrum and a second length of Penrose tubing passed around the antrum of the stomach for traction By this means trauma from handling the lesion or from instruments applied to the

creas in the lesser omental sac before the spleen and the fundus of the stomach are mobilized, splenectomy can be facilitated, and considerably less vascularity will be encountered in the subsequent dissection The spleen is then mobilized and the pedicle divided, being careful not to injure the end of the tail of the pancreas in the splenic hilum It is well in all types of gastric surgery to avoid opening pancreatic tissue or injuring it even to the slightest degree unless it is part of a planned resection, since this may be the direct cause of serious complications such as acute pancreatitis, fistula, residual abscess, or dehiscence of the anastomosis

When the spleen is freed from the tail of the pancreas, mobilization of the greater curvature is completed However, we often preserve the right gastroepiploic artery by staying outside this vessel as we divide the gastrocolic omentum The artery is sectioned later if necessary, to provide greater mobility for the distal gastric stump in bringing it up to the esophagus The stomach can now be rotated medially, permitting a good exposure of the gastrohepatic mesentery This mesentery is then divided from the diaphragm downward until the left gastric artery is encountered at the border of the pancreas and the celiac axis This artery is divided close to its origin, removing the entire gastrohepatic mesentery and the celiac nodes The right gastric artery is preserved at this point and will be ligated only if additional mobility is required

The stomach and lower esophagus have now been entirely freed and the extent of the resection is determined with regard to the limits of the lesion at this point (Fig 8 20) Again, it must be stressed that microscopic intramural extension is likely to be present, both distally toward the antrum and proximally into the lower esophagus Therefore, it frequently becomes necessary to resect a considerable portion of the stomach and, to a greater extent, along the lesser curvature side of the stomach The stomach is transected obliquely, preserving a little more of the greater than of the lesser curvature The end of the stomach is closed carefully in layers Figure 8 21*a*, a continuous mucosal suture of fine chromic catgut, Figure 8 21*b*, a running, inverting Lembert type of suture in the seromucosal layer using fine chromic catgut, and Figure 8 21*c*, a serosal layer of interrupted inverting Lembert sutures of fine silk An adequate aperture is left on the greater curvature side of the stomach for anastomosis with the esophagus This aperture should be slightly larger than the esophagus above In spite of past teachings that an anastomosis in a suture line of this type is undesirable, it has worked out very satisfactorily without complications in our hands Large amounts of stomach wall must not be turned in with this end closure, however, and the closure must be made in meticulous layers or it will be difficult to make a satisfactory esophageal anastomosis at the angle We no longer use the von Petz machine for transecting the stomach in this particular operation because of the resultant bulky turn in of the line of silver clips

Our method has the advantage of allowing very ready adjustment of the gastric opening to the size of the esophagus above The esophagus is frequently of very small caliber, and in order to prevent stricture and poor function it is best to increase the size of the anastomosis by enlarging the end of the esophagus This may be accomplished by making a short longitudinal incision at the end, which is more satisfactory than an oblique incision across the esophagus since the circulation of the tip of the obliquely transected esophagus may be impaired The detail of the esophagogastric anastomosis is the same at any level a two layer anastomosis made entirely with interrupted fine, No 000 silk sutures

Because of the great retractability of the esophagus and the difficulty in controlling the esophagus after transection, the stomach is left attached to the esophagus for traction until the posterior row of sutures is placed between the esopha-

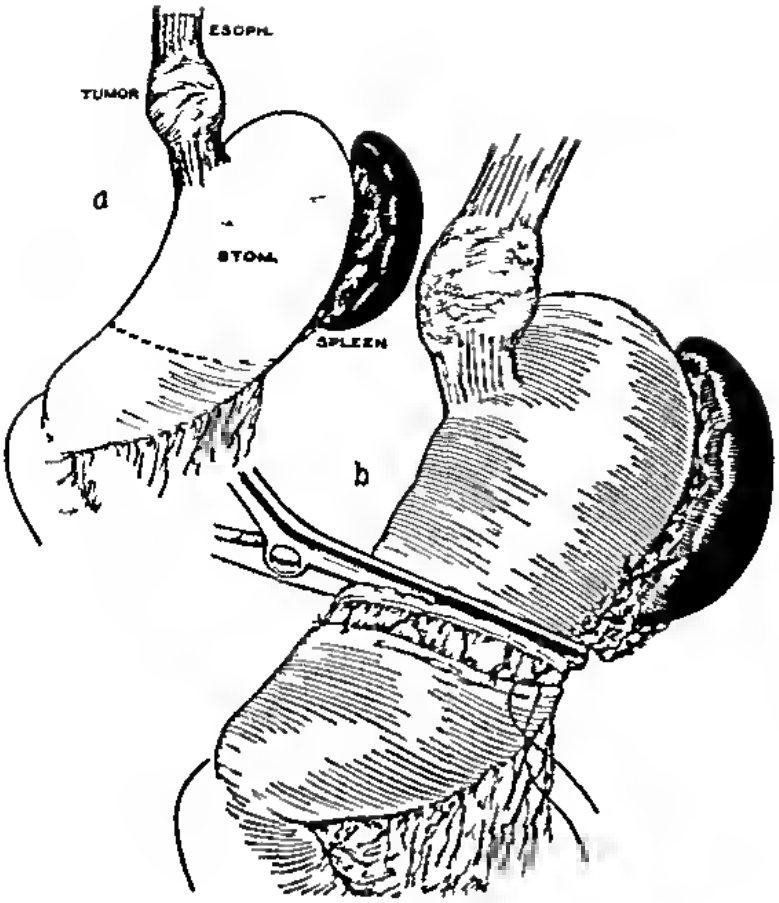


Fig 8 20 (*a*) Approximate extent of resection in proximal subtotal gastric resection (*b*) Method of transection of the distal portion of the stomach Serosal muscular layer is incised, exposing large vessels in submucous plane These vessels are ligated in continuity with fine silk sutures before the mucosa is divided

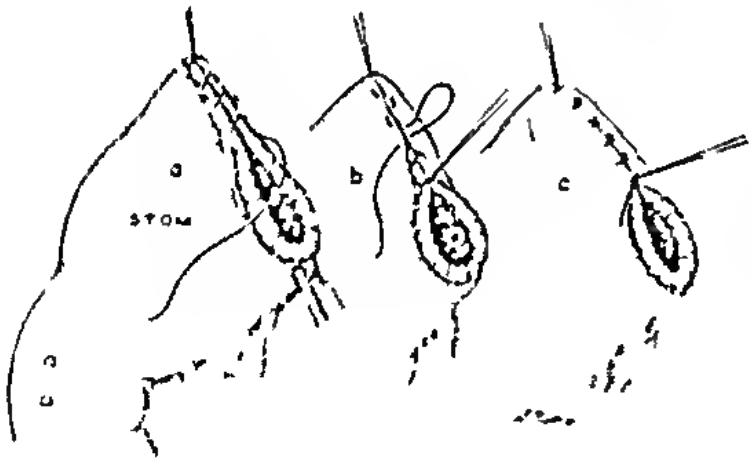


Fig 8-21 A portion of the transected end of the stomach is closed in layers. (*a*) Continuous suture of fine chromic catgut for the mucosa (*b*) fine chromic catgut forms a running inverting Lembert type of suture in the serimucosal layer, (*c*) interrupted inverting Lembert sutures of fine silk complete the closure Note that the aperture to form the stomal orifice is left on the greater curvature side of the transected

MEDICAL COLL
LIBRARY
UDAIPUR

Fig 8 22 (*a*) First row of interrupted sutures of the esophagogastric anastomosis (*b*) Second or mucosal row of sutures of the posterior half of the anastomosis

postoperative period and in promoting rapid healing and preventing late strictures

Finally, the first mucosal serosal layer is completed anteriorly, exercising care not to turn in a large amount of the wall with this line of sutures, thereby producing a bulky shelf at the anastomosis that may result in partial obstruction The operative field is then irrigated with penicillin solution, the mediastinal pleura closed loosely with interrupted sutures, and the diaphragm is closed with great care In this type of resection, no great bulk of the stomach passes through the diaphragm and it can be closed to approximately the size of a normal hiatus at the normal anatomical level The chest is closed in layers with an intercostal catheter placed in the chest for suction drainage

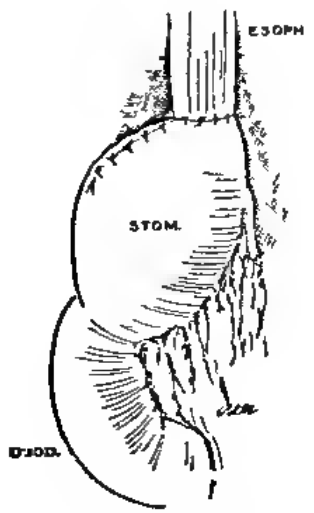


Fig 8 23 Completed anastomosis

### *Technique of Proximal Total Gastric Resection*

As in the management of lesions of the distal part of the stomach, an adequate proximal subtotal gastrectomy is by far the most common operation employed for those found in the proximal portion Under certain conditions, however, total gastrectomy and more extensive resection of the lower portion of the esophagus are necessary to obtain an adequate margin beyond the carcinoma both distally and proximally (Fig 8 24) Under these conditions the stomach and spleen are mobilized as previously described the duodenum is transected just beyond the pylorus and the duodenal stump closed If the primary cardial carcinoma has extended into the lower esophagus this dominal total gastrectomy Instead, we employ a Roux en Y type of procedure with an end to-end jejunoesophageal anastomosis (Fig 8 25) the jejunum is transected about 6 to 8 inches from the ligament of Treitz, dividing the highest jejunal arteries near the root of the mesentery and preserving the arcades Adequate circulation and mobility must be provided to the distal end of the jejunum to allow satisfactory healing of the anastomosis without undue tension The proximal end of the divided jejunum is reunited with the jejunum proper about 6 to 8 inches distally by an end to-side anastomosis. This is made in two layers, as in the technique of gastroenterostomy The end to-end jejunoesophageal anastomosis (Fig 8-26) is made with meticulous care, using two layers of interrupted

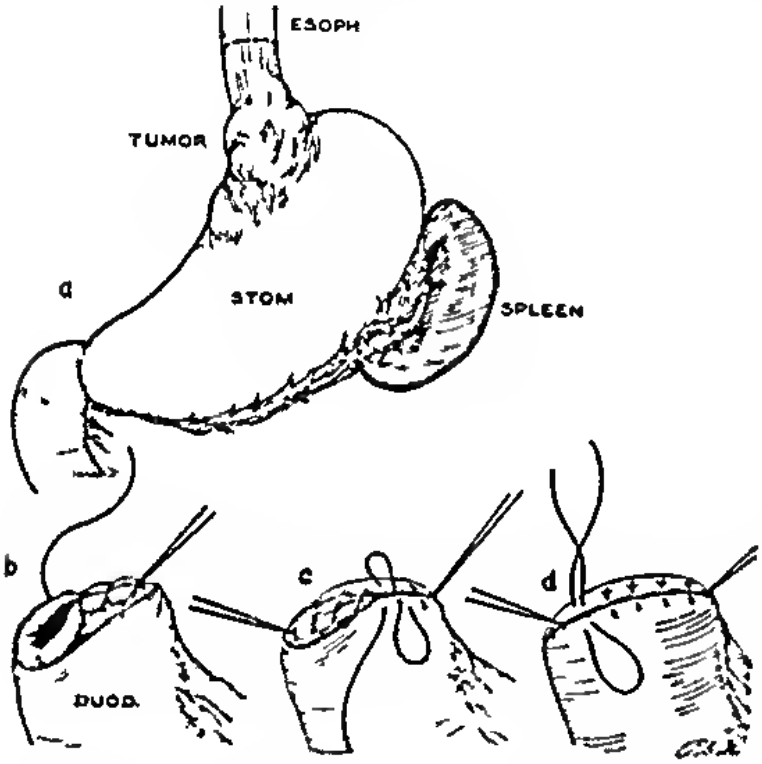


Fig 8 24 (*a*) Approximate extent of resection in proximal total gastric resection Closure of duodenal stump (*b*) continuous mucosal suture of fine chromic catgut, (*c*) inverting Lembert suture in seromuscular layer, using fine chromic catgut (*d*) serosal layer of interrupted inverting Lembert sutures of fine silk

## Postoperative Management of Proximal Gastric Resections

The postoperative management of patients who have had an esophageal anastomosis of any type must be most careful Both the Levin tube and the chest tube are usually removed in twenty four to forty-eight hours Nothing is given by mouth for forty eight hours and on the third postoperative day, 1 ounce of water per hour is given by mouth Adequate fluids and electrolytes are administered parenterally during this period and continued until sufficient amounts can be taken by mouth If the ounce of water is tolerated well on the third postoperative day, 2 ounces of clear fluids per hour are given on the fourth day, supplemented with parenteral fluids and progressing on the fifth day to a liquid diet that includes milk in quantities of 3 ounces per hour At this point the quantity of the feeding is not increased, but soft foods are added to the diet so that, by the end of the first week, multiple small meals of soft bland foods are taken satisfactorily In order to avoid increased complications, this routine must not be altered and must not be pushed with respect to quantity at any point These patients are permitted out of bed within the first few postoperative days as are most surgical patients today It is also important in dealing with all patients with an esophageal anastomosis to give large doses of antibiotics for coverage during the first week or ten days It has been our practice to administer 1,000,000 units of penicillin and 0 5 Gm of streptomycin every six hours for the first forty eight hours, and then Bicillimycin twice a day for the remainder of the period in which it is needed

## Complications of Proximal Gastric Resections

Aside from complications of pulmonary, cardiac, and renal origin which are commonly seen after any major surgical procedure in debilitated and depleted patients, those particularly associated with proximal gastrectomy and gastroesophagectomy are related to the anastomosis and the suture line If the latter are carried out meticulously, obstruction, dehiscence, and leakage, with resulting mediastinitis empyema, and peritonitis, will be avoided in most cases In addition, if any unrecognized residual microscopic carcinoma is left in the line of resection and anastomosis, dehiscence will commonly occur A poorly executed anastomosis may remain intact during the immediate postoperative period, but can result in a late stricture that will cause dysphagia, distress, malnutrition, and weight loss In

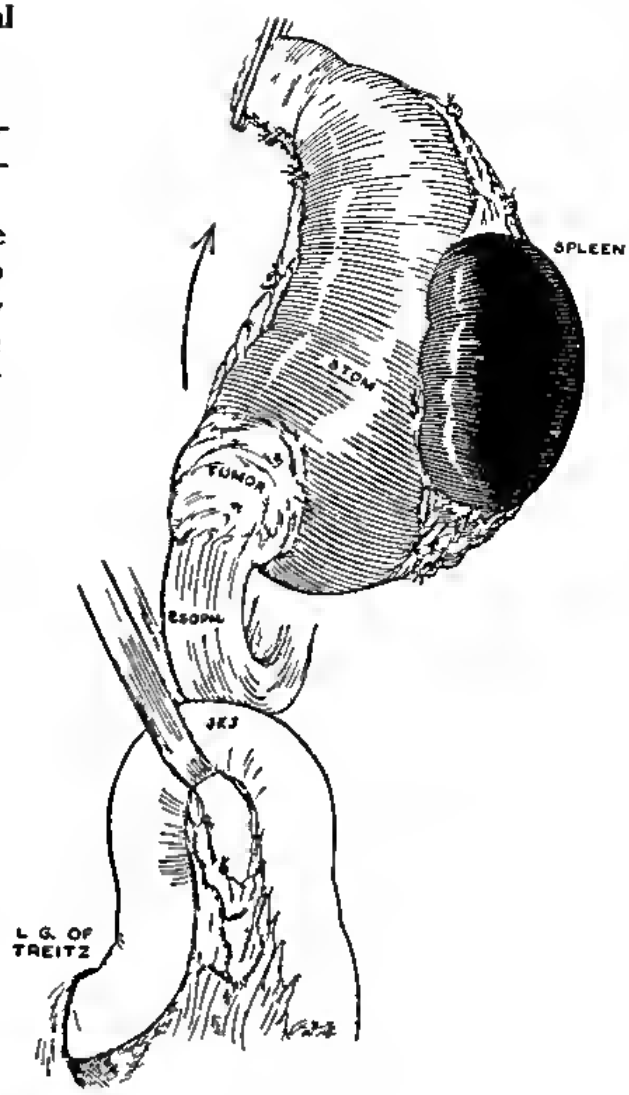


Fig 8 25 Jejunal mobilization for anastomosis with the esophagus

these patients, varying degrees of stricture at the gastroesophageal or jejunoesophageal anastomosis are by far the most common cause of inability to ingest food, rather than the small size or total loss of the stomach Dilatation of the stricture is usually helpful, but is often inadequate and difficult to maintain

## Gastric Problems Associated with Hiatus Hernia, Cardiospasm, Cardial Stricture, and Ulceration

No consideration of gastric surgery can be complete without some reference to the gastric aspects of hiatus hernia, cardiospasm, cardiostricture, and ulceration

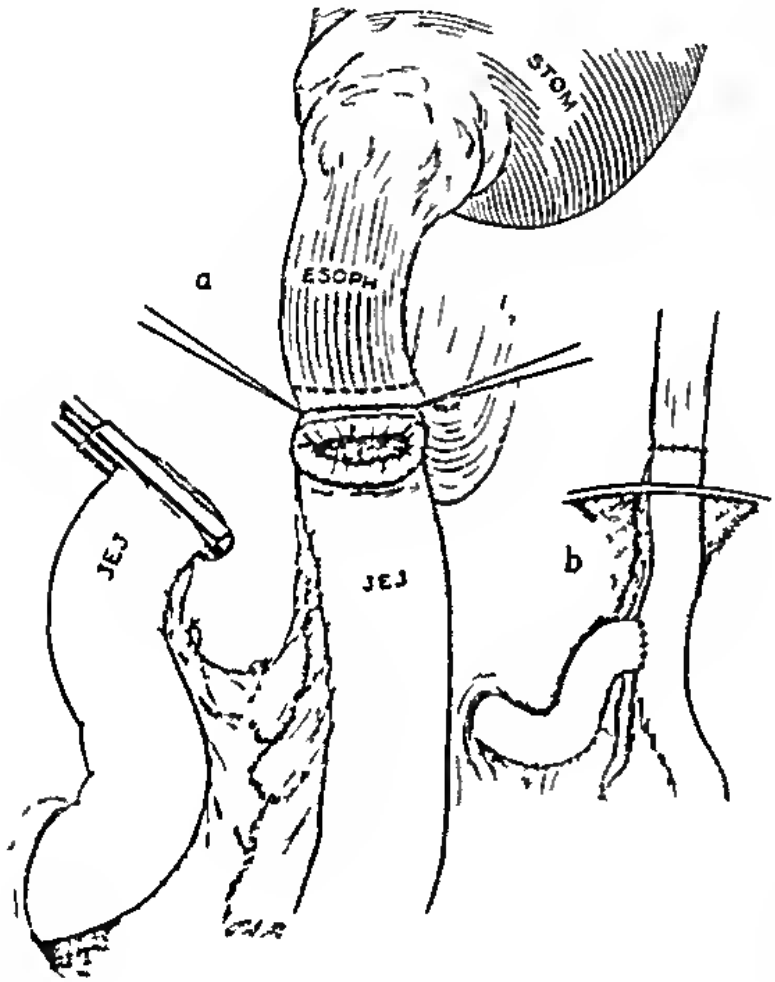


Fig 8-26 (a) End-to-end jejunoesophageal anastomosis, (b) completed Roux en Y anastomosis, with jejunoesophageal anastomosis above the diaphragm

this operation is definitely limited, and it should not be used in the presence of advanced structural damage to the cardia When in cases of true organic stricture of the cardia dilatation for one reason or another has failed, or if cardial ulceration with stricture is present and the possibility of malignancy is difficult to rule out adequately, proximal gastroesophagectomy should be done, taking into careful consideration the ulcer diathesis factor present in these cases A Finney or other type of pyloroplasty must be carried out simultaneously if good long-term results are to be obtained

## REFERENCES


Adams, H D, Hare, H F, Davis, W L, Trump, J G, and Granke, R C The treatment of carcinoma of the esophagus and cardia by resection and postoperative supervoltage roentgen rays *Ann Surg 138* 631, 1953

Adams, H D, and Ross, J R Posterior perforating peptic ulcer *J A M A 164* 2009, 1957

Aird, I *A Companion in Surgical Studies* Baltimore, Williams and Wilkins Company, 1949, p 593

Allen, A W Cancer of the stomach Editorial *Surg Gynec & Obst 92* 757 1951

Allen, A W, and Welch C E Gastric ulcer, significance of this diagnosis and its relationship to cancer *Ann Surg 114* 498, 1941

Armitage, G, and Rhind, J A Fate of tumour in infantile hypertrophic pyloric stenosis *Brit J Surg 39* 39, 1951

Balfour, D C, and Waugh, J M In Christopher, F *Textbook of Surgery* ed 5 Philadelphia, W B Saunders Company, 1953, pp 977–990

Behrend, A, Katz, A B, and Robertson, J W Acute necrotizing gastritis *A M A Arch Surg 69* 18, 1954

Benedict, E B, and Atkins, L Gastritis Its differential diagnosis and treatment *M Clin North America 40* 343, 1956

Bockus, H L "Symptomatic and Physical Diagnosis of Uncomplicated Gastric and Duodenal Ulcer," in Sandweiss, D J, Ed, *Peptic Ulcer Clinical Aspects, Diagnosis, Management* Philadelphia, W B Saunders Company, 1951, pp 199–208

Boyd, D P, Adams, H D, and Salzman, F A Carcinoma of the esophagus *New England J Med 258* 271, 1958

Carman, R D A new roentgen ray sign of ulcerating gastric cancer *J A M A 77* 990, 1921

Cove, A M, and Curphey, W C Prolapse of redundant gastric mucosa *Surg Gynec & Obst 88* 108, 1949

Dragstedt, L R, and Owens, F M, Jr Supra diaphragmatic section of the vagus nerves in treatment of duodenal ulcer *Proc Soc Exper Biol & Med 53* 152, 1943

Ekstrom T On the development of cancer in gastric ulcer and ulcer symptoms in gastric cancer *Acta chir scandinav 102* 387, 1952

Eliason, E L, and Ebeling, W W Catastrophes of peptic ulcer *Am J Surg 24* 63, 1934

Eliason, E L Pendergrass, E P, and Wright, V W M Roentgen ray diagnosis of pedunculated growths and gastric mucosa prolapsing through pylorus *Am J Roentgenol 15* 295, 1926

Eliason, E L, and Wright, V W M Benign tumors of stomach *Surg Gynec & Obst 41* 461, 1925

Eusterman, G B Newer phases of gastroduodenal ulcer *Gastroenterology 8* 575, 1947

Eusterman, G B, and Balfour D C *The Stomach and Duodenum* Philadelphia, W B Saunders Company, 1935, 958 pp

Eusterman, G B and Senty, E G Benign tumors of stomach *Surg Gynec & Obst 34* 5, 1922

Ewing, J *Neoplastic Diseases*, ed 3 Philadelphia, W B Saunders Company, 1928, p 668

Feldman M, Morrison, S and Myers, P Clinical evaluation of prolapse of gastric mucosa into duodenum *Gastroenterology 22* 80, 1952

Ferguson, L K, and Cameron, C S, Jr Diverticula of stomach and duodenum, treatment by invagination and suture *Surg Gynec & Obst 84* 292, 1947

Fieber, S S Hypertrophic gastritis, report of 2 cases and analysis of 50 pathologically verified cases from literature *Gastroenterology 28* 39, 1955

Finsterer, H Malignant degeneration of

gastric ulcer *Proc Roy Soc Med 32* 183, 1939

GORDON, J S, and MANNING, J J An autopsy survey of gastro-duodenal ulcers in the Philadelphia General Hospital 1920-1937 *Am J Med Sc 202*:423, 1941

GROSS, R E *The Surgery of Infancy and Childhood Its Principles and Techniques* Philadelphia, W B Saunders Company, 1953, 1000 pp

GUISS, L W Collective review End results for gastric cancer, 2,891 cases *Internat Abstr Surg 93* 313, 1951

v HABERER, H Volvulus des Magens bei Carcinom *Deutsche Ztschr f Chir 115* 497, 1912

HILLSTROM, N Kasuistische Beitrage zur Kenntnis des Intestinallipoms *Deutsche Ztschr f Chir 84* 488, 1906

HOLMES, G W DRESSER, R, and CAMP, J D Lymphoblastoma, its gastric manifestations, with special reference to roentgen findings *Radiology 7*:44, 1956

JEMERIN F F, and COLP, R Gastric carcinoma, statistical study based on 344 cases from 1938 through 1947 *Surg Gynec & Obst 95*:99 1952

LAMPERT, F G, WAUGH, J M, and DOCKERTY, M B Incidence of malignancy in gastric ulcers believed preoperatively to be benign *Surg Gynec & Obst 91* 673 1950

LEHMANN W Cited by HAYES, M A, and GOLDENBERG, I S The problems of infantile pyloric stenosis *Internat Abstr Surg 104* 105, 1957

LIPP W F Discussion *Gastroenterology 34* 17, 1958

MAULENER, M Pylorectomy in gastric ulcer *Zentralbl f Chir 50* 1313, 1923

MAINGOT R Gastrojejunocolic fistula following gastrojejunostomy for infantile pyloric stenosis *Lancet 2*:910, 1952

MAINGOT, R *Abdominal Operations* cit 3 New York, Appleton-Century Crofts, Inc, 1955, 1550 pp

MARSHALL, S F The relation of gastric ulcer to carcinoma of the stomach *Ann Surg 137* [illegible], 1953

MARSHALL, S F, and MEISSNER, W A Sarcoma of the stomach *Ann Surg 131* 821, 1950

MARSHALL, S F, and WELCH, M L Results [illegible]

MOSBECH, J, and VIDEBAEK, A. Mortality from, and risk of, gastric carcinoma among patients with pernicious anemia *Internat Abstr Surg 92* 152, (Feb ) 1951

MOYNIHAN, B Observations on gastric and duodenal ulcers *Practitioner 129*:4, 1932

PACK, G T, and MCNEER, G Sarcoma of stomach, a report of nine cases *Ann Surg 101* 1206, 1935

PACK, G T, and MCNEER, G A M A Convention Exhibit, 1956

PALMER, E D Collective review, gastric diverticula *Internat Abstr Surg 92*:417, 1951

PALMER, W L Differential Diagnosis Between Benign and Malignant Gastric Ulcer" In SANDWEISS, D J, Ed, *Peptic Ulcer Clinical Aspects, Diagnosis, Management* Philadelphia, W B Saunders Company, 1951, pp 269-274

PAYER, A. Volvulus ventriculi und die Achsendrehung des Magens *Mitt Grenzg Med Chir 20*:686, 1909

RIENIETS, J H The frequency and pathologic aspects of gastric leiomyoma *Proc Staff Meet Mayo Clin 5* 364, 1930

RIGLER, L G Roentgenologic observations on benign tumors of the stomach, with a report of 15 cases *Am J Surg 8* 144, 1930

RIGLER, L G, and ERICKSON, L G Benign tumors of stomach, observations on their incidence and malignant degeneration. *Radiology 26*:6, 1936

RIGLER, L G, and KAPLAN, H S Pernicious anemia and tumors of stomach *J Nat Cancer Inst 7* 327, 1947

ROSSELET, A, and GILBERT, R Roentgen ray observation of volvulus of stomach. *J de radiol et d electrol 6* 76, 1922

SCHELL, R F, DOCKERTY, M B, and COMFORT, M W Carcinoma of stomach associated with pernicious anemia, clinical and pathologic study *Surg Gynec & Obst 98* 710 1954

SCHMIEDEN, V Zur Technik der Darmnaht, die fortlaufende Einstulpungsnaht bei Enteroanastomose *Zentralbl Chir 38* 531, 1911

SCOTT, W G Radiographic diagnosis of prolapsed redundant gastric mucosa into duodenum with remarks on clinical signifi- [illegible]

SELYE, H "The General Adaptation Syndrome and Peptic Ulcer" In SANDWEISS, D J, Ed, *Peptic Ulcer Clinical Aspects Diagnosis, Management* Philadelphia, W B Saunders Company, 1951, pp 125–146

SINGLETON, A. C Chronic gastric volvulus *Radiology 34* 53, 1940

SMITH, C A, MOULDER, P V, and ADAMS, W E Gastric ulcer following esophago-gastric anastomosis for carcinoma of the esophagus or gastric cardia *Ann Surg 146* 630, 1957

SMITH, F H, and JORDAN, S M Gastric ulcer A study of 600 cases *Gastroenterology 11* 575, 1948

TANNER, N C Non malignant affections of upper stomach *Ann Roy Coll Surgeons England 10* 45, 1952

TRACEY M L Cited by FRANK, L. L. Diverticulum of the stomach *Am J Roentgenol 52* 510, 1944

WALTERS W Diverticula of stomach *J A M A 131* 954, 1946

WARREN K W Acute pancreatitis and pancreatic injuries following total gastrectomy *Surgery 29* 643 1951

WARREN, S *Personal communication*

WHITE F W The Incidence of Gastroduodenal Ulcer ' In SANDWEISS, D J, Ed, *Peptic Ulcer Clinical Aspects, Diagnosis, Management* Philadelphia, W B Saunders Company 1951, pp 185 195

Constitutional factors may also be important, as the disease frequently affects several members of the same family An increased incidence has been observed in portal hypertension, long-standing biliary obstruction, burns, intracranial disease and moribund states

Peptic ulceration occurs generally in non acid-secreting mucosa adjacent to the parietal cell mass This is true of antral ulcers, most lesser curvature gastric ulcers, ulcers around the cardia and lower esophagus, ulcers associated with Meckel s diverticula, stomal ulcers, and duodenal ulcers The conclusion that acid pepsin juice is responsible for ulceration seems apparent Although it is axiomatic that acid pepsin juice is essential for ulcer production, other largely unknown factors determine the site of discrete ulcer mucosal susceptibility at a given time, and spontaneous ulcer healing when it occurs

The work of Dragstedt has given much support to the view that duodenal ulcer and gastric ulcer are pathogenetically different entities The danger of carcinoma in association with gastric ulcer provides a second important reason for differentiating between the two lesions and considering them in separate chapters in this book

## Gastric Hypersecretion and Duodenal Ulcer

Dragstedt s work has shown that patients with duodenal ulcer secrete a greater volume of gastric juice of higher acid content than normal These measurements have been made under fasting conditions, during the night, the subject being shielded from environmental stimuli to assure a basal state The twelve hour nocturnal secretion of hydrochloric acid is three to twenty times normal levels in patients with duodenal ulcer, whereas patients with gastric ulcer secrete at normal or subnormal levels The normal level of hydrochloric acid secretion under these conditions is between 5 and 15 mEq Dragstedt has shown that vagotomy either abolishes or reduces to normal levels the nocturnal secretions of patients with duodenal ulcer and that duodenal ulcers will then heal This is in support of the view that duodenal ulcer is caused by overactivity of the neurogenic phase of gastric secretion

Studies in experimental ulcer production have added much to our understanding of the etiology of peptic ulcer that can be profitably correlated with various situations in man This work underscores basic principles that underlie the surgical treatment of the disease

1 Ligation of the pylorus in rats results in peptic ulcer formation Pyloric obstruction in man may be an end stage of chronic active ulcer and usually requires surgical treatment Pyloric obstruction is in itself ulcerogenic Dependent gastroenterostomy which was for many years the mainstay of surgical therapy, will result in healing of the ulcer by affording prompt gastric evacuation and diversion of gastric juice away from the ulcer

Following vagotomy without a complementary emptying procedure a high incidence of duodenal ulcer reactivation has been reported as well as the development of gastric ulcer It has been noted by both Harkins and Dragstedt that following vagotomy in dogs prepared with Heidenhain pouches the total acid secretion of these pouches increases The vagotomized stomach is at least in some cases functionally obstructed so that gastric phase secretion is accentuated Consequently, if vagotomy is performed in the treatment of duodenal ulcer gastroenterostomy or pyloroplasty must also be done

2 The classical experimental ulcer of Mann and Williamson, which can be regularly produced in dogs by diversion of the duodenal secretions to the lower ileum and re establishment of gastrointestinal continuity by gastroenterostomy, has in some degree a counterpart in man The marginal ulcer that forms is similar to the ulcer that can be anticipated if an enteroenterostomy is made below a gastroenterostomy for the relief of afferent loop stasis. This situation is ulcerogenic be

and mechanical factors have been implicated as governing the gastroduodenal mechanism of gastric evacuation The antral musculature, pyloric sphincter, and duodenal bulb have a coordinated function during gastric evacuation Smooth peristaltic waves pass through the antrum producing a positive pressure gradient carrying the chyme through a relaxed pyloric sphincter into the receptive, dilated duodenum

As a result of controlled gastric evacuation the digestive processes are orderly There is no overloading, optimal stimulation for the flow of pancreatic juice and bile is afforded, glucose absorption rate is controlled, and the small bowel is protected from overdistention and irritation that cause hypermotility and a variety of poorly understood disturbances

The normal emptying time varies with the composition of the food and may require five or more hours for fatty meals

## Secretory Function

Hydrochloric acid is secreted by the parietal cells of the gastric glands The maximal concentration of parietal cells is found in the body of the stomach To a lesser degree they are present in the fundus Practically none are present in the pyloric glands of the antrum The precise location of the pyloric zone cannot be determined grossly There is variation in extent along the lesser curvature of the stomach and there is a variable intermediary zone in the parietal cell content of the glands between the antrum and the body of the stomach

The pH of parietal cell secretion is constant and in the pure state is an isosmotic solution containing 166 mEq per liter of chloride ion, 159 mEq per liter of hydrogen ion, and 7 mEq per liter of potassium ion with a pH of 0 83 Operative procedures are effective in altering the pH of the gastric juice only as they alter the complex of factors that influence the stimulatory inhibitory balance of hydrochloric acid secretion and the various factors that contribute to acid neutralization

Measurement of hydrochloric acid secretion under various conditions has been used widely in clinical and experimental work

Simple measurement of the fasting secretion for free acid is satisfactory for diagnostic work and is a measure of physiologic secretion under basal neurogenic stimulation The results are similar to those obtained by collecting the nocturnal secretions, which is generally impractical Histamine stimulation is useful particularly in patients with achlorhydria in the fasting specimen to prove the presence of true achlorhydria, which would tend to rule out peptic ulcer as a diagnosis The insulin test, or Hollander test, is useful in demonstrating the completeness of vagotomy Vagal stimulation results from induced hypoglycemia which should be determined by blood analyses A blood sugar drop to 50 mg per cent is required for adequate stimulation The Hollander test is particularly useful in evaluating patients with marginal ulcer who have had prior vagotomy

Pepsin is produced in the presence of an acid medium from pepsinogen, which is secreted by the chief cells of the gastric glands Pepsinogen is stable in alkaline solutions and may be detected in both the blood and urine Elevated pepsinogen levels have been noted in patients with duodenal ulcer Pepsin activity is considered essential for ulcer production, as is implied by the term peptic ulcer It is believed that, if the pH of gastric juice is maintained above four, adequate protection is afforded against ulcer formation, although it is clear that at least a degree of peptic activity would still be present Optimal activity develops at about pH 2 Peptic digestion hydrolyzes the protein molecule into proteoses and peptones These substances are important in secretory stimulation during the intestinal phase of digestion and in promoting pancreatic flow

Mucus is secreted from specialized cells throughout the gastrointestinal tract and is the predominant secretion of the pyloric antrum and of Brunner's glands, which are found throughout the duodenum and

to provide a gastric reservoir, but it is clear that most patients do very well with small stomach pouches and some even after total gastrectomy Regardless of the degree of resection, the antrum and pylorus and the control of gastric emptying are lost.

ALTERED SMALL BOWEL FUNCTION Wells and Welbourn and Glazebrook and Welbourn have shown that small bowel hypermotility, elicited by hypertonic solutions of protein hydrolysates and carbohydrates and jejunal distention, is a consistent finding in the postgastrectomy patient These stimuli may be used to produce symptoms experimentally in patients with the efferent loop syndrome (dumping syndrome) Characteristic symptoms of tachycardia, increased blood pressure, sweating, weakness, and desire to lie down ten to twenty minutes after eating may be present

DEFICIENCY STATES Increased fecal fat content is frequent after subtotal gastrectomy Shingleton has shown through isotope studies that there is a defect in fat hydrolysis rather than fatty acid absorption Pancreatic deficiency may be due to loss of secretory stimulation from both altered vagal innervation and duodenal function Change in biliary flow may also be involved Whether gastroduodenostomy providing normal continuity is less likely to be followed by untoward symptoms than gastrojejunostomy has not been clearly determined Protein digestion and absorption appear relatively normal after gastric resection

ACHLORHYDRIA The ulcer diathesis is well controlled if achlorhydria has been obtained, but secondary disadvantages may be related to loss in sterility in the upper gastrointestinal tract Impaired iron absorption with iron deficiency anemia and megaloblastic anemia rarely occur after subtotal gastric resection, though the patient who has had total gastrectomy must have appropriate therapy to prevent these complications

ALKALINE REGURGITATION There is clinical evidence to suggest that gastritis may develop from regurgitation of duodenal content and be productive of symptoms similar to those of marginal ulcer

## PATHOLOGY OF DUODENAL ULCER

Acute ulceration of the duodenum is rarely seen by the surgeon except in conjunction with an occasional case manifesting acute massive hemorrhage or perforation The acute bleeding ulcer may be superficial, free from scar formation, and impossible to detect grossly at the operating table Acute ulcerations are frequently multiple both in the duodenum and in the stomach Such diffuse ulceration is not an uncommon occurrence in moribund patients

Chronic duodenal ulcers are usually single and occur within 1 to 2 cm of the pylorus within the duodenal bulb on the anterior or posterior wall In about 5 per cent of instances the ulcer is postbulbar and may occur in the retroperitoneal portions of the duodenum where its detection is difficult

The gross findings at laparotomy will, of course, vary from case to case It is common, when operating on a patient during a more or less quiescent interval, to find little more than an area of slight thickening distal to the pylorus with a small stellate scar and perhaps some narrowing of the bulb More active cases are characterized by a far-advanced chronic process in which there are dense adhesions to local structures, contraction of the duodenal bulb with obvious deformity and, in some cases, a palpable ulcer crater Acute inflammation with edema and induration in the lesser sac, pancreas, and adjacent omental tissues makes dissection difficult In the dissection of a posterior wall ulcer the crater may be entered, and special care in closure of the duodenal stump is essential It is the posterior wall duodenal ulcer penetrating the pancreas that presents the greatest hazard in massive bleeding The gastroduodenal artery may be eroded and the ulcer bed may be indurated and friable

tive morbidity and mortality should be minimal A 75 per cent subtotal gastrectomy with gastroenterostomy including all the distal stomach and an adequate cuff of duodenum is the operation of choice Properly performed, difficulties with the duodenal stump and gastroenterostomy stoma are rarely encountered and this operation offers maximal protection against the development of stomal ulceration The mortality rate in a consecutive series of elderly patients treated by gastric resection in our clinic was 1 62 per cent

PERFORATION Although perforation may be the first manifestation of peptic ulcer, in about 90 per cent of cases it is a catastrophic event in the course of a severe form of the ulcer diathesis About one third of patients give a prior history of gastrointestinal bleeding In most cases there is a history of acute ulcer exacerbation over a period of a week or two prior to perforation Occasionally an acute ulcer may develop and go on to perforation without prior warning

Perforated ulcer accounts for 10 to 20 per cent of hospital admissions for peptic ulcer The lesion is so common and generally presents in such characteristic form that the correct diagnosis is suspected immediately The onset of perforation is punctuated by the sudden development of severe abdominal pain and the rapid development of generalized spasm with resultant splinting of the abdomen The boardlike rigidity that accompanies perforated ulcer is rarely seen to such a degree in peritonitis of other cause Being mindful of pathological features previously outlined, however, one must be prepared to suspect and look for evidence of perforation in less typical cases where abdominal signs are less dramatic It is clear that in some instances perforation may be rapidly walled off, the true nature of the process not being discovered for several weeks when the patient presents with a subdiaphragmatic abscess

Early operation is indicated Adequate time should be taken preoperatively to treat shock and assure adequate hydration Occasionally a patient presents evidence of having had perforation several days previously and creates a challenging problem in surgical judgment Usually after proper general treatment laparotomy will be indicated in such a patient In the majority of cases the patient should be operated on a few hours after admission and closure accomplished Although it has been shown that gastric resection can be performed as a definitive operation for perforated ulcer in selected cases with low mortality, we do not favor the general use of this plan On a priori grounds morbidity and mortality rate would almost certainly be higher than after simple closure

It has been shown by Turner and others, and this is consistent with our own experience that many patients having survived perforation following closure continue to manifest ulcer symptoms Re perforation, pyloric obstruction, and massive bleeding are frequent and less than 25 per cent of patients may be expected to do well on medical management For this reason, a definitive operation planned to cure the ulcer diathesis should be done in most cases following successful management of the perforation

HEMORRHAGE Massive hemorrhage is a grave complication of gastroduodenal ulcer Any patient having tarry or grossly bloody stools should be suspected of having a bleeding duodenal ulcer Massive hemorrhage from peptic ulceration is unheralded by significant history of ulcer disease in 20 per cent to 25 per cent of cases Differential diagnosis includes particularly portal hypertension and esophageal varices Search for the physical signs of cirrhosis and portal hypertension, such as hepatomegaly, splenomegaly, cutaneous spiders, ascites, and pedal edema and enlarged veins of the abdominal wall is in order X rays of the esophagus and the diagnostic use of the Sengstaken tube should be employed as well as laboratory tests of liver function when indicated The presence of cirrhosis and gastroesophageal varices, however, does not eliminate the possibility that bleeding is from peptic ulcer Tumors of the stomach and

may occasionally be done in the poor-risk patient.

MARGINAL ULCER The development of peptic ulceration at the gastroenterostomy stoma may occur as an occasional early or late complication after surgical treatment for peptic ulcer, particularly duodenal ulcer The diagnosis of marginal ulcer is difficult Pain, usually to the left in the epigastric region and bleeding are the most common symptoms Massive hemorrhage is not unusual Marginal ulcer may develop in a period of months following what we consider adequate gastric resection or its appearance may be delayed for many years Roentgenologic studies are notoriously unreliable both in failing to show the ulcer and in presenting false positive findings All these factors, and especially the necessity for prolonged follow-up, make it difficult to compile accurate statistics on the incidence of stomal ulcer

The occurrence of marginal ulcer is much lower after operation for gastric ulcer than after operation for duodenal ulcer This is further evidence suggesting a difference in the etiology of gastric and duodenal peptic ulcer In addition it is for this reason that we feel that subtotal gastrectomy should be more radical in the treatment of duodenal ulcer including at least 75 per cent of the stomach We anticipate a 3 per cent to 5 per cent incidence of marginal ulcer following this operation Following gastroenterostomy alone, the incidence of marginal ulcer has been reported as from 15 to 35 per cent Following vagotomy and gastroenterostomy, the incidence of marginal ulcer has steadily risen as follow up studies have become more complete and of longer duration Walters has reported an incidence of either duodenal ulcer reactivation or marginal ulcer in 14 per cent of cases followed The combination of hemigastrectomy and vagotomy with Billroth I or II type of anastomosis is under extensive trial at the present time Whether this combination of procedures will reduce the incidence of recurrent ulceration cannot yet be stated

Marginal ulcer is notoriously refractory to medical management and it is generally conceded that the treatment is surgical The following fundamenal objectives must be accomplished in the primary treatment of marginal ulcer

1 If a gastroenterostomy or inadequate gastric resection had been previously done, a 75 to 80 per cent gastric resection should be done

2 No antral mucosa should remain in the duodenal stump

3 Enteroenterostomies should be taken down

4 A gastrojejunostomy that empties readily and produces no afferent limb obstruction should be created

5 If gastric resection has been adequate as determined by laparotomy, infradiaphragmatic vagotomy should be added

6 The pancreas should be examined for the presence of grossly detectable islet-cell tumor

7 Recurrence or persistence of marginal ulceration is not unknown In the rare case refractory to medical as well as previous surgical therapy, total gastrectomy will be indicated

GASTROJEJUNOCOLIC FISTULA The formation of a gastrojejunocolic fistula produces a derangement that will lead to death if not successfully treated Although these lesions may be produced by neoplasm, marginal ulcer is the most common cause, duodenal ulcer is uniformly the pre existing lesion Marginal ulcers may be expected to penetrate into the colon and give rise to gastrojejunocolic fistulas in about 10 per cent of cases so that the lesion is not rare and should be looked for

Pfeiffer's observations and conclusions have clarified the pathophysiology of these lesions and established the basic principle upon which successful management is accomplished Rather than by diversion of gastric and jejunal contents into the colon the reverse occurs, colonic contents being diverted into the stomach

and jejunum with the development of marked gastroenteritis and small bowel hypermotility

The recent study of Marshall and Knud-Hansen provides a comprehensive evaluation of this problem. Diarrhea, all cases, but the fluoroscopist should be alerted to the possible diagnosis. Gastrointestinal series frequently is not diagnostic because flow is not from stomach to colon. Preoperative evaluation should be done quickly, ruling out neoplasm of the

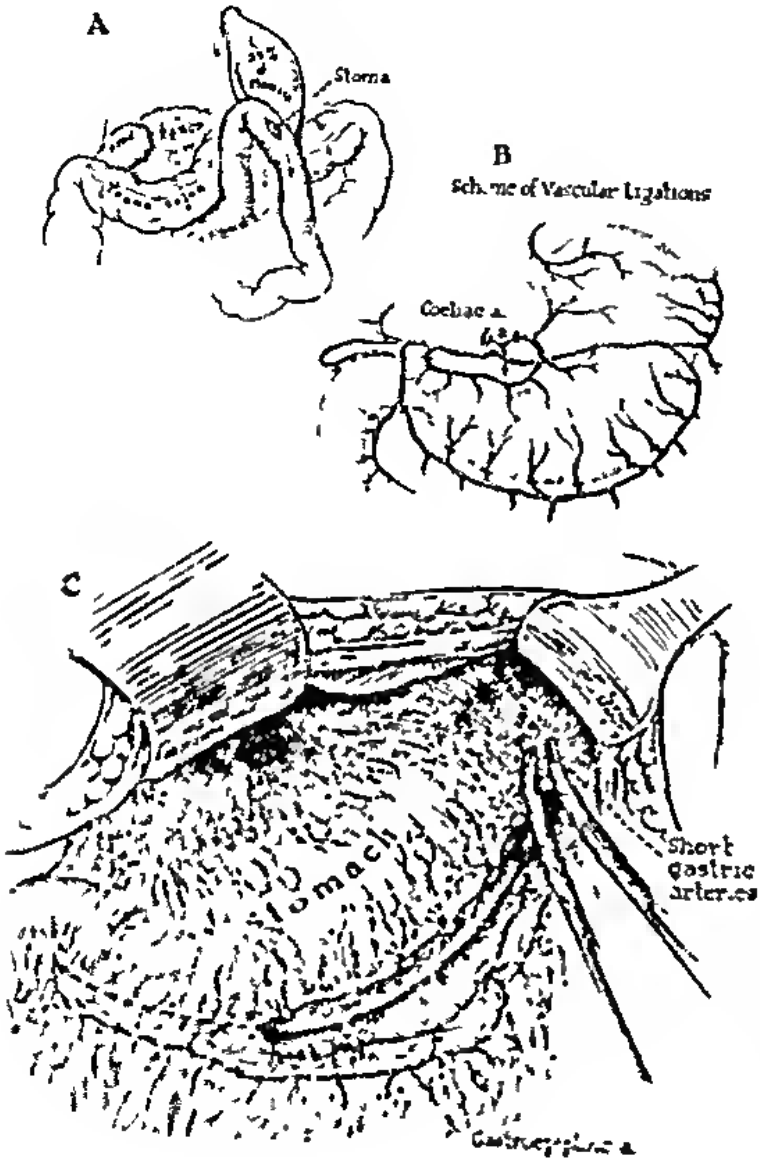


Fig 9-1. Subtotal gastrectomy (A) The usual relationships of the completed gastroenterostomy stoma (B) Scheme of the vascular ligations. (C) Division of the short gastric arteries. Extension of the dissection high on the greater curvature of the stomach greatly facilitates mobilization and exposure for the subsequent steps of the operation.

*benefit in restoring the condition of the* depleted patient Subsequently, after a period of several months affording maximal recovery, an adequate gastric resection with resection of the jejunal and colic components of the fistula is carried out If ileosigmoidostomy is performed initially, it may be advisable to excise the right and transverse colon along with the stomach and fistula at the second operation

In better risk patients who have responded well to supportive measures a one stage procedure is preferred Since this type of operation was associated with *high mortality in the past it must be* recognized that its successful application today demands proper use of all measures characterizing good preoperative and postoperative care ideal anesthesia and surgical technique It is probably fair to say that the one stage definitive operation is gaining more proponents with the advance of surgery

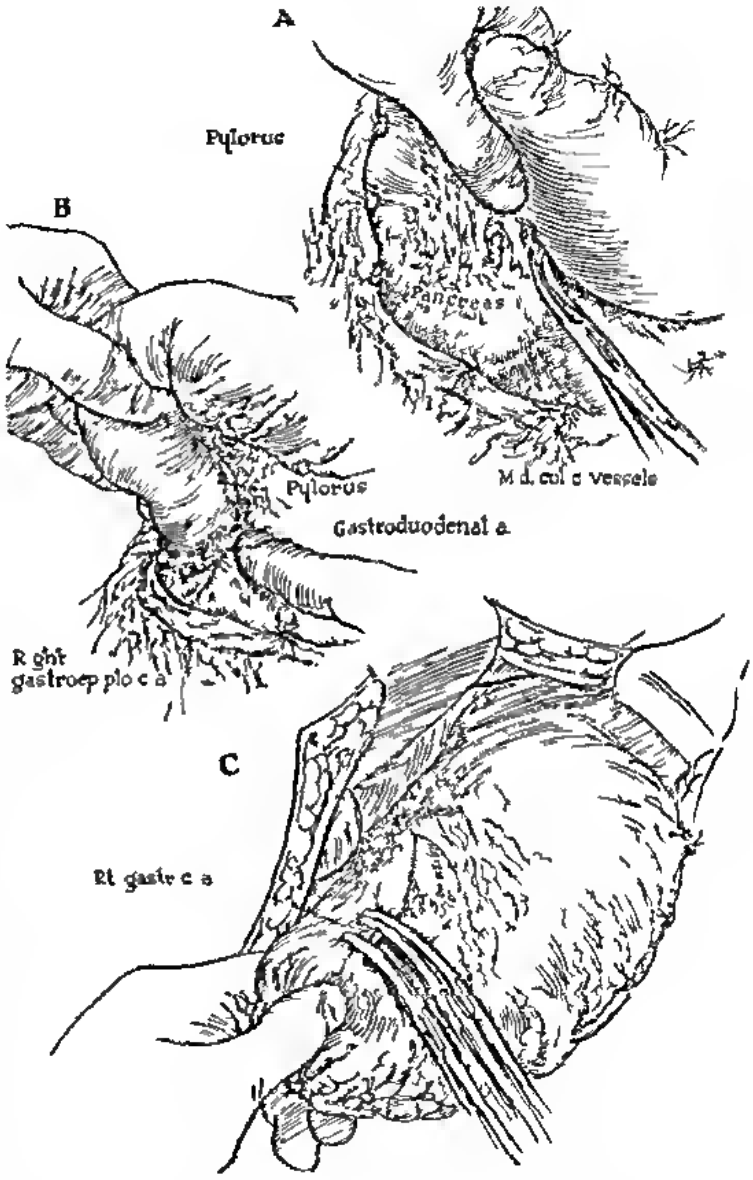


Fig 9 2 Subtotal gastrectomy (*A*) Dissection of adhesions in the lesser omental bursa These adhesions are avascular and when divided completely facilitate retraction of the cardia and fundus inferiorly so that an adequate resection can be done safely (*B*) The duodenal bulb has been freed up on its posterior aspect The gastroduodenal artery is identified (*C*) Dissection of the superior aspect of the duodenal bulb with ligation of the right gastric artery

## SUBTOTAL GASTRIC RESECTION TECHNIQUE

A resection of at least 75 per cent of the distal stomach is required to achieve

freeing the stomach, exposing and protecting the pancreas from injury, and bringing the stomach well down so that the full extent of the fundic portion is visualized and the left gastric vessels identified (Fig 9 2*A*) The middle colic vessels and the transverse mesocolon are protected from injury

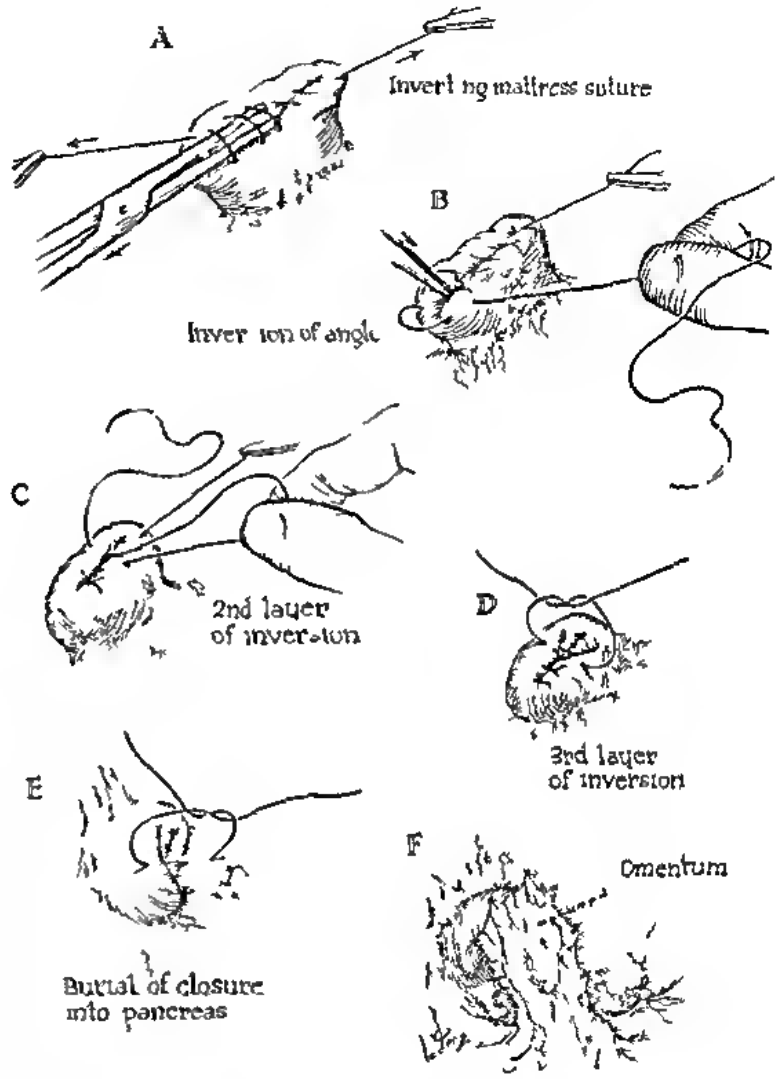


Fig 9 4 Closure of the duodenal stump (*A*) Running inverted mattress suture (*B*) Inversion of the angle (*C*) Second layer of inversion (*D*) Third layer of inversion (*E*) The suture line is turned over onto the capsule of the pancreas (*F*) Omental fat is sutured over the completed stump closure

## Dissection of the Duodenum

As the dissection is carried along the greater curvature beyond the pylorus, the visceral peritoneum is incised along the anteroinferior aspect of the bulb, and the distal stomach and bulb are retracted upward so that the posteroinferior dissection of the bulb may be completed Fine pointed hemostats are used and the dissection is carried out with great care as one wishes to avoid injury to the gastroduodenal artery (Fig 9 2*B*) The duodenum may often be more satisfactorily mobilized if the right gastroepiploic artery is divided near its origin in this area After freeing up to 3 to 4 cm of duodenum beyond the pylorus, the stomach is retracted downward and with the hand in the lesser sac a large rent is made in an avascular portion of the lesser omentum and the right gastric artery is easily clamped and divided as it rises to the lesser curvature near the pylorus (Fig 9 2*C*) The peritoneum along the anterosuperior aspect of the duodenal bulb is incised and the duodenal stump dissec

tion completed by dividing the fine branches of the supraduodenal artery (Fig 9 3A)

In difficult cases where there is a large posterior wall ulcer penetrating the pancreas it may not be safe to free up as much duodenum or as the dissection pro- been entered, a satisfactory closure is obtained by freeing up the duodenal wall distal to the crater for closure, followed by inversion of the duodenal stump into the pancreas over the ulcer bed Great care must be taken in this most difficult of surgical tasks to secure mucosal ap-

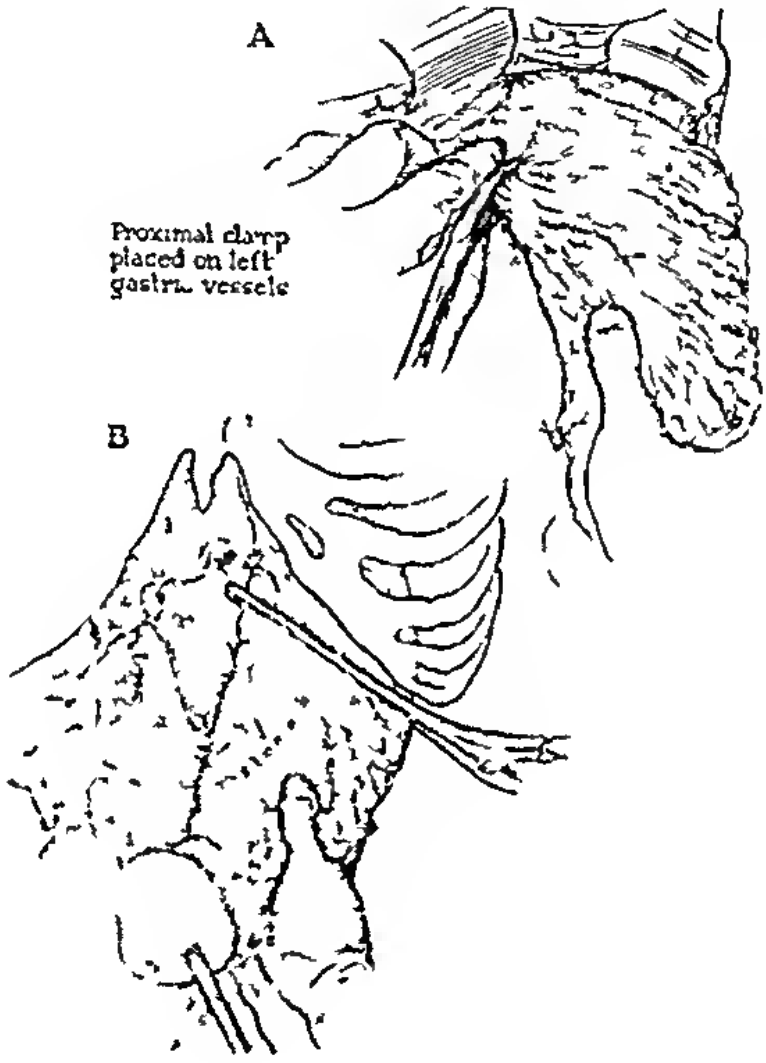

cut end of the stomach A continuous No 00 chromic inverting mattress suture is placed across the duodenal clamp and as the clamp is removed the suture is drawn taught During this step suction is at hand and pads are placed around the stump to guard against spillage which is largely avoided by the skill of the operator The inferior angle is inverted (Fig 9 4*B C*) and the suture returned as a serosal layer The superior angle is inverted in a similar manner and the suture tied The third layer consists of interrupted No 000 nonabsorbable sutures (Fig 9 4*D*) The suture line is then inverted into the pancreas and covered with an omental graft (Fig 9 4*E, F*)

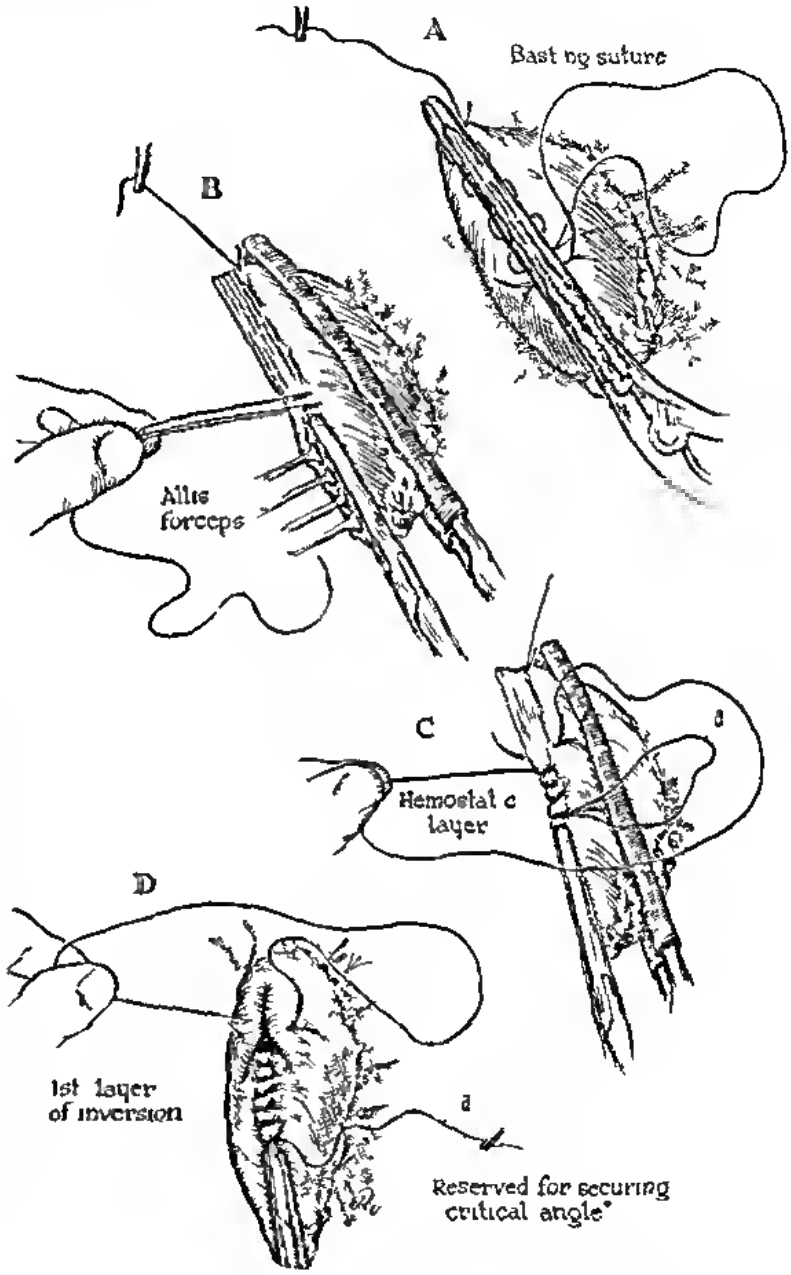


Fig 9 6 Closure of the lesser curvature side of the gastric stoma (*A*) Basting suture This suture prevents retraction of the inner layers when the Payr clamp is removed thereby assuring the adequacy of the hemostatic suture to follow (*B*) The stoma is held in Allis forceps while the Payr clamp is removed and an appropriate clamp is applied to the narrowed gastric stoma (*C*) The end of the basting suture is returned as an over and over running hemostatic suture and tied at the lesser curvature (*D*) The inverting seromuscular layer which is subsequently reinforced by interrupted silk sutures

**Ligation of the Left Gastric Artery and Completion of the Resection**

By retraction of the stomach inferiorly the left gastric vessels may be grasped by the left hand as they passed from the celiac axis to the lesser curvature The vessels are triply clamped divided, and

doubly ligated in this interval with No 3 silk (Fig 9 5*A*) The stomach is now ready for proximal division The highest segmental vein on the lesser curvature has served as a useful landmark in most cases for the level of resection With the stomach retracted inferiorly and the 00 chromic is placed (Fig 9 6*A*), and after application of four Allis clamps to the narrowed stoma the Payr clamp is removed and a straight duodenal clamp applied (Fig 9 6*B*) The excess of crushed gastric wall at the stoma is cut away (Fig 9 6*C*) The basting suture

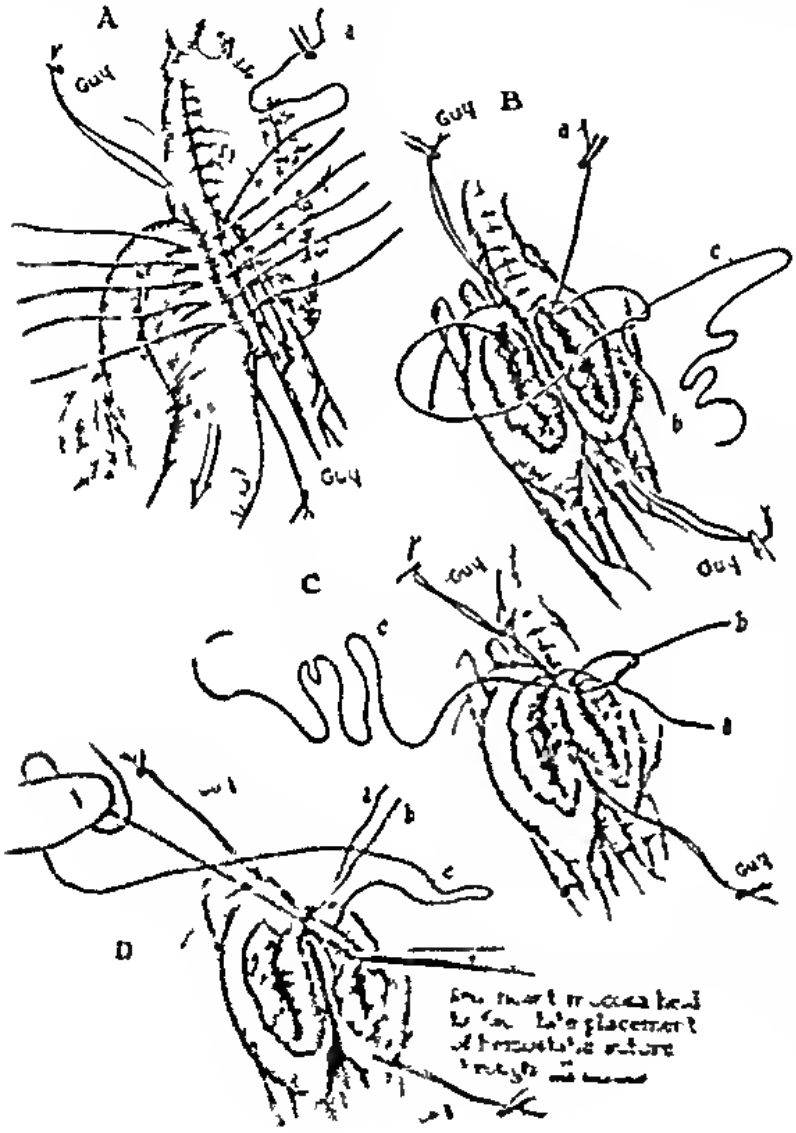


Fig 9 7 Suture technique of the gastroenterostomy (*A*) The posterior seromuscular layer of interrupted sutures (*B*) The beginning of the mucosal closure This continuous over and over suture must include all layers of the gastric and jejunal walls (*C*) The free end of the mucosa uniting suture at the reconstituted lesser curvature (suture *a*) is united with the mucosal suture (suture *b*) of the gastroenterostomy This serves to avoid leakage at the lesser curvature angle of the anastomosis (*D*) The continuous over and over horizontal suture must be carefully placed, and it should be held with adequate tension to prevent suture bleeding

ture closure is now inverted by a second layer of running chromic and reinforced with interrupted silks (Fig 9-6*D*) The jejunal loop is now brought up in front of the transverse colon and the short afferent limb is oriented to the lesser curvature side of the gastric stoma by placing Guy sutures at either end of the stoma (Fig 9 7*A*) If any tension is present it is usually due to shortness of the jejunal mesentery This is to be avoided and on occasion splitting of the greater omentum or freeing up the ligament of Treitz may be advisable The posterior row of interrupted silk sutures is placed close to the mesenteric edge of the jejunum as almost half of the jejunal circumference will be required for the anastomosis Rubber shod clamps are applied to prevent spillage and maintain hemostasis (Fig 9 7*B*) and the jejunum is opened The hemostatic mucosal suture is started and continued to the greater curvature side, being careful to include all layers of both stomach and jejunal walls This is a point of greatest technical importance as hemostasis is dependent upon including submucosal vessels, which tend to retract on the stomach side (Fig 9 7*C,D*) The suture is locked or tied at the greater curvature side and then continued as an over and over suture to approximate the mucosa and all layers anteriorly The rubber shod clamps are removed when the anterior mucosal layer is half completed and careful inspection is made to insure that hemostasis is complete (Fig 9-8*A*) All mucosal sutures are united at the lesser curvature angle by being tied to one another The anterior mucosal layer is next inverted with a running chromic suture (Fig 9 8*B*), and

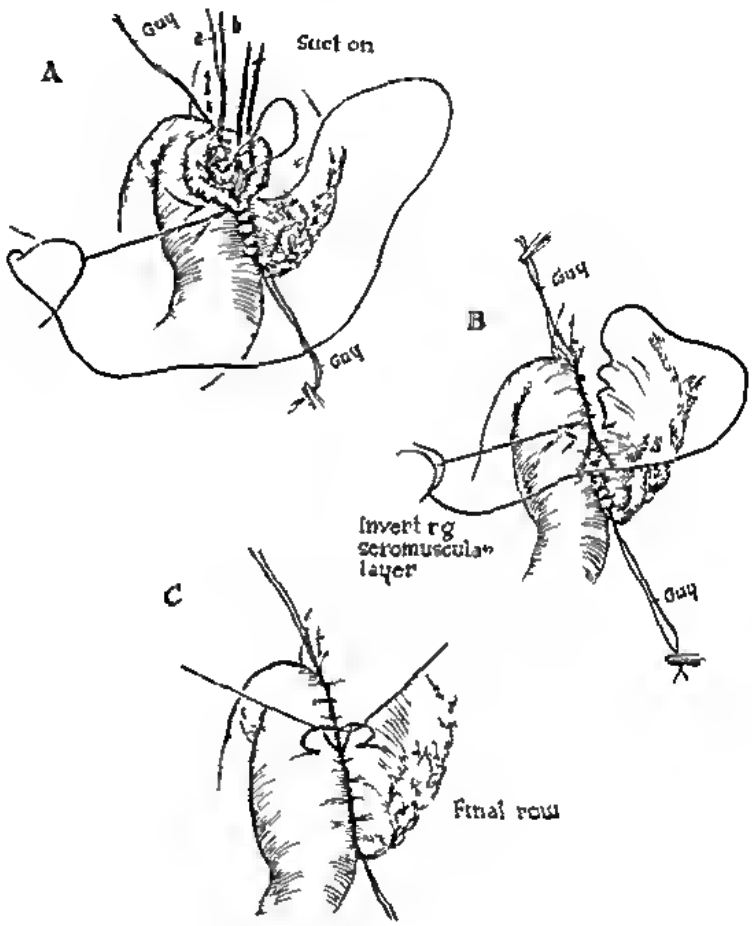


Fig 9 8 Suture technique of the gastroenterostomy (*A*) The mucosal suture is continued along the anterior surface of the anastomosis after having been tied at the greater curvature Note that the rubber shod clamps are removed at this point The fundic pouch and posterior suture line are inspected and peritoneal soiling is carefully avoided (*B*) Anterior inverting seromuscular layer (*C*) Final anterior row of interrupted sutures

reinforced with interrupted silks (Fig 9 8C) The completed anastomosis is examined circumferentially and the lumen tested between the fingers for size and patency

## SUBTOTAL GASTRECTOMY WITH GASTRODUODENOSTOMY

The re establishment of gastrointestinal continuity following gastric resection for duodenal ulcer by gastroduodenostomy is rarely employed in this clinic for the

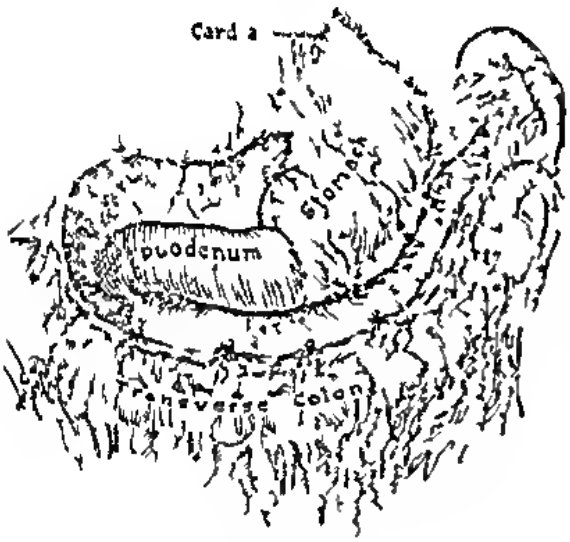


Fig 9 9 Gastroduodenostomy Refer to text

treatment of duodenal ulcer Numerous methods of performing this anastomosis have been proposed and have had extensive trial Advantages have been claimed for the procedure on theoretical grounds and by its elimination of the duodenal stump and its attendant complications Some believe that the incidence of postprandial symptoms is less

The operation requires extensive mobilization of the duodenum if satisfactory gastric resection and anastomosis are to be obtained without tension In the presence of duodenal pathology this may be hazardous

We favor an anastomosis in which the lesser curvature side is closed so that the gastric stoma is equal in size to the duodenal lumen This affords optimal dependent drainage to the gastric pouch (Fig 9-9)

## CLOSURE OF PERFORATED GASTRODUODENAL ULCER

Favoring early operation the peritoneal cavity may be evacuated of gastric spillage and the perforation closed by methods that have become standardized The procedure is usually done under general anesthesia but can be done by regional intercostal nerve block and local administration of procaine in poor risk patients

Where possible, transverse closure of the opening is preferred using a few interrupted chromic sutures followed by application of an omental graft that is sutured over the closure avoiding strangulation of its blood supply (Fig 9 10*A,B*)

When the opening is large and the gastroduodenal wall friable, an omental tab is used for obturation of the defect and is incorporated in the sutures that are placed across the perforation The sutures are tied carefully so that they do not cut through Although this method has been used widely with good results, we have observed reperforation in a few instances that have been attributed to incomplete serosal closure with necrosis of the strangulated omental seal (Fig 9 10*C*)

## VAGOTOMY TECHNIQUE

Anatomic studies have shown that the abdominal approach is comparable to the transthoracic in performing complete vagotomy and is the procedure of choice since it offers exposure for exploration and performance of complementary gastroenterostomy or pyloroplasty Vagotomy should not be done without provision for gastric evacuation

A mid line or paramedian incision may

be used The left lobe of the liver is retracted to the right with division of the triangular ligament The cardia is retracted down and the peritoneum overlying the cardioesophageal junction incised

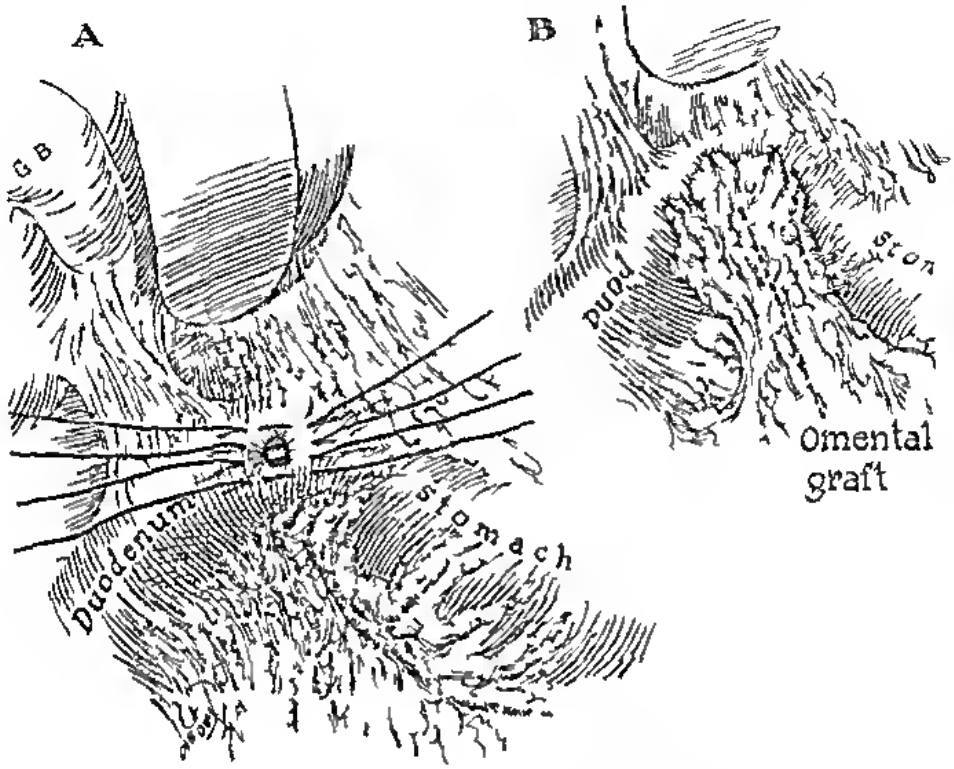


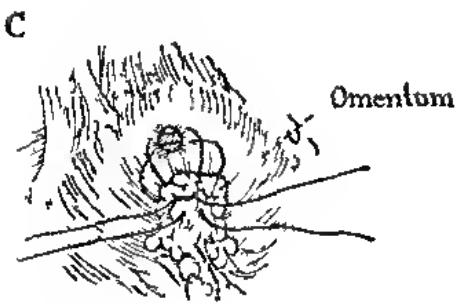


Fig 9 10 Methods of closure of perforated ulcer (*A*) Transverse closure with interrupted seromuscular sutures followed by suture of viable omentum over the closure is preferable if the duodenal wall is not friable (*B*) It is shown here that the omentum is not used for obturation of the perforation but rather as a seal of viable tissue (*C*) Graham closure is based on obturation of the perforation with omental fat, which is strangulated by the sutures that hold it in place This method is particularly useful where the supporting sutures cannot be tightened greatly for fear they will pull through

The esophagus is then easily mobilized with blunt dissection and as it is retracted 4 to 6 cm of terminal esophagus is delivered The anterior vagus is in view The posterior vagus is readily palpated as a tight cord, usually lying in areolar tissue in the right posterior quadrant behind the esophagus (Fig 9 11) The nerves should be freed up and a segment excised Since either nerve may be paired the esophagus should be skeletonized for an interval of 6 cm and search made for additional branches to insure a complete interruption

Bradley found that in 8 per cent of cases the vagal nerves at this level are plexiform and poorly defined, so that complete vagotomy would be difficult or impossible to achieve.

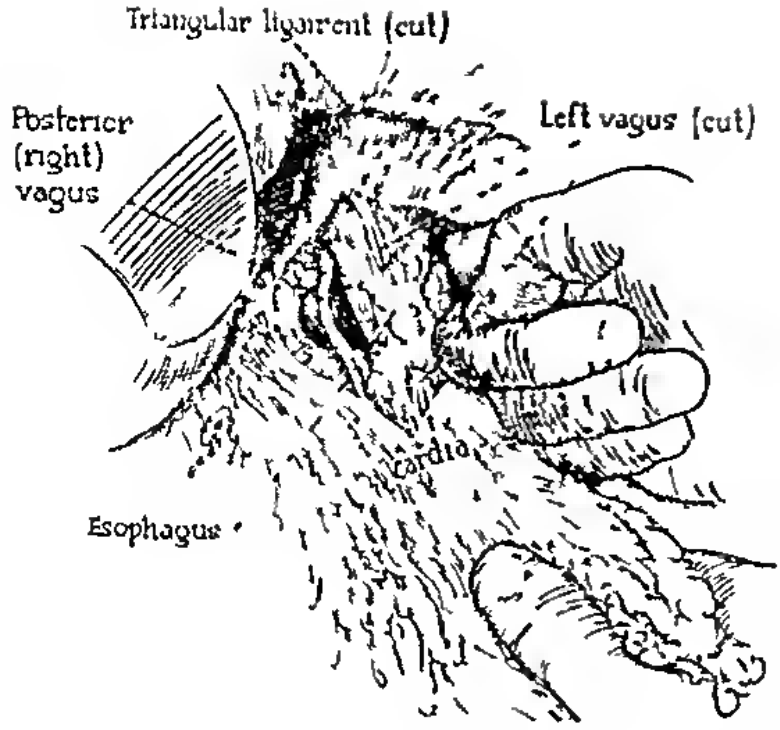


Fig 9 11 Abdominal vagotomy The figure demonstrates the excellent exposure that can be obtained Search for small fibers of the vagus plexus demands adequate mobilization and skeletonization of the terminal esophagus

## GASTROENTEROSTOMY TECHNIQUE

It is our conviction that gastroenterostomy is rarely indicated in the treatment of duodenal ulcer When performed it is used as a complementary emptying procedure in conjunction with vagotomy

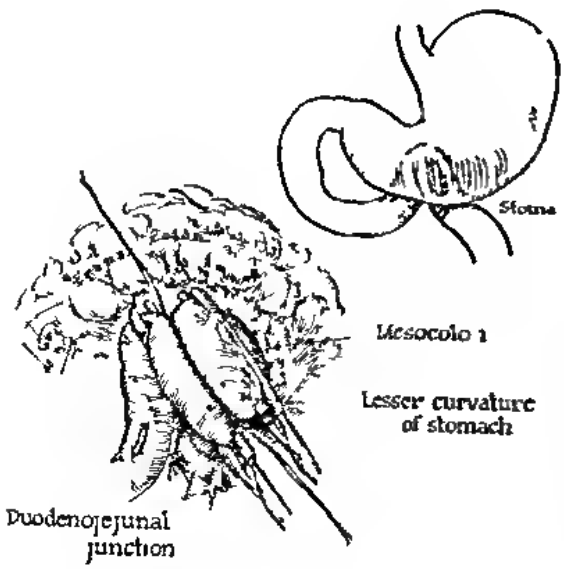


Fig 9 12 Gastroenterostomy Refer to text.

The important features of the operation have been emphasized by Dragstedt and by Crile and consist of the following

1 The stoma should be placed as near to the pylorus as possible
2 Dependent drainage should be provided into the efferent loop the efferent stoma being close to the greater curvature
3 The anastomosis is placed in the retrocolic position

The most important technical consideration is that the posterior wall of the stomach is invaginated through the mesenteric rent and sutured to the mesocolon prior to placement of the posterior row of interrupted sutures bringing enough stomach down so that a rubber shod clamp can be applied to prevent contamination (Fig 9 12) The approximation of the short afferent loop to the stomach is such that there is not undue tension or angulation the end result being comfortable dependent drainage

The technique of the anastomosis is similar to that described previously

## PYLOROPLASTY

Pyloroplasty originally devised as a method of ulcer excision that would over come the problem of secondary stenosis of the pylorus is a poor operation as it does not control the ulcer diathesis In recent years however the procedure has come into use as an emptying procedure in conjunction with vagotomy

Two methods of pyloroplasty are illus trated Longitudinal pylorotomy with transverse closure (Heineke Mikulicz) is readily accomplished without the neces sity of extensive duodenal mobilization The incision need not be carried more than a centimeter beyond the pylorus division of the circular layer of the pyloric musculature and sphincter being the ob jective (Fig 9 13*A,B*)

Pyloroduodenostomy according to the method of Finney produces (Fig 9 13*C*) wide dependent drainage for the stomach The technique is more difficult and re quires adequate mobilization of the duo denum by incising the lateral peritoneum along the second portion

## DIVERTICULUM OF THE DUODENUM

Diverticulum of the duodenum is a common lesion being noted in 10 to 20 per cent of autopsy material and 2 to 5 per cent of x ray examinations Associa tion with diverticulosis in other parts of the gastrointestinal tract is common par ticularly in the colon but also occasionally in the jejunum and esophagus Multiple diverticula may be present in the duo- denum Since these lesions are generally discovered in patients under investigation for other diseases hiatal hernia peptic ulcer and disease in the biliary tract are often associated The lesion is almost always found on the concave inner border of the duodenum and may be anterior or posterior to the pancreas intimately related and often penetrating its sub stance A close relationship of the neck of the sac with the ampulla of Vater is of the greatest surgical significance Most diverticula are found in the descending portion of the duodenum close to this vital structure

The sac is thin walled with a narrow neck Mucosa submucosa and serosa with absence of the muscularis and oc casional presence of gastric mucosa or

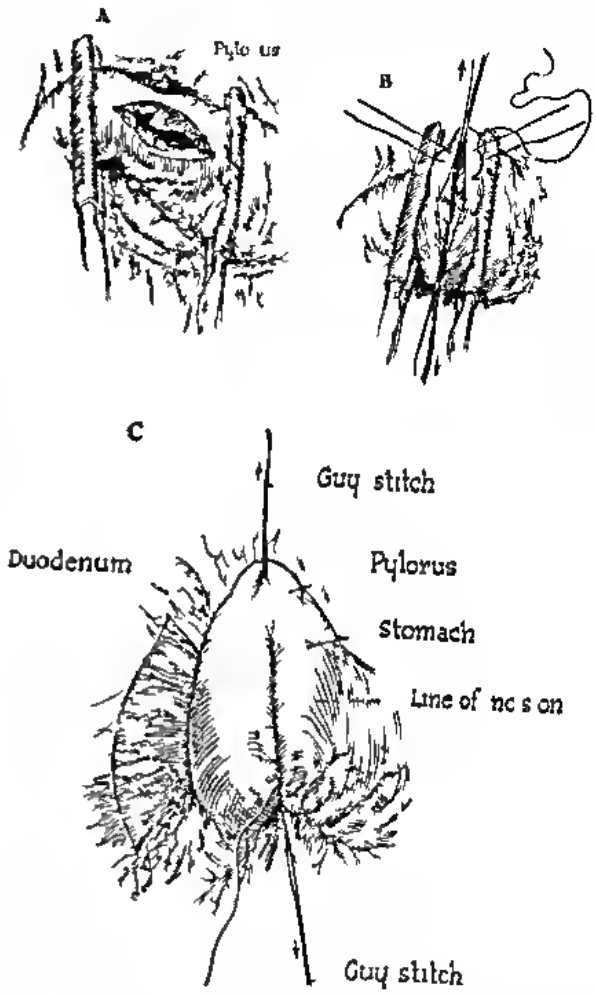


Fig 9 13 Pyloroplasty (*A*) and (*B*) Longitudinal incision with transverse closure (Heineke-Mikulicz) (*C*) Pyloroduodenostomy (Finney)

pancreatic tissue characterize the wall of the sac This is considered a true divertic ulum in contradistinction to pseudo- diverticulum which is commonly seen in the duodenal bulb in association with duodenal ulcer and clover leaf deformity The latter are sacular distortions of the duodenal wall including all its layers

Only after exhaustive search for other

lesions and after a suitable period of nonsurgical treatment should excision of this lesion be considered

The most common disturbance produced by a duodenal diverticulum is stasis, distention, and delayed emptying This may produce sharp localized pain Varying degrees of inflammation and frank peptic ulceration may develop Massive hemorrhage may occur as well as gangrene and perforation in rare instances

## TUMORS OF THE DUODENUM

Excluding invasive carcinoma of the pancreas and ampulla of Vater, which may frequently involve the second portion of the duodenum, tumors of the duodenum are rare lesions The majority of primary duodenal tumors are malignant, adenocarcinoma being the most common, sarcoma being occasionally seen The incidence of primary malignant tumors in autopsy material is less than 0 050 per cent

Over a period of fifty years at the Boston City Hospital (Ebert) only fifteen malignant primary tumors were encountered, three of which were resected

Lesions are classified according to their relation to the ampulla of Vater as supra-ampullary periampullary, and infra ampullary About half are periampullary in location

A wide variety of benign tumors has been reported, adenoma and myoma being the most common

The great rarity of small bowel tumors poses a difficult puzzle in the etiology of neoplasms, neighboring organs, the stomach and colon, being such common sites of tumor formation

Clinical features are easily predicted and consist of pain, indigestion, and anorexia Obstruction, bleeding, perforation with peritonitis, and jaundice may occur

Treatment is dictated by the local findings Benign lesions are treated by local excision Malignant lesions, if favorable, are radically resected or treated by segmental resection or by diverting procedures if metastases have occurred or the lesion is nonresectable

## REFERENCES

Brailey, W F, Small, J T, Wilson, J W, and Wallus, W Anatomic considerations in gastric neurectomy *J A M A 133* 159, 1947

Cattell, R B, and Mudge, F J The surgical significance of duodenal diverticula *New England J Med 246* 317, 1952

Cooley, D A, Jordan, G L, Brockman, H L, and DeBakey, M F Gastrectomy in acute gastroduodenal perforation Analysis of 112 cases *Ann Surg 141* 840, 1955

Crile, G, Jr An analysis of the vagotomy controversy *Ann Surg 136* 752, 1952

Dragstedt, L R, Oberhelman, H A, Jr, and Smith, C A Experimental hyperfunction of the gastric antrum with ulcer formation *Ann Surg 134* 332, 1951

Ebert, R E, Parkhurst, G F, Melendy, O A, and Osborne, M P Primary tumors of duodenum *Surg Gynec & Obst 97* 135, 1953

Edwards, L W The technique of vagus nerve resection *Ann Surg 20* 872, 1944

Edwards, L W, Herrington, J L, Stephenson, S E, Carlson, R I, Phillips, R J, Cate, W R, Jr, and Scott, H W Treatment by vagotomy and removal of the gastric antrum *Ann Surg 145* 738, 1957

Evans, S O, Zubiran, J M, McCarthy, J D, Ragins, H, Woodward, E R and Dragstedt, L R Stimulatory effect of vagotomy on gastric secretion in Heidenhain pouch dogs *Am J Physiol 174* 219 1953

Everson, T C, Hutchings, E J, and Witanowski, M E A comparative evaluation of changes in weight after partial gastrectomy and after vagotomy with gastroenterostomy *Ann Surg 145* 210, 1957

Glazebrook A J, and Welbourn, R B Some observations on the function of the small intestine after gastrectomy *Brit J Surg 40* 111, 1952

Grimson, K S, Rowe C R, and Taylor, H M Results of vagotomy during 7 years Clinical observations and tests of gastric secretions *Ann Surg 135* 621, 1952

Ivy A C, Grossman, M I, and Bachrach, W H *Peptic Ulcer* Philadelphia, The Blakiston Company, 1950

LEVIN, E, KIRSCHNER, J, and PALMER, W L A simple measure of gastric secretion in man Comparison of one hour basal secretion, histamine secretion, and twelve hour nocturnal gastric secretion *Gastroenterology 19* 88, 1951

PFEIFFER, D B, and KENT, E M The value of preliminary colostomy in the correction of gastrojejunocolic fistula *Ann Surg 110* 659, 1939

POTTER, W H, ANDERSEN, M N, and STEWART, J D Gastric surgery in the aged *Geriatrics* 7 173, 1952

QUIGLEY, J P Motor physiology of the stomach, pylorus, and duodenum *Arch Surg 44* 414, 1942

SHINGLETON, W W, ISLEY, J K, FLLOYD, R D, SANDERS, A P, BAYLIN, G J POSTLEWAIT, R W, and RUFFIN, J M Studies on postgastrectomy steatorrhea using radioactive triolein and oleic acid *Surgery 42* 12, 1957

STABINS, S J The aftermath of perforated duodenal ulcer *Surgery 34* 614, 1953

STEWART, J D, COSGRIFF, J H, and GRAY, J G Experiences with the treatment of acutely massively bleeding peptic ulcer by blood replacement and gastric resection *Surg Gynec & Obst 103* 409, 1956

TURNER, F P Acute perforations of stomach, duodenum, and jejunum An analysis of 224 cases with late follow up data on 147 cases of acute perforated peptic ulcer *Surg Gynec & Obst 92* 281, 1954

WADDELL, W R The physiologic significance of retained antral tissue after partial gastrectomy *Ann Surg 143* 520, 1956

WADDELL, W R, and BARTLETT, M K Antral exclusion with vagotomy for duodenal ulcer I Acid secretory studies in 50 patients *Ann Surg 146* 3, 1957

WALTERS, W, and MOBLEY, J E Five ten year follow up of 162 cases of duodenal ulcer treated by vagotomy with and without associated gastric operations *Ann Surg 145* 753, 1957

WELLS, G, and WELBOURN, R Postgastrectomy syndromes—A study in applied physiology *Brit Med J 1* 546, 1951

WOLF, S, and WOLFF, H G *Human Gastric Function* New York, Oxford University Press, 1943

WOODWARD, E R, STORER, E H, OBERHELMAN, H A, and DRAGSTEDT L R Quantitative studies on the mechanism of gastric secretion in health and disease *Ann Surg 132* 626, 1950

ZOLLINGER, R M, and ELLISON, E H Primary peptic ulcerations of the jejunum associated with islet cell tumors of the pancreas *Ann Surg 142* 709, 1955

CHAPTER 10

# DISEASES OF THE LIVER EXCLUSIVE OF THE BILIARY TRACT*

*Charles G. Child, III, and Arthur J. Donovan*

## CONGENITAL MALFORMATIONS OF LIVER, BILE DUCTS, AND HEPATIC VASCULATURE

### Parenchyma

Congenital malformations of the liver are rare and commonly discovered during routine roentgenography of the chest They do not in themselves generally require surgical treatment They may, however, pose important questions in differential diagnosis of shadows lying just above or just below the diaphragm These may not be answered short of exploratory thoracotomy or celiotomy

Heretofore, ectopic liver has been considered congenitally misplaced hepatic tissue, perhaps analogous to the lobulation of this organ encountered in lower animals Recently congenital origin of some hepatic malformations has been questioned by those who emphasize that developing liver is readily molded by its surroundings For instance, according to this theory a congenital defect in the diaphragm may permit protrusion of liver into the lower thorax Two varieties of this abnormality have been reported where the diaphragmatic defect is complete, a mass of liver may actually reside within the chest attached to its parent organ by a pedicle (Fig 10-1), should the diaphragm be intact, although attenuated and weak, a knob of apparently ectopic liver develops in the hepatic dome (Fig 10 2)

Whatever the origin of these unusual masses of hepatic tissue, attention is drawn to them more often by roentgenography than by related symptoms In roentgenograms of the chest, they appear as minor or even sizable irregularities of the diaphragm or discrete tumor masses seeming to lie within the thorax just above the diaphragm When hepatic origin is suspected, pneumoperitoneum followed by roentgenography of the areas above and below the diaphragm may establish the mass as liver More often, however, the nature of the lesion remains in doubt and surgical exploration becomes a matter of diagnostic necessity At operation the diagnosis does not long remain in doubt. If it presents in the thorax,

* This investigation was supported in part by a research grant H 2064(C) from the National Heart Institute U S Public Health Service

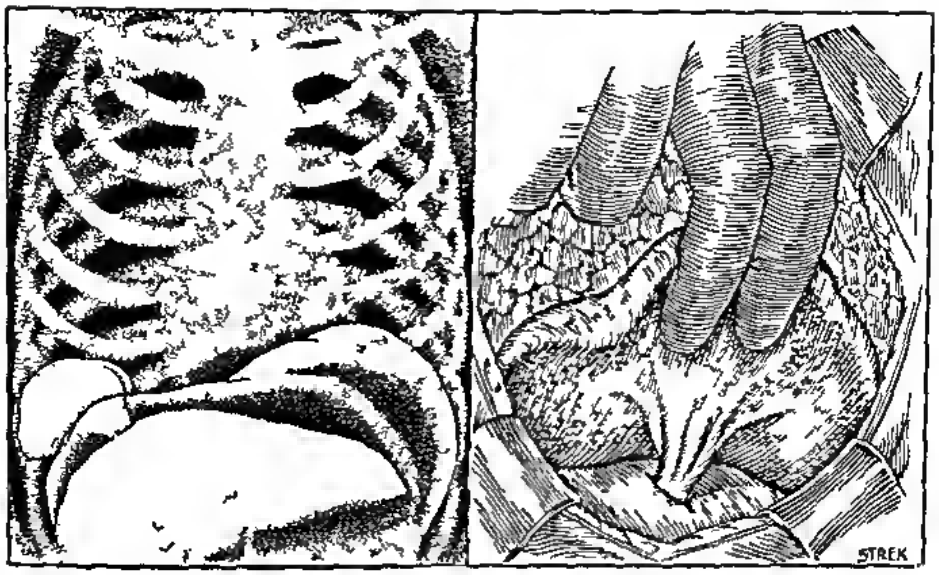


Fig 10 1 Intrathoracic lobe of l ver Th s mass of normal l ver was dis covered upon a roentgenogram of the chest Whether this represents con genital lobulation of the liver or extrus on of normal liver into the chest through a diaphragmatic defect was not determined In any event its hepat c origin was betrayed preoperat vely by a roentgenogram taken after intro ducing air into the peritoneal cavity (*Left*) This mass v as easily removed and the d aphragmat c defect closed (*Right*) (*Redraun by permission after* E T Hansbrough and R J Lip n *Annals of Surgery 145* 564 1957 )

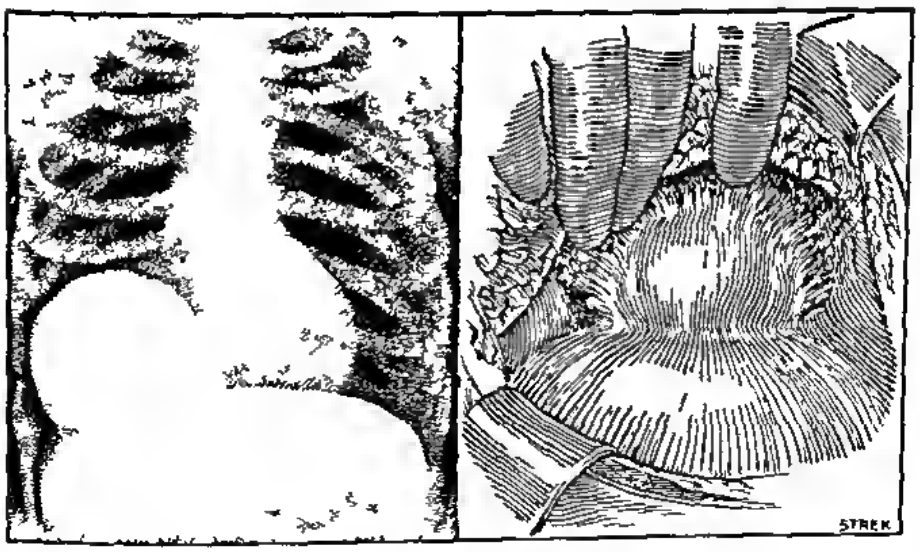


Fig 10-2 Intrathoracic mass of liver This mass of normal liver was d scovered incidentally dur ng the study of a pat ent v ith obscure gastro intest nal compla nts Although the pat ent s history included severe ab- dom nothoracic trauma many years before the time of th s investigat on, decision was never reached v hether th s mass of ectopic l ver was congen tal or traumat c in origin It was removed uneventfully and the defect in the diaphragm closed (*Redraun by permission from* C G Ch ld G S Har mon, C T Dotter and L. Steinberg *J Thoracic Surg 21* 391 1951 )

its hepatic origin is betrayed by a pedicle containing blood vessels and bile ducts When covered by diaphragm, incision through this structure promptly displays its origin from the liver

The treatment of these benign lesions is largely a matter of surgical conviction A knob of normal liver with a broad base should not be disturbed If it is attached by a narrow pedicle that might become twisted it should be removed and the diaphragmatic defect repaired Distorted liver between these two extremes presents problems in surgical judgment without categorical answers

## Bile Ducts

The annals of pediatric surgery are replete with reports of infants whose intrahepatic biliary drainage system is congenitally defective Jaundice is the presenting sign in such infants Hepatic cholangiography or excision of part of the left hepatic territory* serves most expeditiously to discover whether an intrahepatic drainage system exists If ducts are present within the liver, one or two sizable branches should be encountered Intraoperative cholangiography aids materially in defining the extent of biliary atresia Should the defect be outside the liver, a hepatic duct at the hilum large enough for enteric anastomosis may be found (see Chap 13) If within the liver biliary enteric continuity can sometimes be established between an intrahepatic duct presenting on the cut surface of the left hepatic territory and a loop of jejunum (Fig 10 3) This technique has been described by Longmire Surgical measures for relief of total failure of development of the intrahepatic biliary drainage system have not been devised

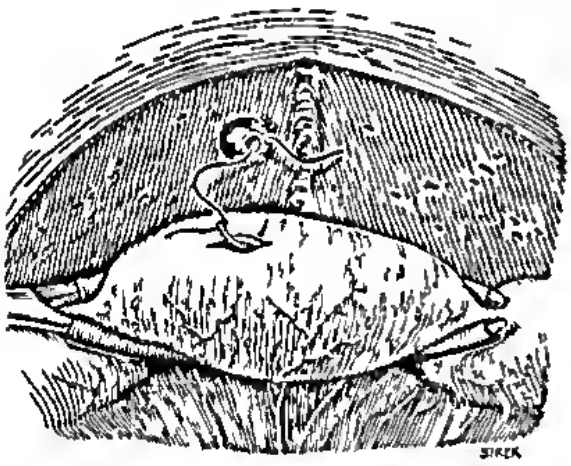

Fig 10 3 Intrahepatic cholangiojejunostomy In the course of resecting a sizable portion of the left hepatic territory, a dilated intrahepatic bile duct may be delineated sufficiently to permit an anastomosis between it and a loop of jejunum This need not necessarily drain the entire liver for it is well known that even a relatively small portion of functioning liver can clear the blood stream of bilirubin (*Redrawn by permission from* W P Longmire Jr, and M C Sanford *Surgery* 24 264 1948 )

## Congenital Cysts of the Liver

This unusual anomaly of the liver is generally regarded as a segmental failure in development of bile ducts There may be congenital stricture or complete obstruction of biliary drainage of one or more hepatic segments In either event cysts of the liver develop Congenital cysts are often associated with cystic disease of other organs such as the kidneys lungs spleen, and pancreas Hepatic cysts are generally asymptomatic and discovered only by the appearance of a slowly en

* Throughout this chapter the right and left portions of the liver are designated territories not lobes This terminology is in accord with studies of intrahepatic anatomy made by Mc Indoe and Counseller Hjortsjo Elias and Petty and many others These investigators have clearly shown that the fundamental division between the right and left portions of the liver is in a plane passing through the long axis of the gallbladder to the middle of the vena cava rather than in a plane marked by the falciform and round ligaments Although the concept of right and left lobes separated by these ligaments is topographically acceptable it is anatomically misleading as far as intrahepatic blood vessels and ducts are concerned The terms right and left hepatic territories originally introduced by Hjortsjo are used here to reflect facts of anatomical and surgical importance (see Surgical Anatomy of the Liver)

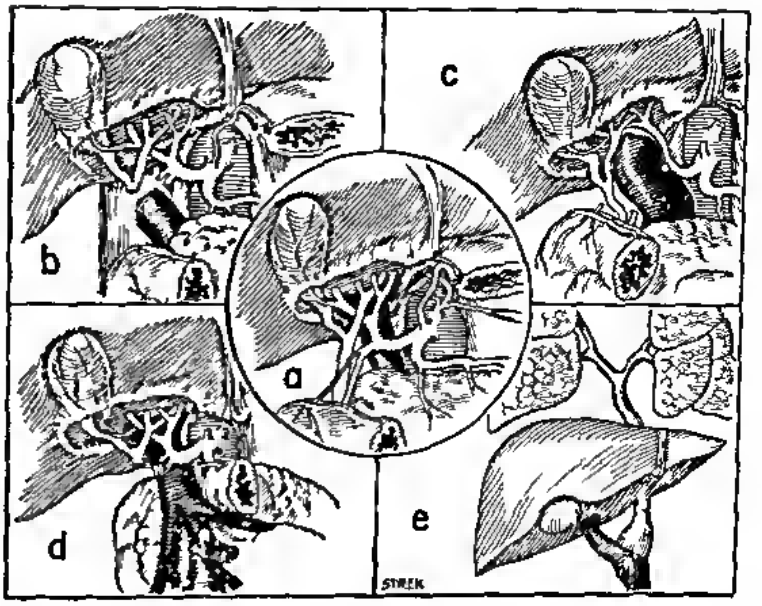


Fig 10 4 Normal portal vein and its reported congenital anomalies (*a*) Normal portal vein (*b*) Portal vein entering the vena cava directly (*c*) Stricture of portal vein (*d*) Portal vein anterior to pancreas and duodenum (*e*) Portal vein receiving pulmonary venous drainage (*Collected by* C G Child *The Hepatic Circulation and Portal Hypertension* Philadelphia W B Saunders Company 1954 )

larging upper abdominal mass for which diagnostic surgical exploration is undertaken Rarely can these cysts be removed and the surgeon and his patient must be content with a biopsy for microscopic study When the liver is but one of a number of organs involved little in the way of therapy is indicated for the patient is more likely to succumb to failure of one of the organs involved other than the liver

## Congenital Anomalies of the Hepatic Vascular Systems

Congenital absence of the arterial supply or the venous drainage of the liver is probably incompatible with life A number of interesting anomalies of each of the liver s vascular systems have been reported Rarely, however, do these require surgical treatment

At a time when there was great discussion about whether bile was formed from hepatic arterial or portal venous blood two patients were discovered at autopsy whose portal veins entered their vena cavas directly (Fig 10-4*b*) These patients at least proved that bile could be formed from arterial blood alone. Other anomalies include congenital stricture of the portal vein aberrant passage of this vessel ventral to the pancreas, and drainage of the pulmonary blood into the portal vein These are shown diagrammatically in Figure 10 4*c* *d* and *e*

Anomalies of the hepatic outflow tracts are rare and the one depicted in Figure 10 5 is included to emphasize that they can occur Here venous drainage of the liver entered the right auricle rather than

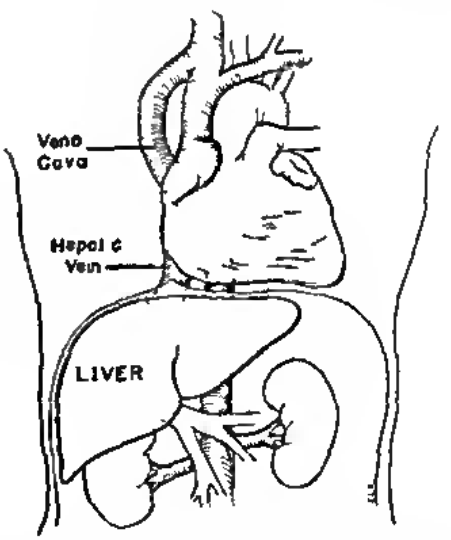


Fig 10 5 Anomaly of hepatic vein During a right thoracotomy a large vein thought to be azygos was ligated The patient died and at autopsy the entire hepatic venous drainage was found to enter the right auricle It was the main hepatic vein that had been inadvertently ligated during operation. Complete and sudden obstruction of the hepatic outflow tracts is incompatible with life

the vena cava Inadvertent ligation during an intrathoracic operation resulted in the death of the patient owing to complete obstruction of hepatic venous drainage

Just as the anatomy of the hepatic and portal veins is remarkably constant, that of the hepatic artery may be erratic Although unusual origins and courses of the hepatic artery are not of intrinsic surgical significance detailed awareness of aberrancies of this vessel is essential if operations upon the biliary tract, pancreas and portal vein are to be undertaken safely The commonest deviations from normal are diagrammatically portrayed in Figure 10 6*b c d* and *e*

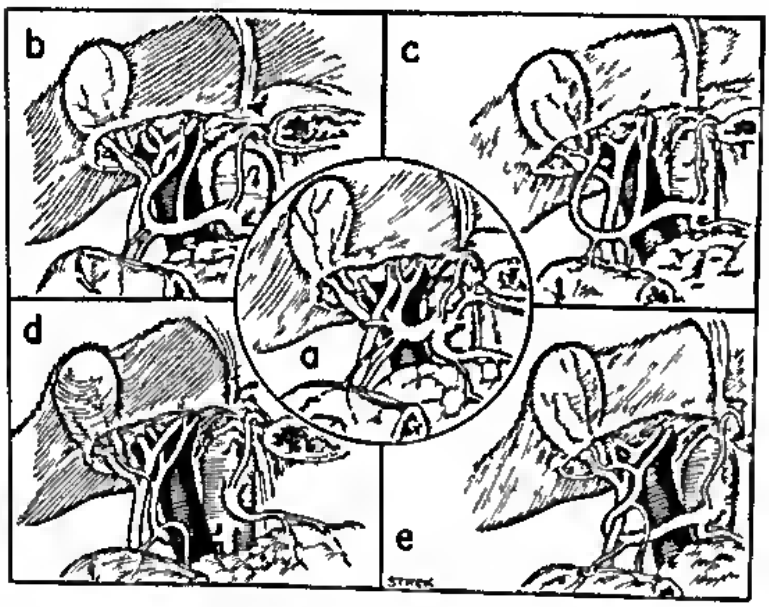


Fig 10-6 Normal hepatic artery and its common anomalies (*a*) Normal course of hepatic artery (*b*) Early division of hepatic artery into right and left branches Here the artery to the right territory lies on top of the common duct (*c*) Early division of the hepatic artery into its right and left branches with the right hepatic artery lying across the common duct (*d*) Hepatic artery originating from the superior mesenteric artery and passing behind the portal vein. (*e*) Normal hepatic artery encircling the common duct

### Aneurysm of Hepatic Artery

The difficulties in clinical diagnosis of hepatic arterial aneurysms congenital or acquired are but a prelude to the problems encountered in their treatment The stimulus to remove or obliterate these small aneurysms is great because of their tendency to rupture Unpredictable and massive hemorrhage from them constitutes an ever present threat to the life of patients with one of these vascular lesions A few general principles are available as guides in the management of the patient with an aneurysm of the hepatic artery should this be encountered incidentally at operation or, more fortunately, with advance warning The nearer the aneurysm lies to the origin of the hepatic artery, the better are the patient s chances of surviving excision of the aneurysm together with its segment of artery Under these circumstances hepatic circulation is usually sustained by anastomoses existing between the peripheral hepatic artery and the gastroduodenal pancreaticoduodenal and supraduodenal arteries Even when the aneurysm is more peripherally placed, anatomic dissections have demonstrated that in nearly 50 per cent of patients an aberrant hepatic arterial supply exists with capacity presumably adequate to maintain viability of the liver A completely thrombosed aneurysm can be excised with impunity because an adequate collateral circulation has almost surely developed

## TRAUMA OF THE LIVER

During the past 30 years the mortality of hepatic injury among persons surviving their accident long enough to be treated surgically has been dramatically reduced from 60 to 70 per cent to 10 to 20 per cent Prompt operation whole blood transfusions resection of damaged liver and introduction of antibiotic therapy have together accounted for this

important achievement The liver, a large organ rigidly fixed within the abdomen is prone to injury by both penetrating and blunt trauma Stab and gunshot wounds are common in the former category while in the latter automobile accidents account for the majority of hepatic injuries While gas rationing was in effect during World War II a large hospital in New York City reported but one patient with serious nonpenetrating injury of the liver Under normal traffic conditions many times this number of patients with vehicular injuries of the liver are admitted to large municipal hospitals

### Penetrating Wounds of the Liver

These are most consistently stab or gunshot wounds Unless serious injury to other organs is sustained this variety of hepatic wound is usually dealt with easily at the operating table with a few hemostatic mattress sutures Only shot gun wounds inflicted at close range are apt to produce devastating hepatic injury

### Nonpenetrating Wounds of the Liver

Accidents caused by motor vehicles account for the majority of patients with blunt trauma to the liver It has been estimated that of those who sustain this variety of hepatic injury one third die at the scene of the accident and one third shortly after reaching a hospital Only one third survive long enough to be treated surgically The extent and number of associated wounds significantly affect the survival of the patient whose liver is injured For instance Mikesky Howard and DeBakey have reported that when the liver alone is injured the mortality is in the neighborhood of 6 per cent depending upon the number and degree of associated injuries this figure rose as high as 70 per cent Sparkman and Fogelman have shown that in their hands liver injury alone carried a mortality of 3 1 per cent. When two to three additional injuries were present, this figure rose to 30 per cent and the mortality was 100 per cent when four or more injuries were present

### Diagnosis and Treatment of Hepatic Injuries

Since approximately half of patients with evidence of hepatic injury are admitted in shock this must be treated vigorously while diagnostic investigations are performed Whole blood should be administered until signs of shock subside If additional fluid is needed physiological saline is preferred to water and glucose In peritonitis owing to seepage of bile from a badly fractured liver large amounts of salt are sequestered in the peritoneal cavity If there are associated thoracic injuries a clear airway must be assured because a hypoxic liver is particularly subject to necrosis Excessive pain should be allayed by Demerol administered intravenously in small doses and repeated at as frequent intervals as necessary Gastric decompression is an essential preoperative measure and antibiotic therapy should be started early

Few signs or symptoms are pathognomonic of an injured liver In penetrating wounds of the right upper abdomen or lower thorax laceration or puncture of the liver may legitimately be assumed Any patient injured in an automobile accident who complains of abdominal pain referred to either shoulder should be suspected of hepatic injury Blood and bile obtained on abdominal paracentesis establish the need of immediate abdominal exploration Blood in the vomitus or gastric aspirate arouses suspicion of hepatic trauma for deep lacerations of the liver are often associated with bleeding into the biliary tract. Blood from the liver enters the duodenum through the common duct and is regurgitated into the stomach

Hemorrhage massive and continuing, is the most serious immediate problem among patients whose livers have been severely injured The veins of the portal and hepatic systems are thin walled and

without valves When broken they bleed copiously and blood mixed with bile clots poorly Infallible surgical methods for controlling hemorrhage from a severely damaged liver have not been developed Bleeding points from the surfaces of torn liver can generally be controlled by transfixion or free ligatures Massive hemorrhage occasioned by displacement of a large clot during abdominal exploration can be arrested temporarily by digital

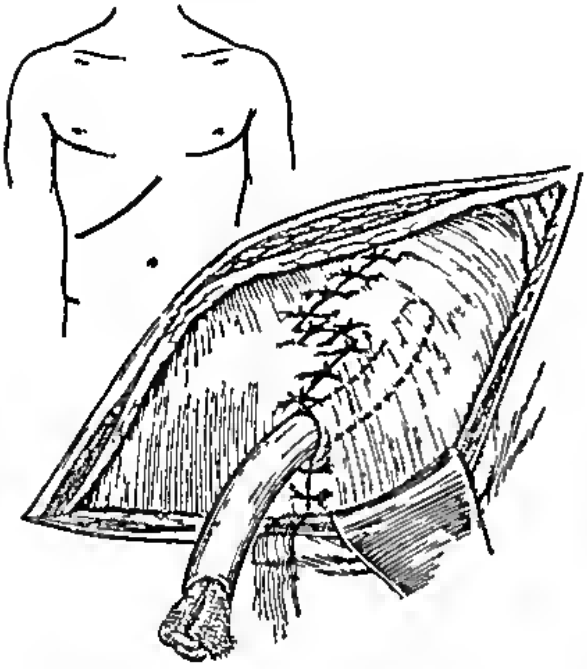

Fig 10 7 Drainage of deep fracture or laceration of liver Deep wounds of the liver may be satisfactorily closed provided the hepatic tissue involved is clearly viable The depths of the wound should be drained to prevent formation of an intrahepatic hematoma

compression of the hepatoduodenal ligament Hemorrhage from inaccessible or severely fragmented liver is least amenable to control by suture or ligature Under these circumstances the traditional technique for stopping hemorrhage has been through pressure exerted on the bleeding surfaces of the liver by large gauze rolls or packs that have been left in place several days to a week Unfortunately these promoted further devitalization of already injured liver Extensive infection was often associated with these packs and secondary hemorrhage following their removal was common So serious were these complications of compression packs that they lost favor during World War II Their use was replaced except under direst of circumstances by resection of all injured liver after appropriate ligature of the blood vessels and bile ducts in the area of damage (see page 307) Many are convinced that the decline in mortality and morbidity of severe hepatic injury during the past decade or two relates directly to substituting resection for pressure packs For over 50 years surgeons have been tempted to resect liver pulped torn or fragmented by severe injury but have not done so for fear of inciting fresh hemorrhage in critically ill patients Well stocked blood banks appreciation of surgical principles and increasing awareness of anatomic facts have led to wider acceptance of resection as the method of choice in treating patients with severe hepatic injury

From time to time controversies have flourished with respect to drainage after emergency operations upon the liver These discussions have generally been prompted by small series of patients with hepatic injury whose wounds have healed successfully without drainage When patients have done well under these circumstances absence of drains has been held responsible for success Careful thought and general consensus indicate that these conclusions are invalid Failure to drain off bile and the products of injured and often infected liver is a serious error in judgment in the treatment of hepatic injuries

Two circumstances of drainage are important The first relates to large deep wounds of the liver the edges of which can be united by suture These wounds should be closed about one or two cigarette drains in order to prevent formation of a large intrahepatic hematoma which may subsequently become infected (Fig 10-7) The second concerns the site of hepatic injury and repair Here

drainage should be generous, employing as many large cigarette drains as necessary Their paths of exit from the peritoneal cavity should be large enough to accommodate the drains easily and even allow for egress of necrotic liver (Fig 10 8)

## Complications of Hepatic Trauma

The early complications of surgical intervention for hepatic injury are recurrent hemorrhage, intrahepatic and subdiaphragmatic abscess, extensive necrosis of the liver, and biliary cutaneous fistulas Secondary hemorrhage usually occurs from eroded blood vessels lying in infected liver Reoperation for bleeding unavoidable as it may be, is particularly unrewarding and should be undertaken only in absolute necessity All too often bleeding is diffuse and lends itself poorly to control by ligature Drainage of abscesses at the site of repair of the injury should be performed without delay Biliary cutaneous fistulas will usually close spontaneously, though recently Shackelford reported a patient whose left hepatic territory had to be resected to achieve complete closure of such a fistula

Two late complications of hepatic trauma are troublesome and difficult to manage surgically The earliest of these is traumatic hemobilia or bleeding into the biliary tract from an infected area of necrotic liver lying deep within this organ This generally appears within two or three weeks after injury When this complication occurs, antibiotic therapy may be intensified in the hope that infection will be controlled and that the necrotic vessels that are bleeding into the biliary tract will heal Persistent bleeding in alarming amounts requires immediate operative intervention Exploration of the liver in the hope of ligating the bleeding vessel may be a frustrating endeavor and Spector reports that ligation of a major branch of the hepatic artery had to be performed to control hemorrhage in a patient with traumatic hemobilia

Traumatic cysts of the liver are still later complications of hepatic trauma They are rare and may appear only after many months For instance Hanson and his associates were able to collect only five patients with this complication from the entire surgical experience of the Mayo Clinic Extravasated blood and bile which remain uninfected produce these cysts Attention is called to them by right upper quadrant pain radiating to the shoulder together with a slowly enlarging upper abdominal tumor Rarely traumatic cysts can be removed but generally all that can be accomplished surgically is drainage

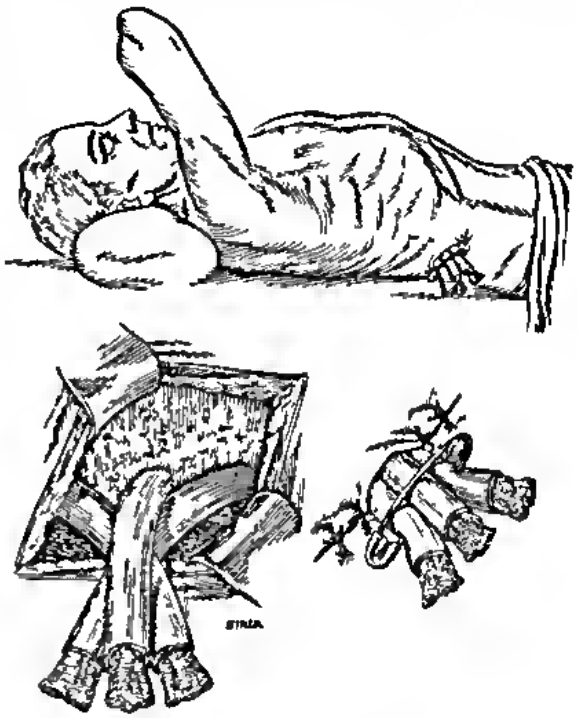

Fig 10 8 Drainage to the site of hepatic resection or extensively damaged liver Although most hepatic injuries or resections are approached anteriorly dependent drainage free and adequate is essential This can be accomplished most efficiently through a generous counterincision in the right flank

## Injury of the Hepatic Artery and Portal Vein

As a result of unusual or bizarre stab or gunshot wounds, the hepatic artery or portal vein may be injured Minor lacerations of the hepatic artery may be closed

by suture if extensive end to end reconstruction is essential if hepatic survival is to be assured Minor injuries to the portal vein can also be repaired by fine suture For many years it was assumed that continuity of a badly torn portal vein had to be re established if the patient were to survive This was based upon the conviction that ligation of the portal vein of man was fatal Recent experiments in man and monkeys have demonstrated that man can survive ligation of his portal vein uneventfully Furthermore, whether or not the portal vein in any given patient can be ligated safely is subject to conclusive test at the operating table Should temporary occlusion of the portal vein be followed by a profound fall in systemic arterial pressure that fails to recover within 20 to 30 minutes it is probable that the patient will not survive occlusion of his portal vein If however systemic arterial pressure returns to normal within a half hour or so such a patient can be relied upon to survive sudden and permanent occlusion of his portal vein

## ABSCESSES OF THE LIVER

Abscesses of the liver that may require surgical drainage are of two varieties those resulting from pyogenic organisms and those secondary to infestation by parasites particularly *Endamoeba coli* or *Echinococcus capsulatus*

### Pyogenic Abscess

Pyogenic abscesses that form within the liver may be multiple or single Commonly encountered organisms are *Escherichia coli* enterococci staphylococci streptococci and Friedlander s bacilli Single abscesses occur more frequently in the right than in the left hepatic territory multiple abscesses may involve both territories

The commonest cause of hepatic abscess is intraperitoneal sepsis or ascending cholangitis secondary to obstruction of the common duct Bacterial emboli detached from pylephlebitis are swept up the portal vein into the liver purulent exudate collecting in the common duct above a point of obstruction is forced up the bile ducts into the hepatic parenchyma Hepatic abscesses due to pylephlebitis were common prior to wide use of antibiotics in treating patients with perforation of the appendix and generalized peritonitis Today however purulent cholangitis predominates as the cause of pyogenic abscess of the liver Occasionally a bacterial embolus may enter the liver from an unrecognized focus of intraperitoneal infection This untoward event probably accounts for some so called primary intrahepatic abscesses Characteristically these are single

Bacteremia from whatever cause may result in the development of multiple or single hepatic abscesses owing to organisms carried to the liver through the hepatic artery The liver may also become infected by direct extension from adjacent septic processes such as intrathoracic empyema subphrenic abscess perforated duodenal ulcer or empyema of the gall bladder A rare cause of hepatic abscess is direct inoculation of the liver with virulent organisms by stab or gunshot wounds A liver extensively fractured by blunt trauma may of course become secondarily infected This is probably owing to organisms entering from without for the liver in man is normally sterile

### Diagnosis of Pyogenic Abscess

Because hepatic abscesses frequently develop in a setting of serious intra abdominal or generalized illness their onset may be difficult to detect Signs and symptoms are protean and often obscured by those of the primary disease Nevertheless pain in the upper abdomen an enlarging and tender liver fever chills and an elevated white blood count are usually sufficient evidence to arouse suspicion of an hepatic abscess Particularly should intrahepatic abscess be suspected if jaundice makes its appearance during any septic illness Roentgenology is precise in localizing an intrahepatic abscess if survey films of the upper abdomen disclose intrahepatic air fluid levels Chest and abdominal

films disclosing an elevated right diaphragm anteriorly and an obliterated cardiophrenic angle amply justify a tentative diagnosis of an intrahepatic abscess in the anterosuperior segments of the right hepatic territory Similar films demonstrating elevation and fixation of either diaphragm, and obliteration of costophrenic or costovertebral angles, are suggestive of intrahepatic abscess They do not, however, distinguish between intrahepatic abscesses or abscesses lying between the surface of the liver and diaphragm (see Chap 4) More esoteric roentgenologic methods such as intravenous or direct cholangiography and pneumoperitoneum have occasionally proved useful in detecting an intrahepatic abscess but have not been widely adopted for this purpose

Aspiration of the liver by needle is important not only in locating an intrahepatic abscess but also in deciding treatment If pyogenic organisms are identified on microscopic examination or culture of aspirated material, the abscess should be drained surgically If not, the abscess is probably parasitic and should not be openly incised A No 15 spinal needle with a blunt point and fitted stylet is employed in hepatic aspiration Although a wide difference of opinion regarding the proper method for aspiration of the liver is recognized, the following techniques have proved consistently useful

1 *Right Hepatic Territory*

a If the abscess is thought to be anterior, the needle is inserted just below the costal margin in the midclavicular line and directed superiorly and posteriorly (Fig 10 9, *Left*)

b If the abscess is believed to be posterior and inferior, the needle is inserted just below the 12th rib in the costovertebral angle (Fig 10 9, *Center*)

c The dome of the liver is best approached through the 9th or 10th intercostal interspace in the mid axillary line (Fig 10-9 *Right*)

2 *Left Hepatic Territory*

Because spleen, stomach, colon, and pancreas are interposed anatomically between the left hepatic territory and the lateral posterior thorax, aspiration from the lateral, anterior or posterior approach is unsafe If a large abscess is suspected on the left anteriorly, and if the left hepatic border is palpable anteriorly, aspiration just beneath the left costal margin is justified If, however, this is unproductive, the most satisfactory approach to any left hepatic abscess is surgical

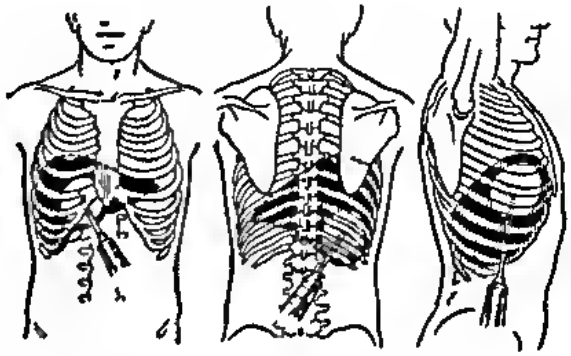

Fig 10 9 Aspiration of intrahepatic abscess (*Left*) If the abscess is thought to be anterior in the right territory it is best approached just beneath the right costal margin The needle is directed sharply upward and toward the right side of the patient (*Center*) If the abscess is thought to be in the posterior and inferior portion of the right territory, it is best approached through the right costovertebral angle directing the needle upward (*Right*) Abscesses in the dome of the right territory can be explored with a needle inserted through the 9th or 10th costal interspace

Diagnostic aspiration of the liver by needle incurs some risk of hemorrhage or contamination of pleural or peritoneal spaces with bacteria or parasites The advantage against which these risks must be weighed is that of saving a patient with an uninfected amoebic abscess an unnecessary operation In addition, accurate localization of a pyogenic abscess permits drainage by the most direct and least hazardous route If frank pus is aspirated, the cavity of the abscess should not be emptied and the needle should be left in place as a guide to open drainage Should repeated probing of the liver with a needle fail to locate an abscess, the operator must

by suture, if extensive, end to end reconstruction is essential if hepatic survival is to be assured Minor injuries to the portal vein can also be repaired by fine suture For many years it was assumed that continuity of a badly torn portal vein had to be re established if the patient were to survive This was based upon the conviction that ligation of the portal vein of man was fatal Recent experiments in man and monkeys have demonstrated that man can survive ligation of his portal vein uneventfully Furthermore, whether or not the portal vein in any given patient can be ligated safely is subject to conclusive test at the operating table Should temporary occlusion of the portal vein be followed by a profound fall in systemic arterial pressure that fails to recover within 20 to 30 minutes, it is probable that the patient will not survive occlusion of his portal vein If, however, systemic arterial pressure returns to normal within a half hour or so, such a patient can be relied upon to survive sudden and permanent occlusion of his portal vein

## ABSCESSES OF THE LIVER

Abscesses of the liver that may require surgical drainage are of two varieties those resulting from pyogenic organisms and those secondary to infestation by parasites, particularly *Endamoeba coli* or *Echinococcus capsulatus*

### Pyogenic Abscess

Pyogenic abscesses that form within the liver may be multiple or single Commonly encountered organisms are *Escherichia coli*, enterococci staphylococci, streptococci, and Friedlander s bacilli Single abscesses occur more frequently in the right than in the left hepatic territory, multiple abscesses may involve both territories

The commonest cause of hepatic abscess is intraperitoneal sepsis or ascending cholangitis secondary to obstruction of the common duct Bacterial emboli detached from pylephlebitis are swept up the portal vein into the liver, purulent exudate collecting in the common duct above a point of obstruction is forced up the bile ducts into the hepatic parenchyma Hepatic abscesses due to pylephlebitis were common prior to wide use of antibiotics in treating patients with perforation of the appendix and generalized peritonitis Today, however, purulent cholangitis predominates as the cause of pyogenic abscess of the liver Occasionally a bacterial embolus may enter the liver from an unrecognized focus of intraperitoneal infection This untoward event probably accounts for some so called primary intrahepatic abscesses Characteristically these are single

Bacteremia, from whatever cause, may result in the development of multiple or single hepatic abscesses owing to organisms carried to the liver through the hepatic artery The liver may also become infected by direct extension from adjacent septic processes such as intrathoracic empyema, subphrenic abscess, perforated duodenal ulcer, or empyema of the gall bladder A rare cause of hepatic abscess is direct inoculation of the liver with virulent organisms by stab or gunshot wounds A liver extensively fractured by blunt trauma may, of course, become secondarily infected This is probably owing to organisms entering from without for the liver in man is normally sterile

### Diagnosis of Pyogenic Abscess

Because hepatic abscesses frequently develop in a setting of serious intra abdominal or generalized illness, their onset may be difficult to detect Signs and symptoms are protean and often obscured by those of the primary disease Nevertheless, pain in the upper abdomen, an enlarging and tender liver, fever, chills, and an elevated white blood count are usually sufficient evidence to arouse suspicion of an hepatic abscess Particularly should intrahepatic abscess be suspected if jaundice makes its appearance during any septic illness Roentgenology is precise in localizing an intrahepatic abscess if survey films of the upper abdomen disclose intrahepatic air fluid levels Chest and abdominal

films disclosing an elevated right diaphragm anteriorly and an obliterated cardiophrenic angle amply justify a tentative diagnosis of an intrahepatic abscess in the anterosuperior segments of the right hepatic territory Similar films demonstrating elevation and fixation of either diaphragm, and obliteration of costophrenic or costovertebral angles, are suggestive of intrahepatic abscess They do not, however, distinguish between intrahepatic abscesses or abscesses lying between the surface of the liver and diaphragm (see Chap 4) More esoteric roentgenologic methods such as intravenous or direct cholangiography and pneumoperitoneum have occasionally proved useful in detecting an intrahepatic abscess but have not been widely adopted for this purpose

Aspiration of the liver by needle is important not only in locating an intrahepatic abscess but also in deciding treatment If pyogenic organisms are identified on microscopic examination or culture of aspirated material, the abscess should be drained surgically If not, the abscess is probably parasitic and should not be openly incised A No 15 spinal needle with a blunt point and fitted stylet is employed in hepatic aspiration Although a wide difference of opinion regarding the proper method for aspiration of the liver is recognized, the following techniques have proved consistently useful

1 *Right Hepatic Territory*

a If the abscess is thought to be anterior, the needle is inserted just below the costal margin in the midclavicular line and directed superiorly and posteriorly (Fig 10 9, *Left*)

b If the abscess is believed to be posterior and inferior, the needle is inserted just below the 12th rib in the costovertebral angle (Fig 10 9, *Center*)

c The dome of the liver is best approached through the 9th or 10th intercostal interspace in the mid axillary line (Fig 10-9 *Right*)

2 *Left Hepatic Territory*

Because spleen, stomach, colon, and pancreas are interposed anatomically between the left hepatic territory and the lateral posterior thorax, aspiration from the lateral, anterior, or posterior approach is unsafe If a large abscess is suspected on the left anteriorly, and if the left hepatic border is palpable anteriorly, aspiration just beneath the left costal margin is justified If, however, this is unproductive, the most satisfactory approach to any left hepatic abscess is surgical

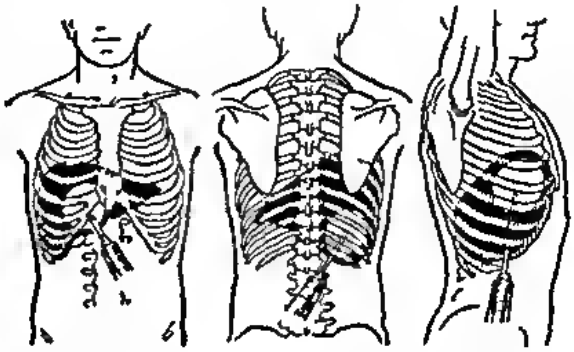

Fig 10-9 Aspiration of intrahepatic abscess (*Left*) If the abscess is thought to be anterior in the right territory, it is best approached just beneath the right costal margin The needle is directed sharply upward and toward the right side of the patient (*Center*) If the abscess is thought to be in the posterior and inferior portion of the right territory, it is best approached through the right costovertebral angle directing the needle upward (*Right*) Abscesses in the dome of the right territory can be explored with a needle inserted through the 9th or 10th costal interspace

Diagnostic aspiration of the liver by needle incurs some risk of hemorrhage or contamination of pleural or peritoneal spaces with bacteria or parasites The advantage against which these risks must be weighed is that of saving a patient with an uninfected amoebic abscess an unnecessary operation In addition, accurate localization of a pyogenic abscess permits drainage by the most direct and least hazardous route If frank pus is aspirated, the cavity of the abscess should not be emptied and the needle should be left in place as a guide to open drainage Should repeated probing of the liver with a needle fail to locate an abscess, the operator must

then decide whether evidence at hand warrants immediate surgical exploration or further delay

Wherever possible, intrahepatic abscesses should be drained without contaminating the pleural or peritoneal cavities Observation of this principle is practical where the abscess is accessible extraperitoneally or when associated inflammatory reaction has sealed the hepatic surface to the adjacent parietal peritoneum Often these ideals may have to be compromised under a variety of special circumstances

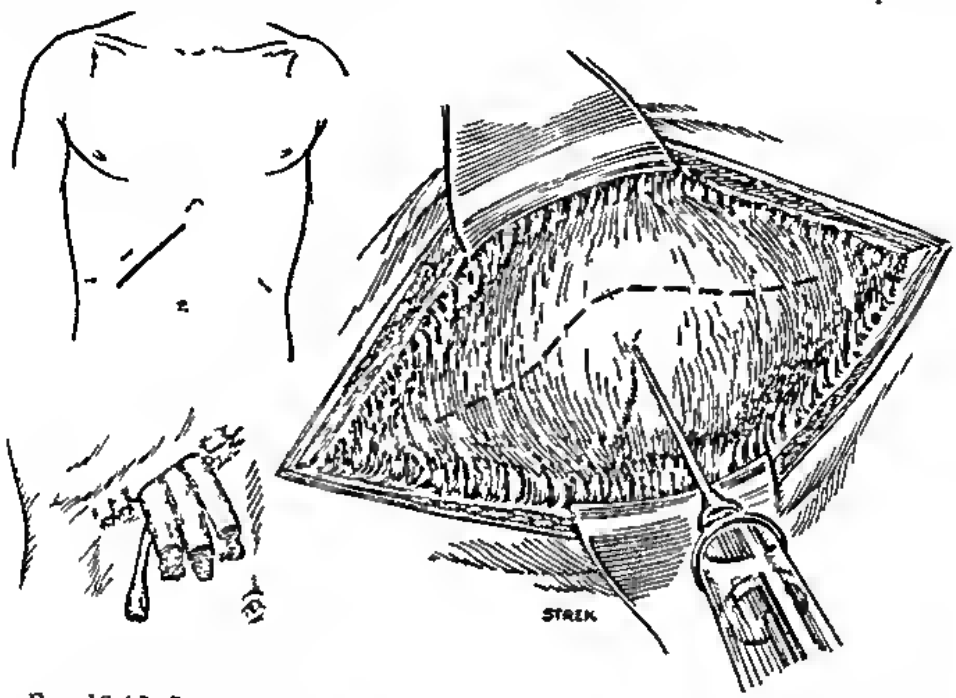


Fig 10 10 Incision and drainage of hepatic abscess occupying the antero-superior segments of the right territory Here fusion between the surface of the liver and overlying peritoneum and rectus and transversalis fasciae is depicted as having occurred The abscess is located by aspiration and incised over its dome Drainage is generous and a catheter is left in place for irrigation This same general approach is useful for an abscess in the left anterior territory and for right and left anteroinferior abscesses

## Surgical Drainage of Hepatic Abscesses

The liver is surgically accessible anteriorly and posteriorly The location of the abscess will determine which approach is used Those in the anterior portions of the right or left territories may readily be drained through an appropriate subcostal incision Some abscesses in these locations produce fusion between the liver and parietal peritoneum of the anterior abdominal wall The free peritoneal cavity may then be avoided by dissecting superiorly in a plane between the peritoneum and the rectus and transversalis fasciae until the abscess is reached (Fig 10 10) Under these circumstances of course drainage can be secured without contaminating the general peritoneal cavity More often however the peritoneal space over the liver will be open and transperitoneal drainage becomes necessary Here some measure of peritoneal protection can be afforded by suturing the liver to the under surface of the peritoneum of the anterior abdominal wall In either instance once free pus has been identified on aspiration the liver overlying the abscess is freely incised and drained by large cigarette drains (Fig 10 10)

Prior to the use of antibiotics two-stage drainage was the rule where the liver had not become adherent to the parietes Staged procedures involved an initial wound down to the peritoneum into

which gauze was packed, either plain or saturated with an irritating substance such as iodoform Several days were allowed for adhesions to seal the surface of the liver to the peritoneum before the abscess was drained Broad spectrum antibiotics in use today have made two stage procedures less common

Abscesses located posteriorly or laterally on either side are readily approached through the bed of the resected 12th rib Posteriorly this incision permits drainage of the abscess without entering the pleural or peritoneal spaces Laterally the peritoneal cavity is exposed to bacterial or parasitic contamination In treating most abscesses in the left hepatic territory or those presenting on the under surface of either territory, extraperitoneal drainage is impossible Transthoracic drainage of intrahepatic abscesses should be avoided except where the abscess has traversed the subphrenic space and diaphragm to present within the chest as empyema

Success in treating patients with pyogenic abscess of the liver depends upon whether the primary cause can be controlled, whether the abscesses are multiple or single, whether drainage is effective and whether the organisms involved are sensitive to available antibiotics A patient with a single abscess sealed from the pleural and peritoneal cavities that is precisely drained should be cured In spite of antibiotics the mortality among patients with multiple pyogenic abscesses of the liver is estimated at close to 90 per cent

## Parasitic Infestation of the Liver

AMOEBIC ABSCESS Approximately 70 per cent of amoebic abscesses are single and of these over 80 per cent occur in the right hepatic territory, particularly the dome In many patients with amoebic abscess of the liver, intestinal symptoms have subsided, in fact, by the time the abscess makes its appearance amoebae often cannot be recovered from the stool The signs and symptoms of amoebic abscess include malaise, upper abdominal pain, a large tender liver, and chills and fever These may appear acutely or be protracted enough to suggest a chronic illness of perplexing etiology If amoebic hepatitis or multiple small abscesses are suspected, a therapeutic trial with antiamoebic drugs is advocated If the patient's complaints thereafter subside promptly, a diagnosis of amoebic hepatitis or multiple small abscesses is nearly certain Emetine, once the antiamoebic drug of choice, has largely been supplanted by Chloroquin, which is less toxic One Gm of this amoebicide is given the first day, 0 5 Gm for the next six days, and 0 5 Gm weekly thereafter If, however, signs and symptoms of hepatic infestation do not subside upon drug therapy, a large amoebic abscess must be suspected This may or may not have become secondarily infected

The diagnosis and treatment of secondarily infected amoebic abscesses are similar to pyogenic abscess (see above) Amoebic abscesses, however, which have not become secondarily infected are best treated by repeated aspiration and antiamoebic drugs rather than by open drainage By nonsurgical measures the mortality is as low as 10 per cent In open drainage however secondary infection has raised this figure to 50 per cent or over

ECHINOCOCCUS CYST OF THE LIVER In man the shell of the ovum of *Echinococcus capsulatus* is digested in the stomach and the enclosed embryo released into the gut The developing parasite burrows its way through the wall of the small intestine and into a tributary of the portal vein Thence it is swept up the portal circulation into the liver where it may produce a typical cyst

As hepatic infestation develops, a large cyst is formed that is surrounded by a dense fibrous wall This, referred to as the adventitia, is derived from liver These cysts contain fluid and potentially active parasites When mature, innumerable daughter cysts may be present This fluid has the capacity to produce a fatal anaphylactic reaction if spilled, spontaneously or accidentally, into the general peritoneal cavity Calcification in the wall of the cyst is not uncommon and is readily detected roentgenographically

Echinococcus disease of the liver does not produce specific symptoms Often it is first suspected by finding an enlarged liver on routine physical examination Occasionally the cyst is large enough to interfere with biliary drainage and its first sign may be jaundice When one of these cysts becomes secondarily infected the patient s problem is then one of pyogenic abscess within the liver A complement fixation test and an intradermal skin test are available and should be used if the diagnosis of Echinococcus cyst of the liver is suspected The former is 80 per cent accurate while the latter comes close to 95 per cent

Most important in the treatment of Echinococcus cyst of the liver is avoiding contamination of the peritoneal cavity with its contents These cysts are approached through the same routes employed for drainage of pyogenic or amoebic abscesses After entering the cyst with an aspirating needle 10 per cent formalin is injected in an amount sufficient to yield a 1 5 per cent solution For instance 15 cc is injected into a cyst estimated to contain 1 000 cc of fluid The formalin solution is permitted to remain in the cyst for four or five minutes and then withdrawn as completely as possible After sterilization by this method the cyst is removed surgically in a plane between the hepatic adventitia and the wall of the cyst The large cavity left after removal of the cyst should be drained

### Granulomata of the Liver

Syphilis and tuberculosis may both involve the liver Generally a diffuse granulomatous process results that is not amenable to surgical treatment Well circumscribed gummas and tuberculomas have both been removed surgically

## PORTAL HYPERTENSION AND ESOPHAGOGASTRIC VARICES

Portal hypertension and esophagogastric varices are well recognized and surgically important complications of cirrhosis of the liver and of portal thrombosis Here varices are an ever present menace to life for they may bleed copiously at any time and without warning Portal pressure also rises and varices may appear in the esophagus and upper stomach of patients with cardiac failure pulmonary fibrosis and a variety of obstructions of the hepatic veins Varices developing in these latter illnesses do not commonly bleed Either they subside on appropriate medical treatment or the patients do not survive long enough for variceal hemorrhage to become clinically important

In patients with cirrhosis or portal thrombosis portal hypertension has been conventionally thought due to obstruction to flow of splanchnic venous blood through the liver or portal vein On this concept was based Whipple s original division of the etiology of varices into two categories intrahepatic and extrahepatic block Recently this single explanation of portal hypertension in cirrhosis has been challenged by those demonstrating that in this disease myriad abnormal communications develop between intrahepatic arterioles and portal venules These tiny arteriovenous fistulas support portal hypertension by contributing a portion of the arterial head of pressure to the portal venous bed Even more recently a number of investigators have postulated that normal arteriovenous shunts in the far periphery of the splanchnic bed respond in some obscure way to demands of the liver for more blood These may be satisfied by increased amounts of blood being poured into the portal system by way of the splenic gastric and superior and inferior mesenteric arteries

The frequency with which patients with alcoholic nutritional or Laennec s cirrhosis are encountered varies and reflects the socioeconomic status of the community under consideration An incidence of from 1 to 10 per cent in autopsies is commonly cited the lower figures are from private the higher from charity hospitals This disease is most frequent in white males, and least common, in temperate zones at

least, among Negroes Availability of medical and psychiatric therapy, abuse of alcohol, prevalence of viral hepatitis, and racial differences are but a few of the many factors explaining variations in statistics on this disease Approximately two thirds of patients with this variety of cirrhosis develop esophagogastric varices Of those with varices, from 25 to 30 per cent sustain severe bleeding at some time in the course of their disease The incidence of postnecrotic cirrhosis is generally considered lower than that of Laennec's but reported frequencies vary considerably These differences not only reflect variations in population characteristics, but also diversity in interpretation of the pathological material obtained in these two diseases at operation or postmortem examination Schistosomal cirrhosis is a well recognized cause of portal hypertension and bleeding varices where these parasites are endemic Portal thrombosis is rare and is found in from 3 to 10 per cent of patients with bleeding varices Characteristically this disease is one of young individuals

Whatever may be the cause of persistent portal hypertension, a shunt of good size fashioned between the hypertensive portal and adjacent low pressure caval circulation reduces portal pressure to normal or near normal levels Furthermore, after successful portal decompression the varices disappear and as long as these shunts remain widely patent patients are protected from further variceal hemorrhage

## Selection of Patients for Portal Decompression

Critical selection for portal decompression is important if patients with esophagogastric varices are to be managed successfully Among those with cirrhosis the problem is selection of the patient for the operation, in portal thrombosis the problem is selecting an appropriate operation for the patient

PORTAL THROMBOSIS Patients whose varices are associated with thrombosis of the portal, superior mesenteric, or splenic vein should be ideal candidates for portal decompression They are generally young, have normal liver function, and if protected from variceal hemorrhage can expect to live out a normal life span Because of technical difficulties in securing a good shunt, prolonged protection from recurrent hemorrhage has been difficult to achieve among these patients Nevertheless, brilliant successes are well known after portal decompression and all these young patients should be considered candidates for surgical intervention as soon as a diagnosis of varices is established An exception to this generality may be made in infants and small children Here, waiting until the child s vessels are large enough for successful anastomosis must be weighed against the risk of hemorrhage Fortunately hemorrhage, should it occur in these youngsters, is easily controlled and rarely fatal Patients with normal liver function tolerate hemorrhage better than do those with cirrhosis, and the risk of waiting a few years to insure a shunt of good size is not excessive

CIRRHOSIS OF THE LIVER When varices associated with cirrhosis of the liver bleed, control of hemorrhage is urgent The selection of patients for emergent or elective operation is pressing and offers many problems in clinical judgment Why varices bleed suddenly and without warning is not clearly understood Rupture owing to increased pressure, erosion owing to peptic esophagitis, and pressure necrosis of the vessel wall and mucosa from within have all been suggested as possible causes for sudden hemorrhage from a varix Once started, continuing hemorrhage is doubtless supported by hemorrhagic tendencies often manifest in patients with cirrhosis of the liver and related hypersplenism

## Emergent Control of Variceal Hemorrhage

The most effective immediate control of variceal hemorrhage from whatever cause is pneumatic tamponade by one of

a variety of esophagogastric balloons The most useful of these devices is widely known as the Sengstaken-Blakemore balloon This bears a globular gastric and a sausage-shaped esophageal component Success in pneumatic tamponade of esophagogastric varices will be no greater than the care exercised in its application Both balloons must be tested and individually calibrated before insertion in the esophagus They must be inflated under direct manometric control and pressure regulated by an ordinary mercury manometer inserted in each pneumatic circuit Traction on the apparatus should be just enough to maintain it in place and nasal hygiene should be carefully observed

When variceal hemorrhage in patients with cirrhosis has been controlled by tamponade, attention is next turned to evacuating blood from the gastrointestinal tract by repeated enemas and saline catharsis Although these latter measures may appear drastic in acutely ill patients recovering from shock, they are the only effective means of minimizing posthemorrhagic hepatic stupor and even coma Should a patient become stuporous or comatose, protection against respiratory embarrassment and aspiration should be afforded by tracheostomy Once the intestinal tract has been rid of blood, an effective intestinal antibiotic should be started to lower the rate of production of ammonia Neomycin, 1 to 2 Gm several times a day, has proved most effective in this regard

After bleeding has been controlled, parenteral fluid deficits repaired and the amount of ammonia in the gastrointestinal tract reduced, the question immediately arises as to what step should be taken next in the patient s behalf If, in spite of energetic supportive therapy, the patient is stuporous or actually in coma, if jaundice is deepening and ascites accumulating rapidly, all save continuing supportive therapy should be withheld Any operation under these circumstances is hazardous and can be expected to accomplish little in a patient obviously in a state of near terminal cirrhosis

The optimum time for deflation and withdrawal of the esophagogastric balloons is not accurately known A reasonably safe and logical procedure is to deflate the esophageal balloon 48 to 72 hours after its insertion If bleeding does not recur, the apparatus may be left in place with its balloons deflated for another 12 to 24 hours and then cautiously withdrawn If bleeding still does not recur, a progressive program of medical rehabilitation for elective portal decompression is started

Prompt recurrence of bleeding upon release of pneumatic tamponade presents a difficult problem in therapy and one about which much controversy centers today Blakemore believes that continued tamponade for a matter of weeks is appropriate Linton has long supported immediate transthoracic transesophageal ligation of the bleeding varices Welch has proposed transabdominal and transgastric control of hemorrhage Others believe that prompt portal decompression is advisable Ravdin's recent comments on so-called emergency portacaval shunts reflect the present indecision with regard to the place this operation should play in bleeding varices, 'So it is likely that the emergency portacaval shunt will take its place in our armamentarium, but the time is not now upon us ' In a recent article, Watson wrote, I personally believe the latter [shunt] is to be preferred if an emergency operation is necessary Only by greater experience with these divergent methods of managing the patient with cirrhosis and portal hypertension who continues to bleed upon release of his tamponade will the answer be found to this currently perplexing problem In our hands the results of portal decompression with pneumatic tamponade in place have been sufficiently encouraging to warrant continued use of urgent portal decompression

### Elective Portal Decompression

Clear indication for elective portal decompression is found today in patients

with cirrhosis who have recovered from one or more episodes of variceal hemorrhage Those who have bled once have clearly demonstrated their capacity to bleed and few are found who do not bleed again Protection from recurrent hemorrhage among these patients is urgently needed They should be advised to accept portal decompression unless they present such advanced hepatic failure as to incur a prohibitive surgical mortality or incapacitating postoperative morbidity

How to define in terms of hepatic reserve which patients who have bled are candidates for portal decompression and which are not is still a problem in clinical judgment Certainly there are patients with cirrhosis and variceal hemorrhage whose bleeding appears in a setting of good hepatic reserve They are generally persons not addicted to alcohol who are useful citizens carrying on gainful occupations Suddenly they suffer a massive hemorrhage readily controlled by pneumatic tamponade They do not then go into coma, but stop bleeding and recover from the effects of their hemorrhage Here portal decompression may be advised without hesitation for surgical mortality should be less than 5 per cent and postoperative morbidity rare

In sharp contrast to these good risk patients with cirrhosis are those who have had ascites, have been in coma are jaundiced, and whose serum albumin is less than 3 Gm per 100 milliliters Often these individuals are neither gainfully employed nor able to abstain from alcohol Here then are sick persons whose life expectancies are limited, who entertain a surgical mortality of 30 per cent or more and a high incidence of prolonged postoperative morbidity True, they may be protected from further hemorrhage at great price only to become problems in more or less permanent hospitalization To recommend portal decompression under these circumstances seems unwise

Between these two extremes fall many patients with arrested variceal hemorrhage in whom decisions with regard to portal decompression must be reached Few infallible rules can be cited in this regard although Linton's original criteria are useful In 1951 he postulated that if a patient had persistent ascites, if he were deeply jaundiced, or if his serum albumin were less than 3 Gm per 100 milliliters, operative risk would be great In addition, Linton pointed out that if Bromsulphalein retention were greatly increased, prothrombin time prolonged, and cephalin flocculation were seriously abnormal, operative mortality would be high Inflexible application of these criteria will deprive a number of patients of operation while violation as principles invites a prohibitive surgical mortality

Guided by Patek's original studies, many investigators have shown that cirrhosis of the liver can be treated effectively by prolonged hospitalization, low sodium intake, and a high caloric high protein diet Patients who have bled but who, by laboratory and clinical evidence are not candidates for immediate decompression should not be finally refused operation until they have had at least a month or two of strict medical treatment. Under such a regimen, many improve their health sufficiently to warrant operation In Figure 10-11 is diagrammatically represented the course of a patient too sick to be operated upon when first seen After 14 weeks of intensive dietotherapy, he improved to a point where portal decompression was *tolerated uneventfully During this period* his serum bilirubin fell from 3 4 to 0 8 mg per 100 milliliters, his serum albumin rose from 2 5 to 4 0 Gm per 100 milliliters he lost his ascites and gained in muscle mass This man is well and active three years after operation

Depressed prothrombin activity is a common finding among patients with hepatic disease Many times this responds to parenteral vitamin K, but occasionally prothrombin time continues to be prolonged and operation has to be undertaken in spite of abnormal prothrombin activity Here, blood lost should routinely be replaced by blood freshly drawn in plastic containers When hypersplenism and a low platelet count complicate op-

eration, transfusion of platelets has been an important adjunct

## Prophylactic Portal Decompression

When varices that have not bled are discovered in a patient with compensated cirrhosis and without hypersplenism, evidence is inadequate today to render a categorical decision regarding portal decompression Some maintain that sooner or later all patients with varices will bleed mightily and that a shunt therefore is indicated as soon as varices are discovered Others believe that the mortality and morbidity of an elective shunt are still too high to justify portal decompression as a preventive measure against hemorrhage This controversy is not likely to be resolved satisfactorily until the risk of hemorrhage and death in patients with varices that have not bled is accurately known

Patients whose varices have not bled occasionally develop clinically significant hypersplenism Here splenectomy and a splenorenal shunt should be performed when the patient's portal hypertension is due to portal thrombosis Failure to perform a splenorenal shunt at the time of splenectomy deprives the patient of one of his main chances for portal decompression Three possible operations are available to patients whose hypersplenism and varices have developed secondary to cirrhosis (1) a portacaval shunt may be

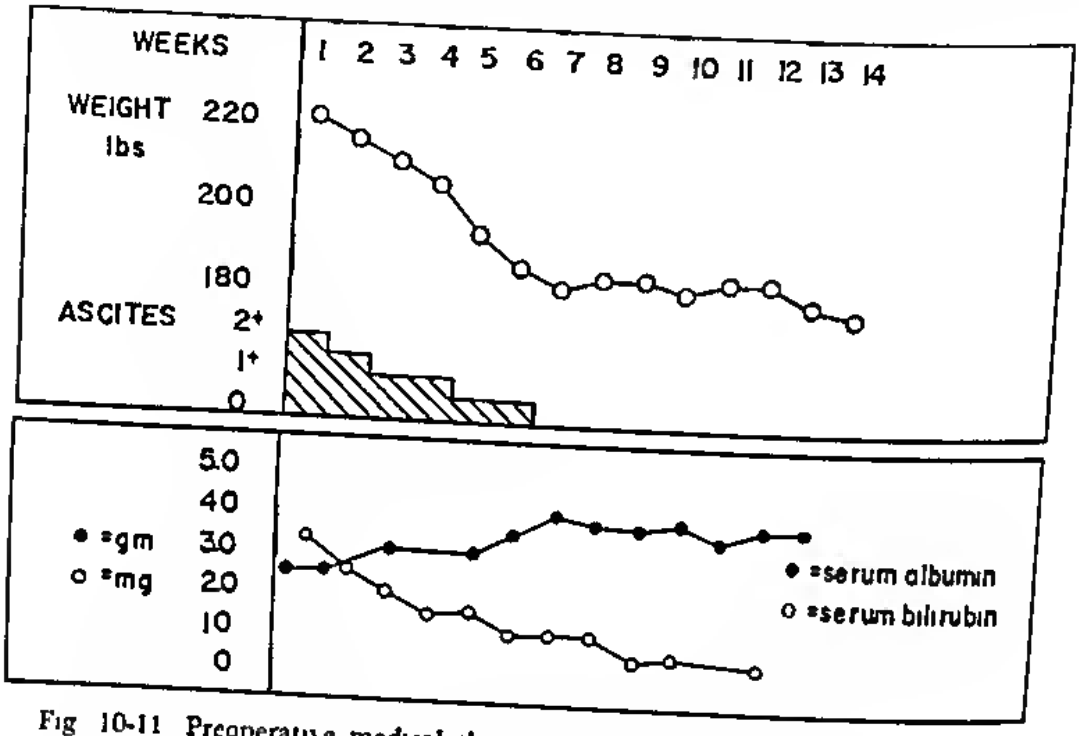


Fig 10-11 Preoperative medical therapy in cirrhosis of the liver The patient whose preoperative course is represented by this chart was a male, 50 years of age He recovered from his third massive hemorrhage but was jaundiced, had ascites, and his serum albumin was 2 4 gm per 100 milliliters Portal decompression was withheld at this time After 14 weeks on a nutritious diet and 200 mg of salt daily his health improved dramatically His ascites subsided, his serum bilirubin fell from 3 4 to 0 8 mg per 100 milliliters, and he was able to maintain a serum albumin level of 4 0 gm per 100 milliliters At the end of this period portal decompression was performed successfully He is well without varices three years after operation

performed relying upon portal decompression to relieve the hypersplenism, (2) splenectomy and a splenorenal shunt may be undertaken, and (3) a portacaval shunt and concomitant splenectomy may be used There is inadequate evidence today to prove which of these procedures is most useful In view, however, of our success in protecting patients from recurrent varicеal hemorrhage and hypersplenism by an end to-side portacaval shunt, we favor decompression alone rather than concomitant splenectomy or splenectomy and a splenorenal shunt

## Hemodynamics of Portal Decompression

Hemodynamically only two types of shunt are widely used for decompressing a hypertensive portal system into the low pressure caval circuit These are, Type 1*A* the splenorenal, 1*B* the side to side portacaval, and 1*C* the end to-side caval-superior mesenteric shunt, and Type 2 the end to-side portacaval shunt (Fig 10-12) All of these shunts have their special usefulness, the splenorenal in patients with portal thrombosis of cirrhosis of the liver, the end to side portacaval in

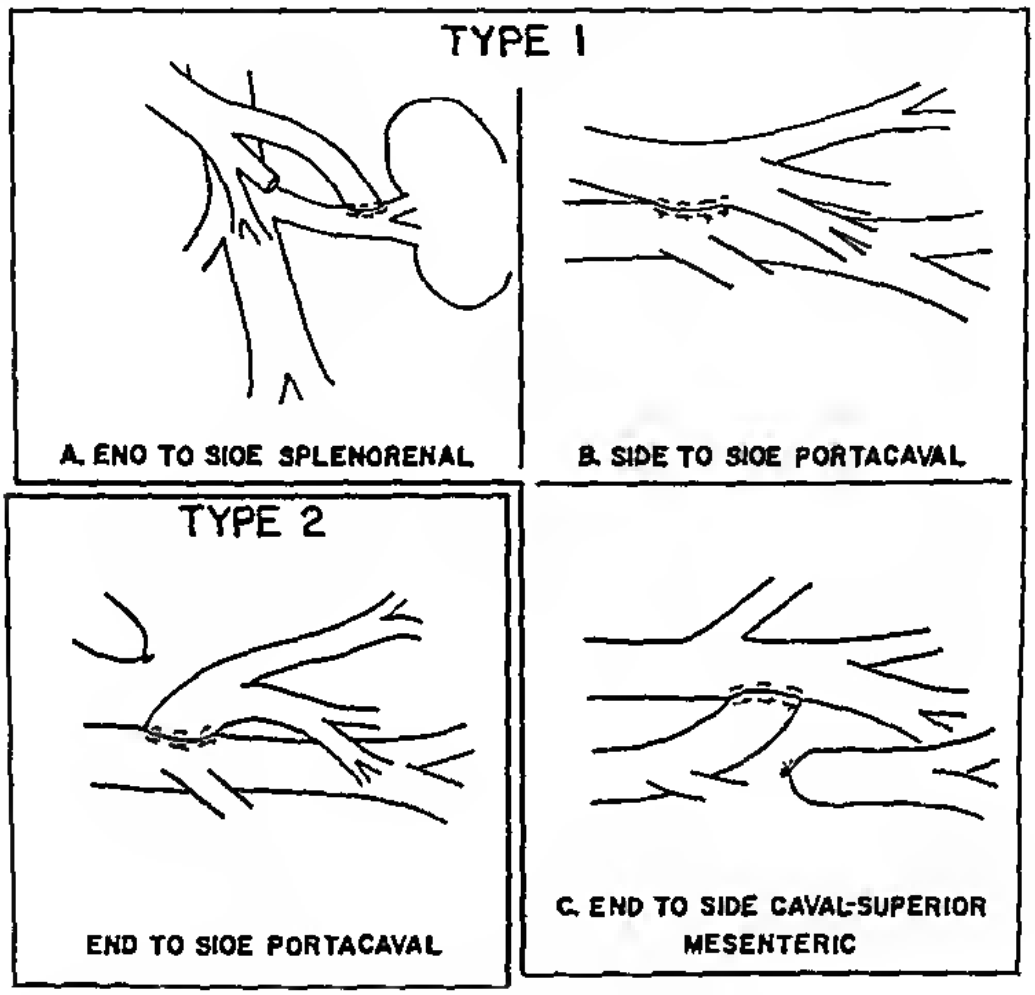


Fig 10-12 Hemodynamic types of shunt Four types of shunts are in common use today for portal decompression In Type 1, which includes the end to-side splenorenal (*A*), the side-to side portacaval (*B*), and the end to-side caval superior mesenteric (*C*), a free pathway exists between the splanchnic bed and the liver In Type 2, the end to-side portacaval, splanchnic blood is effectively excluded from the liver The advantages and disadvantages of these several shunts are discussed in the text

cirrhosis, and the end-to-side caval-superior mesenteric in instances of portal thrombosis where other shunts are impossible The particular usefulness of the side-to-side portacaval shunt has not been clearly defined although recently Longmire has expressed renewed enthusiasm for this variety of portal decompression After disappointing experiences with end-to side portacaval anastomosis in seven patients, Longmire began to employ the side-to side anastomosis whenever possible His most recent report includes 18 patients with shunts in the side to side position without operative mortality

Today, however, discussions center primarily around whether the end to side portacaval (Fig 10 12, Type 2) or the end to side splenorenal (Fig 10 12, Type 1A) should be employed in patients with cirrhosis where a free choice between the two is available Two suggestions dominate thinking in this regard Julian, reflecting the general agreement that intrahepatic obstruction to portal flow may wax and wane with variations in the activity of the cirrhotic process, has emphasized that the splenorenal shunt may only intermittently be called upon to carry the full load of portal flow With a high degree of portal obstruction the splenorenal shunt functions successfully when however, the potential of such a fistula is not fully realized in draining blood from the portal to the systemic circuit Julian has postulated that it may well shrink in size or even close Should once again it be needed, its full diameter may no longer be available Credence is lent this thought by the fact that the incidence of recurrent bleeding is generally higher after the splenorenal shunts than after the end to-side portacaval variety In explanation of this observation, Julian emphasizes that the portacaval shunt, once established, must always carry the full load of portal flow irrespective of hepatic resistance Its tendency to close, therefore, is unlikely

A number of surgeons, however, favor the splenorenal shunt (as well as the side-to-side portacaval) on the basis that a channel from the splanchnic bed to the liver exists by which portal blood could, if circumstances were favorable, flow to the liver The supposed advantage of portal blood gaining access to the liver is that this organ can exercise immediately its detoxifying action on blood draining the lower gastrointestinal tract This, it is hoped, lessens the incidence of post operative intoxication by ammonia If indeed this were true, splenorenal and side to-side portacaval shunts would hold a distinct physiological advantage over the end-to-side portacaval We however, have produced evidence, indirect to be sure, that in splenorenal and side to side portacaval shunts splanchnic blood may not enter the liver because intrahepatic portal pressure is higher than that in the decompressed splanchnic bed The experiments that we consider critical in this regard were performed during operation in 24 patients with cirrhosis and esophago gastric varices Intrahepatic portal pressure was estimated by measuring portal pressure on the hepatic side of a temporarily occluded portal vein (Fig 10-13b) In all save one patient intrahepatic portal pressure was 5 to 15 cm of saline higher than that existing in the splanchnic venous bed after opening an end to-side portacaval shunt We believe it unlikely that, if a comparable degree of decompression had been obtained in these same patients by a splenorenal or side to-side portacaval shunt, portal blood would flow from the splanchnic bed to the liver even though a potential venous pathway would in fact exist It remains, however, a matter of conjecture which way portal blood actually flows after splenorenal or side to-side portacaval shunts have been performed in patients with cirrhosis An effort to portray diagrammatically these hemodynamic relationships has been made in Figure 10 13 Recently Longmire has tried to determine by radioisotopic techniques whether, in the presence of a side-to-side portacaval shunt, some part of portal blood gains access to the liver As a result of his studies, Longmire concluded that 'with the transient changes

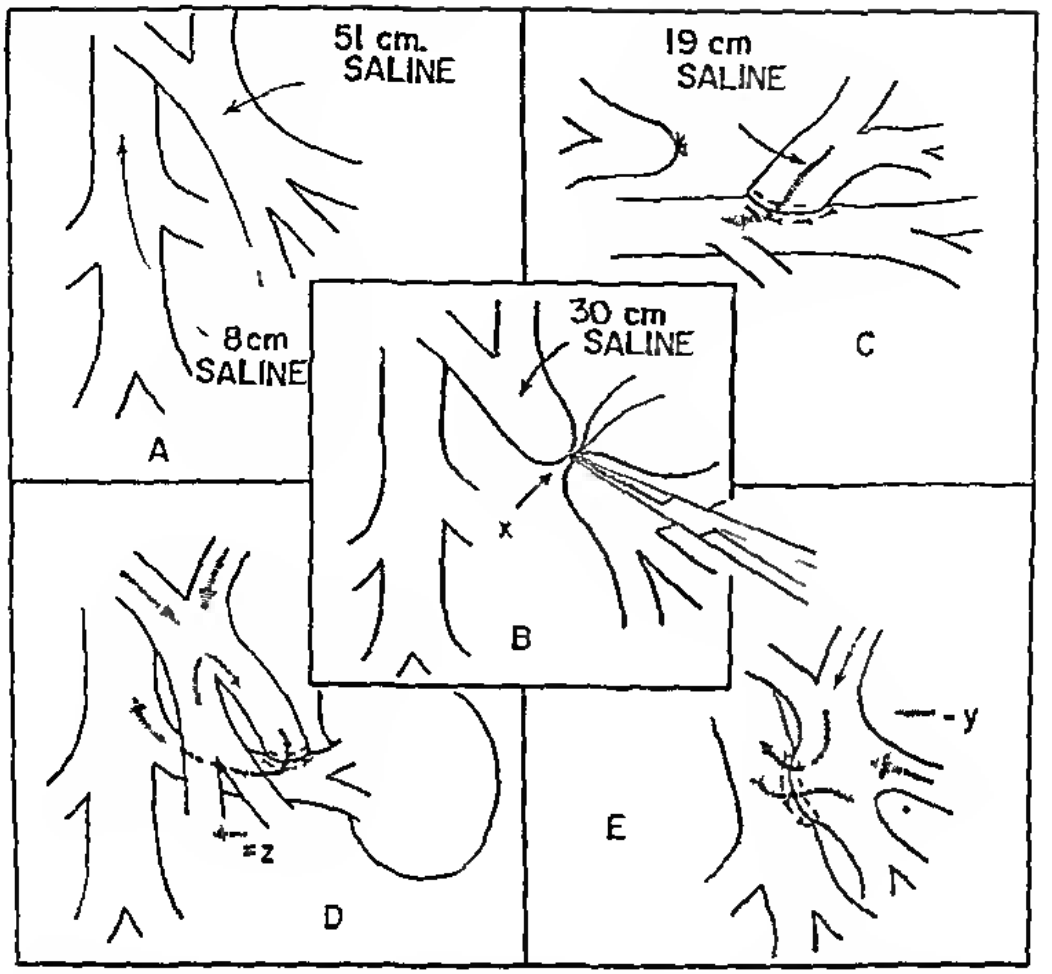


Fig 10 13 Hemodynamics of an end to side portacaval shunt compared in directly with those of an end to side splenorenal or side to-side portacaval shunt In this experiment performed upon a patient with cirrhosis and large esophago gastric varices the portal pressure was 51 cm of saline (*A*) The portal vein was temporarily occluded for 20 minutes Portal pressure was then measured on the hepatic side of the temporarily occluded portal vein This was 30 cm of saline (*B*) After opening the end to side portacaval shunt performed in this patient, splanchnic portal pressure fell to 19 cm of saline (*C*)

Had an end to side splenorenal (*D*) or a side to side portacaval (*E*) shunt been performed *and* had a fall in pressure been obtained comparable to that se cured by the end to side portacaval shunt (*C*) it appears unlikely that splanchnic blood would flow through the liver Rather hepatic portal blood would be drained from the liver through the shunt (Arrows in *D* and *E*)

This experiment representative of 23 similar ones is offered as evidence that little if any blood gains access to the liver in cirrhosis following portal decom pression by the conventional splenorenal or side to side portacaval shunt

in portal pressure associated with normal activities a portion of the portal blood may intermittently pass beyond the shunt into the liver ' Nevertheless, Longmire records three late deaths from hepatic failure among 18 patients with side to-side shunts.

In general most will agree that the portacaval shunt is easier to perform than the splenorenal For this reason it will probably retain its current popularity until splenorenal or side to-side porta caval shunts are proved unequivocally superior Always, of course, there will be

patients in whom a portacaval shunt can not be performed because of thrombosis of the portal vein Here a splenorenal or end to side caval superior mesenteric shunt becomes an important method for portal decompression

## Splenoportography

The portal and splenic veins may be visualized radiologically by preoperative injection of contrast medium into the spleen At the same time intrasplenic pressure an accurate reflexion of portal pressure can be measured The portal vein, splenic vein and superior mesenteric vein can similarly be visualized at the operating table (Fig 10-14) Great strategic advantage accrues to the surgeon by clear visualization of the vessels with which he has to work before commencing the long and oftentimes tedious dissection required to prepare a portal or splenic vein for anastomosis It is frustrating indeed to spend an hour or two dissecting out a portal vein only to find it thrombosed Similarly a small and tortuous splenic vein is probably an ineffective method for obtaining useful decompression As a clinic or individual begins to acquire experience with portal decompression, either preoperative or intraoperative splenoportography should be performed As facility is acquired with these operations, splenoportography becomes less essential because, with practice, patency of the portal or splenic veins can be determined by palpation at the operating table This practically should not in any way detract from the research value of splenoportography By these radiographic techniques much has been learned of the hemodynamics and anatomy of this obscure circulatory system, which has heretofore been relatively unavailable for study



Fig 10 14 Intraoperative splenoportography This roentgenogram, which clearly outlines the superior mesenteric splenic, portal and coronary veins as well as the intrahepatic portal radicles was obtained at the operating table by simultaneously injecting 40 milliliters of 70 per cent Diodrast into a cannula in a branch of the superior mesenteric vein and directly into the spleen Films such as this clearly outline the veins generally used in portal decompression and determine their availability in a given patient

## Anesthesia*

The preferred anesthetic agent and technique for major surgical procedures in patients with hepatic disease is cyclopro-

* The authors wish to thank Dr Benjamin E Eisten Professor of Anesthesia Tufts University School of Medicine for contributing this section

pane, d-tubocurarine, or succinylcholine, endotracheal intubation, and controlled respirations Cyclopropane supplemented with either succinylcholine or d-tubocurarine provides excellent operative conditions without depression of the vital systems The primary requirement of the inhalation agent is the loss of perception of pain by the patient Light levels of cyclopropane anesthesia avoid depression of myocardial function, peripheral circulation, hepatic function, and alterations in electrolytes Cyclopropane is ideal not only from this point of view but also because it aids in the support of the blood pressure and peripheral circulation by virtue of its pressorlike properties Muscle relaxants are administered to provide the required relaxation for surgery Depression of respiration or apnea usually is associated with the use of these drugs Therefore, the technique of endotracheal intubation and controlled respirations" is employed throughout the entire operation to insure adequate ventilation A volume displacement ventilator for controlling respiration is valuable because the proper tidal exchange and respiratory rate can be predetermined for each patient With this method, the arterial oxygen saturation and carbon dioxide tension can be maintained within physiologic levels and the adverse effects of anoxia and hypercarbia on the liver avoided

## Technique of Portal Decompression

The techniques of portal decompression have not been standardized and will doubtless ever reflect the special interests and skills of the surgeons performing this operation The hepatoduodenal ligament or the left renal and splenic veins may be approached either abdominally or through combined abdominal and thoracic incisions Opening the chest and splitting the diaphragm are not necessary, however, and seem to carry some additional surgical risk and morbidity

In the abdominal approach the patient is placed flat upon his back on the operating table with his thorax supported by two firm cotton rolls 10 to 15 cm in diameter These should be long enough to be reached easily from the head of the operating table and one or the other extracted by the anesthetist, depending upon whether a splenorenal or portacaval shunt is performed The patient's arms may be crossed in hornpipe fashion and secured to the anesthesia screen or they may remain at his side (Fig 10 15 *Upper* and *Lower*) The abdominal cavity is entered through an upper transverse incision transecting both rectus muscles Through this the viscera may readily be explored and a loop of jejunum drawn into the wound for cannulation of one of its mesenteric veins The tip of the spleen is readily available for injection Portal pressure is easily measured with a spinal manometer If desired the superior mesenteric, portal, and splenic veins may be visualized radiographically by the simultaneous injection of contrast media into the superior mesenteric cannula and into the spleen (see Fig 10 14) If a portacaval shunt is decided upon, the abdominal incision is extended deep into the right flank close to the right costal margin after withdrawing the roll supporting the left thorax

## End-to-Side Portacaval Shunt

Experience has demonstrated that adequate exposure to the structures of the hepatoduodenal ligament and regional vena cava can be obtained through an abdominal incision Dissection of the hepatoduodenal ligament is commenced by clearly defining the gallbladder, the cystic duct, the common duct, and particularly the hepatic artery and its branches (Fig 10-16) Inadvertent injury to the extrahepatic biliary tracts or the arterial blood supply of the liver invites undesirable operative and postoperative complications Particular emphasis should be placed upon division between clamps and secure ligature of all loose areolar tissue encountered in the course of this dissection (Fig 10-17) Herein pass the

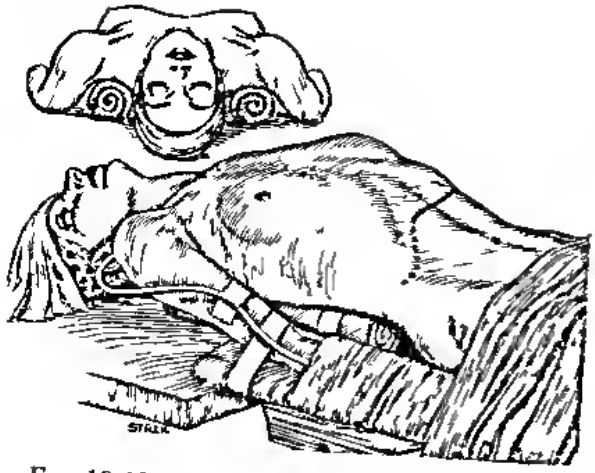

Fig 10 15 Position of patient for abdominal portal decompression The patient is placed flat upon the back with the thorax supported by two long firm cotton rolls 10 to 15 cm in diameter Depending upon whether a portacaval or splenorenal shunt is to be performed, the appropriate roll is withdrawn from the opposite side The abdomen is first entered through an upper abdominal transverse incision This is adequate to select, by palpation or splenoportography, which variety of shunt is appropriate If a portacaval shunt is elected, the original transverse incision is readily extended deep into the right flank, if a splenorenal shunt is elected, the original incision can easily be extended into the left thorax or flank as need may dictate

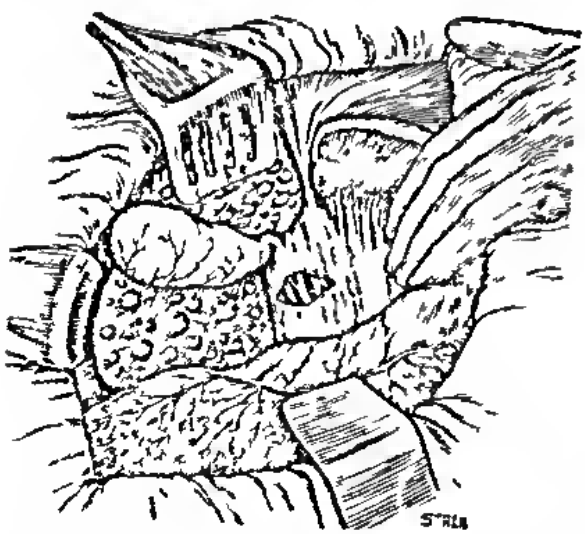

Fig 10-16 End to-side portacaval shunt The gallbladder, cystic duct, and common duct have been clearly defined The hepatic artery need not be dissected free for its position can generally be located by palpation.

lymphatics draining the liver Failure to secure lymphostasis results in excessive collection of hepatic lymph within the peritoneal cavity after operation Such lymphorrhea deprives the patient of important amounts of circulating water, electrolytes, and colloid Furthermore, careful lymphostasis precludes the necessity of performing the shunt in a puddle of lymph

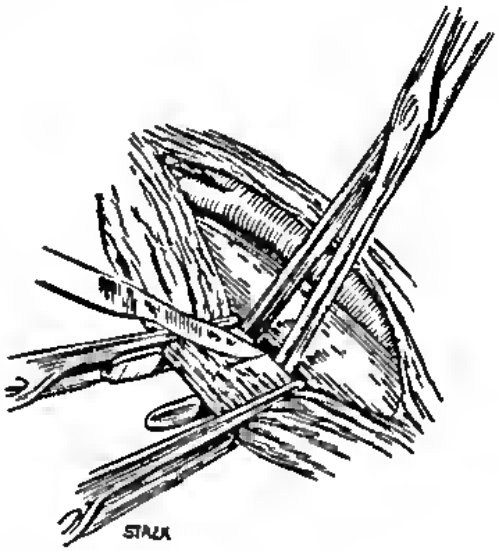

Fig 10 17 End to-side portacaval shunt As the thickened areolar tissue of the hepatoduodenal ligament is dissected free, it should always be divided between clamps and securely ligated Herein lie hypertrophied lymphatics draining the liver Failure to secure complete lymphostasis may complicate completion of the shunt by having to operate in a puddle of lymph and prejudices a smooth postoperative course by sequestration of large amounts of water, sodium, and serum albumin in the free peritoneal cavity

With areolar tissue and lymphatics swept aside, hepatic arterial branches clearly delineated, and the common, cystic and hepatic bile ducts safely retracted anteriorly, the right lateral wall of the portal vein comes readily into view (Fig 10 18) Freeing the portal vein from its surrounding structures, particularly inferiorly in the groove between the head and uncinate process of the pancreas and on the side away from the operator, must be done under direct vision to insure location

and division between hemostats of small veins entering the portal vein from below and medially Inadvertently tearing one or more of these small vessels promptly results in profuse hemorrhage from the hypertensive portal branches as well as from the portal vein itself Ofttimes this can be controlled only by discouragingly tedious and less than precise surgical maneuvers Once the portal vein adjacent to the pancreas has been mobilized, dissection in a cephalic direction may proceed less cautiously When the bifurcation of the portal vein into its right and left branches has been reached this vessel has been adequately prepared for anastomosis It should not, however, be divided at this time

A generous vertical incision is next made through the posterior peritoneum where the vena cava is believed to lie This dissection may be complicated by great thickening and vascularity of the peritoneal and subperitoneal tissues Particularly is this so if the patient has suffered from ascites for any considerable period A hypertrophied caudate lobe of liver can be relied upon to exasperate the operator further Nevertheless after diligent, bloody, and ofttimes prolonged search the vena cava is uniformly found in its normal position The anterior two thirds of this vessel is stripped clean of adventitia in preparation for anastomosis

Attention is once again turned to the portal vein, which is occluded at the upper border of the pancreas by a large Blalock clamp and divided as high as practical within the porta hepatis The operator is invariably as delighted at the apparent length of portal vein secured before division as he is disappointed at its actual length after division A little extra work in securing an additional centimeter of portal length is well worth the effort Blakemore has emphasized that the portal vein should be divided obliquely (Fig 10 19) to provide an anastomosis in which portal and caval blood streams merge with minimal eddies and countercurrents. This, Blakemore believes, prevents back pressure in the distal cava and protects the patient from troublesome edema of his lower extremities

A variety of clamps, the Alfred M Large, the Beck aortic clamp, and the

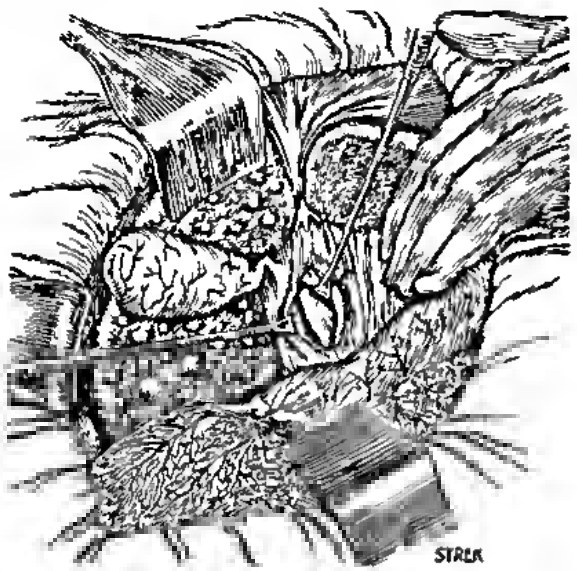

Fig 10 18 End to-side portacaval shunt (*Left and Right*) Upon drawing the common duct to the left the right lateral wall of the portal vein comes readily into view The ventral, left lateral and dorsal aspects of the portal vein are dissected free from the surrounding structures All small tributaries should be divided between clamps and ligated under direct vision

Satinsky are available to occlude partially the vena cava during its anastomosis to the portal vein Which one of these is used will depend upon the operator's preference and anatomic approach In placing the caval clamp, the operator, recalling that the patient is tipped away from him, should take pains to place the caval stoma precisely in the mid line Placing the stoma too far to right or left inevitably produces a kink prejudicing free flow through the anastomosis With the caval clamp in place, an oval button of cava is excised This insures the lips of the completed anastomosis remaining apart In excising this button of cava it should be recalled that the caval stoma can be enlarged more readily than closed should discrepancy between its size and that of the portal vein exist at the time of anastomosis (Fig 10-20)

While portal decompression was being developed, all vascular anastomoses were performed by interrupted everting mattress sutures that assured accurate intimal approximation Lately it has been shown in arterial anastomoses that a continuous suture is simple, effective, and without any particular hazard of thrombosis Because portal decompression involves two low-pressure systems, we have always believed that even the most ideal suture was none too good We have, therefore, employed interrupted everting mattress sutures in portacaval shunts (Fig 10-21*a, b, c, d*) As far as we know only one of our shunts has closed This misfortune occurred about a week after decompression in a patient who developed massive ascites and gaseous distention We have always believed that closure of this shunt was due to its role as a point of anchorage of distended loops of bowel floating upon a sea of ascites Strain on this anastomosis forced its edges together, where they healed tightly Numerous shunts have been examined as early as a few days to as late as five years after operation and all were beautifully healed Particular care to place the sutures close together on the far side of the anastomosis is important for this

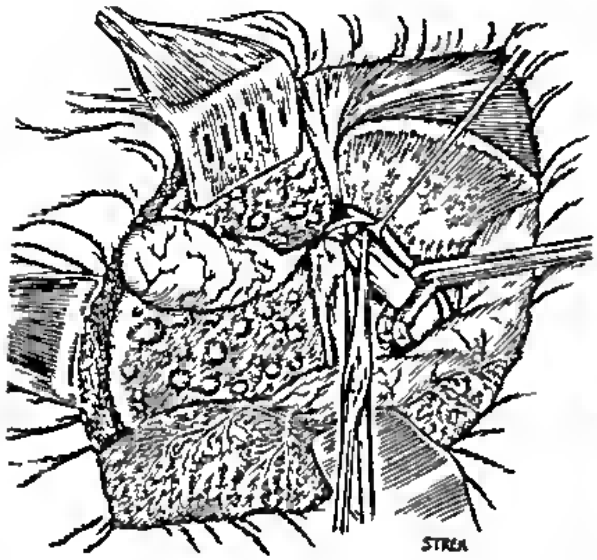


Fig 10 19 End to-side portacaval shunt The portal vein is occluded at the upper border of the pancreas by a large Blalock clamp and ligated as high in the porta hepatis as possible The portal vein is divided obliquely to insure a smoothly functioning shunt without eddies or countercurrents

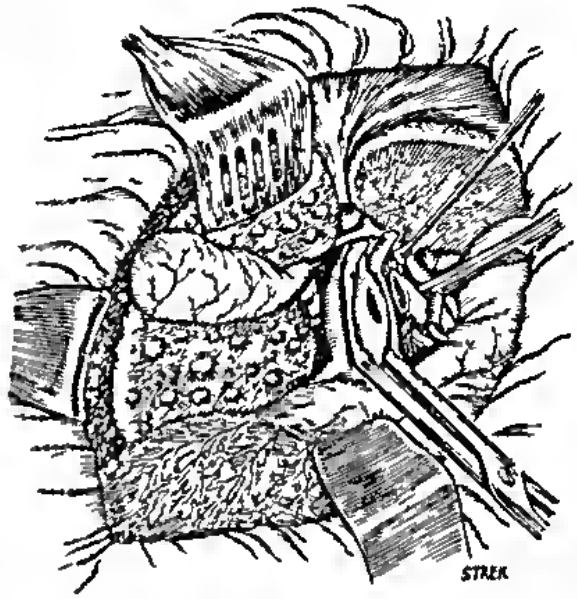


Fig 10-20 End to-side portacaval shunt The portal vein and vena cava have both been prepared for anastomosis A button has been removed from the ventral wall of the vena cava corresponding in size to the diameter of the portal vein Both vessels are now ready for anastomosis

line of suture is practically unavailable for repair should it leak upon removal of the caval and portal clamps

Upon opening a shunt fashioned in this manner, brisk bleeding has been rare but if it occurs, has been readily controlled by an additional suture or two Slight oozing has been encountered but this has always ceased spontaneously after a few minutes

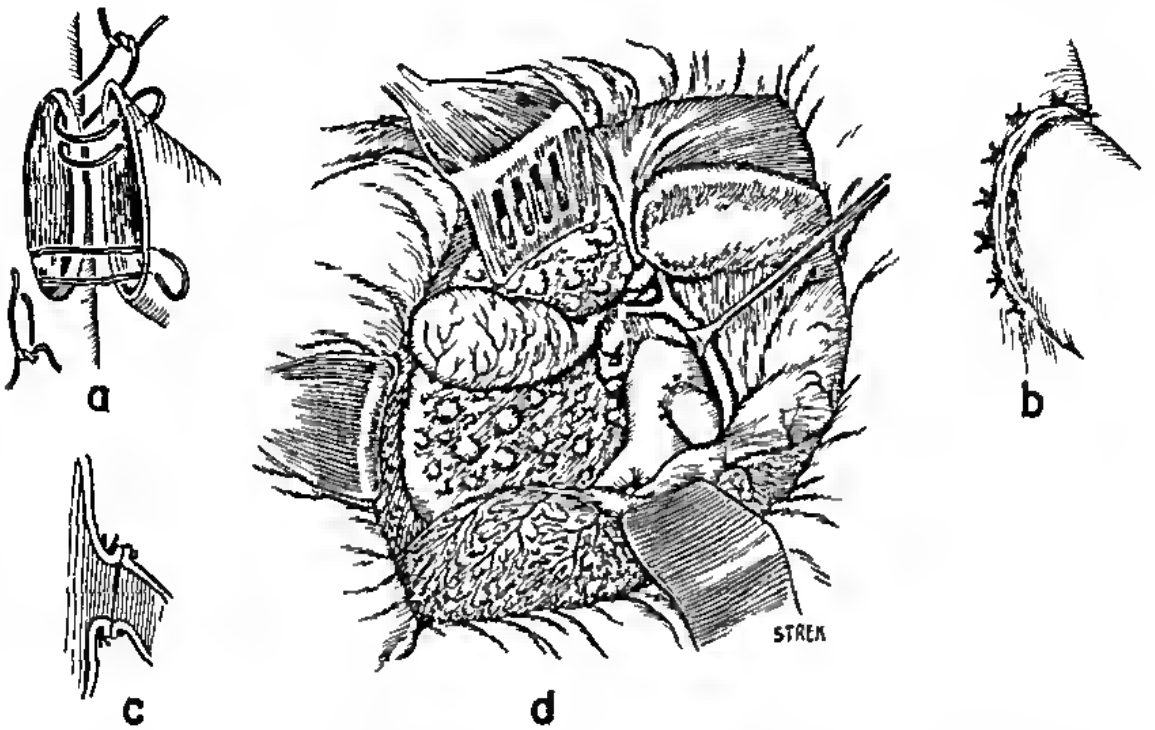


Fig 10 21 End to-side portacaval shunt In this composite diagram are illustrated (*a*) the aperture left in the ventral vena cava after removal of a button of the wall of this vein, and the obliquity of division of the portal vein (*b*) and (*c*) the everting mattress sutures used to secure intimal approximation in this anastomosis which is fashioned between two relatively low pressure vascular circuits In (*d*) is represented the completed end to side portacaval shunt

After opening the shunt a variable fall in portal pressure is the rule Sometimes this is as great as 20 to 30 cm of saline At other times a fall of only 5 to 10 cm of saline is obtained How much significance to attach to these figures is questionable, except that they do give evidence that immediately, at any rate, the shunt is patent. The only true measures of an adequate shunt are disappearance of varices and protection from further hemorrhage These can only be determined later in the postoperative period

**Splenorenal Anastomosis**

If a portacaval shunt is impossible or believed inadvisable the right thoracic roll is removed, the original transverse abdominal incision extended deep into the left flank, the twelfth rib excised and the incision continued posteriorly through its bed An alternate but satisfactory exposure, although it entails entering the chest, may be obtained by extending the original abdominal incision across the left costal margin and into the lower thorax in the eighth or ninth costal interspace The spleen is removed, its vein carefully dissected free from the tail of the pancreas and direct end to-side anastomosis performed between the end of the splenic vein and the side of the left renal vein (Fig 10-22) Greater or lesser degrees of difficulty are encountered in procuring an adequate length of splenic vein to provide

Satinsky are available to occlude partially the vena cava during its anastomosis to the portal vein Which one of these is used will depend upon the operator's preference and anatomic approach In placing the caval clamp, the operator, recalling that the patient is tipped away from him, should take pains to place the caval stoma precisely in the mid-line Placing the stoma too far to right or left inevitably produces a kink prejudicing free flow through the anastomosis. With the caval clamp in place, an oval button of cava is excised This insures the lips of the completed anastomosis remaining apart In excising this button of cava it should be recalled that the caval stoma can be enlarged more readily than closed should discrepancy between its size and that of the portal vein exist at the time of anastomosis (Fig 10-20)

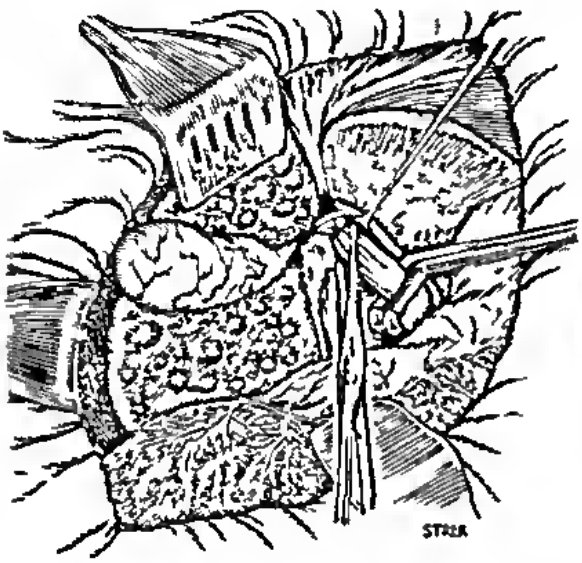


Fig 10-19 End to-side portacaval shunt The portal vein is occluded at the upper border of the pancreas by a large Blalock clamp and ligated as high in the porta hepatis as possible The portal vein is divided obliquely to insure a smoothly functioning shunt without eddies or countercurrents

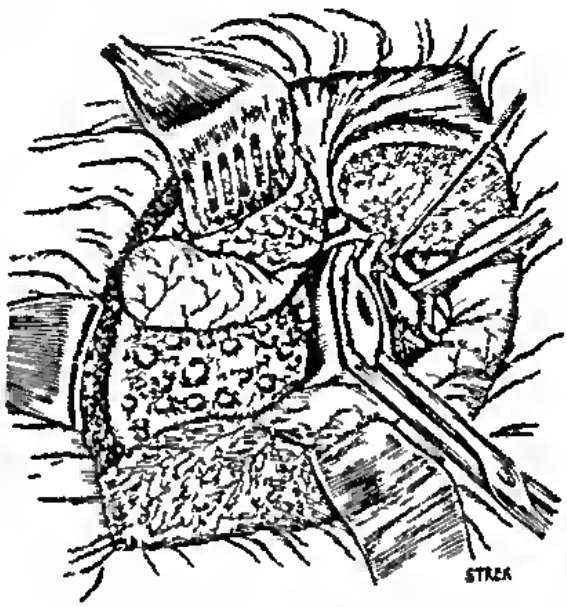


Fig 10-20 End to-side portacaval shunt The portal vein and vena cava have both been prepared for anastomosis A button has been removed from the ventral wall of the vena cava corresponding in size to the diameter of the portal vein Both vessels are now ready for anastomosis.

While portal decompression was being developed, all vascular anastomoses were performed by interrupted everting mattress sutures that assured accurate intimal approximation Lately it has been shown in arterial anastomoses that a continuous suture is simple, effective, and without any particular hazard of thrombosis. Because portal decompression involves two low-pressure systems, we have always believed that even the most ideal suture was none too good We have, therefore, employed interrupted everting mattress sutures in portacaval shunts (Fig 10-21*a*, *b*, *c*, *d*) As far as we know only one of our shunts has closed This misfortune occurred about a week after decompression in a patient who developed massive ascites and gaseous distention We have always believed that closure of this shunt was due to its role as a point of anchorage of distended loops of bowel floating upon a sea of ascites Strain on this anastomosis forced its edges together, where they healed tightly Numerous shunts have been examined as early as a few days to as late as five years after operation and all were beautifully healed Particular care to place the sutures close together on the far side of the anastomosis is important for this

line of suture is practically unavailable for repair should it leak upon removal of the caval and portal clamps

Upon opening a shunt fashioned in this manner, brisk bleeding has been rare but if it occurs, has been readily controlled by an additional suture or two Slight oozing has been encountered but this has always ceased spontaneously after a few minutes

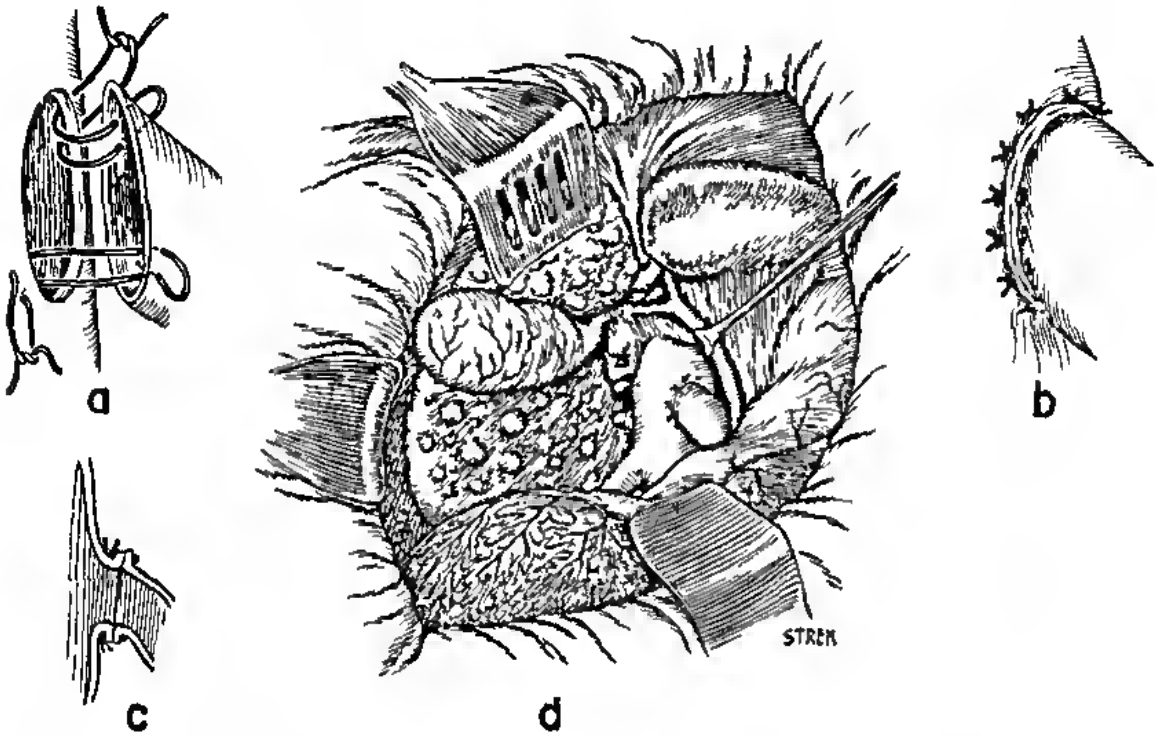


Fig 10 21 End to-side portacaval shunt In this composite diagram are illustrated (*a*) the aperture left in the ventral vena cava after removal of a button of the wall of this vein, and the obliquity of division of the portal vein, (b) and (*c*), the everting mattress sutures used to secure intimal approximation in this anastomosis, which is fashioned between two relatively low pressure vascular circuits In (*d*) is represented the completed end to side portacaval shunt

After opening the shunt a variable fall in portal pressure is the rule Sometimes this is as great as 20 to 30 cm of saline At other times a fall of only 5 to 10 cm of saline is obtained How much significance to attach to these figures is questionable, except that they do give evidence that unmediately, at any rate, the shunt is patent. The only true measures of an adequate shunt are disappearance of varices and protection from further hemorrhage These can only be determined later in the postoperative period

**Splenorenal Anastomosis**

If a portacaval shunt is impossible or believed inadvisable, the right thoracic roll is removed, the original transverse abdominal incision extended deep into the left flank, the twelfth rib excised and the incision continued posteriorly through its bed An alternate but satisfactory exposure, although it entails entering the chest, may be obtained by extending the original abdominal incision across the left costal margin and into the lower thorax in the eighth or ninth costal interspace The spleen is removed, its vein carefully dissected free from the tail of the pancreas and direct end to-side anastomosis performed between the end of the splenic vein and the side of the left renal vein (Fig 10 22) Greater or lesser degrees of difficulty are encountered in procuring an adequate length of splenic vein to provide

a sound anastomosis Rousselot has shown that an autogenous graft taken from the superficial femoral vein may facilitate splenorenal decompression The clamps and techniques employed in end to-side splenorenal anastomoses are similar to those described above for portacaval decompression

Closure of abdominal or combined abdominothoracic wounds is accomplished according to the operator s preference Because patients with cirrhosis are usually hypoproteinemic, we have long preferred in addition to layer closure buried stay sutures through all layers save the skin Anticoagulants have not been used postoperatively The peritoneal cavity has

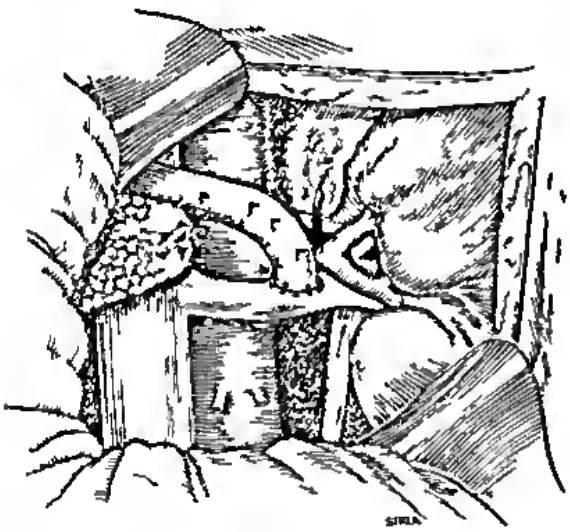

F g 10 22 End to-s de splenorenal anastomos s D agrammat c representation of an end to-s de splenorenal anastomos s This variety of shunt s part cularly useful in portal hyper tens on o v ng to thrombosis of the portal ve n

been drained only in the presence of a concomitant cholecystectomy exploration of the common duct or resection of the colon

## Side to-Side Portacaval and End to-Side Caval Superior Mesenteric Anastomoses

Side to side portacaval anastomoses have been employed in a number of clinics in the belief that they are more physiologic than the end to-side portacaval shunt Legitimate questions have been raised as to whether or not portal blood does in fact gain access to the liver after this variety of shunt (see page 284) Some maintain that the effects of the side to side shunt might even be deleterious to hepatic function because it promotes run off of hepatic arterial blood before this reaches the cells of the liver Welch has proposed the side to side portacaval shunt as a treatment of ascites in the belief that hepatic decompression by this technique might retard formation of ascites Nickel and Eisenmenger, however have managed to control ascites in selected patients by conventional end to-side portacaval anastomosis End to side anastomosis between the proximal end of the divided vena cava and superior mesenteric vein has been proposed by Clatworthy for portal decompression when neither a portacaval nor a splenorenal shunt is possible As noted previously Longmire has produced additional evidence in favor of the side to side variety of portacaval shunt

## Lesser Portacaval Anastomoses

From time to time in the past anastomoses have been made between vessels such as the inferior mesenteric and spermatic or ovarian veins These shunts between lesser vessels have uniformly failed

## Postoperative Care

In general patients with reasonable hepatic reserve who have been selected carefully for portal decompression have tolerated their operations well Continuous nasogastric suction has been omitted for fear of starting esophagogastric hemorrhage On the slightest evidence of gastric dilatation however a small well greased nasogastric tube has been passed carefully the stomach emptied of air and secretions and the tube withdrawn Only rarely has it been necessary to repeat th s procedure more than once or twice Repeated passage of such a tube has been considered less hazardous than leaving the tube in place

Two features of an uncomplicated postoperative course are common The serum bilirubin rises several milligrams per 100 milliliters and then returns to the preoperative level within a week or two Generally this is believed due to transient impairment of hepatic function It may, however, be a phenomenon relating to trauma to the common bile duct, which is extensively manipulated during portacaval anastomosis Serious and prolonged elevations in serum bilirubin are ominous and regularly reflect impending hepatic failure Serum albumin is regularly depressed in spite of adequate blood replacement during operation For this reason serum albumin levels should be maintained between 3 and 4 Gm per 100 milliliters by the use of 25 to 50 Gm of human serum albumin daily Within several weeks after operation most patients able preoperatively to maintain a normal serum albumin, will again demonstrate their capacity to fabricate this important constituent of the blood As in the case of serum bilirubin transient depression of serum albumin has been interpreted as evidence of postoperative lessening of hepatic function Portal decompression, however, requires a wide area of peritoneal dissection and complete lymphostasis can rarely be achieved Transient albumin depression may quite as logically represent sequestration of this important colloid in the peritoneal cavity rather than failure in its formation

A depressed level of serum sodium is a serious complication of hemorrhage or operation among patients with cirrhosis To prevent ascites, many of these individuals are maintained on diets containing little more than 200 mg of salt a day Hemorrhage, operation, or sudden increases in ascites rapidly deplete stores of available body sodium to a point where normal serum concentrations are not maintained This may be accentuated further by the administration of solutions containing only water and dextrose Shock, oliguria, and other signs of hyponatremia may appear Treatment should be initiated by 300 ml of 3 per cent sodium chloride solution administered intravenously Thereafter, careful attention should be paid urinary excretion, body weight, and serum sodium concentrations if such patients are to be carried successfully through their acute episode of stress

### Postoperative Mortality

Postoperative mortality has been reported to vary from 5 to 30 per cent In considering surgical mortality it must be borne in mind that a clinic can choose its own mortality within relatively narrow limits For instance, if only excellent risk patients are accepted for operation, a mortality may be predicted in the range of 5 per cent and even as low as 2 to 3 per cent Under these circumstances a number of patients will have been deprived of a much needed shunt Should a clinic or individual decide to accept all or nearly all patients with variceal hemorrhage for operation, a number who clearly would die from hemorrhage would be protected but an inordinately large number (30 to 40 per cent) would die following portal decompression Patients with cirrhosis of the liver and variceal hemorrhage must not be likened to patients with cancer where even extraordinary risks are justified and legitimately taken Progression of cirrhosis is not inexorable for it may be treated medically, ofttimes with surprising success

### Intra-abdominal Hemorrhage

Twice, in nearly one hundred patients subjected to portal decompression, has intraperitoneal hemorrhage been serious enough to warrant reoperation In each instance specific bleeding points could not be found and the patients continued to bleed from retroperitoneal surfaces, from the needle holes of their anastomoses, and into the layers of their abdominal wounds In one, a grave deficiency in plasma fibrinogen was encountered This failed to respond to replacement therapy, in the other, severe fibrinolysis was demon-

strated Postoperative hemorrhage, a terrifying complication of portal decompression, is probably akin to massive bleeding seen postpartum and after major operations upon the lung and other organs high in fibrinolysins This type of bleeding may also reflect the hemorrhagic diathesis seen in patients receiving many transfusions where citrate intoxication has been held responsible Prevention and treatment of these complications of portal decompression are only imperfectly understood

### Early Hepatic Failure

Occasionally a patient, no matter how carefully selected for operation, will progress rapidly into coma, oliguria, sodium retention, blood nitrogen retention, massive ascites and death Clearly, such patients should not have been accepted for operation Once hepatic failure, however, has appeared, despair should not dominate for perseverance and attention to every therapeutic detail may reverse this process and ultimate recovery of the patient be achieved

### Protein Intolerance

Some patients subjected to portal decompression develop postoperative intolerance to ingested protein This may vary from confusion and somnolence to frank hepatic coma Some recover sufficiently to return to work while others remain more or less permanent neuronutritional cripples When patients develop this syndrome after operation, they should be placed on carefully controlled dietary programs Initially all protein is withdrawn from the diet and treatment with intestinal antibiotics started Generally a week or two is required for the sensorium to clear Dietary protein may then be added in increasing amounts Ten to 20 Gm may be added weekly until an intake is reached compatible with normal activity Usually such patients over a month or two or even longer will regain their ability to ingest a normal diet.

### Late Hepatic Failure

Patients in whom a shunt has been performed for variceal hemorrhage secondary to portal thrombosis live out their individual life spans Patients with an Eck fistula in the presence of cirrhosis of the liver are subject to the unpredictable laws that govern the natural life history of this disease Sooner or later patients with cirrhosis may die of their hepatic disease or some other unrelated illness apparently irrespective of the shunt Hepatoma, cancer of the lung, and massive hemorrhage from peptic ulceration have in our experience each claimed their share of patients treated for variceal hemorrhage by portal decompression In man there is little specific evidence that the shunt either promotes or detracts from hepatic function Linton has expressed the opinion that after portal decompression many patients appear to be improved clinically This observation has been made a number of times and it may be conjectured that lowering portal pressure to normal enhances nutrition by promoting more normal absorption from the gastrointestinal tract As attractive as this hypothesis is little proof of its validity is available One is tempted to conclude that the better hygienic way of life that many patients adopt after operation is the more likely explanation of their better health

A number of patients, however, from six months to a number of years after operation develop progressive liver failure This may bear specific relationship to the continued use of alcohol or it may appear in the face of temperate living Deepening jaundice, ascites edema, coma, and sodium retention, as well as other features of hepatic failure, overtake the patient at unpredictable periods after portal decompression

From time to time the question has been asked whether portal decompression significantly prolongs life A precise answer to this perplexing question of prolonged survival following portal decompression is not available because randomized series of comparable patients,

some operated upon and others not, are unavailable for comparison Today the good-risk patient who has bled is operated upon while the poor-risk patient is not The latter, subject to recurrent hemorrhage and progressive liver failure, is then erroneously compared to his brother who has been operated upon successfully Such comparisons are unscientific and far from objective

## Postoperative Gastric and Duodenal Ulceration

For many years gastric and duodenal ulcers have been known to occur more frequently in patients with cirrhosis than in the general population Alcohol and poor diets have usually been advanced in explanation of this observation Recently experimental and clinical evidence has indicated that total acid secretion is high in experimental animals and in patients with portal obstruction or portacaval anastomoses In our experience one patient required gastrectomy for a large gastric ulcer appearing six months after a portacaval shunt Another patient died from massive upper gastrointestinal bleeding 13 months after a shunt Because this latter patient s varices had completely disappeared within a few months after his shunt, his fatal hemorrhage was presumed to have been from a large duodenal ulcer, which was readily identified by x ray studies a week or so before his death Unfortunately permission for postmortem examination could not be obtained from this patient s relatives Evidence today indicates that all patients whose portal circuits have been decompressed should be followed closely for evidence of peptic ulceration

## Portal Hypertension and Ascites

In 1877 Nicolai Eck described his original success in dogs with the venous fistula that now bears his name and wrote, 'I am conducting these experiments with the purpose of clarifying some physiological problems as well as to determine whether it would be possible to treat some cases of mechanical ascites by means of forming such a fistula" From this time until the present, physicians, surgeons, and laboratory investigators have been attracted by the thought that portal hypertension plays a contributing if not primary role in the formation of ascites in patients with cirrhosis Careful metabolic study of patients with cirrhosis has demonstrated that in many, formation of ascites can be controlled by a low sodium intake together with an adequate diet and a hygienic way of life Patients exist, however, whose ascites is troublesome and responds poorly to dietotherapy and salt restriction A few of these have been selected upon a purely experimental basis for portal decompression So far the results have only been encouraging enough to warrant portal decompression for ascites upon a controlled basis in a research environment In Figure 10-23 (*Left and Below*) and its legend is outlined the course of a patient whose massive ascites appears to have been controlled by portal decompression

## Miscellaneous Problems in Variceal Hemorrhage

SPONTANEOUS SUBSIDENCE OF VARICES From time to time well documented reports have appeared of patients whose varices have subsided upon a medical program This observation prompts two questions, first, should not all patients with varices that have bled be maintained under strict medical management for several months before decision is reached as to whether or not they should be subjected to elective portal decompression, and second, in what percentage of patients can the varices be relied upon to disappear and how can these patients be selected for medical rather than surgical management? These questions have been raised only to point out that the answers to them are not available at the present time In our experience, once large varices are demonstrated by roentgenography, they are probably permanent In Figure

Fig 10 23 Massive ascites and portal decompression (*Left*) Unretouched photograph of M B S, aged 50 who developed massive ascites owing to alcoholic nutritional cirrhosis of his liver (*Below*) Here are displayed in chart form the features of this patient s course Although his hepatic disease improved on a strict medical program over a six month period, his incapacitating ascites did not abate Because his serum bilirubin level was not seriously elevated (1 8 mg per 100 milliliters) and because he was able to maintain a very nearly normal serum albumin, he was accepted for an end to side portacaval shunt He did *well after operation for the first* four months but then began to reaccumulate troublesome amounts of ascites His serum albumin level had fallen however, to 2 6 gm per 100 milliliters This returned to normal on parenteral human albumin and stabilized upon an improved d etary program at 3 8 gm per 100 milliliters His ascites subsided appreciably and once again he was able to return to work as a salesman for a large regional brew ery

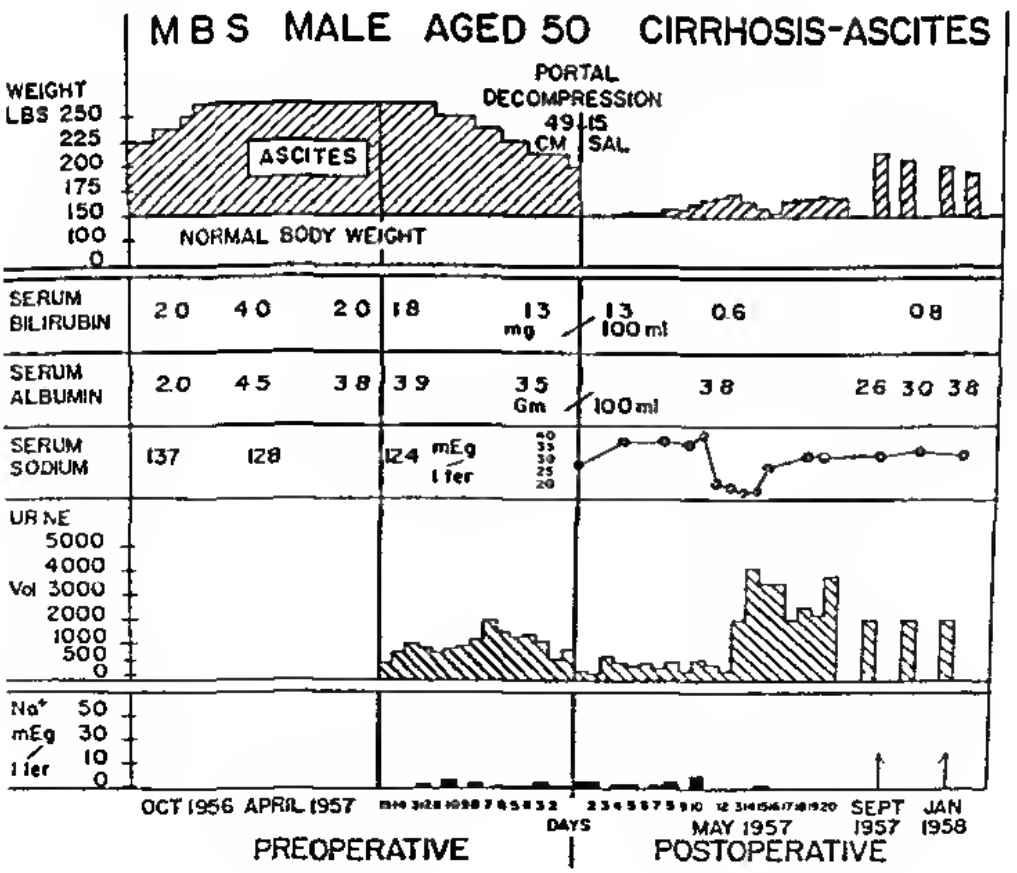

10 24 are reproduced the esophagograms of a patient at the beginning and end of a four year period On each examination the varices were quite as prominent as they had previously been Each time this man overindulged in alcohol he bled massively He survived each episode but after four massive hemorrhages in three years was persuaded to accept portal decompression His varices have now completely subsided and he has returned to his usual occupation

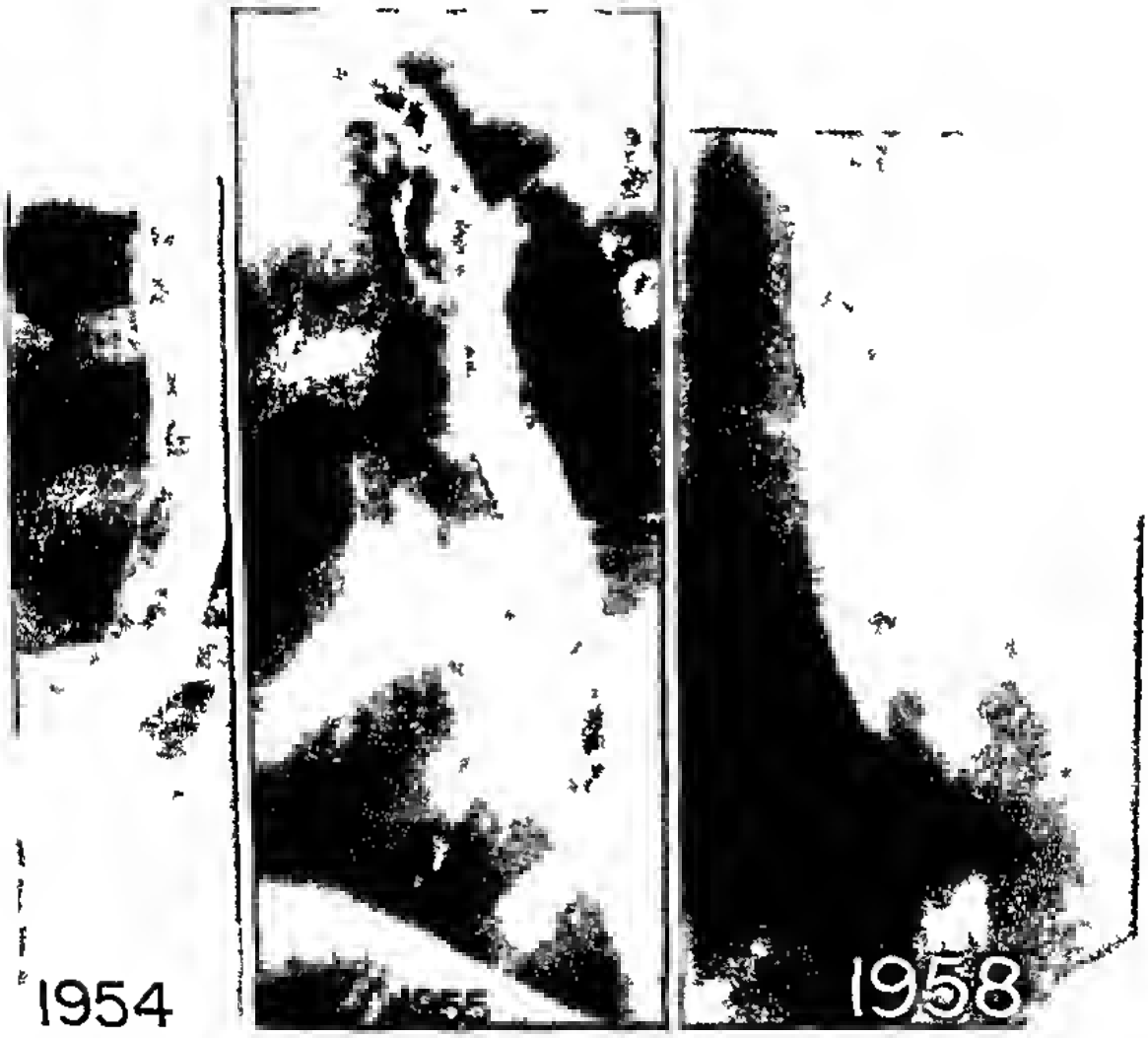


Fig 10 24 Serial esophagograms in a patient who steadfastly refused portal decompression for four years During this time he bled massively after each of four bouts of overindulgence in alcohol His varices have completely disappeared after successful portal decompression

VARICES AND NORMAL PORTAL PRESSURE As experience with bleeding varices is acquired every clinic encounters a rare individual with large varices in the presence of normal portal pressure It has been conjectured that varices under these circumstances are congenital that they have appeared during a period of transient hepatic disease or that they reflect a process as yet undefined When these varices bleed repeatedly, limited esophagogastrectomy appears warranted although apparently this operation does not guarantee protection from further hemorrhage

In spite of reasonable evidence that

esophageal varices do exist in the presence of normal portal pressure, we would like to suggest that whenever such a diagnosis is entertained extraordinary efforts be made to exclude some form of intra hepatic obstruction as the true reason for the varices A recent clinical experience provides ample basis for our skepticism as far as this particular group of patients is concerned Because of the unusual features

Fig 10 25 Portal venogram of a patient with huge varices and normal portal pressure A limited esophagogastrectomy and esophago jejunostomy was performed in this patient The varices did not even temporarily subside and he bled again four years after operation

encountered in this patient and the many lessons to be learned from his study we believe he merits a detailed report here

A A NECH No 103 274 was 33 years of age when he was referred to us because of repeated episodes of massive upper gastrointestinal hemorrhage Of interest in his past history was a splenectomy performed at the age of 15 years for hypersplenism He sustained his first hemorrhage at the age of 20-odd years and shortly after that hemorrhage esophageal varices were discovered on roentgenesophagography A few years later he was referred to us for treatment.

On physical examination A A was a thin but well developed man whose pallor gave evidence of recent blood loss His splenectomy wound was well healed All laboratory studies were negative He did not and as far as could be determined had never manifested any signs or symptoms of hepatic failure or protein intoxication Roentgenograms of his esophagus confirmed the presence of large varices

At operation a few days after admission A A s liver appeared normal and a portal venogram was interpreted as normal although note was made of an exceptionally large coronary vein (Fig 10 25) His portal pressure measured repeatedly to avoid any possible error was always 15 cm of saline Portal decompression was not considered appropriate because of his low portal pressure nor in view of the normal appearance of his portal venogram was his portal vein explored Instead limited esophagogastrectomy bilateral vagotomy, Finney pyloroplasty and esophagojejunostomy were performed in the belief that this operation would prevent further esophagogastric hemorrhage As an added protection the distal esophagus was invaginated deeply into the proximal jejunum hoping thereby to produce a valve that would be effective in preventing jejunoesophageal reflux (Fig 10 26) A A tolerated his procedure well recovered nicely and was discharged on his twentieth day after operation A roentgenogram of his esophagus obtained just before discharge disquieted us because his varices were quite as large as they had been just prior to operation Experience with similar operations had let us to believe that varices always disappeared promptly following esophagogastrectomy even though they might reappear later in the postoperative course Nevertheless we permitted A A to return home hoping that he might not bleed further

Although he did well gained weight and returned to work he continued to bleed periodically After two years he

returned to the hospital for further surgical intervention to check his repeated esophagogastric hemorrhages At this operation (our second, A A's third) his liver was again normal and portal venography once again disclosed what appeared to be a normal portal vein His portal pressure, however, was now 36 cm of saline Believing we were now justified in portal decompression, we proceeded to dissect this man's portal vein free of the other structures in his hepatoduodenal ligament Much to our chagrin we found his portal vein completely filled with old organized thrombus in which, however, there were many reconstituted vascular channels In toto, these were obviously adequate to provide a normal portal venogram when filled with abundant contrast media Much bleeding was encountered in trying to define the portal vein and in course, several transfixion sutures were tied deeply in thrombosed and partially canalized clot As a result of our efforts to outline this portal vein for anastomotic purposes, we proved that it was unsuitable for portal decompression and believed that we had undoubtedly initiated further thrombosis, perhaps even complete occlusion

Because a splenic vein was clearly unavailable and because a large superior mesenteric vein clearly was available, portal decompression was secured by an end-to-side caval-superior mesenteric venous shunt as originally described by Clatworthy This was commodious and reduced A A's portal pressure to 20 cm of saline Recovery from this operation was delayed by the development of bilateral thrombosis of the deep and superficial circulations of both legs Edema attendant upon this unfortunate complication subsided and A A was discharged home upon his twenty-first postoperative day, taking a general ward diet eagerly

At home his wife decided he urgently needed dietotherapy to "build him up" She embarked upon a high caloric, high protein, forced feeding diet consisting primarily of meat, eggs, and milk After three days, A A became lethargic, stuporous, and finally lapsed into coma Upon hospitalization, complete withdrawal of all protein from his diet, and 250 mg of oral Achromycin his sensorium rapidly cleared, his liver flap disappeared, and recovery appeared quite complete Ten days after admission he was discharged on Achromycin and 75 Gm of dietary protein a day At present, three months after operation, he is well and working, but requires neomycin and

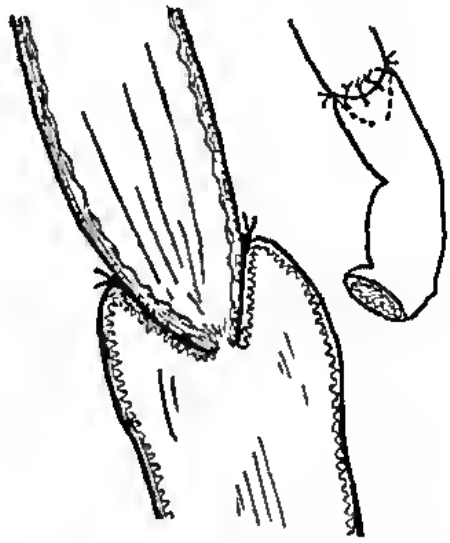

Fig 10 26 Diagrammatic representation of a valve fashioned in association with an esophagojejunostomy following esophagogastrectomy A number of reports indicate that this maneuver may be helpful in preventing esophagitis and varicoal hemorrhage following esophagojejunal anastomosis

limited protein to prevent recurrence of his episodic stuporous states Furthermore, his serum albumin persists at levels varying from 2 4 to 2 8 Gm per 100 milliliters

## Comment

This patient represents the fifth recorded instance* that we have found

* McDermott, W V A one-stage pancreaticoduodenectomy with resection of the portal vein for carcinoma of the pancreas, *Ann Surg 136* 1012, 1952

Hubbard, T B, Jr Carcinoma of the head of the pancreas Resection of the portal vein and portacaval shunt, *Ann Surg 147* 935, 1958

of an Eck fistula in a patient with a normal liver As in the other four instances, episodic stupor ("ammonia intoxication" and "protein intoxication") has been a discordant feature of this man's postoperative course In addition, A A evidences a pronounced tendency to protein deficiency as reflected in a persistently low serum albumin level, which so far has defied dietary correction Furthermore, were we to have opportunity to perform a

Fig 10 27 Portal venogram in portal thrombosis This portal venogram was obtained just prior to esophagogastrectomy in a young girl who continued to bleed from esophagogastric varices after a splenorenal shunt had failed

Clatworthy shunt again, we would certainly make an effort to bridge the gap between the distal and proximal vena cava by means of a crimped teflon prosthesis

"POSTSPLENECTOMY BLEEDERS" As a result of increased interest in treating patients with varices and hemorrhage secondary to portal thrombosis a group of individuals has emerged who for convenience have been designated post splenectomy bleeders These include patients whose spleens have been removed unwisely as a hopeful gesture to control esophagogastric hemorrhage, patients in whom splenectomy alone has been performed for hypersplenism, as well as those whose splenorenal shunts have failed and for whom no other opportunity for portal decompression exists These unfortunate persons present themselves with persistent varices and continuing bouts of esophagogastric hemorrhage The commonest effort made to prevent their recurrent hemorrhages has been esophagogastric resection limited to the terminal few centimeters of esophagus and upper third of stomach Originally enteric continuity was re established by esophagogastrostomy Because of a high incidence of peptic esophagitis, esophagojejunostomy has recently been more popular To preserve intrinsic gastric function, the stomach has been left in place and gastric emptying insured by a Finney pyloroplasty To help prevent jejunoesophageal regurgitation, a valve has been created at the junction of the esophagus and jejunum by inverting the former into the open end of the latter as diagrammatically portrayed in Figure 10 26 After this procedure, varices usually disappear temporarily, but reappear within a few months or a year or so Recurrent bleeding has been the rule rather than the exception In Figure 10 27 has been reproduced the portal venogram of a young girl whose splenorenal shunt for portal hypertension owing to portal thrombosis failed Esophagogastrectomy was performed in an effort to prevent her continuing varicoal hemorrhages In Figure 10 28*A*, *B* are reproduced her preoperative esophagogram and one obtained a year after operation The varices, readily seen in *A*, have disappeared in her postoperative film, *B* Slowly over the next four years varices in her lower esophagus reappeared in response to her persisting portal hypertension and once again she experienced repeated esophageal hemorrhage

HYPERSPLENISM Many patients with cirrhosis manifest splenomegaly and mild

degrees of hypersplenism Early in the development of the surgical treatment of variceal hemorrhage among these patients it was widely held that splenectomy should accompany portal decompression This belief obviously encouraged wider use of splenorenal rather than portacaval shunts In over a hundred patients with cirrhosis and splenomegaly, splenectomy has become necessary only once after an end to-side portacaval shunt has been performed for variceal hemorrhage This patient, a male, aged 48, developed extensive ecchymoses and bleeding from his gums two years after his portacaval shunt This was associated with low platelets, a white blood cell count of 2,000 per milliliter, anemia and a persistently elevated serum bilirubin These signs and symptoms subsided promptly after splenectomy Relevant data on this patient are displayed in Figure 10-29 Our experience indicates that after an effective end to side portacaval shunt, the spleen usually shrinks greatly in size and hypersplenism only very rarely becomes a problem requiring splenectomy

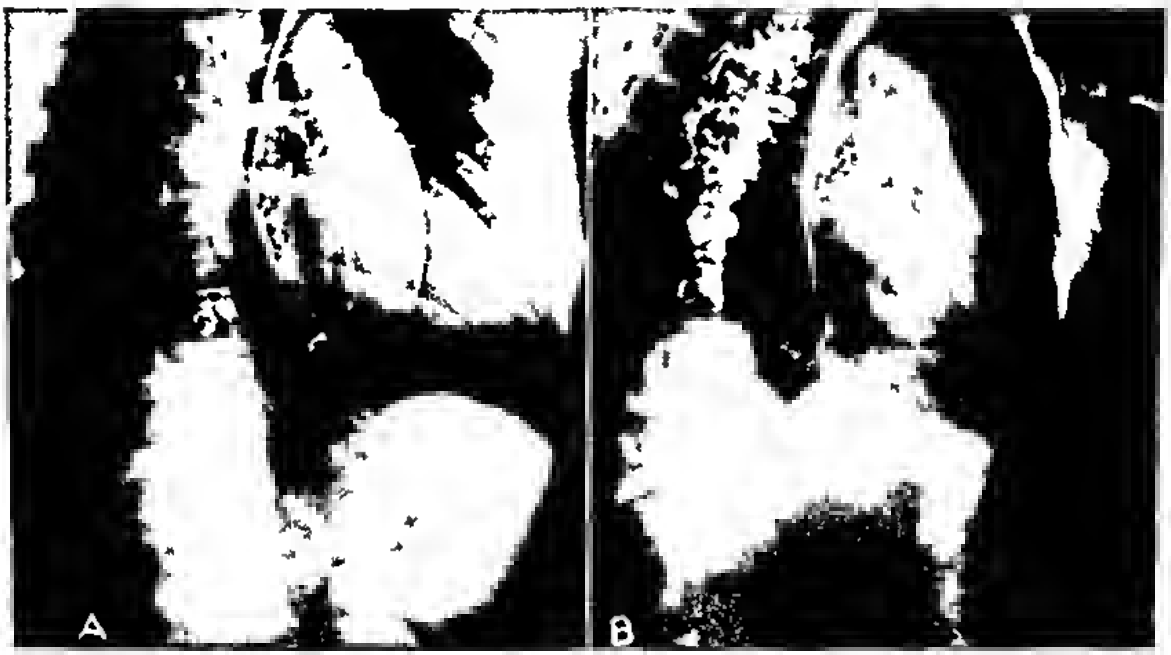


Fig 10 28 (*A*) Preoperative and (*B*) postoperative esophagograms in a young patient in whom an esophagogastrectomy and esophagojejunostomy was performed in an effort to prevent recurrent esophageal bleeding A splenorenal shunt had failed as had further attempts to secure adequate portal decompression

BILIARY CIRRHOSIS AND VARICEAL HEMORRHAGE Biliary cirrhosis, secondary to either intrahepatic or extrahepatic obstruction to biliary drainage, may, if longstanding, become complicated by portal hypertension, varices, and hemorrhage Two logical approaches to such patients may be taken One, their bleeding may be considered an immediate threat to life and portal decompression undertaken ahead of efforts to relieve the biliary obstruction, or the other, efforts to relieve biliary obstruction may precede portal decompression Which approach is employed will have to be individualized according to the needs of the particular patient For instance, a patient whose biliary obstruction is calcular should have his stone removed, hoping that as biliary cirrhosis subsides, portal pressure will fall, varices recede, and threat of hemorrhage vanish A patient, however, who has developed varices secondary to primary

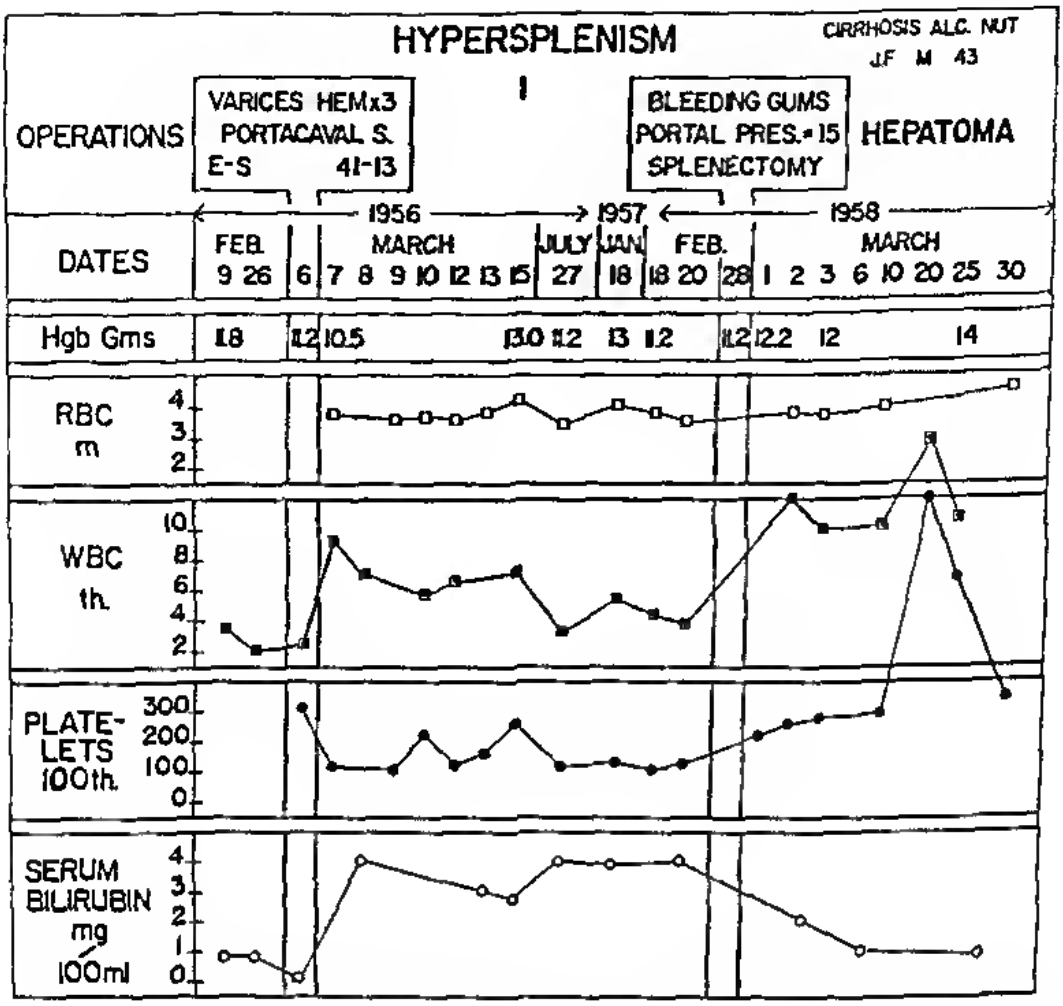


Fig 10 29 Hypersplenism requiring splenectomy following portal decompression by an end to side portacaval shunt Of nearly 100 patients with cirrhosis and splenomegaly whose portal circuits have been decompressed for bleeding varices by an end to-side portacaval shunt, the patient whose course is represented in this chart is the only one who required a postshunt splenectomy Two years after portal decompression he returned to the hospital with severe bleeding from his gums and extensive cutaneous ecchymoses His platelets and white blood cell count were depressed All his untoward signs and symptoms subsided after splenectomy His portal pressure at this time was normal but his spleen had decreased only to about half of its preshunt size Tragically enough, malignant hepatoma was discovered in both hepatic territories at the time of splenectomy

biliary cirrhosis or sclerosing cholangiolitis should not have portal decompression long delayed The most trying circumstance is in the patient whose common duct has been injured surgically and who presents with large varices, recurrent hemorrhage, and a common duct stricture that has been operated upon several times Here a shunt should be performed first Not only is the patient relieved of his immediate threat to life, but also repair of the common duct stricture can later be undertaken in a surgical field uncomplicated by portal hypertension

PORTAL HYPERTENSION IN CHILDHOOD Infants and small children who bleed from varices constitute a particularly difficult chapter in the management of portal hypertension Where this is secondary to extrahepatic block, attention was called earlier in this section to the importance of waiting until the child is

old enough to promise vessels of sufficient size for successful anastomosis Attention is drawn here to a group of children suffering from what, for lack of better, has been termed juvenile cirrhosis Here, more than in other patients with bleeding varices, splenoportography is particularly useful If the portal vein is normal and uncompromised by thrombosis, there is little reason to delay portal decompression In Figure 10-30 is reproduced the portal venogram of a child whose spleen was removed without a splenorenal shunt He promptly bled again and was assumed to be suffering from portal venous thrombosis At operation we were surprised to find a normal portal vein and so called juvenile cirrhosis This has been well without evidence of varices or hemorrhage for his first three postshunt years

LIGATION OF THE HEPATIC ARTERY In spite of reasonable physiologic evidence that ligature of the hepatic and splenic arteries may reduce portal pressure and in spite of a few early successes with this procedure, it has not survived as an important treatment of portal hypertension

GALLSTONES AND OTHER DISEASES OF THE GASTROINTESTINAL TRACT INCIDENTAL TO PORTAL HYPERTENSION From time to time other diseases of intra abdominal organs are associated with portal hypertension and bleeding varices The question arises whether a gallbladder full of stones should be removed concomitantly with portal decompression Cholecystectomy has been performed in these patients directly after portal decompression without untoward incident in the postoperative period A right hemicolectomy for carcinoid mistakenly thought to be carcinoma of the cecum has also been performed concomitantly with a portacaval shunt This patient is well three years after operation Although double headers generally do not have a place in abdominal surgery, the exigencies of the occasional patient may warrant performing two major operations at one time

HEPATOLENTICULAR DEGENERATION (WILSON'S SYNDROME) One of the recognized causes of death in patients with Wilson's Syndrome is massive variceal hemorrhage By the time patients with this illness have developed varices, their disease is usually too far advanced for relief of bleeding by portal decompression Occasionally, however, such patients will be encountered with sufficient hepatic reserve to warrant operation

Fig 10 30 Portal venogram in so called juvenile cirrhosis This 16 year old boy had splenectomy alone performed for variceal hemorrhage at the age of 12 years When first seen a few years later we were convinced that his variceal hemorrhages were due to portal thrombosis. Much to our surprise his portal vein was normal Three years ago he underwent an uneventful portacaval shunt His varices have disappeared and he has not bled since operation

ALCOHOLISM Throughout the history of patients with cirrhosis and variceal hemorrhage the abuse of alcohol plays such an important role that it merits brief comment Whether alcohol is a decisive etiologic factor in cirrhosis or whether it precipitates massive esophagogastric hemorrhage has yet to be decided The incidence of alcoholism among these patients varies from community to community, from city to city, from hospital to hospital, and from individual to in-

dividual Neither can we define the exact role alcohol does play, nor can we escape the conviction that the part it plays in precipitating variceal hemorrhage is significant Too often patients with varices bleed when they overindulge in alcohol Certain it is that hepatic decompensation may appear after a shunt as a result of continued use of alcohol

Portal decompression seems to be enough of a personal investment to encourage many patients to mend their alcoholic ways Physicians and surgeons alike should appreciate that most alcoholics desperately need sympathetic interest in their welfare Much can be accomplished postoperatively by continuing medical attention in the clinics and offices of those who have accepted portal decompression as an important surgical therapy Until the etiology and natural life history of Laennec s cirrhosis is more clearly understood alcoholism will continue to be a psychosomatic enigma in patients with bleeding esophagogastric varices owing to this form of hepatic disease

## TUMORS AND RESECTION OF THE LIVER

For years surgeons have known that hepatic tumors could be removed surrounded by reasonable margins of normal liver Original operations of this nature were generally restricted to local excision of small lesions or amputation of pedunculated ones When more ambitious resections were attempted mortality was high and success meager Recent appreciation that subtotal hepatectomy could be performed in accordance with surgical principles and anatomic facts has led to renewed interest in this subject Current success in dealing with tumors of the liver is evident from an increasing number of reports of right or left hepatectomy Clearly surgeons interested in surgery of the upper abdominal organs should be more conversant today than ever before with the problems of hepatic neoplasia and resection

### Hamartomas

Hamartomas of the liver are derived from one or more of the cellular elements comprising normal liver Their clinical and pathologic character depends upon the relative dominance of the cells of origin Although often regarded as benign neoplasms hamartomas more probably develop as a result of congenital hepatic dysplasia If primarily derived from bile ducts, the tumor is largely cystic if from blood vessels the common hepatic hemangioma results

Small hamartomas are encountered incidentally during abdominal operations large ones when they reach sufficient size to produce symptoms requiring surgical exploration In themselves the smaller variety are of no particular clinical significance When however they are encountered during operations for intra abdominal cancer, they may be mistaken for a metastasis

Sizable hamartomas present a variety of clinical problems The most terrifying occurs in hemangiomas when these rupture and bleed massively Less spectacular are solid tumors that develop insidiously and prompt the patient to seek medical attention only because of upper abdominal fullness and pain A palpable hepatic mass requires exploratory celiotomy if for no other reason than accurate diagnosis Occasionally such tumors can readily be removed Roentgen therapy has been used to promote sclerosis and shrinkage of the tumor either as a preoperative measure designed to facilitate removal or as definite therapy There is little doubt but that a greater number of these tumors will be removed as experience is acquired with resection of the liver

### Benign Neoplasms of the Liver

Benign neoplasms of the liver are rare Encapsulated adenomas composed of hepatic cells have been described as have been solid tumors composed primarily of bile ducts These can be removed by

enucleation or hepatic resection Uncommon indeed are papillomas arising from the epithelium of intrahepatic bile ducts When these occur, however, they are of immediate surgical significance for they obstruct the flow of bile, produce jaundice, and often become associated with ascending cholangitis In the past papillomas have usually been curetted away Because of a marked tendency to malignant degeneration, a more logical approach today would be subtotal hepatectomy provided the origin of the tumor could clearly be included in the resection

## Primary Malignant Tumors of the Liver

The principal types of primary malignant tumors of the liver are recognized hepatoma cholangioma, and endothelioma Hepatoma, the commonest of the three develops frequently in non neoplastic cellular dysplasias such as cirrhosis or hamartomas This highly malignant tumor is often multicentric in origin and extrahepatic vascular and lymphatic metastases are common Rarely such a tumor may be solitary and without evidence of metastases Under these fortuitous circumstances resection of a hepatic territory together with the tumor should be considered Similarly cholangiomas or endotheliomas may be solitary, limited to one hepatic territory, and amenable to surgical extirpation At best a surgeon may become suspicious that a patient is harboring hepatic cancer when his liver enlarges suddenly, hepatic function deteriorates rapidly, and fever and increasing abdominal pain make their appearance

Carcinoma of the intrahepatic bile ducts usually arises at the junction of the right and left main ducts and hepatectomy is rarely possible Such a tumor, arising in one or the other main ducts would, of course, be suitable for resection only if discovered before distant metastases had occurred Wider use of operative cholangiography may provide a means whereby these tumors can be detected early enough to warrant territorial resection

## Metastatic Cancer of the Liver

Fully 50 per cent of patients dying of cancer have metastatic deposits in their livers Conventionally metastatic cancer here has been considered therapeutically hopeless Both x ray treatment and chemotherapy have been found ineffective Rarely, of course, a large single metastasis to the liver has been successfully removed

Recently Warren Cole and his associates have taken a new approach to hepatic metastases from intra abdominal tumors In many of these cancers, malignant cells have been demonstrated invading the veins adjacent to the tumor as well as embolic in portal blood Cole has suggested that recently shed cancer cells might be destroyed by chemotherapeutic agents before they become established in the liver or elsewhere Intraoperative and postoperative chemotherapy of intra-abdominal cancer is now being studied intensively in a number of large clinics Whether or not this form of therapy will improve rates of survival among patients with intra abdominal cancers has not been determined

## Resection of the Liver

In original resections of substantial amounts of hepatic parenchyma, the liver was transected and then efforts were made to control the massive hemorrhage that ensued This was accomplished by a variety of mass ligatures or by one form or another of thermal or electric coagulation For instance, as long ago as 1899 W W Keen successfully resected by actual cautery the entire left half of the liver for a giant hemangioma Inevitably devitalized liver remained after these operations Infection, secondary hemorrhage, and biliary fistulas were often serious complications of these early methods of hepatic resection Little wonder that for many years removal of

significant amounts of liver was generally limited to pedunculated tumors, in which the control of hemorrhage was readily achieved Today improved anesthesia, availability of blood for transfusion, appreciation that large amounts of normal liver can be removed without inviting hepatic failure, and a clearer understanding of the anatomy of the hepatic blood vessels and ducts have all encouraged reconsideration of removal of large masses of liver Indications for hepatectomy include evacuation of traumatized or devitalized liver and resection for a variety of benign and malignant tumors

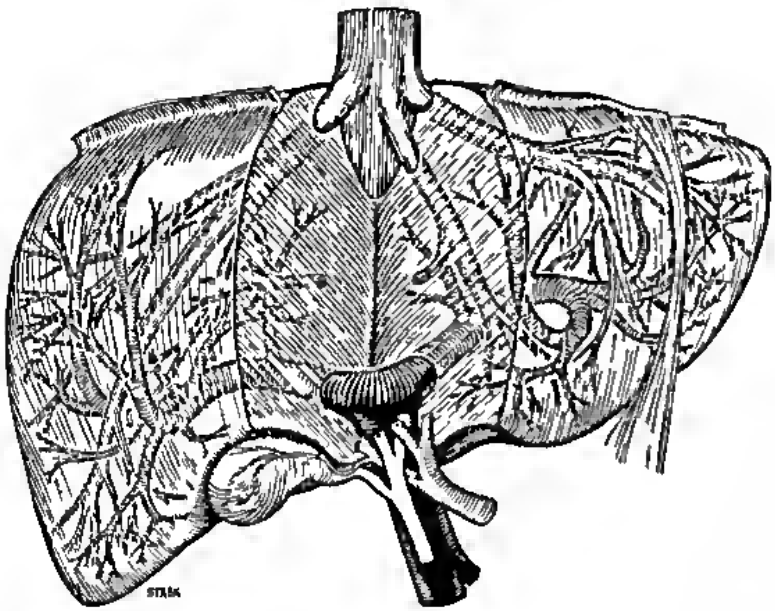

Fig 10 31 Intrahepatic surgical anatomy The liver is divided into two territories right and left These correspond primarily to the right and left divisions of the portal vein and hepatic artery The dividing line lies in a plane extending through the fossa of the gallbladder to the dome of the liver superiorly and to the anterior aspect of the vena cava posteriorly The dividing line between the two territories is not the falciform ligament (See text)

## Surgical Anatomy of the Liver

The liver consists of two territories right and left These are divided into segments each dependent upon a remarkably uniform arborization of portal vein, hepatic artery, and bile ducts A clear understanding of the relationships that these structures bear to the liver as a whole is prerequisite to hepatic resection

The division between the right and left territory lies in a plane extending obliquely from the fossa of the gallbladder to the dome of the liver and along the anterior aspect of the vena cava (Fig 10 31) The right territory consists of less than the conventional right lobe of the liver, while the left hepatic territory includes more than the conventional left lobe The right territory is composed of anterior and posterior segments to which run the anterior and posterior segmental branches of the right portal vein and hepatic artery The left hepatic territory includes a medial and a lateral segment The lateral segment lies to the left of the falciform ligament and represents the conventional left lobe of the liver The medial segment of the left hepatic territory lies to the right of the falciform ligament and comprises that portion of the liver referred to as the quadrate lobe The left territory is supplied by branches of the left portal vein and hepatic artery These vessels divide into two major groups, one turns anterior and toward the right to supply the medial segment of the left territory The other penetrates the lateral segment (i e, the conventional left lobe of the liver) The caudate lobe of the liver is independent, save by proximity, of either right or left territory Its blood supply arises from near the bifurcation of the main portal trunk (Fig 10 32)

There are three major hepatic veins, the right drains the right hepatic territory and enters the right lateroventral aspect

of the vena cava, the middle drains a small segment of the anterior right territory and the medial segment of the left territory and enters the vena cava in the mid line ventrally, the left hepatic vein drains the conventional left lobe of the liver (i e, the lateral segment of the left hepatic territory) and enters the vena cava just to the left of its mid ventral line The middle hepatic vein lies close to the interterritorial plane Whereas the portal vein, hepatic arteries, and bile ducts are remarkably constant within the liver, hepatic venous drainage is inconstant. As Lloyd Davies and Angell have shown, there is always a large right and a smaller left hepatic vein The variations are found in the middle hepatic vein It may be absent, may drain a substantial part of the right territory, or may be the major drainage of the entire left territory Instead of entering the vena cava independently, it may join the left hepatic vein

## Hepatic Resection

Resections of the liver other than biopsies or removal of small wedges of hepatic tissue are primarily concerned with amputation of the right or left territory General anesthesia administered by endotracheal tube is preferred This may be supplemented by hypothermia or hypotensive drugs although the importance of these agents in surgery of the liver in man has yet to be universally accepted Access to the right hepatic territory is most easily gained through a generous right combined abdominothoracic incision

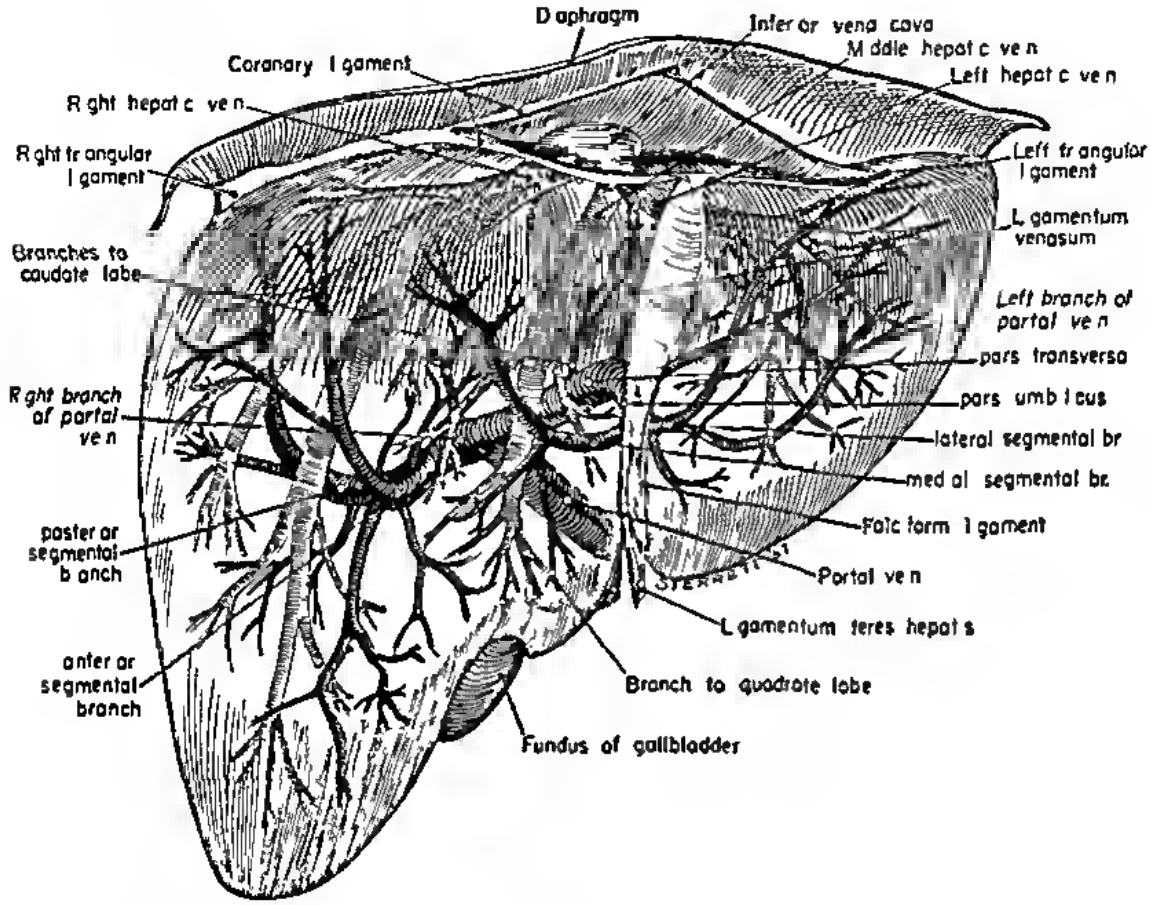


Fig 10 32 The liver in transparency to show the branching and relative position of the parts of the portal and hepatic veins (*Reproduced by permission from* N A. Goldsmith, and R T Woodburne *Surgery, Gynecology, and Obstetrics 105* 310 1957 )

The left lobe of the liver is most readily approached through a mid line incision dividing the lower sternum if additional exposure is necessary

In removal of the right hepatic territory, the liver is depressed exposing the triangular ligament This is divided The right half of the liver may then be rotated upward and the hepatorenal ligament incised The hilar structures are separated and the afferent vessels and

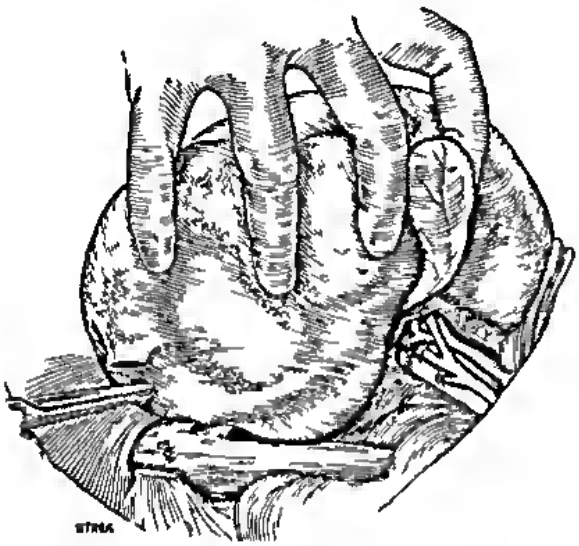

Fig 10 33 Resection of the right hepatic territory In this semidiagrammatic representation of a right hepatectomy an effort is made to display division of the hilar structures followed by ligation of the right hepatic vein The controversial middle hepatic vein is evident as is the left hepatic vein Complete division of the triangular ligament permits extensive mobilization of the right half of the liver (See text)

ducts of the right territory appropriately divided and ligated (Fig 10-33) The right and left territories are teased apart by blunt dissection slightly to the right of the interterritorial plane This line of division is chosen rather than the interterritorial plane itself to preserve the middle hepatic vein This vessel must be preserved if venous drainage of the medial segment of the left territory is to be assured Small bleeding points in the raw surface of the left territory are easily controlled by ligature or electrocoagulation The right hepatic vein is identified ligated flush with the vena cava and the right territorial mass of liver removed

Similar principles are followed in removing the left hepatic territory Its suspensory ligament is incised The structures of the hilus are identified and the afferent vessels and left hepatic duct ligated and divided The liver is split just to the left of the interterritorial plane in an effort to preserve the middle hepatic vein Because of variations in the middle hepatic vein, its preservation may not always be feasible In this eventuality the remaining segments of the right territory should be carefully observed for evidence of venous infarction If this occurs along the line of resection additional amounts of liver may have to be removed independently Finally the left hepatic vein is divided and the left territory removed

After resection of either territory reperitonealization is not practical Multiple cigarette drains are left to the raw surface of the left hepatic territory and brought out deeply in the right flank (see Fig 10 8) Drains after resection of the left territory are brought out anteriorly

## REFERENCES

### Congenital Malformations of Liver, Bile Ducts, and Hepatic Vasculature

Grant J L Fitts W T Jr and Ravdin I S Aneurysm of the hepatic artery *Surg Gynec & Obst 91* 527, 1950

Katz H J and Williams A J Accessory lobes of liver and their significance in roentgen diagnosis *Ann Int Med 36* 880 1952

Kirklin J W Shocket, E Comfort, M W and Huizenga K A Treatment of aneurysm of the hepatic artery by excision *Ann Surg 142* 110 1955

### Trauma of the Liver

Henson S W Jr Hallenbeck G A Gray, H K and Dockerty M B Benign tumors of the liver *Surg Gynec & Obst 104* 302 1957

Mikesky, W E Howard J M, and De Bakey M L Injuries of the liver in 300

consecutive patients *Internat Abstr Surg 103* 323, 1956

SHACKELFORD, R T, and MARBURY, W B, JR Left hepatic lobectomy for external biliary fistula *Ann Surg 144* 245, 1956

SPARKMAN, R S Massive hemobilia following traumatic rupture of the liver *Ann Surg 138* 899, 1953

SPARKMAN, R S, and FOGELMAN, M J Wounds of the liver *Ann Surg 139* 690, 1954

SPECTOR, N Ligation of the right hepatic artery in hemobilia *Ann Surg 145* 244, 1957

WRIGHT, L T, PRIGOT, A, and HILL, L M, JR Traumatic rupture of the liver without penetrating wounds *Arch Surg 54* 613, 1947

## Abscesses of the Liver

DEW, H R "Hydatid Disease of the Abdomen," in MAINGOT, R *Abdominal Operations*, ed 3, New York, Appleton Century Crofts, 1955, p 869

OCHSNER, A, and DEBAKEY, M Amebic hepatitis and hepatic abscess *Surgery 13* 460, 612, 1943

OCHSNER, A, DEBAKEY, M, and MURRAY S Pyogenic abscess of the liver *Am J Surg 40* 292, 1938

## Portal Hypertension and Esophagogastric Varices

BLAKEMORE, A H Portacaval shunting for portal hypertension *Surg Gynec & Obst 94* 443, 1952

CHILD, C G Eck's fistula *Surg Gynec & Obst 96* 375, 1953

CHILD, C G The portal circulation *New England J Med 252* 837, 1955

CLATWORTHY, H W, JR, WALL, T, and WATMAN, R N A new type of portal to-systemic venous shunt for portal hypertension. *A M A Arch Surg 71* 588, 1955

DAVIDSON, C S Cirrhosis of the liver *Disease-a Month*, 1–35 (September), 1957

DUBUQUE, T J, MULLIGAN, L V, and NEVILLE, E C Gastric secretion and peptic ulceration in dogs with portal obstruction and portacaval anastomoses *Surgical Forum, American College of Surgeons 8* 211, 1958

EISENMENGER, W. J, and NICKEL, W. F Relationship of portal hypertension to ascites in Laennec's cirrhosis *Am J. Med 20* 879, 1956

ELLIS, D S, LINTON, R R, and JONES, C M Effect of venous-shunt surgery on liver function in patients with portal hypertension *New England J Med 254* 931, 1956

FINGSTRAND, L, and FRIBERG, O On the function of the liver as affected by various operations and anesthetics *Acta chir scandinav 92* 1, (Supp 104), 1945

JULIAN, O C Choice of operation in portal hypertension with varices Editorial *Surg Gynec & Obst 100* 753, 1955

LI, T H, and EISTEN, B E Effect of cyclopropane anesthesia on cardiac output and related hemodynamics in man. *Anesthesiology 18* 15, 1957

LINTON, R R The selection of patients for portacaval shunts *Ann Surg 134* 433, 1951

LINTON, R R, and ELLIS, D S Emergency and definitive treatment of bleeding esophageal varices *J A M A 160* 1017, 1956

LONGMIRE, W P, JR, MULDER, D G, MAHONEY, P S, and MELLINKOFF, S W Side-to side portacaval anastomosis for portal hypertension *Ann Surg 147* 881, 1958

MCDERMOTT, W V, JR, WAREHAM, J, and RIDDLE, A G Bleeding esophageal varices *Ann Surg 144* 318, 1956

PATEK, A J *et al* Dietary treatment of cirrhosis of the liver *J A M A 138* 543, 1948

RAVDIN, I S The complexity of liver disease, surgical steps toward solution *Ann R Coll Surgeons England, 20* 71, 1957

ROUSSELOT, L M Autogenous vein grafts in splenorenal anastomosis *Surgery, 31* 403, 1952

WATSON, CECIL Current status of treatment of cirrhosis of the liver *J A M A 166* 764, 1958

WELCH, C S *et al* Treatment of bleeding from portal hypertension in patients with cirrhosis of the liver *New England J Med 254* 493, 1956

WELCH, C S, and RAMOS, A G Results of portacaval shunts in the treatment of portal hypertension *Surgery 41* 756, 1957

WHIPPLE, A O The problem of portal hypertension in relation to the hepatosplenopathies *Ann Surg 122* 449, 1945

## Tumors and Resection of the Liver

GOLDSMITH, N A, and WOODBURNE, R T The surgical anatomy pertaining to liver re-

section *Surg Gynec & Obst 105* 310, 1957

KEEN, W W Report of a case of resection of the liver for the removal of a neoplasm, with a table of seventy six cases of resection of the liver for hepatic tumors *Ann Surg 30* 267, 1899

LLOYD DAVIS, O V, and ANGELL, J C Right hepatic lobectomy *Brit J Surg 45* 113, 1957

McDONALD G O, LIVINGSTON, C, BOYLES C F, and COLE, W H The prophylactic treatment of malignant disease with nitrogen mustard and triethylenethiophosphoramide *Ann Surg 145* 624, 1957

## General

CHILD, C G *The Hepatic Circulation and Portal Hypertension* Philadelphia, W B Saunders Company, 1954

POPPER, H, and SCHAFFNER, F *Liver Structure and Function* New York, McGraw Hill Book Co, 1957

SCHIFF, LEON *Diseases of the Liver* Philadelphia, J B Lippincott, 1956

SHACKELFORD, R T *Surgery of the Alimentary Tract*, vol 1 Philadelphia, W B Saunders Company, 1955

ROBBINS, S L *Textbook of Pathology* Philadelphia, W B Saunders Company, 1957

CHAPTER 11

# SURGERY OF THE GALLBLADDER

*Frank Glenn*

In 1867 Doctor John S Bobbs did a cholecystostomy for a large hydrops of the gallbladder Fifteen years later Langenbuch performed cholecystectomy In 1890 Kummel successfully removed calculi from the common duct Thus there were introduced within a period of less than 25 years the three operations still most frequently employed in the surgical treatment of biliary tract disease Fifty years ago each procedure was associated with a mortality rate that justified prolonged deliberation before embarking upon it Great strides have been made during the past half century Thus it has come about that indicated surgical operations can be successfully accomplished with increasing safety and minimal discomfort for an ever increasing number of patients Thorough evaluation good preoperative preparation careful meticulous surgery, and precision management thereafter should provide for further reduction in risk of operation

It is estimated that 10 per cent of our entire population of 171 million have gallstones and 20 per cent of those over 40 (approximately 8 million) In recent years, because of decreased risk of operation and the large proportion (85 to 90 per cent) who gain relief of their major symptoms by surgical therapy, it has come to be almost universally accepted as the treatment of choice For these reasons operations upon the biliary tract are among those most frequently performed in hospitals throughout this country Cholecystectomy is by far the most commonly employed procedure Perhaps 20 per cent of patients undergoing cholecystectomy are subjected to choledochotomy at the same time

Gallstones are present in over 90 per cent of patients with biliary tract disease Until we have a practical means of preventing the formation of gallstones it is incumbent upon the surgeons to be ever mindful of the procedures they do in their surgical treatment An evaluation of the disturbed physiology associated with nonmalignant disease of the biliary tract and the additional burden that operation may add even momentarily in attempts at its correction is required in each patient if the optimal results are to be attained Preservation and extension of the life span and restoration of function with relief of symptoms are the objectives of those who care for these patients

## ANATOMY AND PHYSIOLOGY

The biliary system includes (1) the intrahepatic ducts that receive bile secreted

from the liver cells, (2) the extrahepatic ductal system that begins usually at the junction of the right and left hepatic ducts to form the common hepatic duct, 2 to 4 cm in length Its junction with the cystic duct marks the beginning of the common bile duct The common bile duct varies from 8 to 13 cm in length and empties into the descending or second portion of the duodenum through the papilla of Vater The chief function of the biliary tract is to receive the bile

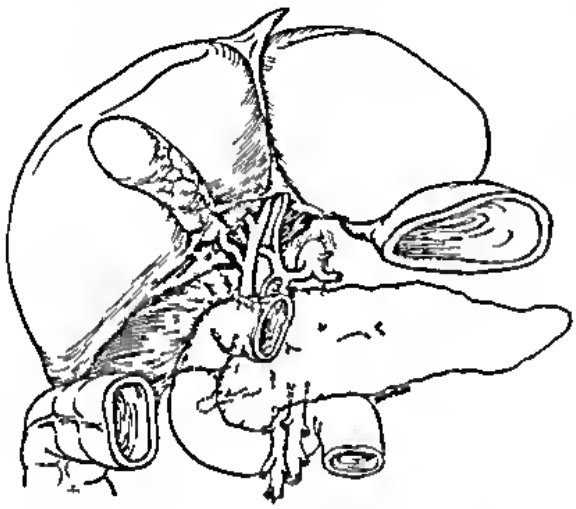

Fig 11 1 Anatomy and physiology of the gallbladder Normal anatomical relationships prevail in less than 70% of patients Alertness to variations and positive identification before division of any structure in this area provide safety from inadvertent injury to blood vessels, the ductal system, and adjacent structures

from the liver where it is produced at an almost constant rate, and deliver it to the duodenum as it is needed for the digestive process of food that is taken at intervals in varying amounts In the course of the accomplishment of this function bile is concentrated and stored in the gallbladder until needed

BILE PRODUCTION Bile as it is produced in the liver is a light orange color, alkaline in reaction and varies from 1 009 to 1 013 specific gravity The secretion of bile in the liver is continuous and for practical consideration at a constant rate It is estimated that 750 to 1000 cc or more is secreted per 24 hours It is made up of the tabulated substances, with the approximate proportions

These salts are essential to the digestion of fats, producing a detergent effect upon them that facilitates the action of the lipase to break them down

Bile salts are formed in the liver cells and secreted into the bile In the intestine they aid in emulsification of the fats and with them are absorbed by the intestinal mucosa into the blood Here, free of fat they are re excreted by the liver cells This circulation of the bile salts is accompanied by some loss through the feces The administration of bile salts by mouth increases only slightly the total amount in their internal secretion It is believed that the greater the amount of bile salts the less tendency there is for cholesterol to become sufficiently concentrated to form stones

Bile pigment is excreted by the liver It is derived for the most part from hemoglobin that is liberated from the red cells and returned to the blood stream by the reticuloendothelial system The liver cells excrete most of it as bilirubin while a small portion is oxidized to biliverdin Further reduction provides the pigments known as urobilinogen, the formation that is facilitated by bacterial action in the intestine Reabsorption of urobilinogen through the intestinal wall into the blood for reexcretion in the liver is known as the interohepatic bile circulation

Bile secreted into the canaliculi of the ductal system passes into the common duct and into the gallbladder through the cystic duct or into the duodenum through the sphincter of Oddi This outlet is closed except for short periods following the ingestion of food when it relaxes to permit the bile to flow into the duodenum to mix with the gastric contents as they move from the stomach When the sphincter of Oddi is closed, the bile that is being produced at a relatively constant rate passes from the common duct into the gallbladder through the cystic duct Water is absorbed from the thin liver bile and it is thus concentrated to a

dark green, viscid "gallbladder" bile with a specific gravity of 1 026 to 1 030 Ordinarily 300 cc of liver bile will be reduced to 60 cc of gallbladder bile The gallbladder of the person of average size will readily store 60 to 75 cc of concentrated bile

As water is absorbed from the bile by the mucosal surface of the gallbladder, mucus is secreted This provides a mucoid-like consistency to the bile, probably enhancing its ready flow through the cystic duct and lower common duct into the duodenum where it is needed In addition this same material may well protect the delicate mucosal surface of the gallbladder wall from the irritating properties of the concentrated bile

The concentration of the liver bile in the gallbladder and its subsequent passage into the duodenum may be nicely followed by cholecystography as demonstrated by Graham, Cole, and Copher Bile containing radiopaque material is to be observed becoming concentrated over a 12 hour fasting period Then on the oral administration of fatty foods the gallbladder empties and the radiopaque material contained in the bile is seen to pass into the duodenum It is generally agreed that a hormone, cholecystokinin is liberated in the duodenal mucosa to enter the blood stream when fatty food enters the duodenum The blood borne cholecystokinin when it reaches the gallbladder musculature causes its tone to increase while at the same time there is relaxation of the sphincter of Oddi Thus optimal conditions are brought about for concentrated "gallbladder bile" to be evacuated from the gallbladder through the cystic duct into the distal common duct, where it passes into the duodenum

If one looks upon the main function of the extrahepatic biliary tract as being that of providing for the collection of bile from the liver where it is being constantly secreted and its delivery to the duodenum through the sphincter of Oddi at variable intervals then the importance of obstruction anywhere within it becomes evident Obstruction is associated with most diseases of the biliary tract. In certain instances it marks the beginning, in some the intermittent interruption of bile flow parallels clinical episodes of illness, and in still others it represents the terminal phase of a pathological process The term "obstruction in the biliary tract" is a comprehensive one It ranges from sluggish emptying of the gallbladder, sometimes referred to as abnormal stasis as observed in some pregnant women, to partial or complete obliteration of the lumen of any

TABLE 11 1 THE COMPOSITION OF BILE*

| | *Liver bile* | *Gallbladder bile* |
|---|---|---|
| Sp gr | 1 009 1 013 | 1 026–1 032 |
| pH | 7 1 8 5 | 5 5 7 7 |
| Total solids (%) | 1 3 5 | 4 17 |
| Mucin (%) | 0 1–0 9 | 1 4 |
| Bile acids (%) | 0 2 2 | 1 5 10 |
| Bile pigment (%) | 0 05 0 17 | 0 2 1 5 |
| Total lipid (%) | 0 1 0 5 | 1 8–4 7 |
| Cholesterol (%) | 0 05–0 17 | 0 2–0 9 |
| Phosphatide (%) | 0 05 0 08 | 0 2 0 5 |
| Inorganic (%) | 0 2 0 9 | 0 5 1 1 |
| Total base (mEq /liter) | 150–180 | |
| Chloride (mEq /liter) | 75 110 | 15 30 |
| Calcium (mg %) | 4 9 | 10 14 |
| Iron (mg %) | 0 03 7 | |

* From Cantarow and Scheparts *Biochemistry* 5 h ed published by W B Saunders 1954 p 267

part of the ductal system by inflammation, calculous material or new growth The recognition and correction of the processes associated with interference of normal biliary tract function has in recent decades become much more efficient Studies and investigation directed toward prevention, however have not been very productive

## CONGENITAL ANOMALIES OF THE GALLBLADDER

Malformations of the extrahepatic biliary system and its associated blood vascular system have been widely described and discussed For the surgeon these are of first importance because a knowledge of them should be his greatest insurance of avoiding their injury during operation In comparison to the anomalies of the ductal system and nearby blood vessels anomalies of the gallbladder are rare Thus although very interesting they do not present a major problem Less than 200 cases have been reported in the literature

Congenital anomalies of the gallbladder according to Boyden may be described under four genetic groups Because all seem to originate early in embryonic life it is of some importance to begin with the analogue from which the gallbladder has its origin This recognizable structure the hepatic diverticulum of the foregut may be traced as the origin of the liver and bile ducts as well as the gallbladder At one stage the gallbladder and cystic duct are a solid cord of cells Failure of normal development from this phase may result in the four types of anomalies that we are concerned with They are (1) complete agenesis (2) duplication—bilobing which is partial duplication (3) diverticulae and (4) malposition

### Complete Agenesis

If at the stage when the structure that gives rise to the gallbladder and cystic duct is but a cord of cells there is arrest of development, then there will be a total absence of the gallbladder This may occur with an intact and normal biliary ductal system and liver However, anomalies of the ductal system are more frequently encountered with the absence of the gallbladder than a normal ductal system In a review of reported cases we have been able to find less than 50 patients who had a normal ductal system without a gallbladder Cholecystography and intravenous cholangiography may suggest the absence of a gallbladder but actual determination is dependent upon findings at operation or post mortem About half of the cases reported have come to attention because of stones in the common duct The rarity of an absent gallbladder with a normal ductal system is emphasized by Boyden who reported only two instances among 9 221 cadavers carefully examined in anatomic laboratories in this country Perhaps operative cholangiography will enable surgeons to establish this diagnosis with greater certainty in the future

### Duplication Double Gallbladder Bilobed Gallbladder

Double gallbladders each with a separate cavity and cystic duct are rare Gross has collected 28 cases from the literature Both gallbladders may function but usually one functions well and the other does not Stones have been found in both at the same time If both function they may be demonstrated by cholecystography Most of those reported have been encountered unexpectedly at operation or post mortem examination Boyden was able to find only five cases of double gallbladders among 19 000 cadavers described in a number of medical schools in this country

The bilobed gallbladder is partially or completely divided into two cavities by a longitudinal septum Usually the septum is complete at the fundus portion fades out as the neck is approached and provides for a common channel of exit through a single cystic duct. This anomaly may be diagnosed by cholecystography

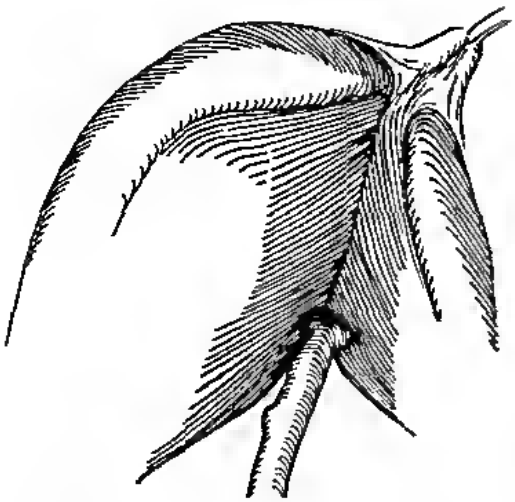

Fig 11 2 Complete agenesis with normal ductal system

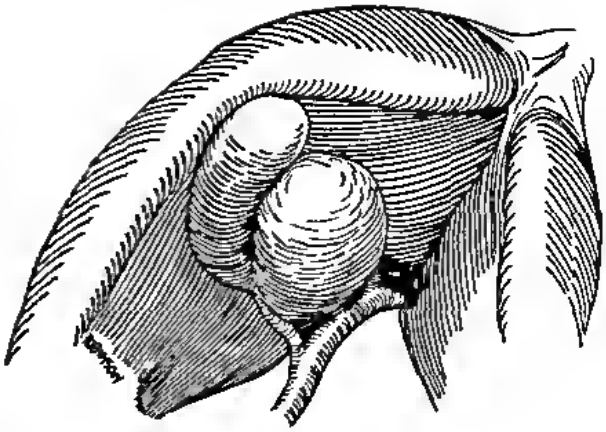

Fig 11 3 Duplication double gallbladder Both may function but usually only one does

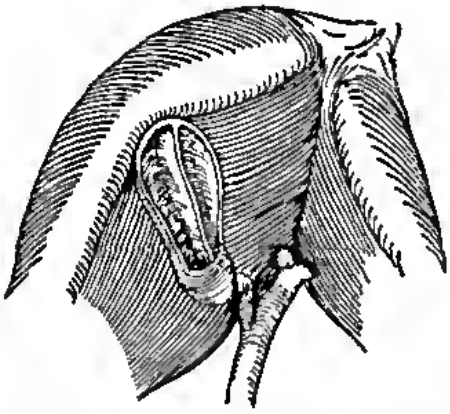

Fig 11 4 Duplication bilobed gallbladder with one cystic duct divided by longitudinal septum

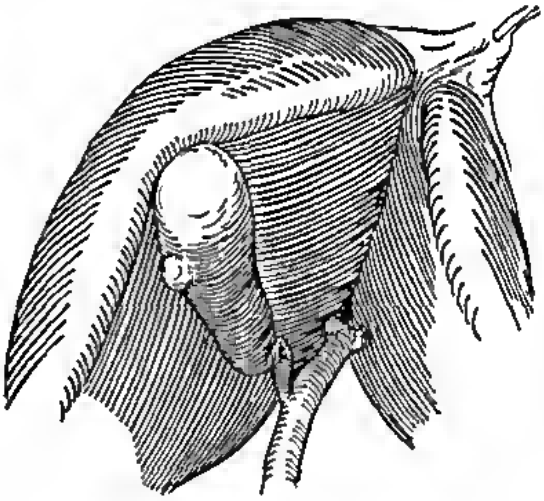

Fig 11 5 Congenital diverticula of the gall bladder wall

Gallstones have been found in one or both cavities Only a few cases have been reported

Anomalies of duplication, double gall bladder and bilobed gallbladder, may be demonstrated by cholecystography in the course of a complete clinical evaluation If they contain no stones and are not causing symptoms they should be left alone However, if stones are present anywhere within the biliary tract or if there is evidence of inflammation surgery should be embarked upon

## Diverticulae

Gross diverticulae of the gallbladder wall may occur from the neck to the fundus Those near the neck and ampulla on the hepatic aspect are probably occluded cystohepatic ducts True diverticulae have been observed on the exposed surface of the gallbladder Whether or not the phrygian cap gallbladder is an example of such a diverticula or whether it is an acquired deformity resulting from disturbance of function is debatable

Diverticulae of the gallbladder unassociated with stones or symptoms relative to the biliary tract are not an indication for cholecystectomy

## Malposition

A normal gallbladder may occupy an anomalous position and thereby be con-

sidered an anomaly The commoner of these locations include

a Within the substance of the liver
b Inferior aspect of left lobe of the liver
c Posterior and inferior aspect of right lobe of the liver
d Horizontal in transverse fissure of the liver

The floating gallbladder' is of clinical importance It lacks fixation to the liver

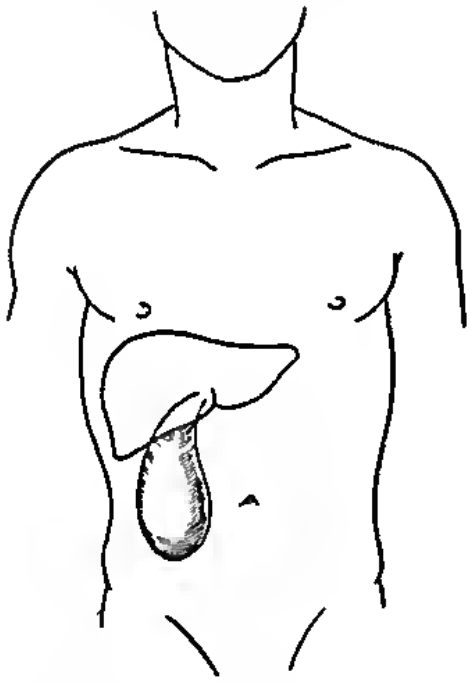

Fig 11 6 Floating gallbladder Markedly enlarged, distended gallbladder suspended on mesenteric pedicle

and is suspended by a mesentery and cystic duct and vessels It may become twisted with impairment of its blood supply Because of poor emptying it gradually increases in size and may become greatly enlarged The term 'phantom tumor' is associated with this condition When distended it may protrude into the pelvis or across the mid line to the left abdomen

Because the floating gallbladder usually functions poorly and is subject to impairment of its blood supply, it should be removed regardless of whether or not it contains stones.

## STONE FORMATION

The normal physiology of the gall bladder and biliary ductal system may be impaired by bile stasis or obstruction associated with infection, calculi, or neoplasm Although restoration of normal function of all parts is theoretically desirable, from a practical viewpoint relief of symptoms arising from these conditions and the maintenance of a free flow of bile from the liver to the duodenum are the more important A gallbladder with partial or complete loss of function that contains stones and is the site of infection may be removed the removal followed by restoration of health The common bile duct then takes over some of the functions of the gallbladder and the patient is in no way disturbed by its absence On the other hand obstruction of the common duct must be approached by removal of the cause while at the same time its integrity as a conduit system is maintained

Stone formation is associated with over 90 per cent of all biliary tract disease Gallstones may form anywhere within the ductal system but most originate in the gallbladder Calculi tend to increase in size and number with the lapse of time It is well established that the longer stones have been present in the gallbladder the greater is the incidence of stones in the common duct Our knowledge about the etiology of stones leaves much to be desired It is known that alterations of normal bile metabolism infection, and stasis are intimately associated in stone formation

### Disturbance of Bile Metabolism

Excessive red cell destruction as is to be observed in congenital hemolytic anemia, sickle cell anemia and similar disorders causes a great increase in the bilirubin excreted in the bile Stones composed chiefly of bilirubin are believed to form by crystallization as a result of hyperconcentration Cholesterol stones are sometimes associated with hypercholesterolemia Bile acids tend to keep the

cholesterol of bile in solution and in normal bile the ratio is 20 1 If the ratio is reduced to 13 1, as may occur during the concentration of bile in the gallbladder, cholesterol precipitates out in crystalline form Once there is a nucleus of such crystals, deposition of the constituents of bile upon them results in an increase in size of the stone thus formed

### Infection

Although bacteria may be isolated from bile of a normal biliary tract, they are not ordinarily retained in the wall of the gall bladder or ductal system In biliary tract disease bacteria can be isolated from 50 per cent and more of gallbladders removed at operation and from 20 per cent of gallstones Streptococci, *Escherichia coli*, and various members of the typhoid group are most frequently identified, however, many other organisms may be encountered including staphylococci Blood borne organisms as well as ascending infection that extends from the papilla of Vater to the gallbladder and smaller tributaries and canaliculi within the liver, combined with stasis and high concentrations of precipitable substances in the bile, would seem to provide optimum conditions for gallstone formation

### Stasis

There are few available specific data concerning stasis of bile alone in the biliary tract without other evident co existing abnormalities It has been demonstrated that during pregnancy the gallbladder often appears larger than normal as visualized by cholecystography and its emptying is sluggish While it is true that all pregnant women do not develop gallstones, the fact that three out of each four women who have gallstones have had one or more pregnancies is highly suggestive of a direct relationship It seems reasonable to conclude that a disturbance in bile metabolism and stasis, both of which may occur during pregnancy, are two important factors

Variations from the normal physiologic pattern of function in the liver, gallbladder, and ductal system may favor gallstone formation Whether in the beginning these be temporary periods of short duration it is difficult to say However, once calcareous material is precipitated out of the bile it is reasonable to assume that the pathologic processes associated with gallstones continues in a progressive manner The interruption of nonmalignant disease of the biliary tract surgically is directed therefore at first removing the gallbladder where stones are usually first formed and secondly removing stones or obstruction within the ductal system

On microscopic examination not all but by far the vast majority of gallbladders containing stones reveal scarring from or evidence of acute or chronic infection Cholelithiasis and impaired function as well as infection are indications for cholecystectomy Under certain circumstances, as in acute obstructive cholecystitis in an elderly and poor-risk patient, cholecystostomy with removal of calculi alone may be done Such a gallbladder should be removed later We have found in our experience that 50 per cent of patients who have had cholecystostomy with removal of stones will, if the gallbladder remains, form additional calculi within two years

## FOUR STAGES OF BILIARY TRACT DISEASE

The pathogenesis of calcareous biliary tract disease lends itself to division into four stages These can be readily demonstrated by the clinical symptoms and findings they give rise to and/or the pathologic changes that are to be observed at operation or postmortem These occur in sequence and the changes that take place are in a sense accumulative, thus findings of the later stages are superimposed upon the earlier In general these changes are not reversible Each stage may undergo phases from which it recovers with or without structural changes For example, acute obstructive cholecystitis may occur in any of the four stages, reach a peak of

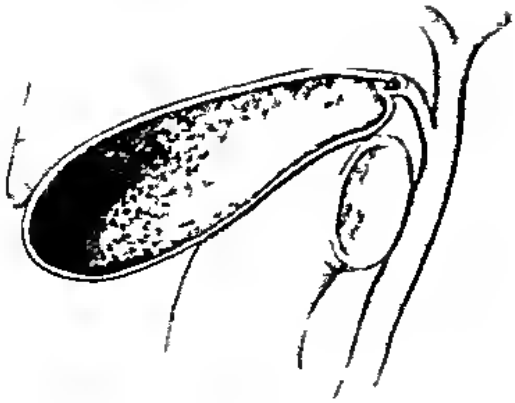

Fig 11 7 Normal gallbladder

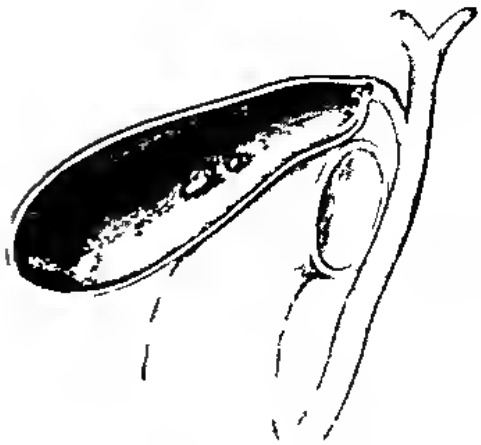

Fig 11 8 Stage 1 Recent stone formation with good gallbladder function and minimal microscopic changes

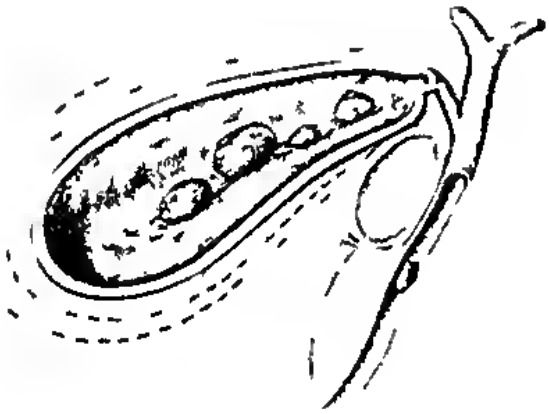

Fig 11 9 Stage 2 Stones have been present for a considerable period of time There is poor function The gallbladder is slightly enlarged, the wall is thickened, and there is evidence of scarring on microscopic examination Common duct stones may be present

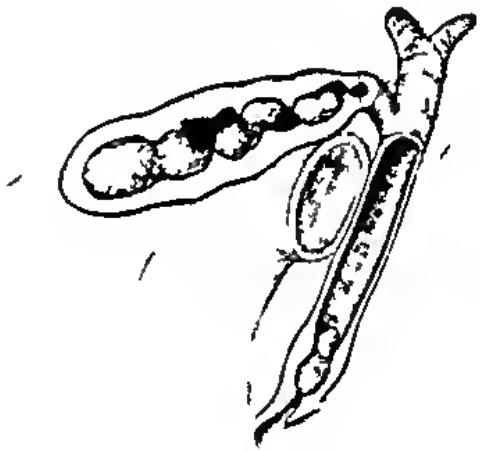

Fig 11 10 Stage 3 Stones have been present for a very long time The gall bladder does not function Its wall is thickened and contracted down about stones Stones are usually present in the common duct

involvement, and then subside without having resulted in structural changes that would alter its stage

The descriptions of the stages supplemented with line drawings are presented to portray the possible course of events if the gallbladder containing stones is not removed Because stones are associated with all biliary tract disease in over 90 per cent of instances, they are accorded a prominent role

## Stage 1

Stone or stones are generally present that have recently formed although they

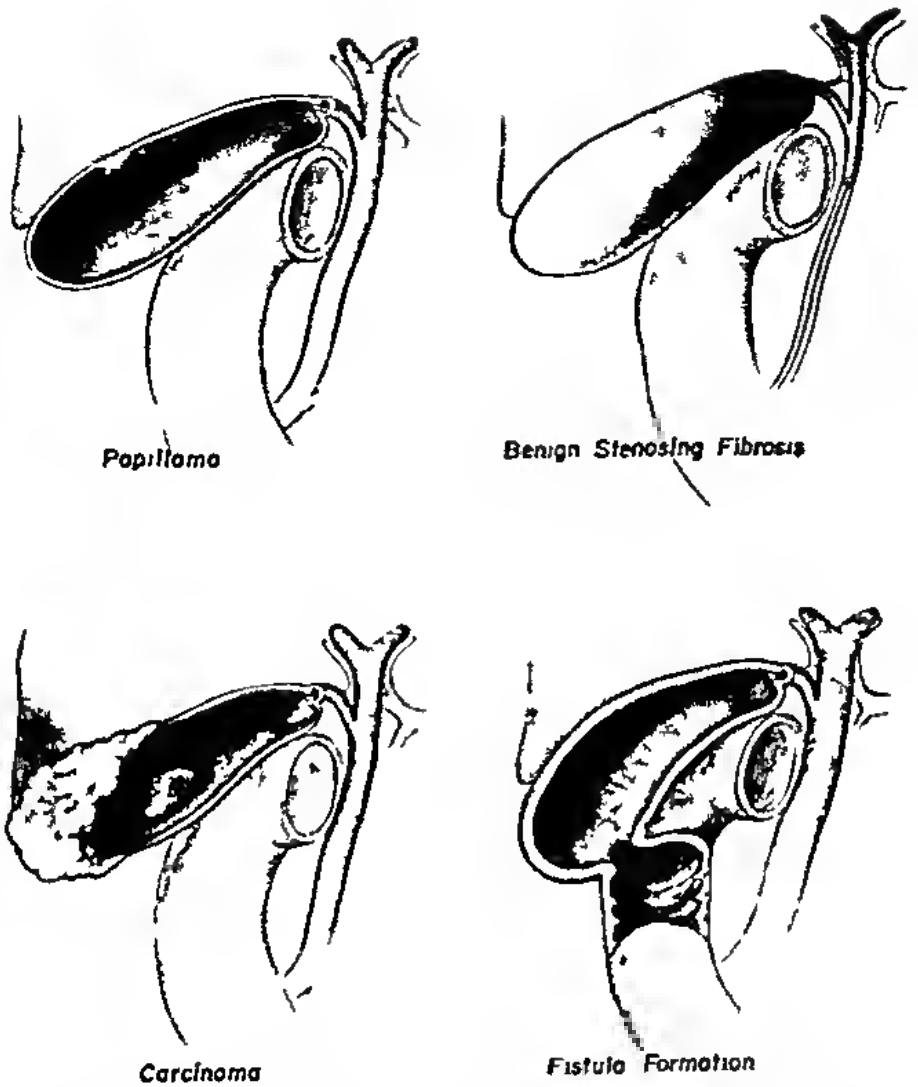


Fig 11 11 Stage 4 This stage is superimposed upon Stages 1 2 and 3 and ncludes pap lloma of the gallbladder benign stenosing fibrosis, carcinoma of the gallbladder and/or ductal system and b l ary enteric fistula

may have existed for varying periods of time The gallbladder functions well as demonstrated by cholecystography it fills readily with the contrast material and it empties following a test meal On ex amination at operation the gallbladder is nearly normal in appearance and con tains one or more stones and on palpation the wall is only slightly thickened if at all Sections selected from different areas of the gallbladder and viewed under the microscope show an absence of significant pathologic changes. Also are included those who in the absence of calculi have had recurrent episodes of acute chole cystitis and as a result have minimal changes of chronic cholecystitis Grossly the gallbladder is of normal size, the color gray rather than blue, and on palpation there is thickening On microscopic ex amination there is scarring and chronic inflammation of somewhat greater degree than in those with stones. The liver is normal in appearance free of detectable injury from recurrent cholangitis or epi sodes of ascending infection the result of,

or in relation to, any episode occurring within the gallbladder

This stage is seen in young women recently pregnant, perhaps the majority in their twenties It is also seen in a somewhat older group, women who have not been pregnant and men Generally these are in the age range of 30 to 45 years It may also be observed in children as well as adults with blood dyscrasias in which there is excess red blood cell destruction

Although this stage, once established, is usually associated with continued activity of the disease of the biliary tract and in time undergoes changes that place it in Stage 2, it may remain quiescent and unchanged for years Perhaps the best known example is that of the single spherical cholesterol stone in the well functioning gallbladder Although we do not know the etiology of gallstones or understand all the numerous mechanisms that may be involved, it seems reasonable to assume that a single stone may be formed and remain in the gallbladder for years without causing obstruction, a sufficient impairment of function to produce symptoms, or additional changes in the biliary system Such a possible innocuous course percentagewise may be of little significance but provides an explanation for the findings of Stage 1 occasionally in old people We favor this concept in preference to the one that projects the precipitous formation of stones for the first time in patients 65 years and older

## Stage 2

Stones have been present for considerable time and gallbladder function has become impaired The gallbladder is faintly visualized by cholecystography if the contrast material enters it readily from the common duct but it is not well concentrated Following a fatty' meal the gallbladder may empty incompletely At operation the gallbladder is enlarged, its color gray rather than blue, and on palpation the wall is unquestionably thickened The liver grossly appears normal in color, size, and texture However, signs of scarring are present on microscopic examination

In from 7 to 15 per cent of patients stones are present in the common duct It is estimated that the majority of patients with chronic cholecystitis and cholelithiasis fall into this group Some do not advance beyond it Post mortem examination may reveal this stage of biliary tract disease with no known history of symptoms, the individual having died from some unrelated condition It is probable that the great majority of patients in this stage continue to have advancement of the disease with consequent changes representing a wide range of variation throughout the entire biliary system

That more patients subjected to operation at present are classified in Stage 2 than in the other three stages merits some discussion First it may be said that Stage 1 is made up for the most part of young individuals whose complaints or symptoms, if minimal, may escape diagnosis Second, that if diagnosis is established they may feel that their symptoms are not sufficient to demand operation As to those in the older age group in Stage 1, they are often without symptoms and have had a diagnosis established by a complete clinical evaluation The gallbladder containing stones and in which intermittent obstruction and recurrent episodes of infection take place is quite likely to give rise to increasing symptoms and disability With each insult or injury from these episodes changes in the biliary tract result, such as thickening and scarring of the gallbladder wall, increase in number and size of stones, formation of or passage of stones into the common duct In many instances injury to the liver results from an ascending infection cholangitis, that involves both the finer canaliculi and liver cells Acalculous cholecystitis is included in Stage 1 It rarely progresses into the later stages however, instances of common duct stone without cholelithiasis are encountered from time to time When this situation

obtains it may best be considered in Stage 2

## Stage 3

Stage 3 is less frequent than Stage 2 It is readily recognized and represents an advanced development in the course of the disease Stones have long been present in the gallbladder The wall is contracted down about them The gallbladder no longer functions Contrast material in attempted cholecystography does not enter Sometimes calculi containing calcium are evident on simple roentgenograms Stones in the common duct are more frequently present than not Injury with scarring in the liver may be minimal and scarcely evident on inspection, or it may be extensive as a biliary cirrhosis Confirmation of the degree of hepatic cirrhosis is dependent upon the findings on microscopic examination

The manifestations of this stage are often dramatic The patient is seized with severe pain in the upper abdomen that radiates to the back and right shoulder This is followed within an hour or two with a chill and high fever Several hours later there is jaundice This was emphasized long ago by Charcot as due to stones obstructing the common duct This late stage of biliary tract disease is accompanied by the injury to the liver that has accumulated during the previous two stages It may be great or little If the patient is elderly, if his biliary tract disease has been long present then it, in combination with the limitations of physiological function of the aged if not corrected, may be fatal

The treatment of biliary tract disease in this stage carries with it a mortality and morbidity rate that is higher than in the first two stages With an ever increasing proportion of our population living into the older age group (65 years and over) it is to be expected for some time that this stage will be seen with increasing frequency In the course of another generation or two this should change because the surgical treatment is becoming safer and easier for patients This coupled with a more alert medical profession establishing diagnosis earlier should see biliary tract disease interrupted before it reaches Stage 3

## Stage 4

The continuation of active biliary tract disease as described in the previous stages (1, 2, and 3) is so frequently the course of events that it may be anticipated and is the basis for prognosis There are other developments that may occur in the wake of the disease that do not seem to fit in well with Stage 3 These are unpredictable and occur in association with biliary calculi but about which we are not always able to demonstrate cause and relationship Thus in Stage 4 are placed those conditions that, although preceded by those in the first three stages actually constitute distinct entities from the standpoint of clinical manifestations and pathology Included in this category are (1) cirrhosis of the liver and benign stenosing fibrosis of the ductal system (2) biliary enteric fistula, and (3) neoplasms including papillomas and carcinomas of the gallbladder as well as carcinoma of the bile ducts

Carcinoma of the gallbladder is rarely (5 to 10 per cent) found except in association with cholelithiasis Malignancy of the extrahepatic ductal system is found in about 50 per cent of instances in patients with calculi The age and the long history of biliary tract disease suggest a causal relationship between stones and neoplasm The poor prognosis by any known therapy renders this an irretrievable sequence Benign stenosing fibrosis of the ductal system although a rare condition in comparison to carcinoma has an equally gloomy prognosis It may or may not be preceded by calcareous biliary tract disease Its origin and course are poorly understood Cholecystoenteric fistula is a complication that may occur in any of the first three stages Once established, the

fistulous communication may persist and be the cause of persistent intrahepatic infection and associated precipitation of additional material into the ductal system

### Phases in Relation to Stage

Each stage may be subject to changes or phases from which it recovers For example, an acute cholecystitis, an inflammatory reaction, may be superimposed on any stage This acute phase may be due to obstruction, infection, or chemical action Complete recovery with little residual scarring can take place so that the stage of the disease according to our criteria remains the same On the other hand the acute phase may not subside, it may persist and become progressive, resulting in a complication such as perforation with a peritonitis If this occurred in Stage 1 the changes in the gallbladder wall would then place it in Stage 2 Again, if the acute phase resulted in the formation of a cholecystoenteric fistula, according to our classification it would be placed in Stage 4

## CHRONIC CHOLECYSTITIS

Chronic cholecystitis is a term designating disease of the gallbladder characterized by evidence of a chronic inflammatory process on gross or microscopic examination Gallbladder function, as demonstrated by cholecystography, is usually impaired, but this is not always the case Stones are present in a high percentage of the subjects The term is a wide and comprehensive one and includes chronic inflammation attended with minimal changes and vague symptoms of dyspepsia to that in which the gallbladder wall has been reduced to dense scar tissue contracted over calculi, the gallbladder is without function, and frequently the process is associated with choledocholithiasis and liver damage Between these two extremes there are inexhaustible varieties and combinations of pathologic changes The gallbladder with minimal microscopic involvement usually produces few symptoms, but this is not invariable, and occasionally such a gallbladder gives rise to severe symptoms The most frequently encountered example of chronic cholecystitis is that of the patient who has had for months or years indigestion manifest by discomfort after eating If a larger amount of food than is usual is ingested, or if food high in fat content is included there is, in addition, belching and regurgitation for several hours These symptoms may increase, to be followed by pain and colic with nausea and vomiting The duration of such episodes may be short or prolonged over hours or days Many of these patients have had repeated episodes of acute cholecystitis Some, however, may never have had an acute inflammatory process involving the entire organ Rather the condition is believed to have been a slowly extending low grade infection

### Symptoms

The symptoms of cholecystitis and cholelithiasis are numerous and varied Perhaps the most frequent complaint of patients with this condition is "indigestion" This of course includes a wide range of manifestations from a sense of uncomfortable fullness to acute pain in the upper abdomen One of the most frequent histories to be obtained from a patient whose symptoms are caused by stones in the gallbladder is as follows The patient had what he considered a large meal, which he enjoyed This meal included a considerable quantity of meat and fat in addition to generous portions of vegetables and a dessert of ice cream with chocolate sauce or something else with an equally high caloric value Several hours later, after a period of feeling uncomfortable, pain has developed in the mid epigastrium, gradually it increases in severity This is followed by nausea and less frequently by vomiting The pain becomes more severe and tends to localize to the right of the mid line and radiates to the back or region of the right scapula The pain may be so marked that the

patient after being apprehensive of his future welfare forsakes concern and seeks only relief of pain This sequence of events is typical of biliary colic and usually represents occlusion of the outlet of the gallbladder or the common duct by a stone that prevents the passage of bile proximal to it

### Physical Examination

On physical examination the patient may be in various degrees of distress from abdominal pain Toleration of pain among individuals differs greatly For the stoical toleration may mask any pain short of agony On the other hand some seem to be supersensitive and shriek wail and cry out in anguish only because they have a moderate amount of discomfort that is either new to them or concerns them because they do not understand what causes it The temperature may or may not be elevated usually not in the early phases The pulse rate is increased There is no constant finding on abdominal examination Often there is resistance of the right rectus muscle to palpation in others there is none The stomach may be full pressure upon it may increase the sensation of upper abdominal fullness but does not increase the patient s pain Vomiting may follow such examination followed by some relief of the patient s discomfort The longer the pain persists the more likely is there to be tenderness on deep palpation of the right upper quadrant. Chronic cholecystitis with cholelithiasis may give rise to symptoms that are the result of the failure of bile to pass into the duodenum When this occurs there is reduced emptying of the stomach and a retention of the gastric contents These acted upon by the digestive juices of the stomach cause distention and discomfort The gastric contents usually acid in nature give rise to heart burn as they are regurgitated into the esophagus If the pyloric occlusion persists and remains complete the gastric contents may become sufficiently irritating to cause increased peristalsis which may further increase and cause vomiting If vomiting is effectual in emptying the stomach then there is usually relief to the patient so far as the distress of fullness in the epigastrium is concerned The pain that is caused by stones that are obstructing the flow of the bile either from the gallbladder or the common duct may persist and even sometimes increase following vomiting However in many instances emptying of the stomach by vomiting may result in a reduction of the stimuli to the biliary tract to deliver bile through the ampulla of Vater into the duodenum and a decrease in the pain

### Cholecystography

X ray examination of the biliary tract as devised by Graham and Cole in 1924 remains the most satisfactory means of indicating directly the presence or absence of calculi in the gallbladder The dye (iodopanoic acid) is given by mouth and absorbed by the gastrointestinal tract to be excreted by the bile If the gallbladder is normal the dye is well concentrated and is visualized on x ray film If the gallbladder is diseased there is poor concentration of the dye The dye will not enter the gallbladder if the cystic duct is obstructed If there are stones in the gallbladder that has good function the gallbladder will be well outlined and also the stones When the gallbladder is not visualized because of lack of function or because of cystic duct obstruction it may be assumed that the gallbladder is diseased and contains stones The degree of accuracy is well over 90 per cent Visualization of the ductal system can also be accomplished by oral and/or intravenous administration of dye using dye substances with high iodine content. Confirmation of the diagnosis is supported by the demonstration of crystals in the duodenal drainage

### Chronic Cholecystitis Without Calculi

The acalculous gallbladder that is not acutely inflamed has in recent years come to be regarded with suspicion by surgeons

Careful studies have led to the conclusion that the results from cholecystectomy for chronic cholecystitis without calculi is unpredictable Over a 22 year period 3 100 patients were treated surgically for chronic biliary tract disease at The New York Hospital Cornell Medical Center (chronic cholecystitis), 135 of these had no stones in the gallbladder Cholecystectomy for chronic cholecystitis with stones on a long term evaluation basis has been considered to have been followed by a good result i e, relief of symptoms in 86 per cent This was in contrast to 121 of 135 patients with an acalculous gallbladder who were evaluated two years or more following cholecystectomy Only 65 per cent were believed to have had a good result on a similar basis An unmistakably thickened wall with general contraction of the gallbladder is sufficient gross evidence for concluding that it is the site of a chronic infection Likewise repeated cholecystograms that reveal impaired function are an indication for cholecystectomy When these are lacking and the appearance of the gallbladder approaches that of being normal then careful consideration must be given to the cause of the patient s symptoms being other than in the gallbladder

Fig 11 12 Cholecystography Radiolucent calculi displacing moderately concentrated dye n slightly enlarged gallbladder

Fig 11 13 Cholecystography Radiopaque calculi seen through dye in a large gallbladder

## ACUTE CHOLECYSTITIS

There has been considerable controversy during the past quarter century as to when surgical treatment for acute cholecystitis should be undertaken however, the trend has been toward early operation Some prefer to encourage the subsidence of the attack by keeping the patient quiet allowing nothing by mouth and maintaining gastric decompression with an indwelling tube and then at some later time doing a cholecystectomy At The New York Hospital Cornell Medical Center we have followed a policy of early surgical treatment of acute cholecystitis over the past 25 years

Surgical treatment of acute cholecystitis provides for operation when the patient is adequately prepared unless some coexisting condition not immediately correctable contraindicates operation The

procedures commonly performed include one of the following, cholecystectomy, cholecystostomy, or either of these combined with choledochotomy The particular procedure to be employed is to be decided upon during the operation The objective is always to secure the greatest possible benefit with the least hazard Sometimes an additional risk must be accepted in order to carry out the procedure indicated For example, exploration of the common duct should be considered imperative when jaundice be

Fig 11 14 Plain x ray film of right upper abdomen showing radiopaque calculi in the gallbladder and common duct (Confirmed by operation )

lieved due to choledocholithiasis is present On the other hand, whether cholecystectomy or cholecystostomy is done is to be determined by a number of variable factors In a series of 978 patients treated surgically over a 25-year period at The New York Hospital-Cornell Medical Center cholecystectomy alone was performed in 767 instances with 12 deaths, a mortality rate of 1 5 per cent Cholecystostomy alone was done in 103 cases with 12 deaths, a mortality rate of 11 6 This procedure is a compromise one, but it may be lifesaving In 108 patients choledochotomy was combined with either cholecystectomy or cholecystostomy because there was evidence suggesting common duct obstruction owing to calculi In this group there were 4 deaths, a mortality rate of 3 7 per cent

Cholecystostomy is clearly indicated under certain circumstances, such as when the patient is too ill to withstand a cholecystectomy, or when cholecystectomy presents too great difficulties In the older age group, where extreme debilitation is encountered most frequently, and among those whose illness is the result of too long delayed operation, the simpler procedure of cholecystostomy should always be employed It can be done under local anesthesia, disturbing the patient very little Not only may it be lifesaving, but decompression of the biliary tract may avert progressive liver damage if complete biliary obstruction is present

Acute cholecystitis associated with calculi is a phase that may develop in any stage of gallbladder disease It may also, in the absence of calculi, represent the primary involvement of the biliary tract as seen in systemic infections such as typhoid fever, bacteremia owing to staphylococci, streptococci, or some other organism In generalized vascular disease that includes an endarteritis or an arteriolitis often associated with renal dysfunction, acute cholecystitis may be but a manifestation of the terminal course of the disease Because of the high incidence of calculi in patients operated upon for acute cholecystitis it is believed that reflux of pancreatic juice is infrequent as an etiological factor As viewed at operation the gallbladder is enlarged, distended, tense, edematous, and reddened It usually contains bile, thick and dark, mixed with blood, or it may be colorless In the majority of instances there is a calculus lodged in the ampulla of the gallbladder or its junction with the cystic duct This is the typical obstructive type of acute cholecystitis (see Fig 11 27) There may be great varia-

tion in the changes in the wall of the gallbladder as a result of impairment of the circulation, infection, and increased intracystic pressure This may range from slight edema to gangrene and perforation The reaction of concentrated bile and the regurgitation of pancreatic juice is believed to be the occasional cause of a chemical acute cholecystitis

Acute cholecystitis is to be seen in the early postoperative period of patients undergoing operative treatment for disease unrelated to the biliary tract It is prone to occur in aged patients, especially males The unusual features are the high incidence of noncalculous gallbladders and the developmental relationship to the resumption of oral feeding preceded by fasting

The clinical diagnosis of acute cholecystitis is to be made from an accurate history and careful physical examination A history of previous attacks of biliary colic and indigestion are important In women pregnancies and their relationship to onset of symptoms compatible with gallbladder disease and a family history of gallstones are significant In some patients no history of biliary tract disease can be elicited and yet they may have had symptoms in early life that they do not recall

## Symptoms

In acute cholecystitis pain begins in the mid epigastrium and rapidly increases in intensity Very often there are short intervals of relief but as it increases it becomes more constant and radiates through to the back more often to the right than to the left Within an hour or two the patient may be aware of tenderness just below the right costal margin in the mid clavicular line when pressure is applied to this area This may also increase the pain in the mid epigastrium Nausea and vomiting are common if the pain is severe and persists Vomiting is followed by some relief but this reprieve is short The acute attack of pain may last from a few to several hours or days It may subside and soreness and tenderness in the right upper quadrant persist Usually there is an elevation of temperature and an increased pulse rate particularly in the young and robust

## Physical Examination

On physical examination the patient is obviously in pain and appears ill There is increased pain on deep palpation in the right upper quadrant and mid epigastrium If the pain has been present very long there is tenderness beneath the costal margin and very often an enlarged and tender gallbladder is palpable Increased muscle resistance and even spasm of the right rectus is not unusual If 24 hours have elapsed since the onset of pain a mild icterus may be present There may also be a leucocytosis ranging up to 20,000 or more

There is great variation in the physical and laboratory findings among patients In general it may be said that in the more robust the systemic reactions as well as the physical manifestations are more evident, whereas in the aged and debilitated these are less marked In the latter there may be little or no fever local tenderness or muscle guarding may be minimal and the leucocyte count within normal range

An attack of acute cholecystitis caused by a stone lodged in the ampulla of the gallbladder is usually rather sudden in onset The pain persists and increases rather rapidly The pain is intensified by coughing and moving If this persists for long the patients often become aware of tenderness just below the right costal margin or the epigastrium Nausea and vomiting commonly occur with the increase in pain and local signs, and precede fever and leucocytosis If generalized abdominal pain develops after a period of localization to the right upper quadrant perforation should be suspected Acute cholecystitis unassociated with calculi is usually slower in its development and it is preceded by manifestations of systemic infection or disease

### Differential Diagnosis in Acute Cholecystitis

In the differential diagnosis of acute intraabdominal conditions acute cholecystitis is relatively easily recognized Appendicitis, pancreatitis, and peptic ulcer are always to be kept in mind The pain of acute pancreatitis may closely simulate that of acute cholecystitis Usually the systemic manifestations are more prominent and the serum amylase is markedly elevated in acute pancreatitis Impending and frank perforation of a duodenal or prepyloric ulcer may more closely resemble an acute cholecystitis than any other intraabdominal condition History, physical examination, and a plain roentgen film of the abdomen will in the majority of instances enable one to make the correct diagnosis

The nature of the onset and the findings on physical examination in acute cholecystitis follow such a consistent pattern that laboratory data, if supporting, add additional confirmatory evidence, yet, if lacking, do not nullify it Mid epigastric pain beginning from one to five hours after eating, gradually increasing in severity with a tendency to shift to the right, and radiating through to the back is seldom caused by other than an obstructive type of acute cholecystitis Nausea and vomiting may or may not be present, and they are of little significance in differential diagnoses because they are often present in a number of intraabdominal conditions that are of rapid onset A history of known biliary tract disease is of great importance in patients with suspected acute cholecystitis

On physical examination there is almost always tenderness and actual pain on deep palpation just below the xyphoid in the mid line There is usually a palpable enlarged gallbladder that is in part protected by muscle guarding by the right rectus Beyond the limits of the right upper quadrant and the infraxyphoid region the abdomen is readily examined without discomfort to the patient Bimanual palpation of the lower right thorax and adjacent abdomen causes increased discomfort or pain to the patient

## PREOPERATIVE MANAGEMENT

Each patient is an individual problem In addition to his biliary tract disease, whether he is normal or has associated conditions that may lead to complications during or after operation is of great importance Careful preoperative evaluation is followed by steps to correct any associated condition, if feasible, so that the patient is in the best condition possible before operation In biliary tract disease one should always be concerned with the functional capacity of the liver and its probable reserve under stress of operation and possible subsequent complications Nutritional disturbances manifested by overweight, starvation, and bleeding tendency owing to vitamin K deficiency are to be recognized and corrected if the operative procedure is to be well tolerated X ray examination and electrocardiograms supplementing clinical evaluation of the cardiorespiratory system may provide critical information in the selection of the anesthetic agent As the proportion of the population in the older age group increases, it behooves us to seek carefully for deficiencies and abnormalities and to correct as accurately as possible dehydration, electrolyte imbalance, hypoproteinemia, diabetes, and other conditions that fall in this category

## ANESTHESIA

Anesthesia has quite properly been accorded more consideration in surgery during the past twenty years We have employed various types including general local, regional block, and spinal, and while specific circumstances render one preferable to another, our tendency has been to use general anesthesia except when there exists some contraindication to its employment

There are two important aspects of general anesthesia The first deals with

the selection of the anesthetic agent Specific consideration is given to the status of the liver and the cardiovascular system Impaired liver function requires a minimal amount of the least toxic agent available The damaged liver may be unable to participate in the elimination of the agent

The second and more important aspect of anesthesia is its administration The art of providing adequate relaxation to facilitate the operation and at the same time using a minimal amount of anesthetic agent together with a respiratory atmosphere high in oxygen has been developed to a degree unanticipated two decades ago Postoperative pulmonary complications have been greatly reduced by preventing aspiration of gastrointestinal contents and the removal of excess bronchial secretions by suction during the operation These have been made possible by (1) evacuating gastric contents before induction and during the procedure by means of an indwelling nasogastric tube and (2) the employment of the intratracheal tube in all patients being operated on under general anesthesia

## OPERATION

The surgeon who operates upon the biliary tract should provide himself with every possible advantage so that the procedure undertaken may be thorough and complete and accomplished without inadvertent injury Sometimes the operation may be simple and at others difficult A generous abdominal incision and properly instructed assistants enables one to have an adequate exposure An awareness of the seriousness of injury to the common duct with the full knowledge of the normal anatomy and the congenital anomalies of the biliary tract and its associated vascular system should result in no structure being divided until it has been identified beyond any question of doubt. Unhurried deliberate dissection enables the surgeon to recognize the abnormal and unusual

Cholecystectomy is an important and frequently performed operation It is important because it affords great relief to those who have gallstones Because there is such a high incidence of biliary tract disease in our population it has become one of the surgical procedures performed most frequently in our many hospitals. If a gallbladder should be removed it should be done carefully and thoroughly There are two hazards that merit attention in this regard One is the possible injury to the common duct and the other is partial or complete occlusion of the right hepatic artery Those who undertake such a procedure as cholecystectomy should be well informed about the various anomalies of the bile ducts as well as the many different anatomic arrangements of the blood vessels that may be encountered in this area If the surgeon is so informed he will exercise diligent caution before dividing any structure until he has identified it beyond a reasonable doubt I know of no complication of biliary tract disease that is of more serious significance than that of the inadvertent division of the common duct or its occlusion by ligatures, in the course of a cholecystectomy

Although the experienced surgeon may remove the gallbladder by a number of surgical approaches with safety, I am convinced that for those who are doing their first few cholecystectomies there is one procedure that of dissecting the gallbladder from the fundus toward the cystic duct, that offers greater safety than all others Furthermore the same approach enables the surgeon to demonstrate to himself the steps that insure a thorough and/or complete operation

The removal of the diseased gallbladder with or without stones should be done irrespective of the stage or phase of biliary tract disease unless there is some contraindication that renders the procedure hazardous The patient s general condition and the inflammatory reaction that distorts the anatomic relationship may for example, be reasons for doing a lesser procedure Although cholecystectomy is the procedure of choice in acute chole-

cystitis, the surgeon should keep an open mind as to just what is to be done until he has evaluated the findings Cholecystostomy, a lesser procedure, may also be indicated in the presence of a peritonitis following a perforation of the gallbladder Later, within a matter of weeks or months when circumstances are more favorable, the gallbladder should be removed It has been observed that over half of the patients who have stones removed and only a cholecystostomy done will develop additional stones within two years In almost every instance of biliary tract disease that is not in an acute phase, cholecystectomy can be done The removal of a gallbladder should include the removal of the cystic duct to within 5 mm of its true junction with the common duct Remnants of the cystic duct may be the site of stone formation and reproduce the clinical picture of cholelithiasis Care is to be exercised in removing the gallbladder not to injure the common duct or the blood supply to the liver The ligation of the right hepatic artery, if mistaken for the cystic artery, may be fatal The incidence of anatomic variations of sufficient extent to be called anomalies of the blood vessels and bile ducts in the subhepatic area is estimated at 15 to 20 per cent

## SURGICAL INCISIONS FOR CHOLECYSTECTOMY

There are three incisions that are commonly used for operations upon the gallbladder They are (1) right subcostal, (2) right paramedian reflecting the rectus muscle, and (3) right mid rectus muscle splitting

1 *Right subcostal* Right subcostal is preferable for the patient of normal habitus or one whose costal sternal angle is wide This is discussed in Chapter 1, Figures 1-14 and 1-15

2 *Paramedian muscle reflecting incision* A linear incision is preferable for the patient of sthenic habitus with a narrow costal margin See Chapter 1, Figures 1-7, 1 8, and 1-9

3 *Right mid-rectus muscle splitting incision* This linear incision is also considered preferable for a person with a sthenic build and a narrow costal margin See Chapter 1, Figure 1 6

## OPERATIONS UPON THE BILIARY TRACT

The surgeon embarking upon operative procedures on the biliary tract should

1 Be aware of the seriousness of common duct injury
2 Be familiar with the normal anatomy and congenital anomalies of the biliary system and its associated vascular system
3 Allow plenty of time for the operation so that deliberate dissection will facilitate unquestionable identification of all structures
4 Employ generous incisions to enable his assistants to provide easy and adequate exposure
5 Divide no structure until it has been identified beyond any question of doubt
6 Only after evaluation of the findings decide upon the operation to be done

### Cholecystectomy for Chronic Cholecystitis

DISSECTION FROM FUNDUS TOWARD CYSTIC DUCT In performing cholecystectomy by dissection from the fundus toward the cystic duct the following steps are recommended

a Incision of the peritoneum parallel to the common duct in the apparent area of its junction with the cystic duct

b The identification of the cystic duct and its dissection sufficient to enable one to pass a silk ligature about it

c Extension of the dissection cephalad and laterally toward the wall of the gallbladder to expose the cystic artery, which is dissected free a sufficient distance to permit a silk ligature to be passed about it and set by one knot, preferably just

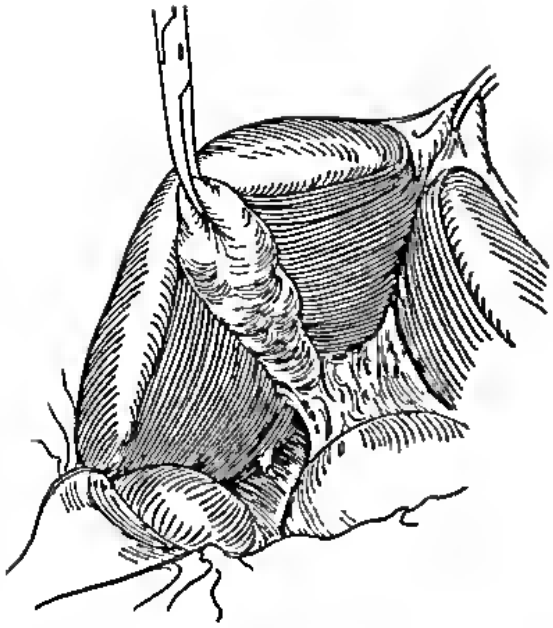

Fig 11 15 Incision of the peritoneum parallel to the common duct in the apparent area of its junction with the cytic duct.

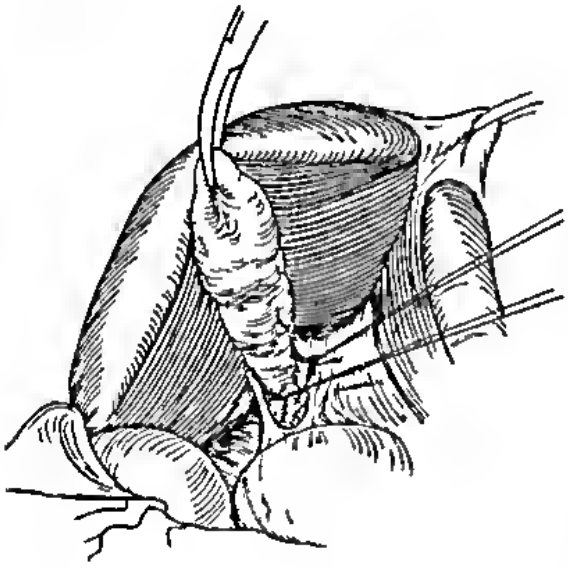

Fig 11 16 The cystic duct is identified and dissected sufficiently to enable one to demonstrate its junction with the common duct The incision is extended cephalad and laterally toward the wall of the gallbladder to expose the cystic artery This is dissected free a sufficient distance to permit a silk ligature to be passed about it and set by one knot preferably just before it branches within the wall of the gallbladder

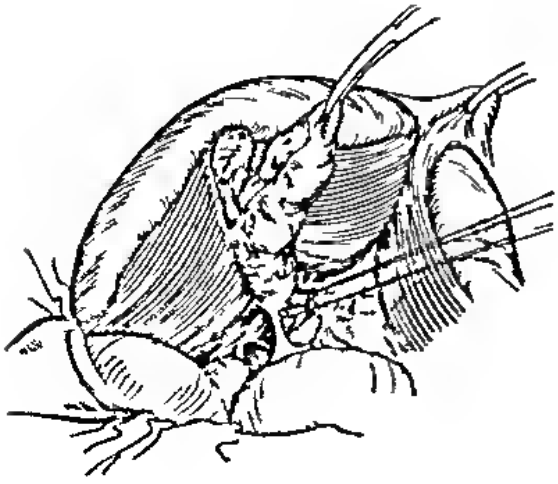

Fig 11 17 The peritoneum over the gallbladder is incised 1 cm from its junction with the liver and the gallbladder is dissected from its liver bed from the fundus toward the cystic duct As the ampulla of the gallbladder is approached the branches of the cystic artery as they enter the wall of the gallbladder are divided and the cystic artery is permanently secured

MEDICAL COLLEGE
LIBRARY
UDAIPUR

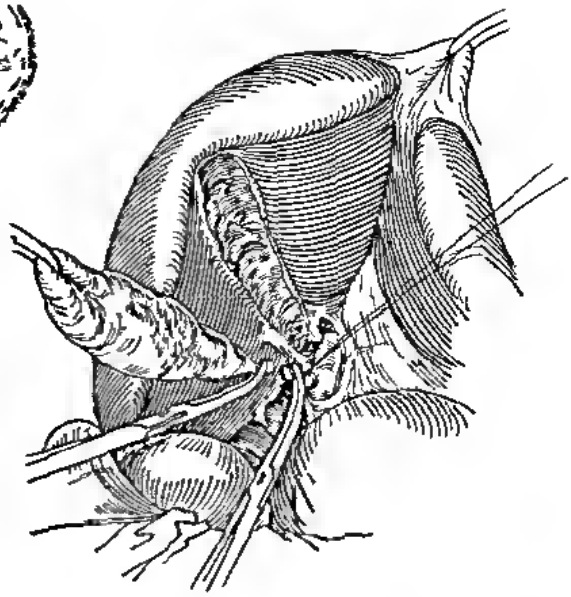

Fig 11 18 Following dissection of the gall bladder from its bed in the liver, the junction of the cystic duct with the common duct is identified Thereafter the cystic duct is divided 5 mm from its true junction with the common duct It is secured with a ligature of No 00 plain catgut and a transfixing suture of silk

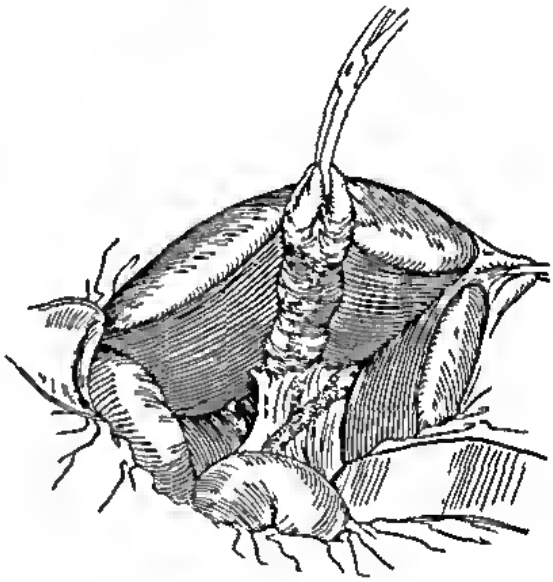

Fig 11 19 With adequate exposure the gall bladder and the subhepatic portal biliary area can be well visualized Tension upon the gall bladder from above and traction upon the peritoneum from below facilitate identification of the cystic and common duct An incision as indicated in the peritoneum marks the beginning of the dissection of the cystic duct, the cystic artery, and the common duct

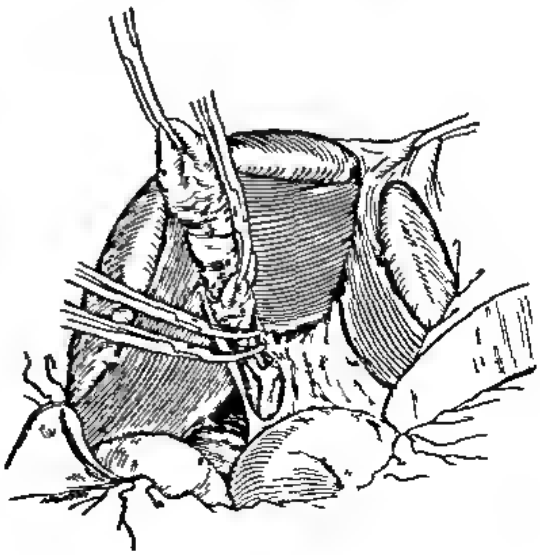

Fig 11 20 The ampulla of the gallbladder often tends to obscure the relationships of these important structures In such instances a clamp may be used to retract it The cystic duct is dissected from the gallbladder down to its true junction with the common duct. This is left intact and then the cystic artery is dissected from its entrance into the gall bladder wall toward its origin from the right hepatic a sufficient distance to permit its being clamped and ligated first with a simple ligature and secondly with transfixing suture It is then divided

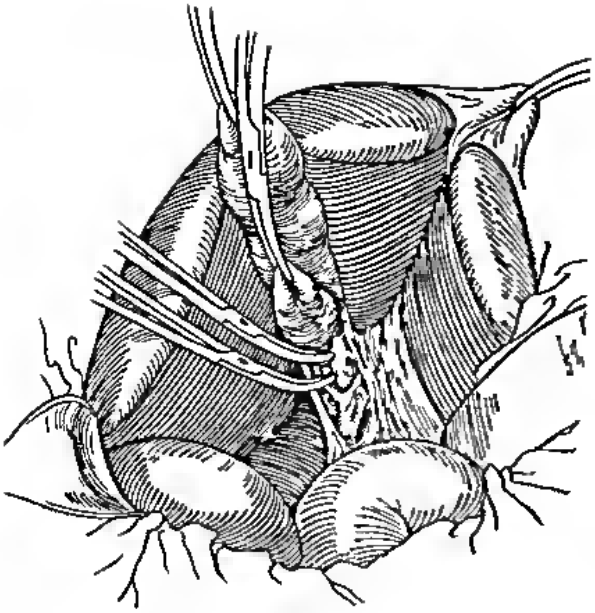

Fig 11 21 After the cystic artery has been divided and secured with ligatures the ampulla of the gallbladder is further dissected from the peritoneum posteriorly This enables one to visualize more easily the cystic duct in its entirety from the gallbladder to its true junction with the common duct A clamp is placed on the cystic duct 5 mm from the common duct a ligature of No 2-0 plain catgut is placed midway between these, a fine silk transfixing suture is placed just proximal to the clamp and secured, and the cystic duct is divided

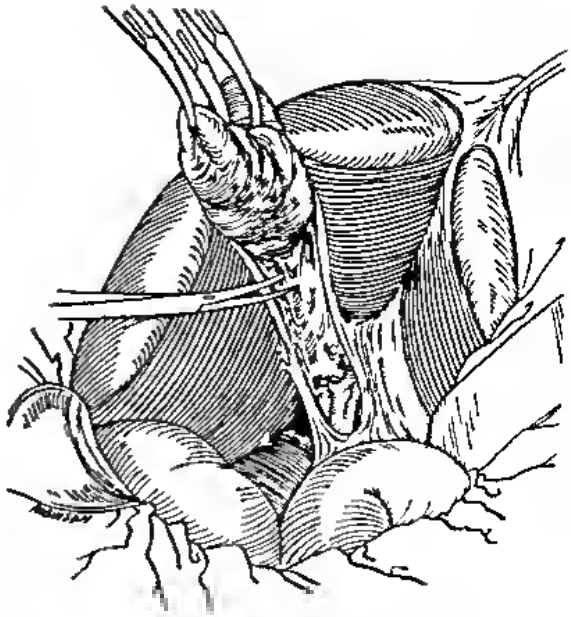

Fig 11 22 The gallbladder is then dissected from its bed in the liver, beginning at the ampulla and proceeding toward the fundus. Care is to be exercised not to denude or lacerate the liver In chronic cholecystitis scar tissue may render dissection difficult It is better to open into the gallbladder than to cut into the liver under such circumstances There are many minute bile ducts within the liver near the gallbladder bed Injury to these results in escape of bile in the subhepatic area in the postoperative period

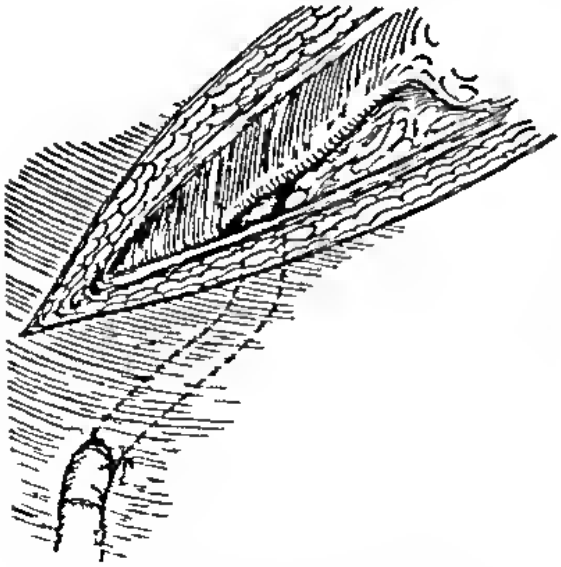

Fig 11 23 The cigarette type of drain emerges through a stab wound below the incision if it is subcostal, it emerges laterally if a midrectus or paramedian incision is made Each drain is secured to the skin by suture

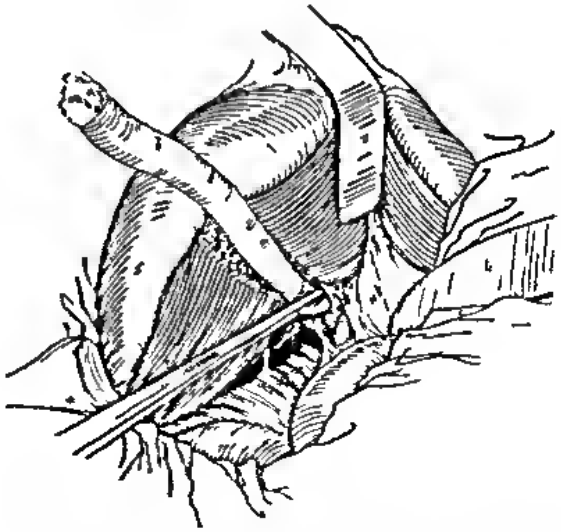

Fig 11 24 A cigarette type of drain is placed so that the tip is within 3 cm of the cystic duct remnant It is brought out along the gallbladder bed.

before it branches within the wall of the gallbladder

d Incision of the peritoneum over the gallbladder 1 cm from its junction with the liver, and dissection of the gallbladder from its liver bed from the fundus toward the cystic duct

e. As the ampulla of the gallbladder is approached division of the branches of the cystic artery as they enter the wall of the gallbladder and permanent fixation of the cystic artery

f Then dissection of the cystic duct down to its true junction with the common duct and division 0 5 cm from it and secured by ligature and/or transfixing suture If it is ligated flush with the wall of the common duct when it is indurated as is frequently seen associated with an inflammatory process then it may be sheared off The result is a defect that allows the escape of bile or requires placing sutures in the wall which may diminish the lumen of the common duct

DISSECTION FROM THE CYSTIC DUCT TOWARD THE FUNDUS In performing cholecystectomy by dissection from the cystic duct toward the fundus the following steps are recommended

a Incision of the peritoneum parallel to the common duct in the apparent area of its junction with the cystic duct

b Identification and dissection of the cystic duct down to its true junction with the common duct

c Dissection of the cystic artery from its entrance into the wall of the gallbladder to its origin from the right hepatic artery It is then divided

d The cystic duct is then divided

e Dissection of the gallbladder from its bed without injury to the liver

REPERITONEALIZATION Following a cholecystectomy reperitonealization of the gallbladder bed may or may not be done If the gallbladder has been removed with care without denuding or injuring the liver, approximation of the peritoneal cuff is not necessary If there are any raw surfaces of liver or any injury reperitonealization is indicated

DRAINAGE OF THE OPERATIVE AREA Drainage of the operative area should be done without exception after removal of the gallbladder This is readily accomplished by placing one or two drains of cigarette type to within 3 cm of the cystic duct and allowing the drain to emerge along the gallbladder bed and through a stab wound below or lateral to the abdominal incision These may be removed after 48 hours if there has been no drainage

## Cholecystectomy with Choledochotomy

See Figures 11 25 through 11 33

Fig 11 25 Acute obstructive cholecystitis A calculus lodged in the ampulla occludes bile flow It also results in reaction of the adjacent wall to impair the blood supply through the cystic artery

## Cholecystostomy

Cholecystostomy may be done under local anesthesia with little disturbance to the patient A vertical incision is made over the fundus of the palpable gallbladder and parallel to the rectus muscle The muscle fibers are separated by sharp and blunt dissection The peritoneum is

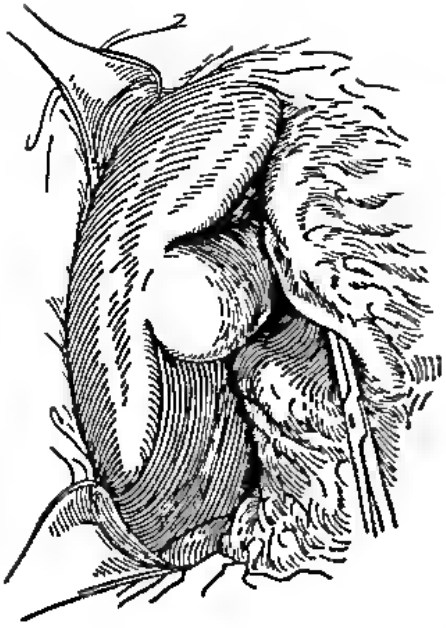

Fig 11-26

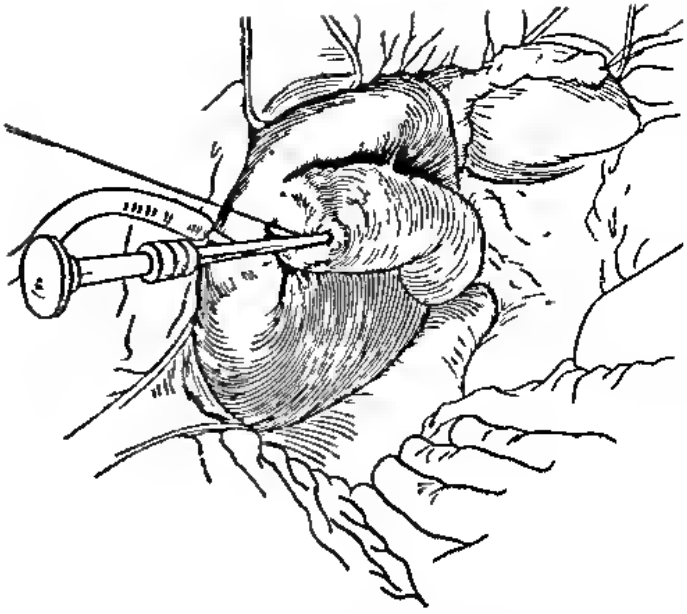

Fig 11 27

Fig 11-28

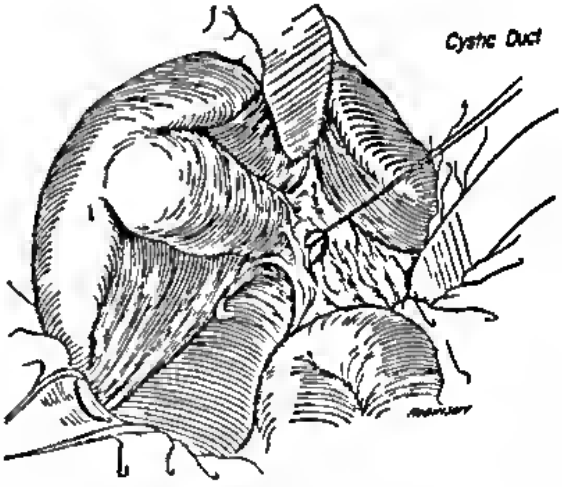


Fig 11-29

Fig 11-26 An edematous, somewhat rigid, and bulky omentum is adherent to the enlarged, tensely distended, acutely inflamed gallbladder It is readily reflected away to expose the biliary fossae

Fig 11-27 After reflection of omentum the distended gallbladder is decompressed with trocar

Fig 11-28 After decompressing the distended gallbladder by aspiration with a trocar, the peritoneum is incised to expose the cystic and common ducts

Fig 11-29 The peritoneum has been incised parallel to the common duct in the apparent area of its junction with the cystic duct. The cystic duct is dissected sufficiently to pass a silk ligature about it for identification purposes. The dissection is then extended cephalad and laterally toward the gallbladder wall to expose the cystic artery

MEDICAL COLLEGE LIBRARY UDAIPUR

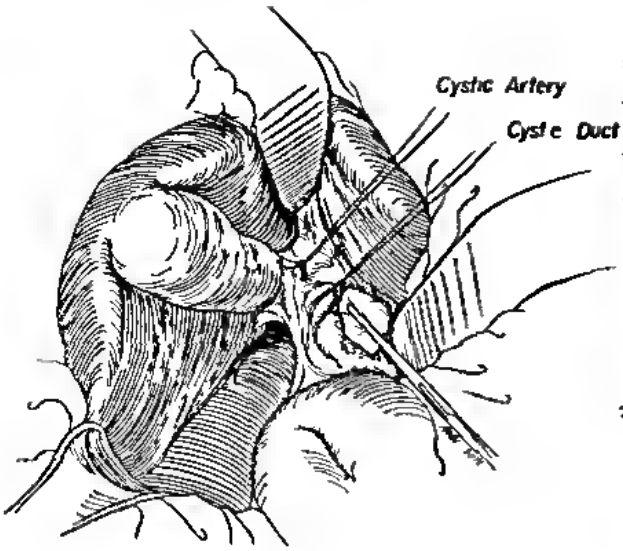


Fig 11 30

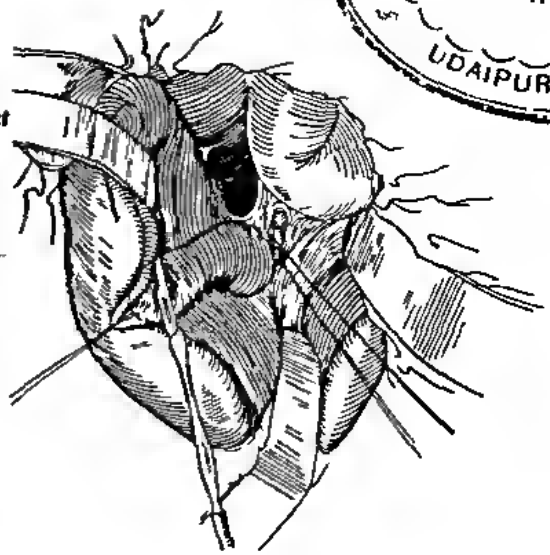

Fig 11 31

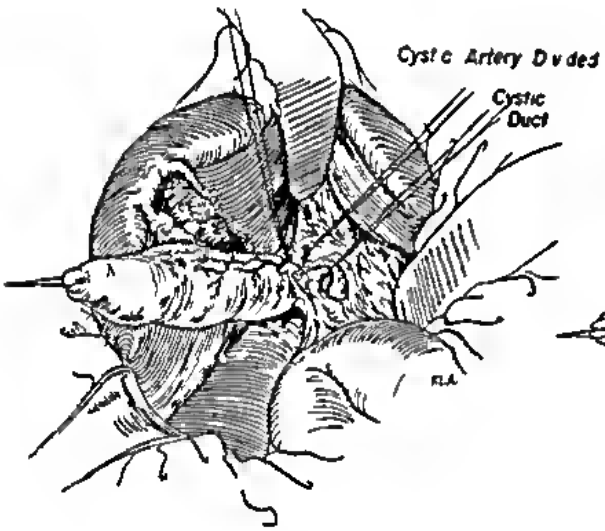


Fig 11 32

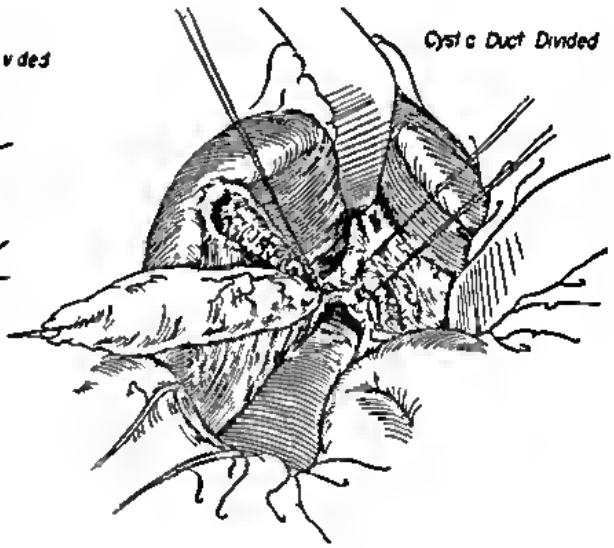


Fig 11 33

Fig 11 30 The cystic artery s identified and d ssected from its entrance into the gall bladder wall to its origin from the right hepatic artery It is then temporarily l gated by set t ng one knot n the s lk l gature

Fig 11 31 The peritoneum over the gallbladder is incised 1 cm from its junct on with the liver and the gallbladder is dissected from its liver bed from the fundus toward the cystic duct

Fig 11 32 As the ampulla of the gallbladder is approached, the branches of the cyst c artery as they enter the wall of the gallbladder are divided and the cystic artery is perma nently secured by l gature and transfixing suture

Fig 11 33 The cystic duct is d ssected down to its true junction with the common duct It is secured with ligature of No 00 plain catgut 3 mm from its junction Just proximal to th s is placed a transfixing suture of fine silk and the cystic duct div ded perm tting the removal of the gallbladder

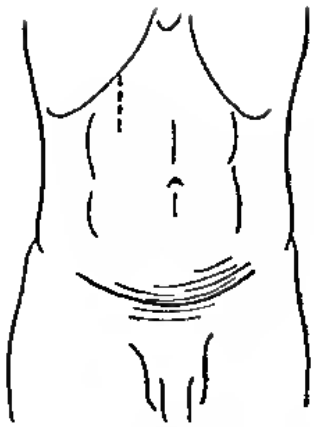

Fig 11 34

Fig 11 34 Vertical incision is made 6 cm in length extending from just below the costal margin over the mid portion of the right rectus muscle

Fig 11 35 A purse string suture is placed in the fundus of the gallbladder and a small incision is made

Fig 11 36 The fluid contents of the gallbladder are evacuated by a trocar attached to suction

Fig 11 37 The incision in the fundus is enlarged and a pituitary spoon is employed to explore the ampullary portion of the gallbladder and to dislodge any impacted calcareous material

Fig 11 35

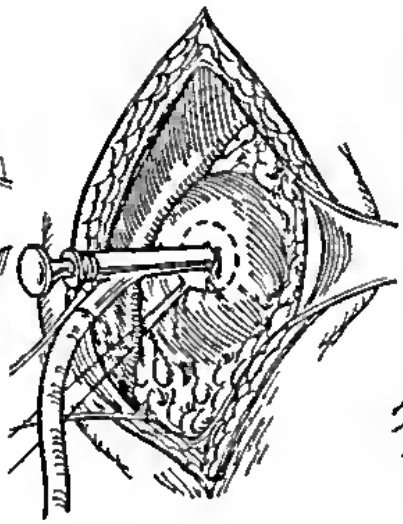

Fig 11 36

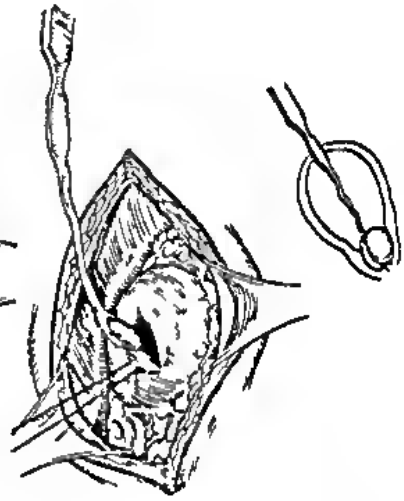

Fig 11 37

incised the extent of the wound A small incision is made in the wall of the gall bladder and its fluid contents are evacuated through a trocar The trocar is then removed and the incision increased to permit the removal of any calculi within the gallbladder Calculi may be lodged in the ampullary portion A malleable pituitary spoon is a very satisfactory instrument for evacuating them Thereafter a No 16 catheter is placed in the gall bladder and a purse string suture used to snug the wall about it The balloon is distended with 2 to 4 cc of saline

The peritoneum and posterior rectus fascia are then sutured to the fundus of the gallbladder with 4 mattress sutures of silk The peritoneum and posterior fascia are then approximated with interrupted sutures The anterior rectus fascia is approximated in a similar manner No stay sutures or subcutaneous sutures are used Interrupted sutures are employed to approximate the skin

## POSTOPERATIVE MANAGEMENT

At the conclusion of the surgical procedure the tracheobronchial tree should be aspirated adequately through the endotracheal tube As the patient recovers from the anesthesia his gag reflex is depressed and he may aspirate excessive secretions or regurgitated stomach contents It is essential that the posterior nasopharynx be repeatedly aspirated with a catheter during this period If atelectasis occurs and cannot be cleared by chest pounding and tracheal aspiration, bronchoscopy must be performed in

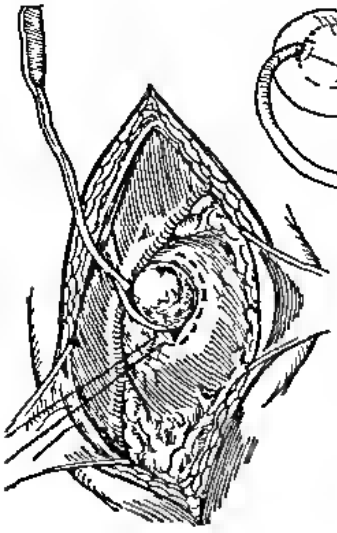

Fig 11 38

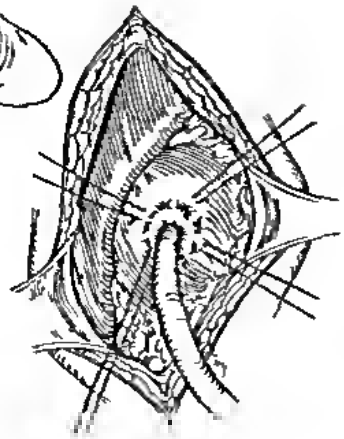

Fig 11 39

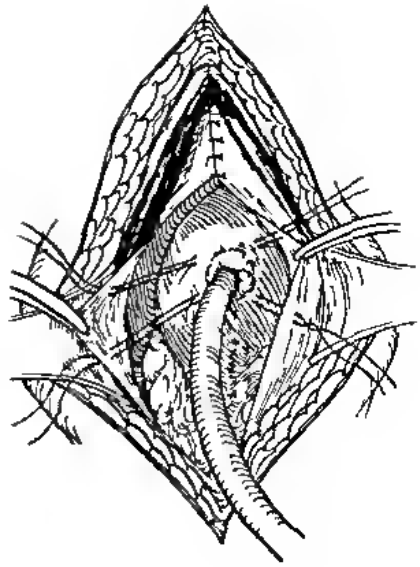

Fig 11 40

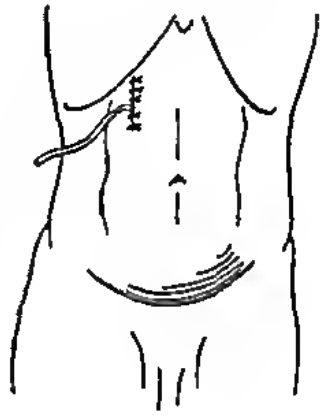

Fig 11 41

Fig 11 38 Calculus brought through enlarged incision in fundus

Fig 11 39 A No 16 Foley catheter with a 5 cc balloon is inserted and the purse string suture snugs the wall about it

Fig 11 40 Four mattress sutures secure the fundus of the gallbladder to the peritoneum and posterior rectus fascia

Fig 11 41 The wound is closed in layers with interrupted sutures The catheter emerges in the mid portion

order to remove the plugs of mucus The patient should be turned frequently and encouraged to cough and to breathe deeply as soon as he is fully conscious Pulmonary congestion owing to excessive fluid and salt intake may contribute to atelectasis and pneumonitis Narcotics are to be used cautiously and in small amounts in order to avoid oversedation and depression of the cough reflex Small doses of barbiturates may be used for restlessness

The maintenance of an empty stomach by means of continuous aspiration does much to keep the patient comfortable following operation It prevents vomiting and thereby reduces the hazard of aspiration It also avoids the increased stress and strain that vomiting places upon the abdominal wound Following an abdominal operation there is ileus of varying degree dependent of course upon the nature of the process and the disturbance to which the intestines have been subjected The continuous evacuation of stomach contents including air diminishes distention

There are two methods of gastric decompression commonly used The first and by far the most frequently used is the indwelling nasal gastric tube While in place, the intragastric tube should be under constant suction and irrigated with small quantities of saline at regular intervals in order to maintain patency of the lumen This tube should be removed as soon as possible, for its presence limits coughing and increases the possibility of atelectasis and pneumonia as well as ulceration of the esophagus It is highly

desirable to commence oral feedings as soon as practicable Abdominal distention should be treated if it develops

The other method is the direct gastrostomy through the abdominal wall For the aged, the debilitated, and those with chronic pulmonary infection this is to be preferred It can readily be established at the completion of the cholecystrostomy through the abdominal wall

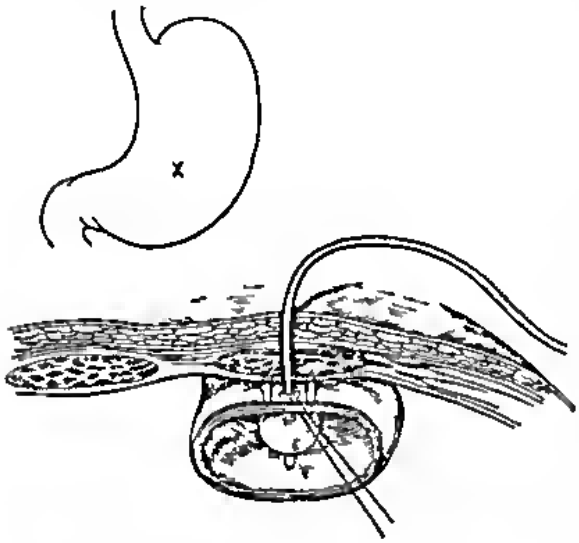


Fig 11 42 Foley catheter type of gastrostomy for maintenance of gastric decompression Schematic insert indicates site of gastrostomy in distal third of stomach

placed through a stab wound in the abdominal wall into the stomach The tube is introduced through a 1 cm incision in the anterior wall of the stomach 6 cm from the greater curvature The balloon is then distended with 15 cc of saline and the stomach wall snugged up about it with a purse string suture The stomach wall is then secured to the peritoneum and posterior rectus fascia with 3 silk mattress sutures Gravity drainage or low pressure negative pressure keeps the stomach empty The tube can be clamped when the patient is able to take fluid and food by mouth The tube is removed on the fifth or sixth day Occasionally there may be some drainage of gastric contents through the site for 12 to 24 hours Patients much prefer this to the indwelling nasal gastric tube

Fluid and electrolyte balance must be maintained When fluids are administered parenterally, an infusion of 900 or 1000 cc of 5 per cent glucose in distilled water with added vitamins is given twice daily as long as the urinary output is adequate Volume for volume replacement of fluid lost by drainage from the intragastric tube or from any tube placed in the biliary tract is accomplished by adding physiologic salt solution to the daily infusion while the patient is maintained on parenteral feedings Potassium loss is replaced by the addition of appropriate amounts of potassium chloride to the infusion, as long as there is an adequate urinary output If drainage from the tubes is marked, the electrolyte content of the fluids lost in this manner should be determined, so that replacement can be accurate

Ambulation is begun on the day of operation unless there is cardiac failure, coronary occlusion, pneumonia, peritonitis, or phlebothrombosis Early ambulation, to us, means that the patient should be up and walking about It does not mean sitting in a chair

While in bed, the lower extremities should be exercised Care must be taken to avoid compression of the veins in the popliteal spaces and groin The legs should be examined for evidences of phlebothrombosis at least twice a day If this occurs anticoagulants may be instituted unless there is some contraindication

If infection occurs, sensitivity studies on the offending organisms are often of value in selecting the most effective antimicrobial agent or agents and these should be used in adequate amounts. Antibiotic therapy is recommended only when indicated

## COMPLICATIONS

In the immediate postoperative period patients who have had operations upon the biliary tract should be carefully observed for certain complications that may develop An awareness that these may occur should encourage the surgeon to exercise measures to prevent them both in the preoperative and postopera

tive period as well as during the actual performance of the operation Although the incidence of complications is low the following are the most frequently encountered

1 Wound infection
2 Subhepatic accumulation
3 Subdiaphragmatic abscess
4 Cholangitis
5 Pancreatitis
6 Common duct obstruction owing to calculi

Proper preoperative evaluation and meticulous operative technique should further reduce the incidence of complications

### Wound Infection

With rare exception the abdominal wound following operations upon the biliary tract becomes progressively less painful If a patient has increasing discomfort in the wound, particularly after the second postoperative day, or if there is local redness and tenderness, it is most likely that a wound infection has developed If the patient has not been on antibiotic therapy it should be instituted The infection will then sometimes recede More frequently the establishment of drainage of a collection of purulent material will be required If the patient has been on antibiotic therapy the wound should be explored immediately and the material cultured, the sensitivity of the organisms determined, and the suitable chemotherapeutic agent given One of the organisms most frequently identified is a staphylococcus that is penicillin resistant

### Subhepatic Accumulation of Material from the Operative Area

As a result of division of small blood vessels, biliary ducts, and lymphatics that are not evident during operation so that they are not ligated by ligature, there accumulates in the biliary fossae varying amounts of fluid If the quantity is not great, it is readily absorbed by the peritoneum Escape for the residual is provided for by placing drains as described elsewhere Lymph, blood, and bile make an excellent medium for bacterial growth If virulent organisms are present an extending infection or an abscess may result If no drains are employed, or if they are removed too early even small amounts of material may be the cause of infection in the subhepatic area and produce severe symptoms The complaint on the second to tenth day of deep seated pain in the right upper quadrant that is increased on moving about associated with an elevation of temperature and leucocytosis always merits investigation with such an explanation in mind If under chemotherapy the process does not subside or if there is no spontaneous drainage through the drainage site then reoperation to establish adequate drainage is indicated

### Subdiaphragmatic Abscess

A subhepatic accumulation that progresses may extend to cause a subdiaphragmatic abscess or a peritonitis beyond the operative area The signs of a subdiaphragmatic abscess following biliary tract operations in addition to those of a subhepatic accumulation include pain referred to the right shoulder and back an elevated and fixed right diaphragm, with questionable involvement of the right lower lobe of the lung Usually there is a high leucocytosis as well as systemic manifestations of a severe infection Surgical drainage is indicated if chemotherapy does not result in subsidence

### Cholangitis

Some patients with an acute cholecystitis may have a slight icterus that is the result of a cholangitis unassociated with common duct obstruction Following operation there may be an increase in the cholangitis Patients who have some degree of common duct obstruction following cholecystectomy and common duct exploration may occasionally develop cholangitis with jaundice, temperature elevation, and a leucocytosis Although it is rare, such cholangitis may come to be suppurative with increase in

symptoms and diminishing liver function to terminate fatally Specific chemo therapy and supportive measures are fol lowed by complete recovery in most instances

### Pancreatitis

Severe mid epigastric pain that tends to radiate to the left within 24 hours of operation upon the biliary tract may be due to acute pancreatitis or an exacer bation of chronic pancreatitis Evidence of pancreatitis at the time of the opera tion or a history of previous attacks should alert one to suspect it Marked elevation of the serum amylase confirms the diagnosis If only a cholecystectomy has been done and the symptoms rapidly progress decompression of the common duct may be indicated For most patients subsidence of symptoms will follow com plete restriction of intake by mouth constant gastric decompression, antibiotic therapy, and anticholinergic agents such as methantheline bromide (Banthine)

### Common Duct Obstruction Caused by Calculi

An individual may have cholelithiasis and choledocholithiasis and yet never have been jaundiced nor had any specific evidence of common duct stones Stones may elude detection at operation, how ever, when the gallbladder is removed the sdent calculi within the common duct may cause obstruction and the symptoms of pain, jaundice and tem perature elevation If jaundice subsides, the presence or absence of calculi can be determined by intravenous cholangiog raphy They should be removed when the surgeon believes the patient can best tolerate a second operation

## PERSISTENCE OR RECURRENCE OF SYMPTOMS FOLLOWING CHOLECYSTECTOMY

Pain in the right upper quadrant fol lowing cholecystectomy may be caused by conditions within the biliary tract and liver or be due to derangements of organs and structures anatomically intimately as- sociated with them Perhaps the majority of patients will have their cause of pain located in the former All merit a careful check into their medical history, a re affirmation of the sequence of events and the findings at operation Determination of the presence or absence of infection or obstruction within the biliary tract is essential Intravenous cholangiography properly performed and supplemented by tomography is a comparatively recent development that has great promise In general it may be said that the results following cholecystectomy are excellent because almost 90 per cent of patients so treated become free of symptoms and seemingly have had their disease inter rupted The approximate 10 per cent of patients who do not become symptom free or have a recurrence certainly merit careful consideration

In the approach to this problem one may separate these cases into two groups first, those whose pain arises from the biliary tract, and second, those whose pain is due to conditions unrelated to the biliary tract

The most frequent causes of pain that are to be found within the biliary tract are

1 Common duct stone
2 Cystic duct remnant, usually con taining calculi
3 Incomplete cholecystectomy
4 Pancreatitis (chronic or recurrent) of such a nature that is associated with a mechanism that permits regurgitation of bile up into the pancreatic ductal system
5 Postoperative neuromas (periductal)

### Common Duct Stone

Common duct calculi are one of the most frequent causes of pain to be found within the biliary tract following chole cystectomy Their removal provides a dramatic relief They are not diagnosed

as promptly as they should be, in part probably because they may produce pain without jaundice Calculi may be present in the common duct at the time of cholecystectomy and escape the surgeon's detection either because the duct was not explored or because even on exploration they were too elusive When the indications for choledochotomy are present this procedure should be done The common duct can be examined by cholangiography before the drainage tube is removed Stones overlooked at operation may thus be demonstrated Pain occurring within days or weeks after cholecystectomy with or without exploration of the common duct should be considered as possibly due to calculi

Common duct calculi with rare exception occur in association with cholelithiasis Common duct calculi may be present and cause no symptoms Patients are to be observed with symptoms of biliary tract disease and no evidence of common duct obstruction who, following cholecystectomy for cholecystitis with cholelithiasis, have had very shortly a new type of pain in the upper abdomen and right upper quadrant, often radiating to the back and left shoulder and followed by jaundice Reoperation with exploration of the common duct and removal of calculi has been followed by relief It is our opinion that cholecysctectomy in some instances where choledocholithiasis is present leads to intraductal changes in pressure with the result that the calculi cause obstruction and symptoms

### Cystic Duct Remnant, Usually Containing Calculi, or Incomplete Cholecystectomy

An incomplete or inadequate operation for a condition within the biliary tract may be followed by pain in the right upper quadrant Patients are seen who give a history that they have had a cholecystectomy performed but who on examination and operation are demonstrated to have had only a cholecystostomy or partial cholecystectomy At the primary procedure a stone or stones may have been removed If stones are left behind they may have a persistence of pain in the right upper quadrant On the other hand, they may have all stones removed and be symptom free for a period and then have a recurrence with the formation of more stones A gall bladder, or any part of it, that remains after removal of stones is more than likely to be the site of new stone formation within two or three years

The leaving behind of a cystic duct remnant in a somewhat similar manner may be the cause of pain following cholecystectomy In a cystic duct remnant even small stones may be prevented from passing into the common duct because of the scarring and inflammation These may give rise to symptoms similar to those caused by stones in the gall bladder immediately after the primary operation Sometimes these small calculi may immediately cause no pain However, if with the lapse of time there is an increase in the size of the calculi or if there is superimposed an inflammatory reaction, the patient usually experiences pain and increasing discomfort

So far as errors in diagnosis are concerned it may be said that acute cholecystitis may be confused with acute pancreatitis but that relapsing pancreatitis and recurrent chronic pancreatitis are not commonly mistaken for chronic biliary tract disease They may and do occasionally occur together but a careful history and examination that includes cholecystograms and serum amylase determinations usually differentiate the two

Intravenous cholangiography is perhaps one of the most rewarding procedures yet developed in evaluating patients who have persistence or recurrence of pain or other symptoms following cholecystectomy and/or common duct exploration In 1955 McClenahan *et al* reported on a study made at The New York Hospital–Cornell Medical Center in which 121 patients with pain and indigestion per-

sisting after cholecystectomy were examined by intravenous cholangiography

Common bile duct abnormalities were demonstrated in 33 per cent These included cystic duct remnants (16 5 per cent), calculi (9 1 per cent), stricture, narrowing or distortion (7 4 per cent) As controls 46 patients who had had cholecystectomy with complete relief of symptoms were examined and 16 or 34 8 per cent had abnormalities These included cystic duct remnants 28 3 per cent calculi 4 3 per cent, and narrowing owing to stricture or distortion 2 2 per cent The findings in the control group quite properly call attention to the observation that the mere presence of these abnormalities does not prove that the patient s complaints are caused by them In this respect they resemble gallstones which may be innocent but usually are not

TABLE 11 2 LESIONS OF THE MAJOR BILIARY DUCTS

| | *Patients with symptoms* | *Asymptomatic control patients* |
|---|---|---|
| Number of patients | 121 | 46 |
| Ducts visualized | 105 (87 0%) | 44 (95 6%) |
| Total duct abnormalities | 40 (33 0%) | 16 (34 8%) |
| Cystic duct remnants | 20 (16 5%) | 13 (28 3%) |
| Strictures & adhesions | 9 ( 7 4%) | 1 ( 2 2%) |
| Calculi | 11 ( 9 1%) | 2 ( 4 3%) |

A series of seventy two patients have been operated upon who had intravenous cholangiograms with adequate visualization of the common duct Forty six of these were considered normal by the radiologist, at operation forty one were normal two were dilated without stones being found on exploration, and three did contain stones. Of the remaining twenty six patients whose common ducts were considered abnormal on intravenous cholangiography by the radiologist, operation revealed twenty had common duct calculi, two were dilated without evident cause one had a patent cystic duct remnant with a small periductal abscess two were normal and one was a biliary enteric fistula

## Pancreatitis Associated with Obstruction to the Free Flow of Bile into Duodenum

Chronic recurrent pancreatitis may be a cause of pain following cholecystectomy It may have been the cause of the pain for which the gallbladder was removed Our knowledge of the etiology and treatment of chronic recurrent pancreatitis is limited indeed It is estimated that in 50 per cent of patients with pancreatitis there is readily demonstrated biliary tract disease Many but not all such patients are improved following the indicated surgical treatment of the biliary tract disease In the other 50 per cent of patients with pancreatitis there are no calculi in the biliary tract but many have associated partial obstruction in the lower portion of the common duct and its junction with the duodenum Spasm and fibrosis of the sphincter of Oddi congenital saccular dilatations of the duct near the papilla of Vater, stenosing fibrosis of the duct, and neoplasm arising from these structures have been found in association with pancreatitis

The reported experience of several American surgeons indicates that the surgical treatment of pancreatitis believed to be the cause of pain following cholecystectomy results in varying degrees of relief Doubilet and Mulholland have reported excellent results by sphincterotomy for this group Waltman Walters has demonstrated that choledochoduodenostomy for these patients may be preferable to sphincterotomy Cattell and Colcock obtained complete relief in 90 per cent of forty nine patients with fibro-

sis of the sphincter of Oddi or papilla of Vater by forceful dilatation of the sphincter and the insertion of a T tube in thirty five, twelve in addition had sphincterotomy with a short T tube being used in two of these, and one patient had a choledochoduodenostomy Saccular dilatations of the lower common duct believed to be congenital in origin have been found to be the cause of postcholecystectomy complaints by Cole and Grove

From our experience we have come to the conclusion that those patients who have chronic recurrent pancreatitis with or without associated changes that produce obstruction to the flow of bile into the duodenum are difficult and their course is unpredictable regardless of the treatment awarded them Some improve and become free of symptoms with no treatment Some improve following any one of several surgical procedures including sphincterotomy choledochoduodenostomy and simple common duct decompression by a T tube In still others the symptoms of pancreatitis have persisted in spite of these and additional procedures including splanchnicectomy partial pancreatectomy and pancreaticojejunostomy

## Postoperative Neuromas (Periductal)

Womack and Crider observed scar tissue around nerve trunks at the site of division of the cystic duct in patients complaining of right upper quadrant pain They report complete relief of pain and other symptoms following removal of such scar tissue with nerve components Removal of this tissue is accomplished by carefully stripping it from the cystic duct remnant and adjacent common duct. This experience led them to suggest the separation and reflection of nerve elements from the cystic duct before dividing it at the primary operation so that they would not be incorporated in the suture used to occlude it They demonstrated fibrous tissue in regenerating nerves around the remnants of the cystic duct identical with that seen in amputation neuroma They are of the opinion that in patients with a large cystic duct remnant the symptoms are not due to the cystic duct remnant per se but to the inclusion in the scarred wall of the duct bundles of nerve fibers Although we have searched for these neuroma we have not had much success in demonstrating them Furthermore in those patients with cystic duct remnant and symptoms we have consistently found changes of an inflammatory nature in the wall Nerve elements are present but little to suggest neuroma formation

## Initially Incorrect Diagnoses

Because of the prevalence of gall bladder disease there is a tendency to conclude that pain in the right upper quadrant in association with gallstones demonstrated by cholecystography or failure to visualize the gallbladder is due to biliary tract disease A lack of critical evaluation of the history and other data pertinent to each individual patient coupled with the unusually satisfactory results of surgical therapy influence one hastily and incorrectly to make a diagnosis for which surgery is undertaken Cholecystitis and cholelithiasis may be present and cause no symptoms The modern concept is that these are a hazardous possession and cholecystectomy should be done unless there is some contraindication And so whereas cholecystectomy done under such circumstances may be beneficial to the patient it is not justified if the symptoms for which it was done were due to something else Certainly the patient is entitled to relief of the symptoms for which he presents himself for treatment

It is well to review the operative note and the description of the specimen removed in all patients who have a persistence or recurrence of symptoms following cholecystectomy Patients who have had a gallbladder removed that was not acutely inflamed and did not contain stones should be carefully re evaluated

The more common conditions that are

extrinsic to the biliary tract and are the cause of pain in the right upper quadrant following cholecystectomy are

1 Peptic ulcer
2 Recurrent acute appendicitis
3 Diaphragmatic hernia (hiatal)
4 Lesions of the right kidney (less frequently to be encountered but to be kept in mind)
5 Coronary heart disease
6 Disease of the large bowel, including carcinoma and diverticulitis
7 Conditions of the vertebra and spinal cord
8 Tumors arising from the right adrenal gland
9 Carcinoma of the pancreas and ampulla of Vater

All these may be misdiagnosed as gall bladder disease Furthermore, these conditions may and frequently do occur in association with gallstones and therefore may be incorrectly diagnosed The eliciting of a careful history would seem in retrospect to be the single most important part in evaluation of the patient It is rare that any of these conditions mimic completely the symptoms and sequence of events seen in biliary tract disease An accurate and complete history in all these will provide the lead that should enable one to make the correct diagnosis so far as symptoms are concerned

Peptic ulcer, for example, is more frequently encountered in young men than young women The pain to which it gives rise is commonly allayed by taking food, in contradistinction to biliary tract disease where food seems to add to a patient s distress

Recurrent acute appendicitis particularly where the appendix is retrocecal and held high, as in incomplete rotation may be the most readily overlooked in the presence of gallstones. For this reason alone visualization of the appendix, even if the surgeon does not elect to remove it at the time cholecystectomy is done, is a sound practice

Hiatal hernia is rare in youth and is frequently seen in the aged Simple questioning by one who is aware of the symptoms it may produce will lead to x ray examination that may confirm it

Lesions of the right kidney are discernible if history, physical examination, and urine examination are evaluated in light of their possible existence

Coronary heart disease, usually increasing in incidence after age 50 but to be seen even in youth, is accompanied by signs and symptoms that are rarely parallel to those caused by gallstones The older the patient the more attention one should direct to the possibility of cardiac disease, particularly in the presence of hypertension

Lesions of the large bowel that cause some degree of obstruction may give rise to complaints that are similar to the indigestion associated with biliary tract disease Abdominal distention is not a common accompaniment of chronic biliary tract disease Acute cholecystitis and a carcinoma of the hepatico flexure may be difficult to differentiate on physical examination but with x ray examination (barium enema) evidence in favor of one or the other is easily obtained The pain of carcinoma of the body and tail of the pancreas has led to cholecystectomy, as has been reported by many authors on this subject Sometimes it is not recognized at operation either because it is not looked for or because the examination is not thorough

Conditions of the spine and lesions of the spinal cord that cause pressure upon the ten to twelve thoracic nerves may likewise lead one into a false path Here again the history is seldom ever compatible with conditions arising within the biliary tract Most of these can be demonstrated by a complete physical examination

Tumors arising from the right adrenal gland may produce symptoms that because of location in the right upper quadrant are attributed to stones in the gallbladder We have seen three patients with a pheochromocytoma on the right who were regarded as suffering primarily from cholelithiasis We are aware of several other instances in the recent experience of other surgeons Differential

diagnosis, if the possibility is kept in mind, is not difficult Other tumors including those that are malignant do arise from the adrenal gland and can be diagnosed by a variety of measures

## CARCINOMA

Carcinoma of the gallbladder is not commonly diagnosed before operation or post mortem examination It is estimated that 10 per cent of persons with gall bladder disease 65 years of age and older have carcinoma of the extrahepatic biliary tract, 60 to 70 per cent of these tumors are found in the gallbladder The symptoms recorded in the histories of patients proved to have carcinoma of the gallbladder are indistinguishable from patients with nonmalignant disease of the biliary tract, with rare exception Physical findings are also similar save for those (about 15 per cent) who have extensive liver metastasis Gallstones are present in carcinoma of the gallbladder in over 90 per cent of instances in our experience We have also observed that the incidence of carcinoma of the gall bladder in patients under 50 years of age upon whom we have operated for presumed nonmalignant disease has been less than 1 per cent, for those 65 to 74 years, 8 9 per cent, and among those 75 and over 12 8 per cent These figures provide justification for elective cholecystectomy for both symptomatic and asymptomatic calcareous gallbladder disease in an attempt to reduce the incidence of cancer of this organ At present carcinoma of the gallbladder accounts for slightly less than 5 per cent of all carcinomas

### Difficulty of Preoperative Diagnosis

Most patients with carcinoma of the gallbladder have a long clinical history of biliary tract disease, many with x-ray evidence of calculi It is a disturbing fact that symptoms are lacking that enables us to distinguish between benign and malignant disease of the gallbladder unless the signs of metastatic or terminal disease are present Persistent severe pain in the right upper quadrant, weight loss, and jaundice superimposed upon a long history of biliary tract disease have been, in our experience, the most frequent symptoms associated with carcinoma of the gallbladder When these are present there is usually massive spread of the tumor into the adjacent liver, regional lymph nodes, and peritoneal cavity, and surgical excision is impossible The majority of these tumors that have been attacked surgically have been encountered unexpectedly at operation for presumed benign biliary tract disease For this reason careful examination of a gallbladder as soon as it is removed is a sound practice

In our experience with eighty eight patients with carcinoma of the gall bladder encountered over a 25 year period we have been impressed with our inability to establish the correct clinical diagnosis before operation or postmortem

TABLE 11 3 CARCINOMA OF THE GALLBLADDER

| | |
|---|---|
| Total number of patients studied | 88 |
| Sex | |
| Male | 23 |
| Female | 65 |
| Age | |
| Less than 50 yrs | 7 |
| 50–64 yrs | 43 |
| 65 yrs or more | 38 |
| Average age | 62 8 yrs |
| Average duration of biliary tract symptomatology | 9 6 yrs |

Seventy eight of the cancers were confirmed by operation and biopsy, the others were proved by autopsy Seventy-five per cent of these patients had a history typical of chronic gallbladder disease of more than one year's duration There is no symptom that distinguishes these patients from those with benign gallbladder disease unless the signs of metastatic or terminal disease are present. This is emphasized by the fact that eighteen of eighty-eight patients entered with the findings of acute cholecystitis, many with an accompanying history of longstanding chronic disease Twenty-

seven were operated upon with an unquestioned clinical diagnosis of chronic cholecystitis, supported by roentgenological evidence of chronic calcareous disease There was a significant weight loss in forty nine patients Gallbladder cancer appears to be correlated with old age and longstanding chronic gallbladder disease Although the age range was 37 to 83 years, 43 2 per cent of the patients were more than 65 years of age Sex incidence also tends to parallel that found in benign biliary tract disease in that 74 per cent of the patients were women

TABLE 11-4 SYMPTOMS DEMONSTRATED

| | |
|---|---|
| 1 Abdominal pain | 68 |
| Radiation to back | 16 |
| 2 Jaundice | 46 |
| 3 Weight loss | 53 |
| 4 Nausea and/or vomiting | 26 |
| 5 Chills fever | 12 |
| 6 Palpable mass noted by patient | 4 |
| 7 Melena gross | 1 |
| occult | 22 |

On physical examination the gallbladder or a right upper quadrant mass was palpable in forty five patients There was a varying degree of associated local tenderness in about a third of the patients Laboratory data included abnormal cholecystograms in fifty three patients There was no significant alteration in the liver function tests Operative procedures were done on 78 cases

## Survival Data

The surgical follow up of these patients revealed that sixty six patients were discharged from the hospital Of these twenty eight were alive at six months thirteen at one year, and seven at two years after surgery Only two patients lived five or more years One patient died from chronic pyelonephritis with uremia at another hospital seven and a half years after surgery, there was no autopsy She had had a laparotomy for intestinal obstruction five years after cholecystectomy and no recurrent tumor was found

## Surgical Procedures for Carcinoma of the Gallbladder

The problem of discovering a small malignant lesion on routine cholecystectomy is a real one It occurred on ten different occasions in this series of seventy eight patients The greatest difficulty was encountered in operations for acute cholecystitis An attitude of suspicion together with frequent frozen sections at operation will help When early lesions are encountered, radical cholecystectomy offers the optimum approach

RADICAL CHOLECYSTECTOMY FOR CARCINOMA LIMITED TO THE GALLBLADDER Radical cholecystectomy includes excision of 1 to 2 cm of the liver adjacent to the gallbladder The peritoneum is then dissected from over the hepatic ducts, the hepatic artery, the common duct and the associated portal vein down to the duodenum This is an established procedure for carcinoma of the gallbladder Postinflammatory attachment of omentum which occurs frequently, should be included in the en bloc resection This approach has been applicable in less than 20 per cent of our cases and introduces the problem of finding such early

TABLE 11 5 SURVIVAL IN PATIENTS OPERATED UPON FOR CARCINOMA OF THE GALLBLADDER The New York Hospital Cornell Medical Center 1932 1957

| | Total number of patients | Patients discharged | Patients known to be alive | | | | | |
|---|---|---|---|---|---|---|---|---|
| | | | 6 mos | 1 yr | 18 mos | 2 yrs | 3 yrs | 5 yrs |
| Patients subjected to surgery for carcinoma of the gallbladder | 8 | 66 | 28 | 13 | 7 | 7 | 5 | 2 |

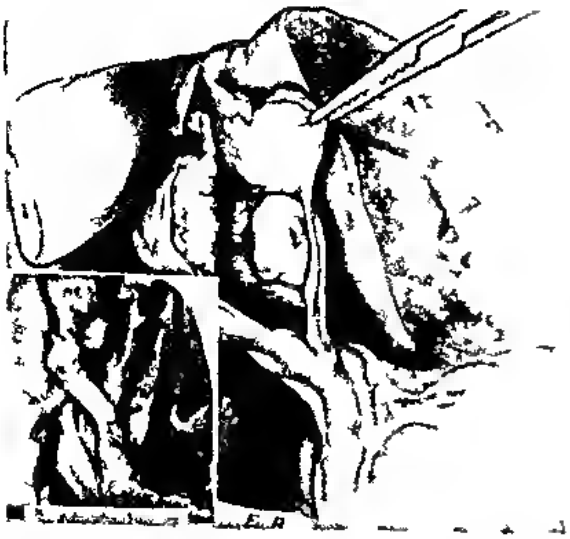

Fig 11 43 Carcinoma of the gallbladder

lesions The symptoms of early carcinoma other than those of associated gallbladder disease, are nonexistent (75 per cent of the patients in this series had long standing symptoms) Wide excision of the adjacent liver bed is advisable particularly in small fundal and gallbladder wall lesions because such lesions have a tendency to early direct extension into the adjacent liver

RESECTION OF RIGHT LOBE OF THE LIVER AND CHOLECYSTECTOMY FOR CARCINOMA THAT HAS NOT SPREAD BEYOND THE ADJACENT HEPATIC AREA Resection of the right lobe of the liver together with the gallbladder and its associated lymphatics and the cystic duct constitutes the most radical and thorough approach to such malignant tumors A sufficient number of right hepatic lobectomies have now been done to demonstrate the practicality of this procedure The essential steps include the identification individual division, and securing of the following

1 The right hepatic artery just distal to its origin
2 The right branch of the portal vein
3 The right hepatic veins
4 The right hepatic duct
5 The cystic duct at its junction with the common duct

If these are successfully accomplished lesser ducts and blood vessels may be secured after removal of the lobe Caution must be exercised not to encroach upon the main trunk of the portal vein or the common or left hepatic artery Adequate exposure for this operation in most instances requires a combined thoracoabdominal approach It is a major undertaking and careful evaluation of candidates is essential The current mortality rate for the operation is estimated

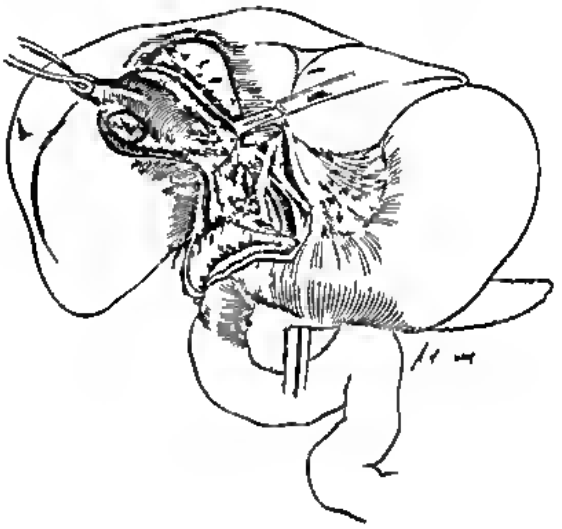

Fig 11 44 Radical cholecystectomy

to be about 30 per cent Life expectancy for carcinoma of the gallbladder is less than two years Only those patients who have no evidence of extension of the tumor beyond the area to be resected should be considered for operation

The surgical treatment of carcinoma of the gallbladder is at present most discouraging In the light of inadequate surgical procedures for the lesions as now commonly encountered it would appear that the best approach to the problem is to advocate cholecystectomy for all calcareous gallbladder disease in an effort to reduce its incidence Failing in this and confronted with a malignant tumor without evidence of extension beyond the adjacent liver, right lobectomy should be more frequently performed

## REFERENCES

ARTUSIO, JOSEPH F, JR, and GLENN, FRANK The Surgeon and the anesthesiologist as a team for geriatric surgery *Am Geriatrics Soc 4* 854, 1956

BOYDEN, E A The accessory gall bladder An embryological and comparative study of aberrant biliary vesicles occurring in man and the domestic animals *Am J Anat 38* 177, 1926

BURDETTE, W J Carcinoma of the gall bladder *Ann Surg 145* 832, 1957

CATTELL, R B, and Colcock, B P Fibrosis of the sphincter of Oddi *Ann Surg 137* 797 1953

CHARCOT, JEAN M Leçons sur les maladies du foie et des voies biliaires et des reins Paris, 1877, Les 12 et seq 125

COLE, W H, and GROVE, W J Persistence of symptoms following cholecystectomy with special reference to anomalies of the ampulla of Vater *Ann Surg 136* 73 1952

CUTLER, I S "John Staugh Bobbs and Lithotomy of the Gall Bladder" *Int Abst Surg 47* 109, 1928

DOUBILET H, and MULHOLLAND, J H Eight year study of pancreatitis and sphincterotomy *J A M A 160* 521, 1956

GILCHRIST, R K Postoperative decompression of the stomach and jejunum by gastrostomy *J A M A 152* 232, 1953

GLENN FRANK and WANTZ, GEORGE F Acute cholecystitis following the surgical treatment of unrelated disease *Surg Gynec & Obst 102* 145, 1956

GRAHAM, E A, and COLE, W H Roentgenologic examination of the gall bladder Preliminary report of new method utilizing intravenous injection of tetrabromphenol phthalein *J A M A 82* 613, 1924

GROSS, R E Congenital anomalies of the gallbladder A review of 148 cases, with report of a double gallbladder *Arch Surg 32* 131, 1936

HAYS, DANIEL M, and GLENN, F The fate of the cholecystostomy patient *J Am Geriatrics Soc 3* 21, 1955

KUMMEL, HERMANN Zur Chirurgie der Gallenblase *Deutsche med Wchnschr 16* 23 1890

LANGENBUCH, CARL Ein Fall von Exstirpation der Gallenblase wegen chronischer Cholelithiasis Heilung, *Berlin klin Wchnschr 19* 725 1883

NAUNYN, B *Klinik der Cholelithiasis* Leipzig Verlag von F C Vogel, 1892 Translation by GARROD, A F New Syndenham Soc, 1896

ROLLESTON, H, and MCNEE, J W *Diseases of the Liver, Gall Bladder and Bile Ducts* London The Macmillan Co, Ltd, 1929

WALTERS, WALTMAN Post-cholecystectomy dyskinesia with pancreatitis, sphincteritis and choledocholithiasis as causes *J A M A 160* 425, 1956

ZIMMERMAN L M, and LEVINE, R *Physiologic Principles of Surgery* Philadelphia and London W B Saunders Co, 1957

CHAPTER 12

# SURGERY OF THE BILE DUCTS

*Waltman Walters*

## INDICATIONS FOR EXPLORATION OF THE COMMON BILE DUCT

The indications for surgical exploration of the common bile duct are enlargement of the common duct with or without associated jaundice, chills and fever, small stones in the gallbladder and cystic duct, and cholangiographic evidence of stones in the common bile duct

### Ductal Enlargement

Enlargement of the common bile duct is a relative estimation of increase in its size, for normally it may vary from 5 to 8 mm in diameter Since the diameter of the common bile duct at necropsy in a large number of cases studied by Trommald was found to range from 3 to 8 mm it has been presumed that the duct is smaller than in living patients In a study of 1,000 cases of disease of the biliary tract in which surgical exploration was carried out in the Massachusetts General Hospital, Bartlett and Waddell considered any duct with an outside diameter of 1 cm. or more to be dilated. In my own experience most common ducts that I have considered normal in size have been from about 5 to 7 mm in diameter I have, however, seen the diameter of the common bile duct change during the course of an operation Such change probably was due to changes in intraduodenal pressure produced by anesthetic gases administered with forced pressure

### Jaundice

The presence of jaundice, particularly if there has been a history of pain associated with it, and if the common duct is enlarged, is an indication for opening and exploring the common duct to determine the cause of the obstruction and to remove it In some cases of jaundice the common duct may not be enlarged and when there is a question of extrahepatic obstruction, it is advisable to open and explore the common, hepatic and intrahepatic ducts with probe and scoops to exclude stones or malignant lesions The exploring instruments should be passed through the lower end of the bile ducts into the duodenum, and the duct should be palpated over the scoop to exclude stones, tumors, and ampullary lesions, for a probe or scoop may pass by a stone and through a malignant ampullary lesion

### Small Stones in the Gallbladder and Cystic Duct

On occasions I have thought it advisable to open and explore a common

bile duct of normal size when the patient had small stones in the gallbladder, particularly when some were in the cystic duct or when the patient gave a history of jaundice In all cases that I have encountered, the common bile duct was enlarged when common duct stones of more

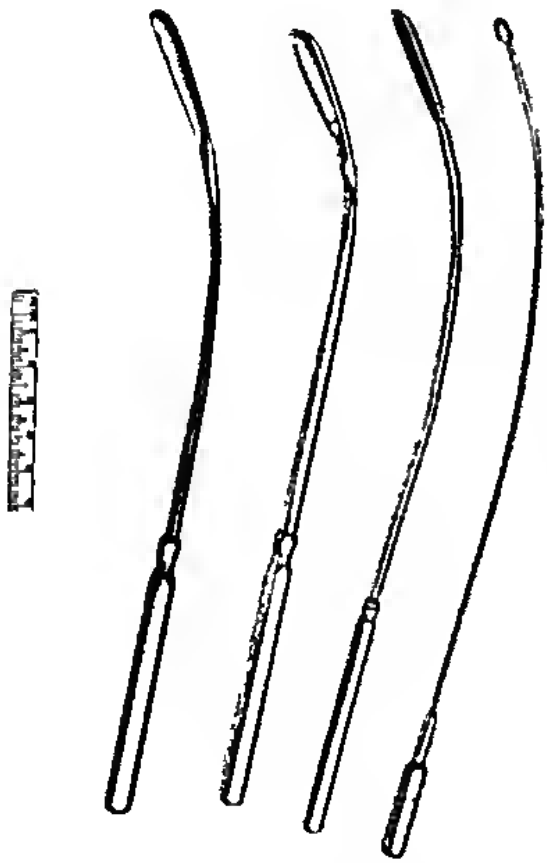

Fig 12 1 Probe and malleable common duct scoops of different diameters. (*From* Walters, Waltman, and Snell A B, *Diseases of the Gallbladder and Bile Ducts* Philadelphia W B Saunders Co, 1940 *Courtesy of the publisher*)

than 2 to 1 mm were present. In every case in which the common and hepatic ducts are explored scoops (Fig 12-1) should be passed through the lower end of the duct into the duodenum and the duct should be carefully palpated over the scoop to be sure that it had not bypassed a small stone in the ampulla or in the lower part of the duct (Fig 12-2)

In Bartlett and Waddell's study of 257 cases in which the gallbladder contained small stones, choledochostomy produced stones in only 16 per cent of the cases. In our experience at the Mayo Clinic in which, for one reason or another, the surgeon has carried out exploration of the common bile duct (in the past several years this has been in about 25 per cent of the cases in which cholecystectomy was performed) stones were found in the common or hepatic ducts in approximately 50 per cent

## Fever

When the common bile duct is obstructed, the duct will always be found to be enlarged In most cases the cause of the enlargement is a common duct stone but other causes such as pancreatitis or sphincteric dysfunction may be responsible I have operated on several patients whose only symptom suggestive of intermittent obstruction of the common duct owing to stones was the so-called intermittent hepatic fever of Charcot I recall three patients with intermittent fever having operations the same week. One of the patients had stones in the common and hepatic ducts, another had right perinephritic abscess, and the third had malignant neuroblastoma of the right adrenal gland which had invaded the inferior vena cava The clinical histories of all three of these patients were somewhat similar

## Intravenous Cholangiography

The introduction by the German scientists Kleiber, Langecker, Harwari, and Junkmann of the concentrated iodine compound Biligrafin (N N'-adipyl bis-[3 amino-2,4,6,-tri iodo] benzoic acid) has been of great value in the diagnosis of lesions of the common and hepatic ducts At first the use of the American compound (Cholografin) was found to give errors in 20 to 25 per cent of cases. With greater experience, improvement in the formula,* and the use of tomograms how-

* Chlorografin methylglucamine

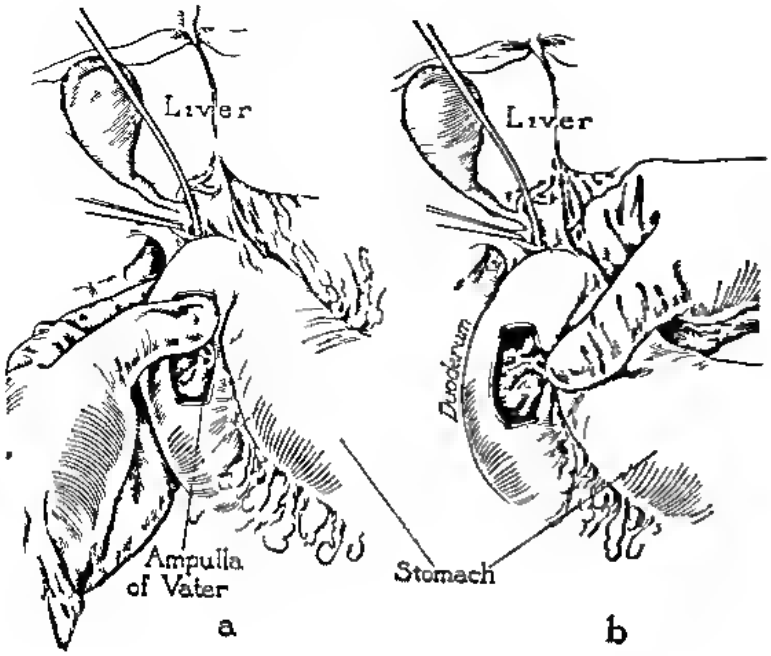


Fig 12 2 (*Left a b*) Palpation of lower part of common duct and the ampulla with malleable scoop in the lower part of the duct (*From* Walters Waltman and Snell A B *Diseases of the Gallbladder and Bile Ducts Courtesy* W B Saunders Co ) (*Below*) Scoops exploring the hepatic and intrahepatic ducts

ever, this incidence has been reduced to 10 to 16 per cent

Intravenous cholangiography is particularly valuable in showing common duct stones of 0 8 to 10 mm or more in diameter when the patient has had pain but no other evidence of biliary obstruction On the other hand I have disregarded a negative report and advised exploration of the common ducts of patients in whom the clinical symptoms warranted such an exploration I must say, however that I have found few stones when the intravenous cholangiogram was reported negative for stones and outlined a duct of normal size

In some instances when the patient has been allergic and has had a reaction to the intravenous injection of the concentrated iodine solution (Cholografin), certain iopanoic acid compounds such as Telepaque, taken orally, have outlined the common duct well in the choledochogram

## SURGICAL EXPLORATION OF THE COMMON DUCT

### Technique at Primary Operation on Biliary Tract

Choledochostomy or exploration of the interior of the common and hepatic ducts

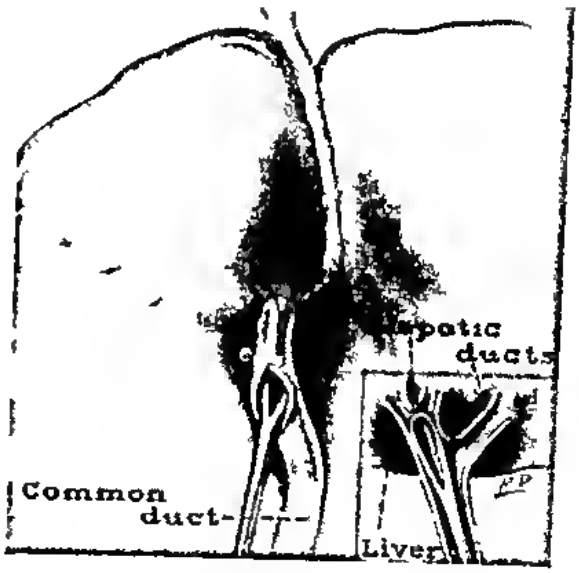


as a primary operation is usually not done until the diseased gallbladder has been disposed of either by cholecystectomy or cholecystostomy (rarely the latter in recent years) I think it is a good plan to sever the cystic duct and artery before opening the common duct, thus preventing small stones passing into it through the cystic duct In muscular or obese patients, traction on the gallbladder will assist in exposing the common duct The common bile duct lies on top of the portal vein and lateral to the hepatic artery (Fig 12 3) Occasionally the hepatic artery or

bile duct of normal size when the patient had small stones in the gallbladder, particularly when some were in the cystic duct or when the patient gave a history of jaundice In all cases that I have encountered, the common bile duct was enlarged when common duct stones of more

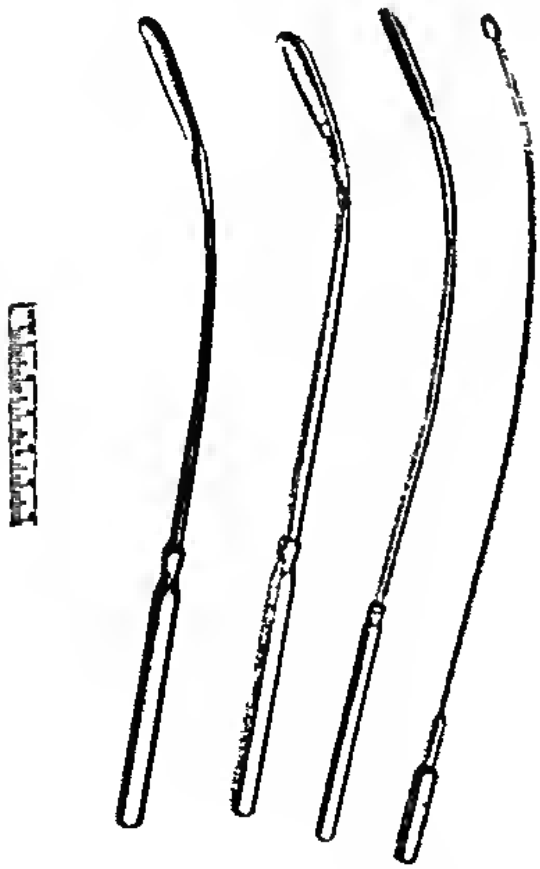

Fig 12-1 Probe and malleable common duct scoops of different diameters (*From* Walters, Waltman, and Snell, A B, *Diseases of the Gallbladder and Bile Ducts* Philadelphia, W B Saunders Co, 1940 *Courtesy of the publisher* )

than 2 to 4 mm were present In every case in which the common and hepatic ducts are explored, scoops (Fig 12-1) should be passed through the lower end of the duct into the duodenum and the duct should be carefully palpated over the scoop to be sure that it had not bypassed a small stone in the ampulla or in the lower part of the duct (Fig 12 2)

In Bartlett and Waddell's study of 257 cases in which the gallbladder contained small stones, choledochostomy produced stones in only 16 per cent of the cases. In our experience at the Mayo Clinic in which, for one reason or another, the surgeon has carried out exploration of the common bile duct (in the past several years this has been in about 25 per cent of the cases in which cholecystectomy was performed) stones were found in the common or hepatic ducts in approximately 50 per cent

## Fever

When the common bile duct is obstructed, the duct will always be found to be enlarged In most cases the cause of the enlargement is a common duct stone but other causes such as pancreatitis or sphincteric dysfunction may be responsible I have operated on several patients whose only symptom suggestive of intermittent obstruction of the common duct owing to stones was the so-called intermittent hepatic fever of Charcot I recall three patients with intermittent fever having operations the same week. One of the patients had stones in the common and hepatic ducts, another had right perinephritic abscess, and the third had malignant neuroblastoma of the right adrenal gland which had invaded the inferior vena cava The clinical histories of all three of these patients were somewhat similar

## Intravenous Cholangiography

The introduction by the German scientists Kleiber, Langecker, Harwart, and Junkmann of the concentrated iodine compound Biligrafin (N,N'-adipyl-bis-[3 amino-2,4,6,-tri-iodo] benzoic acid) has been of great value in the diagnosis of lesions of the common and hepatic ducts At first the use of the American compound (Cholografin) was found to give errors in 20 to 25 per cent of cases. With greater experience, improvement in the formula,* and the use of tomograms low-

* Chlorografin methylglucamine

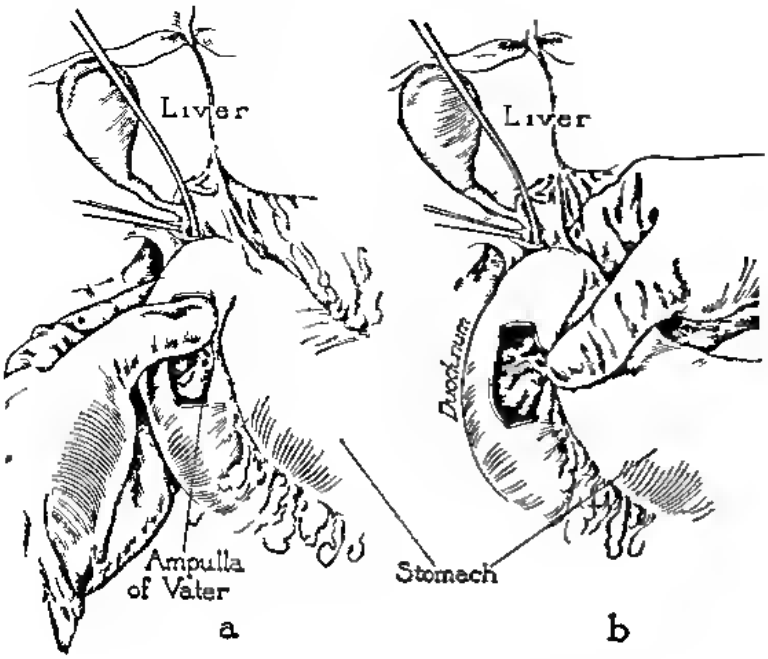


Fig 12 2 (*Left a b*) Palpation of lo er part of common duct and the am pulla with malleable scoop in the lower part of the duct (*From* Walters Walt man and Snell \ B *Dis eases of the Callbladder and Bile Ducts Courtesy* W B Saunders Co ) (*Below*) Scoops exploring the he patic and intrahepatic ducts

ever, this incidence has been reduced to 10 to 16 per cent

Intravenous cholangiography is particu larly valuable in showing common duct stones of 0 8 to 10 mm or more in diam eter when the patient has had pain but no other evidence of biliary obstruction On the other hand, I have disregarded a negative report and advised exploration of the common ducts of patients in whom the clinical symptoms warranted such an exploration I must say however that I have found few stones when the intra venous cholangiogram was reported nega tive for stones and outlined a duct of normal size

In some instances when the patient has been allergic and has had a reaction to the intravenous injection of the concentrated iodine solution (Cholografin) certain iopanoic acid compounds such as Tele paque taken orally, have outlined the common duct well in the choledochogram

## SURGICAL EXPLORATION OF THE COMMON DUCT

### Technique at Primary Operation on Biliary Tract

Choledochostomy or exploration of the interior of the common and hepatic ducts




as a primary operation is usually not done until the diseased gallbladder has been disposed of either by cholecystectomy or cholecystostomy (rarely the latter in re cent years) I think it is a good plan to sever the cystic duct and artery before opening the common duct thus prevent ing small stones passing into it through the cystic duct In muscular or obese patients traction on the gallbladder will assist in exposing the common duct The common bile duct lies on top of the portal vein and lateral to the hepatic artery (Fig 12 3) Occasionally the hepatic artery or

bile duct of normal size when the patient had small stones in the gallbladder, particularly when some were in the cystic duct or when the patient gave a history of jaundice In all cases that I have encountered, the common bile duct was enlarged when common duct stones of more

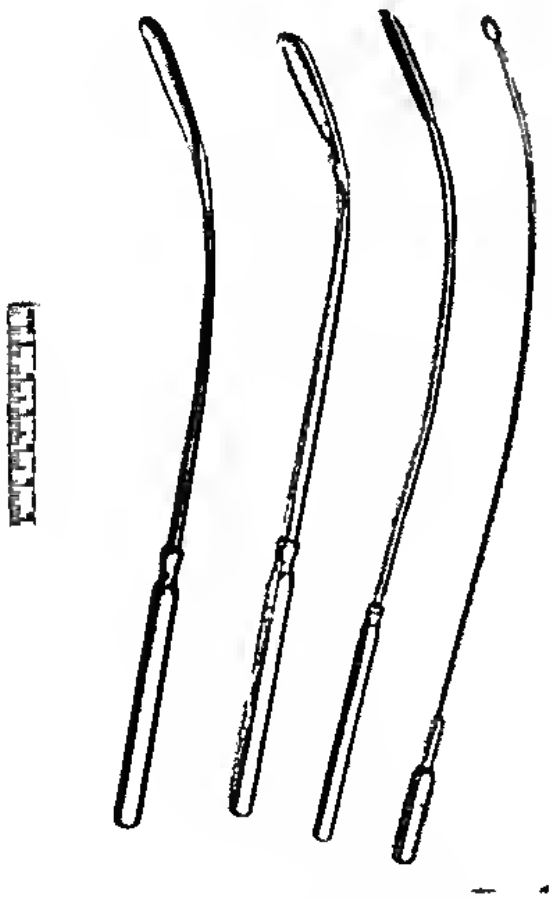

Fig 12 1 Probe and malleable common duct scoops of different diameters (*From* Walters, Waltman, and Snell A B, *Diseases of the Gallbladder and Bile Ducts* Philadelphia W B Saunders Co, 1940 *Courtesy of the publisher* )

than 2 to 4 mm were present In every case in which the common and hepatic ducts are explored, scoops (Fig 12-1) should be passed through the lower end of the duct into the duodenum and the duct should be carefully palpated over the scoop to be sure that it had not bypassed a small stone in the ampulla or in the lower part of the duct (Fig 12 2)

In Bartlett and Waddell s study of 257 cases in which the gallbladder contained small stones, choledochostomy produced stones in only 16 per cent of the cases In our experience at the Mayo Clinic in which, for one reason or another, the surgeon has carried out exploration of the common bile duct (in the past several years this has been in about 25 per cent of the cases in which cholecystectomy was performed) stones were found in the common or hepatic ducts in approximately 50 per cent

## Fever

When the common bile duct is obstructed, the duct will always be found to be enlarged In most cases the cause of the enlargement is a common duct stone but other causes such as pancreatitis or sphincteric dysfunction may be responsible I have operated on several patients whose only symptom suggestive of intermittent obstruction of the common duct owing to stones was the so-called intermittent hepatic fever of Charcot I recall three patients with intermittent fever having operations the same week. One of the patients had stones in the common and hepatic ducts, another had right perinephritic abscess, and the third had malignant neuroblastoma of the right adrenal gland which had invaded the inferior vena cava The clinical histories of all three of these patients were somewhat similar

## Intravenous Cholangiography

The introduction by the German scientists Kleiber, Langecker, Harwart, and Junkmann of the concentrated iodine compound Biligrafin (N,N' adipyl bis-[3 amino-2,4,6, tri iodo] benzoic acid) has been of great value in the diagnosis of lesions of the common and hepatic ducts. At first the use of the American compound (Cholografin) was found to give errors in 20 to 25 per cent of cases With greater experience, improvement in the formula * and the use of tomograms, how

* Chlorografin methylglucamine

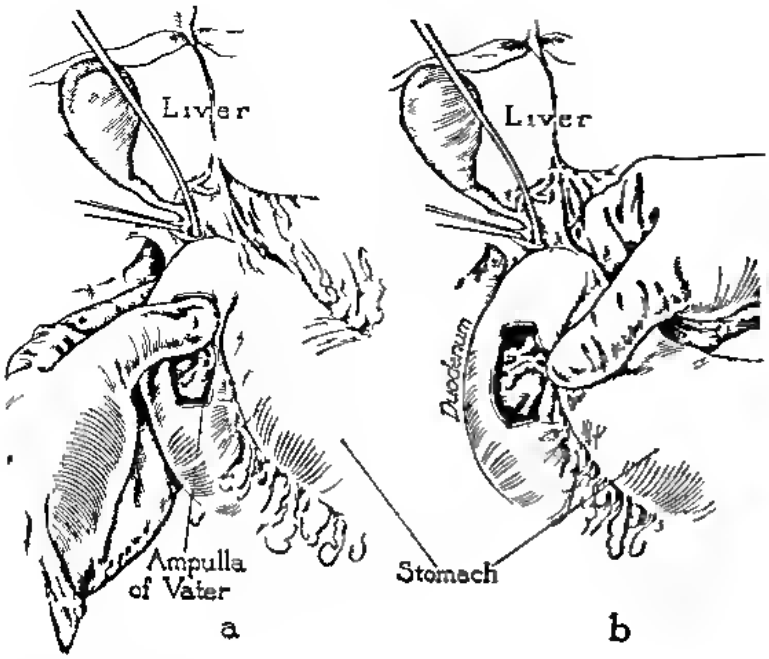


Fig 12 2 (*Left a b*) Palpation of lower part of common duct and the ampulla with malleable scoop in the lower part of the duct (*From* Walters Waltman and Snell A B *Diseases of the Gallbladder and Bile Ducts Courtesy* W B Saunders Co ) (*Below*) Scoops exploring the hepatic and intrahepatic ducts

ever, this incidence has been reduced to 10 to 16 per cent

Intravenous cholangiography is particularly valuable in showing common duct stones of 0 8 to 10 mm or more in diameter when the patient has had pain but no other evidence of biliary obstruction On the other hand I have disregarded a negative report and advised exploration of the common ducts of patients in whom the clinical symptoms warranted such an exploration I must say however that I have found few stones when the intravenous cholangiogram was reported negative for stones and outlined a duct of normal size

In some instances when the patient has been allergic and has had a reaction to the intravenous injection of the concentrated iodine solution (Cholografin), certain iopanoic acid compounds such as Telepaque taken orally, have outlined the common duct well in the choledochogram

## SURGICAL EXPLORATION OF THE COMMON DUCT

### Technique at Primary Operation on Biliary Tract

Choledochostomy or exploration of the interior of the common and hepatic ducts

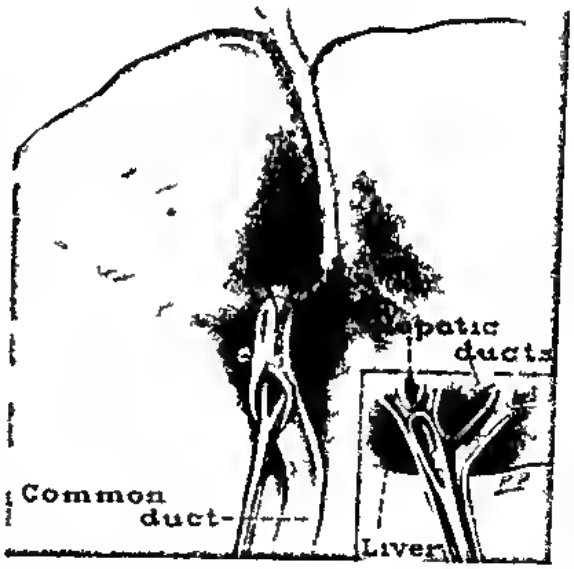


as a primary operation is usually not done until the diseased gallbladder has been disposed of either by cholecystectomy or cholecystostomy (rarely the latter in recent years) I think it is a good plan to sever the cystic duct and artery before opening the common duct thus preventing small stones passing into it through the cystic duct. In muscular or obese patients, traction on the gallbladder will assist in exposing the common duct. The common bile duct lies on top of the portal vein and lateral to the hepatic artery (Fig 12 3) Occasionally the hepatic artery or

its branches lie on top of or cross the common duct One of the characteristics of the appearance of the common bile duct (unless the wall is inflamed or thickened) is the presence of a small longitudinal vein on its visible portion Palpation of the duct is best carried out by the surgeon's inserting the first finger of the left hand into the foramen of Winslow and with the thumb above the structures in the hepaticoduodenal ligament and the palm of the hand directed inferiorly, the first finger and thumb are then moved upward and downward palpating the length of the common duct, the head of the pancreas, and the vicinity of the ampullary or papillary portion of the common duct

Whenever there is any doubt about the relative position of the common duct and the portal vein it is always safer to introduce an aspirating needle into the structure to be sure that bile is obtained and the structure is in the common duct and not the portal vein

Two Allis forceps are placed adjacent to each other (Fig 12 4*a*) in the middle or lower portion of the common bile duct and a small longitudinal incision about 1 cm in length is made in the anterior portion of the common duct (Fig 12-4*b* and *c*) Various sizes of exploring scoops from 2 to 7 or 8 mm in diameter are introduced into the duct, depending on its size The intrahepatic ducts are first searched for stones with a small scoop with a motion resembling that of curettage the bile that is removed is sent to the laboratory for culture Also, the motion used is one that allows the scoop to pick up in its bowl any stone that is present The scoop then is introduced downward into the duct until the resistance of a

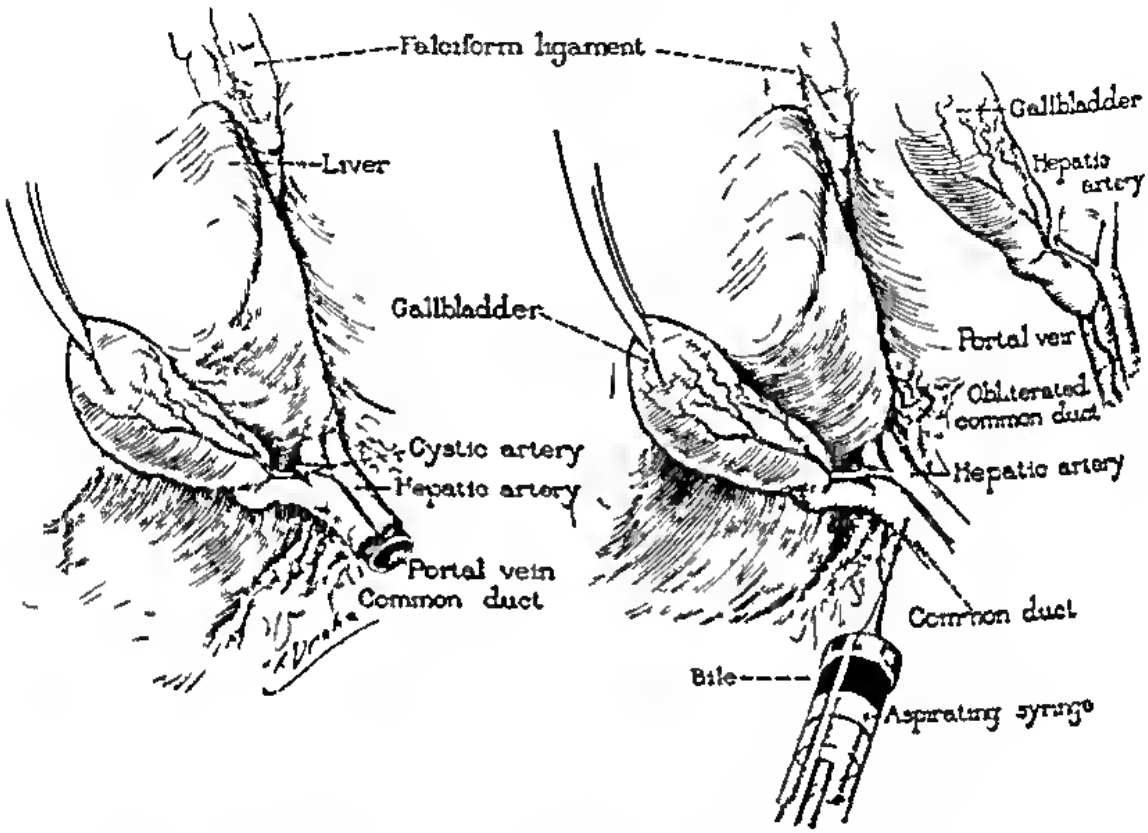


Fig 12 3 Anatomy of structures in the hepaticoduodenal ligament and needle aspiration of common duct *From* Walters, Waltman and Snell, V B *Diseases of the Gallbladder and Bile Ducts Courtesy* W B Saunders Co )

stone or of the sphincter of Oddi is encountered Resistance to the passage of the scoop into the duodenum is met at the sphincter of Oddi, and I frequently go to the patient s left side so that I can pass the scoop gently through the lower end of the duct with my right hand and use my left hand for palpating the lower part of the duct and for helping to manipulate the scoop through the sphincter of Oddi This must be done carefully because the mucous membrane of the duodenum around the ampulla can be torn or the common bile duct perforated when a small probe or scoop is pushed too forcibly in a downward direction It must be remembered that the lower part of the common bile duct extends somewhat mesially for a short distance before it takes a lateral direction past or through the head of the pancreas into the duodenum (Fig 12 5) These procedures should be repeated several times and between them the interior of the duct is irrigated forcibly with sterile water to dislodge and wash out any remaining stones so that they can be recovered at the next exploration of the interior of the ducts with scoops

### Technique at Secondary Operations on the Common Duct

To expose the common bile duct at a secondary operation, the hepatic flexure of the colon is dissected from the undersurface of the right lobe of the liver, and with it the second part of the duodenum, until the hepaticoduodenal ligament is reached A moist laparotomy sponge is placed between these structures and the anterior abdominal wall The direction of the dissection is then changed to the vicinity of the left lobe of the liver This lobe is elevated and the pyloric part of the stomach and the first portion of the duodenum are dissected from its undersurface, and from that of the right lobe of the liver mesial to the fossa formerly occupied by the gallbladder By doing this, one comes down to the hepatic artery, which can be seen to be pulsating, and this forms the mesial edge of the hepaticoduodenal ligament Thus, with the artery outlined and visible, one usually is able to identify the common bile duct by its appearance, or in cases of strictures of the common bile duct, by the aspirating needle If the duct is not stenosed, its identification is not difficult, and methods of surgical exploration of its interior are similar to those described when the operation is performed as a primary one When the ducts have

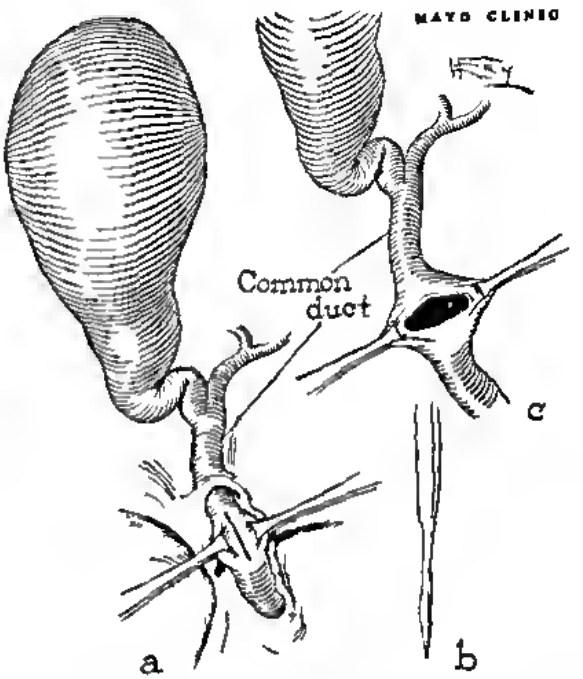


Fig 12 4*a*, *b c* Method of doing a choledochostomy (*From* Walters, Waltman and Snell, A B, *Diseases of the Gallbladder and Bile Ducts Courtesy* W B Saunders Co )

been searched with scoops for stones and a small 4 mm scoop has been passed through the ampulla, I usually follow it with a 6 mm or 8 mm scoop to dilate the sphincter of Oddi, in case there are small stones that might have been overlooked, or may be in the bile radicals within the liver and may slip down later with the secreted bile (Fig 12-1) As mentioned previously, it is worth while forcibly to irrigate the interior of the common duct after its exploration with scoops because in this fashion one usually can dislodge or wash out a small stone that may have escaped the exploring scoop

## Operative Risk at Cholecystectomy

In 1 000 operations performed at the Massachusetts General Hospital from 1943 to 1953, Bartlett and Waddell reported that exploratory choledochostomy at the time of cholecystectomy increased the risk from 0 6 per cent to 1 8 per cent In the experience of my surgical colleagues and myself at the Mayo Clinic the comparable figures for 1 130 operations performed on the biliary tract in 1956 were 0 13 per cent for cholecystectomy (751 cases) and 0 7 per cent (379 cases) when choledochostomy was added It must be remembered that in both these series and certainly in the Mayo Clinic series the cholecystectomy-choledochostomy group was not a selected group of cases but included all cases in which the common duct was opened and explored that is those with palpable stones and with obstructive jaundice resulting from benign obstructive lesions as well as the group in which the common duct was opened and explored to be sure that there were or were not stones present I mention this because in the absence of biliary obstruction I doubt whether properly performed accurate exploration of the common duct will add much to the risk of the associated cholecystectomy, unless the catheter or T tube used temporarily to drain the duct is removed too early, or stones or other lesions causing incomplete obstruction of the common duct are overlooked or the common duct is injured and local or general bile peritonitis or biliary fistula results

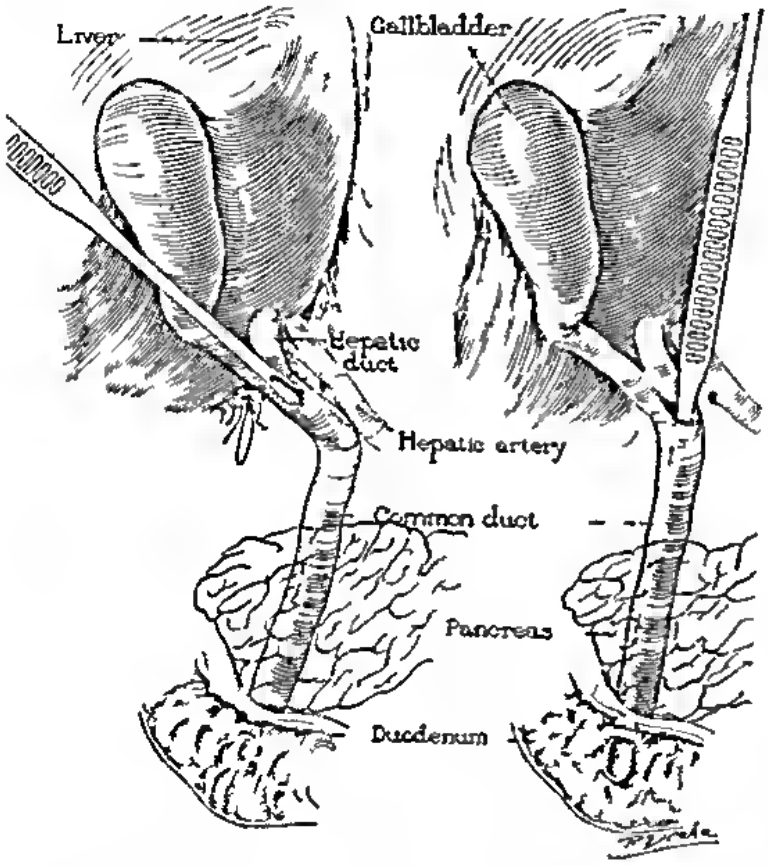


Fig 12 5 Diagram showing the horizontal direction of the upper part of the common bile duct and the lateral direction of the lower part Exploring scoops are in the duct and through the ampulla (*From* Walters, Waltman, and Snell L. B., *Diseases of the Gallbladder and Bile Ducts* Courtesy W B Saunders Co.)

## OPERATIVE CHOLANGIOGRAPHY

The indications for operative cholangiography are (1) uncertainty as to whether all stones have been removed from the common or hepatic duct (2) uncertainty as to position of hepatic ducts or the presence of accessory hepatic ducts or an

elongated cystic duct, and (3) uncertainty as to patency of hepatic ducts (ductal carcinoma or impacted calculi) and the lower end of the common duct (ampullary stone, carcinoma of the ampulla or papilla of Vater)

Operative cholangiography may be indicated too when small stones have been found in the gallbladder and in the cystic duct and uncertainty exists whether to open and explore the common duct.

Among my surgical colleagues who are particularly interested in surgery of the biliary tract, there is one (Ferris) who has expressed the belief that operative cholangiography is valuable as a routine procedure Writing with Weber, he has called attention to the fact that, although the results in 15 of the first 200 cases had to be disregarded because of inaccuracies of technique, in the next 185 cases there were seven in which small stones (4 to 8 mm in diameter) were demonstrated and removed which, he thought, would have been overlooked because the common duct was not appreciably dilated The problem, of course, is what size duct constitutes an enlarged one and also whether these single small stones might not have passed spontaneously The Scandinavians have estimated that 14 per cent will

My other surgical colleagues and myself believe that few stones will be overlooked if enlarged common ducts are opened and accurately explored by the methods that I have described earlier in this chapter In my own experience I have overlooked but seven such stones in ducts that I have explored in the past 13 years Postoperative cholangiograms have been made in all my cases in which exploration of the common duct has been carried out I have opened on many occasions, normal sized common ducts on the suspicion that small stones might be present, but I have found very few, and these were only 2 or 3 mm in diameter I think I have overlooked few common duct stones because the common duct has not been opened and explored I have had only one case to my knowledge in which it was apparent that a common duct stone that gave rise to symptoms necessitating its surgical removal later had been present at the time of the primary operation The patient was a man whose gangrenous gallbladder was removed and the common duct was not visible because of the degree of infection in the hepatic duodenal ligament

## RECURRING COMMON AND HEPATIC DUCT STONES

In my experience common duct stones seldom recur I have found stones in the common duct at reoperation in only four cases in which symptoms of biliary obstruction recurred after I had performed choledocholithotomy and in which the cholangiograms made after the operation had showed no evidence of stones In these cases, persisting biliary stasis with infected bile, I believe, was responsible *

In such cases, that is, cases of enlarged common ducts and edematous thickening of the pancreas, T tube drainage of the common duct should be prolonged for 6 to 8 weeks or until the common duct returns to normal size and empties normally as indicated by choledochograms made by injecting the dye through the T tube In recent years I have been doing more internal drainage by lateral (side to side) choledochoduodenostomy as advocated many years ago by Finsterer of Vienna, without apparent deleterious results The following case is one in point (Fig 12 6)

*Case 1 The patient, a man, gave a history* of having had for 10 years a feeling of fullness and nausea after a heavy meal No vomiting pain, or jaundice had occurred after dietary indiscretions He presented himself for examination at the Mayo Clinic on August 10 1953 The diagnosis was nonfunctioning gallbladder with stones Cholecystectomy was performed on August 24 The common bile duct was enlarged but no stones were found Exploration of the common duct with scoops encountered some obstruction at pancreatic portion of duct and some stony material was

* I reported several years ago a 75 per cent incidence of bacteria (Gram negative bacilli with and without streptococci and staphylococci) in the bile of patients on whom I had opened and explored the common duct.

removed from the ampulla Lateral choledochoduodenostomy was performed because of uncertainty of the cause of obstruction in the common duct Exploration of stomach and duodenum gave negative results The patient had an uneventful convalescence and was dismissed on September 18

The patient returned for examination in 1954 1955 and 1957 Roentgenograms of the stomach after a barium meal in 1954 and

Fig 12 6 (*Case 1*) Barium study of the stomach and duodenum 2 years following choledochoduodenostomy Common duct is filled with barium No symptoms of biliary obstruction or cholangitis

1955 showed barium outlining the biliary tract but in 1957 there was no regurgitation of barium into the biliary tract The patient reported in 1957 that he had had no colic or jaundice and felt fine

## USE OF T-TUBE DRAINAGE AND THE POSTOPERATIVE CHOLEDOCHOGRAM

Because of the edema that inevitably follows manipulation of scoops or dilators through the ampulla and the sphincter of Oddi, and the resulting increase in intraductal pressure, it is always advisable to drain the common bile duct by T tube (Fig 12 7) or a urethral catheter directed upward into the hepatic ducts as advised by Mayo Robson (Fig 12 8) These tubes should be left in the common duct for a sufficient period for a sinus to develop to the exterior so that when the tube, whether a Mayo Robson catheter or a T tube, is

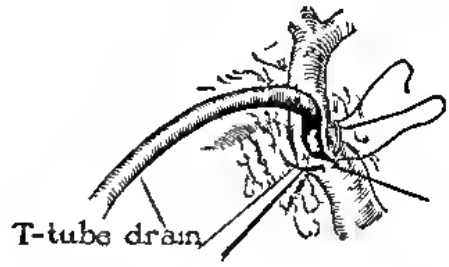


Fig 12 7 Introduction of T tube into the common bile duct (*From* Walters Waltman and Snell A B *Diseases of the Gallbladder and Bile Ducts Courtesy* W B Saunders Co )

Fig 12 8 Urethral catheter in hepatic duct (Mayo Robson) (*From* Walters Waltman and Snell A B *Diseases of the Gallbladder and Bile Ducts Courtesy* W B Saunders Co )

removed there is a secure sinus tract that will allow bile to drain to the exterior should there be obstruction in the lower portion of the common bile duct Whereas Mayo Robson catheters can be removed safely on the tenth day or later, I prefer to allow the T tubes to remain in a few days longer I have seen cases in which bile

Fig 12 9 Shadow of rectangular stone in lower part of dilated common bile duct

Fig 12 10 Deformity of lower part of common duct at ampulla suggesting a neoplasm

peritonitis developed when the tubes draining the common duct were removed in less than seven days

Tubes draining the common duct should not be removed until a choledochogram has showed evidence that the duct is free of stones, has returned to normal size, and empties into the duodenum If shadows of stones are present (Fig 12 9), another choledochogram should be made in a few days to exclude the possibility of an artifact, such as air, having been introduced with the radiopaque material Such air bubbles are always globular, frequently are small and multiple, and usually are located near the ends of the T tube In contrast to this is the single larger rectangular or elliptical shadow of the overlooked stone (Fig 12 10) If the common bile duct remains enlarged and no negative shadows are present in it, the cause of the failure of the duct to return to normal size may be edema in the head of the pancreas or persisting inflammation in the vicinity of the papilla of Vater It then is best to keep the T tube in for several weeks, not removing it until another choledochogram has been made which shows that the duct has returned to normal size and is emptying normally at the end of 10 minutes If two interval postoperative choledochograms indicate that none of the radiopaque substance passes through into the duodenum and there is not an elliptical negative shadow at the lower end of the duct a malignant lesion in the vicinity of the ampulla of Vater must be suspected (Figs 12 10, 12 11)

Fig 12 11 Papillary carcinoma causing ampullary obstruction of common duct

Before the T tube is removed, it is well to clamp it continuously for 3 or 4 days in order to determine clinically the patency of the common duct If, during this time, there is no leakage of bile around the vertical external portion of the T tube, if the patient has no pain in the vicinity of the liver and no fever, and if the stools are normally colored with bile, this usually is

sufficient clinical evidence to warrant removal of the T tube This clinical evidence should be used in connection with the postoperative choledochograms, for they complement each other and the choledochogram is necessary

## SHORT-CIRCUITING OPERATIONS ON THE COMMON DUCT

These operations consist of anastomosis between the common or hepatic ducts and duodenum or jejunum as a side to side, end to side, or end to-end procedure Usually, when a loop of jejunum is used, an enteroanastomosis is made between the two loops to divert food away from the anastomosis (Fig 12-12) It is thought by some surgeons that this is best accomplished, however, by dividing the jejunum and anastomosing the distal segment to the common or hepatic duct, and the proximal segment into the side of the distal one about twelve or fourteen inches below the biliary jejunal anastomosis thus making a Roux-Y anastomosis (Fig 12-13)

These surgical procedures are done for two reasons, first to restore biliary intestinal continuity in cases of stricture of the lower portion of the common bile duct, or in other cases to relieve pressures in the biliary ducts that result either from incomplete obstruction in the vicinity of the ampulla of Vater or from more nearly complete obstruction from a lesion in the head of the pancreas In patients with definite neoplasms in the head of the pancreas that are thought to be inoperable bile can be short-circuited around the site of the biliary obstructions by anastomosing the gallbladder to the stomach (cholecystogastrostomy), to the duodenum (cholecystoduodenostomy), to the jejunum (cholecystojejunostomy), or the common duct can be anastomosed to the duodenum (choledochoduodenostomy) or to the jejunum (choledochojejunostomy)

Although I prefer to use the duodenum

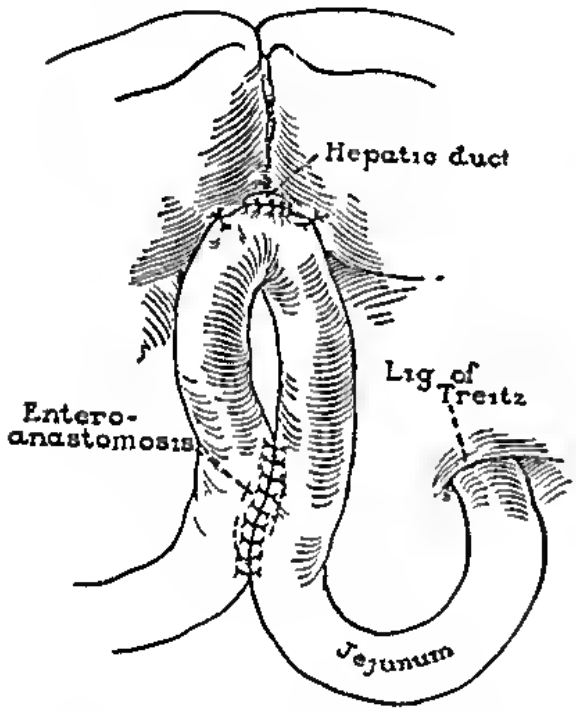


Fig 12 12 Loop hepaticojejunostomy with enteroanastomosis

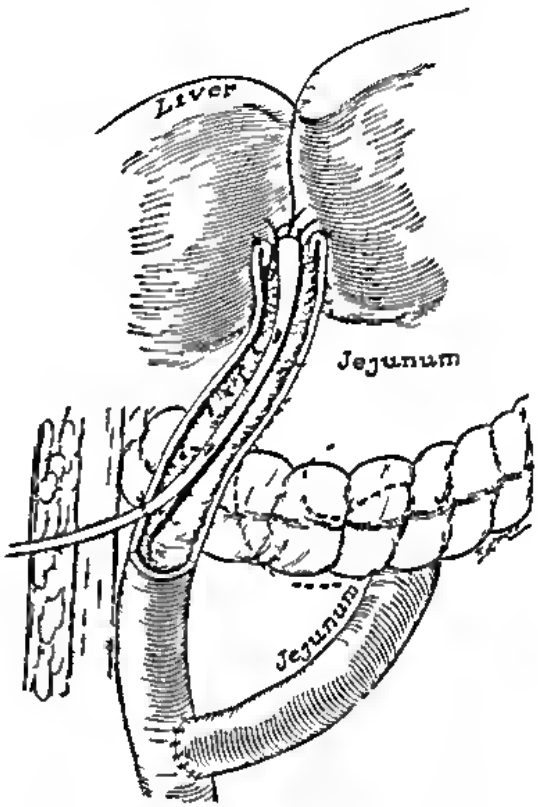


Fig 12 13 Roux Y hepaticojejunostomy

(Fig 12 14) instead of the jejunum when the biliary intestinal anastomosis is to relieve obstruction resulting from extensive stricture of the common duct I prefer not to use the duodenum in cases of pancreatic obstruction because duodenal motility may be disturbed and duodenal obstruction to the passage of food and bile may occur when the lesion is a carcinoma and increases in size

For many years I have performed cholecystogastrostomy on patients with inoperable malignant lesions of the head of the pancreas without any apparent deleterious clinical effect. The operation is easily performed frequently it can be done almost entirely under local anesthesia of the anterior abdominal wall It is always effective in relieving biliary obstruction and I have not known of any ill effect on the patient as a result of entrance of bile into the stomach Conversely I have not seen any clinical evidence of cholangitis developing in such cases from the possible passage of material from the stomach into the gallbladder during the phase of gastric emptying Should chills fever or jaundice develop after the obstruction has once been relieved these symptoms of cholangitis are due to biliary obstruction The same applies when these symptoms appear after biliary intestinal anastomosis for benign obstructions

## POSTCHOLECYSTECTOMY SYNDROME

This term is used to indicate persistence of symptoms suggestive of a lesion of the biliary tract after cholecystectomy The symptoms may vary from attacks of pain in the right upper quadrant requiring morphine for relief to milder attacks usually occurring in the daytime but sometimes waking the patient at night Or the distress may be qualitative food dyspepsia a feeling of gaseous distention after eating such foods as cabbage apples and cauliflower Sometimes the distress may be described as being worse since the gallbladder was removed Sometimes jaundice or fever may follow the attack and this indicates an organic lesion most likely a common duct stone or inflammation of the wall of the common duct associated with pancreatitis and cholangitis Or the symptoms may be due to intrahepatic cholangitis of unknown origin or to such medicaments as chlorpromazine hydrochloride (Thorazine) or testosterone

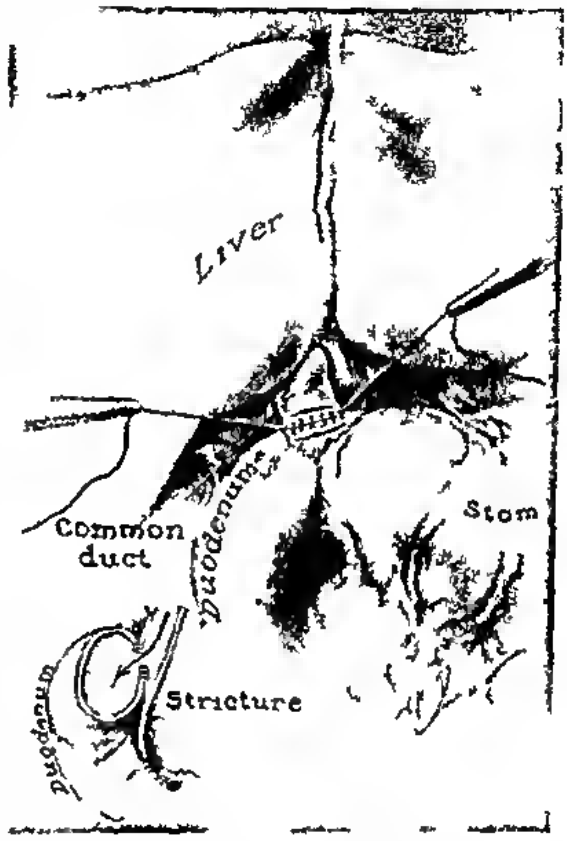


Fig 12 14 Technique of choledochoduodenostomy (*From* Walters Waltman and Snell A B *Diseases of the Gallbladder and Bile Ducts Courtesy* W B Saunders Co )

If such tangible evidence of common duct obstruction as jaundice and fever is lacking the differential diagnosis of the cause of the pain may be impossible without abdominal exploration and sometimes not even then The reasons for this are many (1) The patient may not have had sufficient cholecystitis at the time of the cholecystectomy to have indicated the need for the cholecystectomy this is particularly true if gallstones are not present (2) The patient may have had other abdominal lesions, such as a small ulcer on the

posterior wall of the duodenum with a crater too small to be visualized roentgenographically or recurring chronic pancreatitis that produced the pain in the right upper quadrant (3) Dysfunction of the sphincter of Oddi with or without inflammation or fibrosis or both may be present In these cases as well as in those with chronic pancreatitis the causal relationship of the anatomic findings at operation and the patient's symptoms may be difficult to determine even at operation Thus the proper surgical procedure may be debatable

As examples of these problems let us discuss dysfunction of the sphincter of Oddi in relation to pancreatitis Doubilet and Mulholland have reported that more than 90 per cent of their patients (169 patients) with chronic pancreatitis have been relieved of their attacks of pain by transduodenal sphincterotomy The theoretic basis for the procedure is that with the main pancreatic duct and the ampulla of the common bile duct having a common opening spasm, fibrosis, or inflammation of the sphincter may increase pressure in the common duct and cause bile to enter the pancreatic duct As a result pancreatitis develops Others have not had such successful results from sphincterotomy The reason for this probably is explained by the work of Kleitsch He has shown that in at least 10 per cent of 33 cases studied at necropsy the opening of the main pancreatic duct was separate from the ampulla of the common bile duct and in an additional 60 per cent a large branch of the main pancreatic duct likewise emptied into the duodenum proximal to the opening of the ampulla of Vater

In two cases in which there was nothing to explain the postcholecystectomy colic and in which I performed transduodenal sphincterotomy, spasm of the wall of the common duct with marked increase in common duct pressure (up to 360 mm of water) occurred 3 months after sphincterotomy This occurred in each case at

of Oddi into the duodenum In one case the radiopaque material (Umbrathor) used for the choledochogram was forced into the pancreatic duct by the spasm in the wall of the common duct (Fig 12 15) In one of the cases at the height of the pain and the increased intraductal pressure an injection of procaine hydrochloride into the region of the splanchnic nerves immediately relieved the pain, although it had no effect on either the ductal spasm or the intraductal pressure Only about 60 per cent of the patients on whom I have performed sphincterotomy have been relieved of pain in the right upper quadrant of the abdomen by this procedure

If inflammation and enlargement of the head of the pancreas are of sufficient magnitude, they may cause varying degrees of obstruction of the common duct When the obstruction is only partial, pain may be produced, and when the obstruction is of a maximal degree, jaundice follows In such cases the common duct is always enlarged, and I have preferred internal drainage by lateral choledochoduodenostomy rather than prolonged external drainage with a T tube However, Comfort, Gambill, and Baggenstoss have reported complete relief of pain in 39 per cent of cases of chronic pancreatitis and partial relief in 22 per cent after prolonged (3 months) internal or external (T tube) drainage of the common duct The sphincter of Oddi had been dilated with exploring scoops in these cases

Unfortunately, chronic pancreatitis does not always cause enlargement of the common duct Moreover, it is exceedingly difficult without biopsy to make an accurate diagnosis of chronic pancreatitis If it is proved to be present, my order of procedure is to try the effects of prolonged (3 months) T-tube drainage of the duct first If this is effective, the attacks can be relieved by opening the T tube should they occur when the tube is clamped If under these conditions the attacks recur

the injections of procaine are temporarily effective, then an alcohol block using 5 to 6 cc of absolute alcohol is done, usually doing but one side at a time The alcohol block may be effective for 4 to 5 months at a time and can be repeated with equally good results, at which time it may be done bilaterally at one sitting If the attacks continue after the effectiveness of the second alcohol block has worn off con

reasons are two in number (1) An en larged duct may be due to narrowing of the pancreatic portion of the common duct by an enlarged head of the pancreas If such an obstruction is producing ductal spasm, sphincterotomy would not be effec tive (2) An accurate lateral anastomosis between a small or normal sized common duct and the duodenum is difficult, and it is doubtful whether it would remain

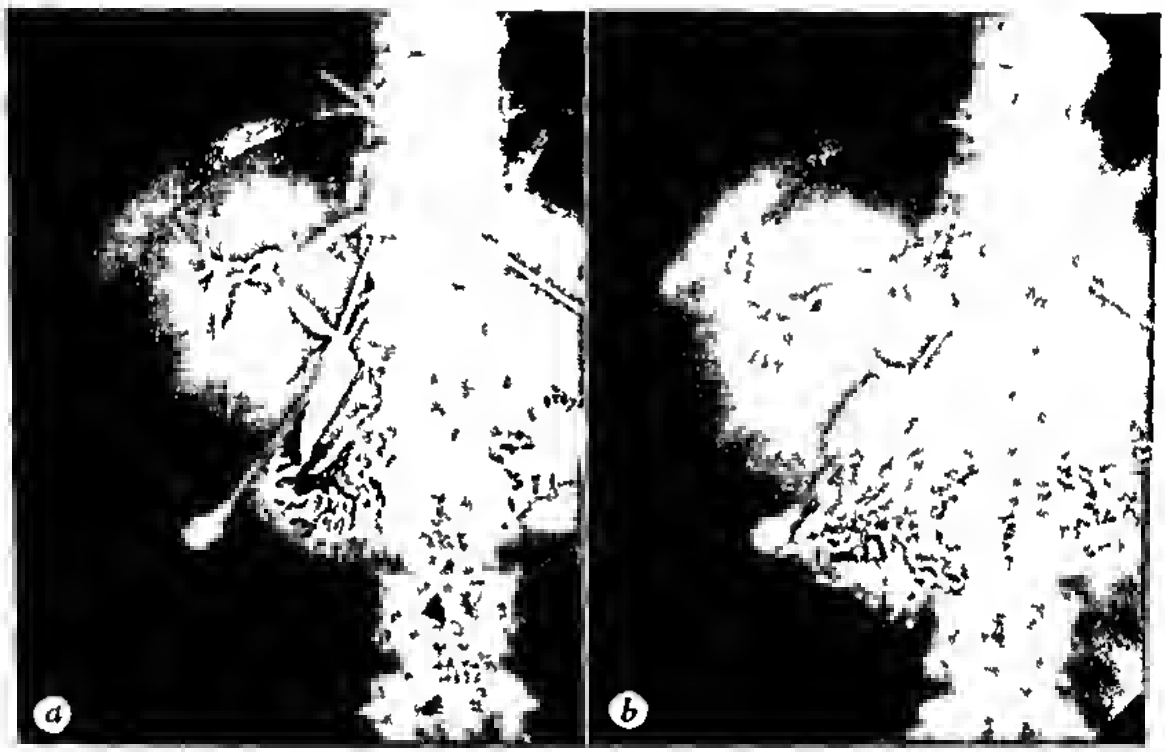


Fig 12 15 Postoperative sphincterotomy (3 months) (a), Spasm of lower end of common bile duct with reflux of radiopaque substance into the pancreatic duct Needles have been placed in the vicinity of the splanchnic nerves (b), Further injection of radiopaque material into the common duct Increase of pressure did not cause pain after splanchnic nerve block with procaine hydrochloride

sideration should be given to another ex ploratory operation to examine the common duct and pancreas (and other abdominal structures including the aorta, as well as retroperitoneal areas in and around the kidneys and adrenal glands) At this time the surgeon must decide whether to perform transduodenal sphinc terotomy or choledochoduodenostomy My preference is sphincterotomy if the duct is small and lateral choledochoduodenos tomy if it is enlarged The principal

open for any period without more biliary obstruction being present

I have used all the methods mentioned as individual and combined procedures with good results, but I have seen cases in which, although each method or combination of methods used was effective for a time, painful attacks have returned, and splanchnic block with alcohol have been repeated In one case chordotomy, done because of the severity of the painful attacks, gave complete relief of symptoms

## Technique of Sphincterotomy

The common duct is opened and explored with scoops for stones and forcibly irrigated with water A 4-mm scoop is passed through the sphincter of Oddi and the degree of resistance to its passage is noted After the sphincter of Oddi is dilated, the scoop is left projecting into the lumen of the duodenum and a small incision is made in the anterior wall of the duodenum opposite the sphincter of Oddi By elevating the scoop, the duodenal mucous membrane overlying the sphincter is brought into view, and the opening of the papilla is found with the scoop extending through it One blade of a pair of pointed scissors is then inserted through the sphincter and a small incision is made, 6 to 8 mm long, which should expose the interior of the ampulla However, an incision by a scalpel is better, I believe, because the surgeon then can accurately see the extent of the incision through the sphincter If bleeding occurs, it is controlled by a single suture of catgut Care is taken to place this suture so that it may not obstruct the opening of the pancreatic duct Unfortunately this opening cannot always be identified, hence, the suture should be superficially placed in a radial direction from the cut edge of the sphincter The scoop is then withdrawn, and a short T tube is inserted into the common duct If it is desired to insert a long T tube, one limb extending through the sphincter of Oddi, a suture is tied to the neck of the scoop, which is pulled up through the opening in the common duct, and the suture is attached to the lower limb of the long T tube to be pulled through the divided sphincter The diameter of a long as well as short T tube should be smaller than the common duct. This is necessary for the short tube so that it will not obstruct the ampullary opening of the pancreatic duct, and for both tubes so that bile can pass along side of them There is always the possibility that partial obstruction of the common duct may occur from scarring contracture at the site of sphincterotomy I have recently (December 1957) had to do a choledochoduodenostomy on such a patient who had had a sphincterotomy in October 1957 A long T tube had been inserted at sphincterotomy and inadvertently removed early (seventh postoperative day)

In other words, a long T tube passed through the divided sphincter and kept in for three months is less likely to prevent this scarring contraction than a small T tube even though it may interfere with the function of the pancreas by either infection or obstruction of the opening of the pancreatic duct in the ampulla of Vater

## REFERENCES


Bartlett, M K, and Waddell, W R Indications for common duct exploration Evaluation in 1000 cases *New England J Med 258* 161, 1958

Comfort, M W, Gambill, E E and Baggenstoss, A H Chronic relapsing pancreatitis Study of twenty nine cases without associated disease of the biliary or gastrointestinal tract *Gastroenterology 6* 239, 376, 1946

Doubilet, Henry, and Mulholland J H Eight year study of pancreatitis and sphincterotomy *J A M A 160* 521, 1956

Ferris, D O, and Weber, H M Evaluation of routine operative cholangiography *A M A Arch Surg 73* 197, 1956

Kleiber, N Zur Frage der peroralen Darstellung der Gallenblase *Deutsche med Wchnschr 2* 1134, 1940

Kleitsch, W P Anatomy of the pancreas A study with special reference to the duct system *A M A Arch Surg 71* 795 1955

Lanzecker, H, Harwart A, and Junkmann, K 2 1 6-Trijod 3 acetamino benzoesaure-Abkommlinge als Kontrastmittel *Arch exper Path u Pharmakol 220* 195, 1953

Priestley, J T Walters, W, Walsh J M, Judd E S, and Hallenbeck G A Annual report on surgery of the biliary system and pancreas for 1956 *Proc Staff Meet Mayo Clin 32* 605, 1957

Trommald J Quoted by Bartlett, M K, and Waddell, W R

MEDICAL COLLEGE
LIBRARY
UDAIPUR

CHAPTER 13

# BENIGN BILIARY STRICTURE

*William P. Longmire, Jr., and Harvey N. Lippman*

In spite of the fact that for many years the diseases which the biliary tract is heir to have been successfully attacked and conquered, the surgical world is still woefully handicapped by the need of a simple safe method of transmitting bile from the liver to the duodenum in the absence of the gall bladder and common duct The high mortality attending cases in which the common duct has been partially or totally destroyed is a sad commentary on our helplessness, which is due largely to the lack of an efficient means of dealing with the situation A casual review of the cases reported in the current literature of the last year impresses one forcibly with the seriousness of any pathologic process which destroys the common duct *

Although it was written nearly fifty years ago, this comment, which appeared in the *Journal of the American Medical Association,* is as timely today as it was when first recorded The surgical management of benign biliary stricture has passed through many different phases in the past half century, but at this writing there is still no tissue or material that may be consistently and satisfactorily utilized to replace a loss of substance or to bypass a severe stricture in the extrahepatic biliary ducts While there are a number of reasonably satisfactory methods of reconstituting biliary enteric continuity, the long term follow up of these procedures, too, leaves a great deal to be desired

There is little doubt as to the proper direction of our efforts for the future The causal relationship between benign extrahepatic biliary stricture and accidental trauma to the ducts incident to the performance of an ordinary cholecystectomy is well established Perhaps less well appreciated, however, is the fact that cholecystectomy is at the present time second only to appendectomy as the most commonly performed major abdominal surgical procedure in the United States If further progress is to be made in the control of this problem, our efforts must be directed not so much toward correction of the strictures that occur but toward prevention of the antecedent injuries to the extrahepatic biliary ducts

## INCIDENCE AND ETIOLOGY

It is very difficult to determine the actual incidence of benign extrahepatic biliary stricture from the figures published in the surgical literature In general, these cases are "collected" by a few major institutions and their published experience obviously does not reflect that of the average clinical surgeon There is recent evidence to the effect that more of these cases are being seen, however, and the possibility of an absolute rise in this number has caused concern

During the years 1938 to 1941, benign fibrotic stricture of the bile ducts repre-

* A G Sullivan, *J.A.M.A* 58 2026, 1912

sented about 2 per cent of all biliary tract surgery performed at the Lahey clinic in Boston Between 1946 and 1947, such operations accounted for 8 to 9 per cent of all biliary tract surgery at this same institution Johns, writing in 1952, indicated that since 1945 there had been 81 separate articles published in the American literature on the techniques of repairing extra hepatic biliary tract injuries Coincident with this sudden new interest, the late Dr Howard Gray, speaking in London before the Royal Society of Medicine in 1951, reported that there had been an absolute rise in the incidence of benign fibrotic stricture of the biliary tract in the United States and that this rise was related to the fact that a higher proportion of major abdominal surgery was being done by less qualified surgeons in this country during the war years While this contention is impossible to substantiate, the implication is probably true There is little doubt that the incidence of this disease is directly related to the quality of the surgery being done in the performance of the ordinary cholecystectomy

## Accidental Injury

Accidental trauma incurred during the course of cholecystectomy and similar types of surgery account for about 80 per cent of all benign extrahepatic biliary strictures The remaining 20 per cent are due to such entities as pancreatitis, duodenal ulcer, eroding biliary calculi, and primary and secondary cholangitis, the exact percentage of each is subject to considerable variation Nonpenetrating trauma with extravasation of bile is a rare cause of biliary stricture

Accidental trauma may occur in the hands of skilled surgeons and in the finest of hospitals, although, generally speaking, the risk under these conditions is considerably less Trauma of this nature is not necessarily limited to the difficult case From the nature of the injuries that have occurred in the past three important mechanisms are apparent (1) unexpected bleeding, (2) confusion with regard to the local anatomy in the region of the porta hepatis, and (3) simple accidents The term unexpected is used in reference to the serious bleeding that may occur, because it is the suddeness of such incidents that leads the operator into maneuvers that he may later have reason to regret The bleeding is usually from a torn cystic artery, although it may occur from an injured right hepatic artery The area is often difficult to expose, and when the blood suddenly starts to well up in the wound, the grave concern on the part of the surgeon may be understood It is his inexperience and lack of judgment that lead him to stab blindly in a pool of blood for the torn end of the cystic artery and it is little wonder that he finds the common bile duct or the common hepatic duct with his clamp as frequently as he is able to secure the end of the bleeding vessel The wisdom is not in securing the cystic artery through a pool of blood but in knowing the basic anatomy sufficiently well that, should such bleeding occur, it is immediately stopped by the classical maneuver of putting the forefinger in the foramen of Winslow and compressing the hepatic artery anteriorly against the thumb The bleeding point may then be discovered with little difficulty and considerably less excitement

Injuries to the ducts that are incurred in this fashion usually cause delayed strictures, which develop six to eighteen months after the operation The portion of the duct that has been clamped will gradually be replaced by fibrous tissue and become scarified and constricted It is under these circumstances that the postoperative course offers no hint of the tragedy later to occur Occasionally, portions of the ductile system may be included in the ligature used to control the elusive bleeder" Here, of course jaundice may occur promptly after operation and the situation be immediately apparent

It is not necessary to commit to memory the many anatomic variations that may occur in the triangle of Calot It is important, however, to know that such variations are very common The triangle of

Calot has as its base the cystic artery and its apex is the angle formed by the junction of the cystic and hepatic ducts Confused by unfamiliar anatomic variations the operator may inflict many types of serious injury on these structures One should always demonstrate and identify every important structure in this region before dividing anything There are few areas in the body in which more lasting harm can be inflicted accidentally in a few short seconds than in the region of the extrahepatic biliary ducts

The mechanism of a simple accident may not necessarily be related to either of the other two The patient may be thin and the exposure excellent the operative field may be perfectly dry and the anatomy classical It has been said that under certain circumstances the case may progress too easily The implication here is that insufficient care is taken to identify all the important structures because everything appears simple and obvious It is under conditions such as this perhaps that the common bile duct is tented by traction on the gall bladder as the clamp is being applied to the cystic duct or the cystic duct ligature is placed in such a manner that it partially or completely occludes the common bile duct

Accidental injury to the extrahepatic biliary ducts may occasionally be inflicted during the course of other operative procedures in this area Implicated most often in this respect is the gastric resection that is performed for a difficult duodenal ulcer The accident usually occurs as the operator attempts to mobilize a severely scarred and edematous duodenal stump for closure The common bile duct is often drawn into the field by inflammation and scarification and unless certain precautions are taken it may be divided ligated or otherwise compromised When it becomes apparent that the dissection of a duodenal stump may proceed beyond ordinary limits injuries to the common bile duct are best avoided by performing an elective choledochostomy as originally suggested by Lahey The sensation of a soft rubber tube within the common duct provides added security to the surgeon as he dissects about the duodenal stump

Exception has been taken by certain authors to the practice of performing a cholecystectomy in the presence of acute inflammation of the gallbladder with the implication that biliary tract injuries are more likely to occur under these conditions The fact is that the great majority of injuries to the biliary tract occur during elective cholecystectomy the ratio to emergency procedures being almost four to one It is true however that cholecystectomy is today performed more and more frequently for both acute and chronic disease and in fact as indicated previously is at present second only to appendectomy as the most frequent major abdominal operation to appear on the surgical schedule A procedure so commonplace lends itself to consideration by the surgeon and the occasional operator alike as one of the less serious abdominal operations The young trainee is frequently allowed to do this procedure as an early test of his skill and the uninitiated will often accept the responsibility of performing a cholecystectomy with as little concern as he would an appendectomy or herniorrhaphy

Such practices and attitudes are mentioned here only to be condemned Certainly any type of operative procedure is potentially dangerous but cholecystectomy must be considered among the more serious operations and its performance must be attended by the highest degree of skill if we are to deter the apparently increasing incidence of accidental injuries to the extrahepatic biliary ducts

When a biliary stricture follows a cholecystectomy and cholecystectomy the burden of proof that the stricture is not related to the operative procedure falls upon the surgeon who has performed the operation It is obvious that such a relationship is very difficult to disprove For this reason when the stricture has been preceded by an operation it has often been categorically assigned to the group caused by trauma By these rigid standards only strictures that occur spon

example is provided by the gradual narrowing and eventual stricture of the intrapancreatic portion of the common bile duct, which may follow a long standing chronic pancreatitis Other examples include the penetrating duodenal ulcer, which causes obstruction of the common bile duct by regional edema and scar, and the choledochal calculus, which on occasion may erode the mucous membrane and eventuate in scarification, narrowing, and finally stricture formation

Apart from the usual secondary inflammatory stricture, there is the occasional case that occurs after operation and to which no immediate etiology may be assigned Donaldson and associates state that the events that follow the performance of cholecystectomy may produce stricture without necessarily impugning the original surgical technique Infection, blood, and bile, which pool about the extrahepatic ducts without adequate drainage, are thought to be sufficient cause for late fibrotic obstruction Cole has written that as many as one third of his cases of stricture were due to nonoperative trauma of this nature Although trauma is never completely excluded under these circumstances, there are instances in which it is fairly clear that trauma is not the basis for the difficulty These lesions may be confused with primary inflammatory strictures and, as often as not, it is probable that such a consideration has been overlooked at the time of the original operation However, certain cases undoubtedly do originate after cholecystectomy and are unrelated to trauma It is probable that the mechanism suggested by Cole and others accounts for some of them, as for the rest, the exact etiology is not clear

## PATHOLOGY AND PATHOLOGIC PHYSIOLOGY

The essential pathology of a benign extrahepatic biliary stricture is related almost entirely to the regurgitation of bile and its effect upon the liver The loss of the normal physiologic properties of bile that result from its complete exclusion from the intestinal tract without being lost to the body is of relative significance only Unrelenting fibrous occlusion of the common bile duct or common hepatic duct invariably follows an established pattern that begins with obstructive jaundice, is punctuated periodically by bouts of chills and fever, and inevitably ends in some complication of advanced biliary cirrhosis

In order to understand the pathologic physiology of biliary regurgitation, it is appropriate to review briefly the normal physiology of the formation and secretion of bile The secretion of bile by the liver is a continuous process It proceeds under a head of pressure that may reach as high as 300 mm of water At this point, secretion ceases and jaundice appears Bile is a complex mixture containing primarily the sodium salts of glycocholic and taurocholic acid, cholesterol, lecithin, and bilirubin, a pigment that represents the end product of the normal metabolism of hemoglobin Bilirubin is derived from hemoglobin by the action of the reticuloendothelial cells of the body, which are located primarily in the liver, spleen, bone marrow, and lymph nodes It finds its way through the blood stream to the liver where it is taken up by the hepatic cells and secreted into the biliary ductile system In passing through the polygonal cells of the liver, bilirubin is changed into a more soluble substance capable of being excreted by the kidneys This alteration takes place under the influence of a specific hepatic enzyme which promotes the conjugation of bilirubin and glucuronic acid The normal course of the soluble pigment is along the biliary channels and into the intestinal tract The action of resident bacteria in the bowel converts the bilirubin into urobilinogen A portion of the urobilinogen is excreted in the stool, the remainder is reabsorbed into the portal circulation and returned to the liver where it is reconverted to bilirubin In turn, the latter is again secreted in the bile A trace of urobilinogen may escape into the systemic circulation from which it is excreted via the kidneys It can be detected in the urine as urobilin into which

rhagic tendency Thymol turbidity is not altered by this procedure, and consistent with this is the absence of any detectable inflammatory change in the liver The animal shows systemic signs of illness such as anorexia and apathy at about four weeks after the onset of the experiment

When the gallbladder is in continuity and the ducts are obstructed, the bile becomes dark green to black in color depending upon the duration of the obstruction When the gallbladder is absent the fluid within the ducts gradually becomes colorless it consists of the mucous secretion of the duct walls and is called white bile'

Parenchymatous and ductile changes occur slowly after experimental obstruction of a major hepatic duct in the dog or cat These pathologic alterations have also been collected and recorded by Moncrief After four to six weeks, the obstructed duct is grossly dilated and the ductile epithelium shows varying degrees of atrophy The small peripheral ducts do not share in this process however, and the lining cells remain cuboidal although the lumina of the ducts are obliterated and their number per unit area is increased After four to six months there is an irregular growth of richly nucleated fibrous tissue around the hepatic lobules, there may be a marked decrease in the number of bile ducts At twelve to fourteen months the fibrous tissue assumes a more mature appearance and the bile ducts are greatly dilated The individual lobules appear smaller in size, although the liver cells are unchanged A small amount of bile is constantly present outside the biliary passages in the periportal areas Grossly, the appearance of the liver is unchanged for four to six months, then the lobular outline becomes more distinct After twelve months an irregular shrinkage occurs and the surface assumes a roughened appearance

The pathologic pattern demonstrable in the human is very much the same as that seen in the experimental animal There is a progressive dilatation of biliary ducts with inspissation of bile in the small cholangioles and occasionally into the canaliculi between the liver cords There is also a progressive increase in the amount of fibrous tissue radiating from the portal areas As the fibrous tissue increases in amount and maturity, the lobular structure of the hepatic lobules is accentuated Eventually, extensive scarring may obliterate the lobular architecture and destroy the normal pattern of the portal triads resulting in the familiar picture of Laennec s cirrhosis It is of interest that once the process has progressed this far, it is not possible to distinguish between cirrhosis that results from obstruction of the extrahepatic biliary tree and that which results from malnutrition and the imbibition of alcohol or from viral hepatitis and other causes

The problem of biliary obstruction is rarely encountered chronically without superimposed infection The exception to this is in infants with congenital atresia or aplasia of the biliary system that remains unconnected directly to the intestinal tract Infection adds the cellular exudate associated with inflammation to the familiar pattern of obstruction, and in effect it accelerates the progressive scarring process that leads to cirrhosis Infection alone or at least without known extrahepatic obstruction, will also lead to cirrhosis, and as we have seen in infants with congenital obstruction the reverse is also true

## DIAGNOSIS

The diagnosis of benign biliary stricture usually resolves itself into the differential diagnosis of a patient with jaundice, although on occasion the former may be made in the absence of this important clinical sign

Patients with fibrotic extrahepatic biliary stricture are usually female and in the middle age group, about 70 per cent being under 50 years and at least 25 per cent in the fourth decade of life. This corresponds with the age distribution and sex of patients with gallbladder disease with which this disorder is intimately associated About 80 per cent of patients will have a

history of previous gallbladder surgery or some type of operation on the biliary tract Oftentimes, one may elicit a history of some unusual incident in connection with this operation References to excessive bleeding, poor exposure, or a difficult anesthetic may be noted in the operative record In certain cases a definite history of common duct injury and primary repair may be elicited from the operating surgeon

In considering the diagnosis of benign biliary stricture, one must first distinguish between those cases of obstructive jaundice that occur promptly after operation and those that develop gradually over a period of months or years after cholecystectomy or some other operation on or near the extrahepatic biliary ducts Patients in the first group offer little challenge as far as diagnosis is concerned, the relationship to the immediate operation being obvious Patients with delayed jaundice however, even when a history of common duct injury and primary repair is elicited, may be very difficult to differentiate from the large group of patients suffering from diseases that manifest themselves in this same manner Obstructive jaundice that develops within the first week after operation on the biliary tract is almost always due to some mishap that has taken place at the time of the original operation However, more than half the patients who subsequently prove to have a benign extrahepatic biliary stricture will not be jaundiced within this early period because of the decompression afforded by an external biliary fistula When biliary drainage lasts for more than one week after cholecystectomy there is a strong indication that some injury has been incurred Biliary drainage that subsides in less than one week is usually insignificant, coming as it often does from the divided, small, accessory bile ducts in the fossa of the gall bladder In those cases in which choledochostomy has been performed, the presence of an injury to the extrahepatic duct may not be apparent until an attempt is made to clamp the T tube or catheter preparatory to removal These patients will not tolerate such a maneuver if the integrity of the duct is compromised distal to the point of drainage

The symptoms of delayed biliary stricture are due to progressive fibrotic obstruction of the extrahepatic ducts and to infection within the biliary tree The degree to which each of these factors is important varies from one case to another In certain instances, obstruction may be almost complete and yet the patient be essentially asymptomatic and not jaundiced except during infrequent attacks of cholangitis In other cases, progressive, increasing, obstructive jaundice may be the cardinal feature of the patient's illness One is occasionally very much surprised to find at operation that while the common bile duct or the functioning biliary channel is too small to admit a probe, the patient s serum bilirubin is normal The explanation for this is probably associated in some manner with the consistency of the patient s bile Infection superimposed upon a narrowed segment of the biliary duct will often cause symptoms of obstruction that are relieved as soon as the infection subsides The bile may be shown to be more viscid during this time and to contain flocculi of mucus

The onset of symptoms in a delayed stricture is usually insidious, although the whole picture may be ushered in by chills and fever Pain may not be a prominent feature of this disorder, although biliary colic and vague upper abdominal distress are described Scleral icterus is often the first visible sign of disturbance Dark colored, foamy urine and light colored stools will soon follow Pruritis may be a very annoying and early complaint Repeated episodes of cholangitis with chills and fever, loss of appetite, and deepening jaundice are characteristic. The presence of a persistent external biliary fistula following a previous operation on the gall bladder or common bile duct is prima facie evidence of biliary obstruction While any obstructing mechanism may be responsible for such a fistula, a stricture must certainly be excluded In certain instances the fistula may close temporarily, but

usually under these circumstances there is a reappearance of jaundice punctuated by bouts of cholangitis until the fistula recurs

Examination may be of little help except for the yellowish discoloration of the skin and mucous membranes The liver is often somewhat enlarged and tender If the disease has been allowed to progress, there may be definite signs of malnutrition and weight loss Peripheral edema, ascites, ecchymosis, a flapping tremor, and a distinct fetor hepaticus are late signs of hepatic deterioration Evidence of portal hypertension implies the existence of advanced biliary cirrhosis This may be demonstrated by the presence of esophageal varices An enlarged spleen may or may not be present

The urine of a patient with biliary obstruction is dark colored, owing to the excretion of bile Urobilin is absent when the obstruction is complete, and the stools may be very pale or clay colored, containing no bile or urobilinogen An elevated serum bilirubin or icterus index is noted on examination of the blood, and a van den Bergh test usually gives a direct reaction

The serum alkaline phosphatase is almost always elevated in this disease above 10 to 15 Bodansky units The prothrombin content of the blood may be reduced to 50 per cent or less of normal but will respond favorably to parenteral vitamin K therapy within twenty four hours if hepatic deterioration is not advanced The serum transaminase is often normal or only slightly elevated Glutamic oxalacetic transaminase values up to 200 to 250 units are consistent with a diagnosis of biliary stricture Cephalin flocculation and thymol turbidity tests are almost always negative, at least in the early phases of the disease before the liver has been seriously damaged When, after prolonged obstruction, these tests may become positive, their value in the differential diagnosis decreases considerably because of the superimposed parenchymal liver disease

The differentiation of delayed biliary stricture from one of the other mechanical obstructing agents that affect the extrahepatic biliary tract is somewhat academic, inasmuch as the treatment for these disorders is the same, i e, exploration and determination of the nature of the obstructing mechanism and the performance of some type of definitive procedure to reestablish biliary continuity The important problem lies, however, in the differentiation of the mechanical extrahepatic obstruction from the primarily intrahepatic parenchymal disorder that is not benefited by operation To operate unnecessarily under these circumstances is not only wasted effort but may cause considerable harm The liver status is often so precarious that the added trauma inflicted by an anesthetic and operation can tip the scales for an unfavorable outcome

## Differential Diagnosis

VIRAL HEPATITIS Primary viral hepatitis is usually associated with general malaise, anorexia, and nausea, often before the appearance of clinical icterus The patient complains of weakness and ease of tiring The appearance of the yellowish tinge to the sclerae is often merely incident to the systemic illness There may be a low grade fever Examination may not be very helpful in the differentiation from biliary obstruction The laboratory data, on the other hand, are often of considerable assistance Although bile is noted in the urine, urobilin may be elevated rather than absent In certain cases, however, the reverse is true The stools are variable in color but may be pale or even clay colored in appearance The cephalin flocculation and thymol turbidity tests are usually positive—a strong point of differentiation The serum transaminase, low or only slightly elevated with biliary stricture, is almost always elevated with viral hepatitis Glutamic oxalacetic transaminase values over 300 units are common, and if over 500 or 1,000 units, the diagnosis of stricture is very unlikely Coronary occlusion, massive muscle-crushing injuries, and pancreatitis are the only other clinical entities known to produce such high transaminase values

PRIMARY BILIARY STRICTURE Included in this category are the various primary inflammatory diseases of both the intrahepatic and extrahepatic biliary tree, which manifest themselves by obstructive jaundice and are unfortunately often differentiated from other causes of extrahepatic obstruction only at laparotomy The onset of illness may be rather vague and indefinite Pain and epigastric discomfort anorexia and nausea are usually followed by the appearance of jaundice Physical examination and the laboratory may only confirm the existence of obstructive jaundice In the absence of a previous operation on or near the biliary tract, it is not difficult to rule out a traumatic stricture but an obstructing common duct stone or more often a pancreatic carcinoma may be impossible to exclude without exploration At operation the surgeon is usually surprised not to find one of these more obvious causes of biliary obstruction He may encounter one of several situations (1) The obstructing mechanism may be entirely intrahepatic, located at the level of the smaller biliary ducts or cholangioles Nevertheless, this situation will not be readily apparent, inasmuch as the extrahepatic ducts will appear to be quite normal Operative cholangiography will not be very helpful The diagnosis may be made by liver biopsy, although by this time it has usually been suspected While it is perhaps a misnomer, the term cholangiolitic hepatitis' has been rather commonly associated with this particular syndrome In the authors' opinion, it represents one of several clinical manifestations of primary inflammation of the biliary tract (2) In the second instance, the obstructing mechanism may be entirely extrahepatic, involving only the major ducts The ducts are usually small in caliber and their walls are often very thick The lumen will sometimes not permit the entrance of the smallest T tube On occasion the narrowed area is limited in size, but usually it involves the entire extrahepatic ductile system This condition has often been designated by the term obliterative cholangitis' (3) The third situation that may be encountered is a combination of the other two Both the intrahepatic and extrahepatic ductile systems may be involved by this primary inflammatory disease, thus creating a most difficult therapeutic problem

In the opinion of the authors this is a progressive disease that is not helped by surgery and usually ends in fatality

BILE DUCT CALCULI It is not uncommon after cholecystectomy to be required to differentiate a stricture from a common duct stone As indicated previously however, this may be of academic interest only, inasmuch as both conditions usually require surgical intervention The jaundice associated with an obstructing calculus is classically intermittent whereas the jaundice of a stricture may be progressive and unrelenting One cannot rely on this feature of the clinical story, however, for as previously indicated, one may have a typical fibrotic extrahepatic biliary stricture in the absence of clinical jaundice and, in fact, in the absence of an elevated serum bilirubin The findings and laboratory tests made under these circumstances may be of very little help As long as the liver will secrete dye, a cholografin study may define the calculus in the common duct As often as not, however, the depth of the jaundice or the degree of liver damage precludes this possibility

DRUG HEPATITIS Certain drugs such as Thorazine, methyl testosterone cinchophen, sulfonamides, thiouracil, and para aminosalycilic acid (PAS) are known to cause a type of jaundice that may be very difficult to differentiate from the jaundice produced by a common duct obstruction The history of intake of one of these drugs in the absence of a previous cholecystectomy is strong evidence against a stricture The other mechanisms of common duct obstruction are not excluded as easily and are frequently differentiated only by operation

DUBIN-JOHNSON SYNDROME Since 1954 the differential diagnosis of jaundice has included a newly described disease of the liver known as chronic idiopathic jaundice Described independently by Dubin and

Johnson and Spinz and Nelson, the disease is characterized by chronic or intermittent jaundice, abdominal pain, fatigue, dark urine, hepatomegaly, bromsulfalein retention and failure to visualize the gallbladder by either oral or intravenous cholecystography The disease has a familial tendency The intermittent quality of the jaundice also characterizes the other symptoms Idiopathic jaundice is considered to be an inborn error of metabolism and has an excellent prognosis as far as the life of the patient is concerned Because of the favorable prognosis, it is most important that this disease be differentiated from the more serious causes of extrahepatic biliary obstruction, though this is seldom done without surgical exploration

NEOPLASM Malignancies of the common duct, the ampulla of Vater, or the head of the pancreas may all present symptoms of obstructive jaundice and must be excluded in any differential diagnosis of benign biliary stricture Certain common duct malignancies are very slow-growing and desmoplastic and, in fact, may look grossly very much like benign strictures In lesions of the ampulla, gastroenteric bleeding is not infrequently noted and may, in certain cases, be the first sign of difficulty The classical inverted three ' pattern seen in the duodenum with barium contrast often identifies the lesion before exploration Contrary to earlier teaching, pain in the back is a frequent symptom in carcinoma of the pancreas

Benign neoplasms of the extrahepatic bile ducts are less common than malignancies They may become large enough, however, to obstruct the duct and enter into the differential diagnosis of jaundice

## CHOICE OF OPERATION

The causal relationship between benign biliary stricture and accidental trauma incident to the performance of an ordinary cholecystectomy is well established In considering the choice of operative procedure that is to be utilized in the restoration of biliary continuity, one must first distinguish between the procedure carried out at the time that an injury is incurred, or shortly thereafter, and the operation that may be performed for the relief of stricture at some later date (delayed stricture) In the first situation, one is dealing with relatively normal tissues and a patient who is generally a satisfactory operative risk In the other instance, there may be considerable scarring of tissues, obliteration of normal anatomic landmarks, as well as a patient who is often less than satisfactory as an operative risk Primary definitive repair of an injured common bile duct or common hepatic duct is not a frequent occurrence to judge from the statistics provided by a series of cases reported by Donaldson and associates in 1956 Out of 85 cases which later proved to have traumatic biliary stricture, only 9 were treated by definitive surgery at the time the injury was incurred There may be several reasons why such injuries would not be treated at the time of the original operation but it is apparent in retrospect that most of them were simply not recognized

Considered generally with the group of primary operative repairs are those patients who are operated upon again shortly after the original operation because of evidence of compromised biliary continuity Obstructive jaundice that becomes apparent within the first week after cholecystectomy or excessive biliary drainage from the wound that lasts longer than one week are both strong indications that some mishap has occurred and re exploration is usually warranted

It is of interest that very little information is available regarding the outcome of primary corrective procedures performed at the time of accidental injury to the bile ducts As already indicated, not many of those cases are recognized at the original operation, and this coupled with the fact that few primary repairs are ever reported accounts for the lack of reliable data on this subject In a small series of patients personally known by the authors and in each case followed from the time of the original operation, an injury to the duct

was repaired immediately by a primary end to end anastomosis In every instance the formation of a fibrotic stricture required further operative intervention in order to re establish biliary continuity Although the number of patients was small (5), the consistent failure of the duct to duct anastomosis performed under these conditions is impressive

In the past great stress has been placed upon the value of the sphincter of Oddi in the prevention of regurgitation of bowel content into the biliary ducts This time honored principle has served as the basis for the popular notion that biliary enteric continuity should always be restored by a procedure that preserves this sphincter One cannot quarrel with the idea that the sphincter of Oddi may prevent regurgitation into the common bile duct, but there is reason to believe that this particular point may be less important in the selection of an operation designed to re establish biliary continuity than heretofore understood In any case as a primary procedure for the restoration of biliary flow following accidental injury to the extrahepatic biliary tree the value of the standard end to end anastomosis of the duct is seriously questioned

On the other hand, through experience gained principally with the Whipple operation there is considerable evidence attesting to the fact that the common bile duct or common hepatic duct may be anastomosed primarily and directly to the enteric tract without subsequent stricture formation Mathewson, using the Roux Y principle in restoring enteric and biliary continuity, found no strictures in 30 consecutive Whipple operations Longmire and Engel studied 50 patients in whom some type of reconstructive operation had been done on the biliary tract. They, too noted consistently good results in those patients who were reconstituted by primary biliary-enteric anastomosis as compared with patients in whom end to-end ductule repairs had been utilized The exact method of bringing the bowel to the proximal end of the bile duct is as controversial a problem in the primary repair as it is for delayed biliary stricture. Moreover, the choice is the same and lies between choledochoduodenostomy and a loop or Roux Y choledochojejunostomy

The authors have preferred to re-establish biliary enteric continuity under these conditions by means of a long Roux Y limb of jejunum However, despite the evidence to the contrary included in the preceding paragraphs, there is not at present sufficient experience with any type of primary repair other than an end to-end anastomosis to warrant recommending any change in this essentially universally accepted method of reconstruction

The choice of procedure under conditions that require a secondary operation to restore biliary enteric continuity for a delayed biliary stricture does not appear to depend necessarily upon the same factors that determine the procedure of choice for a primary operation The selection of a secondary procedure is governed by (1) the presence or absence of an external biliary fistula, (2) the number of previous attempts made to restore biliary continuity (3) the general condition and age of the patient, and (4) the more specific condition of the patient s liver Having determined that it is necessary to re explore the patient's right upper quadrant then (a) the length of the stricture (b) the disparity in size of the duct proximal and distal to the stricture, and (c) the availability of duct above and below the stricture, all provide information from which a decision is made as to the definitive procedure to be used in the restoration of biliary continuity Complete excision of the stricture has been emphasized by many authors and the type of repair will necessarily depend upon the amount of duct available *after* the stricture has been excised Procedures that do not include excision of the stricture have in the past met with little success At one time it was recommended practice, in a small discrete fibrotic stricture to open the duct longitudinally through the narrowed area and close it transversely in the manner of Heineke Mikulicz. Some authors dilated such strictures by means of an instrument

such as the Bakes dilator and placed a T tube in the duct for several months to maintain the flow of bile The recurrence rate utilizing these procedures eventually precluded their further use A similar fate has befallen the operation of implanting an external biliary fistula into the upper gastroenteric tract This procedure consisted of creating an external biliary fistula, where one did not exist, and later dissecting it out for the purpose of conducting the biliary secretions into the stomach, duodenum, or a loop of jejunum In this instance the formation of scar tissue about the implanted fistula almost invariably resulted in recurrent stricture formation and obstruction to the flow of bile

If, after complete excision of the stricture, the two ends of the common bile duct or common hepatic duct may be mobilized and approximated end to-end without tension in an accurate mucosa to mucosa anastomosis, in the minds of a number of surgeons this would be the procedure of choice in the reconstitution of the extrahepatic biliary tract This does not mean to say, however, that even those individuals who recommend this operation believe that an end to-end anastomosis is necessarily the best procedure available under any and all conditions When there is marked or even moderate disparity in size between the two segments of the duct, when the distal end has to be dissected out of the head of the pancreas and is found to be inadequate, when it is apparent that the distal end of the duct consists primarily of scar tissue, or when for any reason an accurate anastomosis cannot be constructed, one should be prepared to abandon the end to-end anastomosis for one of the other available procedures

There are several methods by which one may connect the proximal portion of the common bile duct or common hepatic duct to the intestinal tract Each procedure has its advocates, its advantages, and its drawbacks Most authors are agreed that the stomach is not suitable for this purpose Its walls are too thick for an accurate anastomosis and the presence of highly acid secretions within the stomach is considered a strong disadvantage The duodenum has been used for many years in this connection W J Mayo first introduced the choledochoduodenostomy in 1905, and to this day surgeons at the institution that bears his name are the strongest advocates of this particular procedure Walters has emphasized the simplicity of the surgical technique and the low morbidity of this operation He has always been a strong proponent of the idea that reflux of duodenal content into the biliary ducts made no difference whatsoever, and that when patients did manifest evidence of cholangitis following such a procedure, there was always a recurrent stricture at the point of anastomosis There are many who agree with Walters and there are many patients alive and well today upon whom this operation has been successfully performed Certainly, choledochoduodenostomy and hepatoduodenostomy have earned a rightful place in the surgical management of this disorder

The jejunum has also been used successfully to conduct biliary secretions under these circumstances from the stump of the common hepatic duct in the hilus of the liver It may be brought up to the biliary channel as a loop, or a Roux Y limb may be utilized for this purpose as suggested originally by Allen and almost simultaneously advocated by Cole

The authors favor the principle implied by the use of the defunctionalized jejunal limb for secondary repair of biliary strictures, and have utilized the Roux-Y limb for anastomosis to the biliary tract both at the hilus of the liver and, as will be noted shortly, in the intrahepatic approach with resection of the left lobe of the liver In recent years choledochojejunostomy utilizing the Roux-Y principle has been selected as the method of choice in the reconstruction of all secondary strictures, and even when the distal end of the duct has been readily available, reconstruction of biliary flow is rarely accomplished by an end to-end ductile anastomosis

We now come to a group of cases in which for all practical purposes nothing further may be accomplished to re estab-

lish biliary enteric continuity at the hilus of the liver In this type of case more than one attempt has usually been made at repair in the right upper quadrant as often as not three or more failures have resulted from this approach The intrahepatic cholangiojejunostomy was designed to re establish biliary enteric continuity in those patients in whom the other methods have failed Oftentimes these patients will have reached the end of their rope both physically and emotionally and further attempts to explore the right upper quadrant under these conditions are fruitless The late Frank Lahey observed that with each unsuccessful attempt at duct repair, the chances of a satisfactory and lasting outcome progressively diminish After two three and four or more failures the likelihood of finding an adequate unscarred piece of proximal common hepatic duct to anastomose to the enteric tract in the hilus of the liver is very small indeed Simply to bring a loop or Roux Y segment of bowel up to the porta hepatis without a mucosa to-mucosa anastomosis is a waste of effort The intrahepatic cholangiojejunostomy is based upon laboratory and clinical demonstration of continuity between the ductile systems of the right and left lobes of the liver and the fact that by tapping the major biliary channel in one lobe both lobes may be adequately drained The intrahepatic approach avoids the right upper quadrant entirely The abdomen is opened on the left side the major part of the left lobe of the liver is resected and an end to side anastomosis is carried out between the major left intrahepatic duct and a Roux Y limb of jejunum The intrahepatic ductile system must be dilated if this procedure is to be employed Under most conditions in which this operation will be considered however such will be the case In the authors experience the presence of an external biliary fistula draining from the hilus of the liver is probably a contraindication to the intrahepatic approach The provision of an adequate biliary enteric anastomosis does not necessarily result in spontaneous closure of the fistula In our experience such cases are best approached again through the right upper quadrant

## Choice of Procedure in Primary Stricture

If it could be determined preoperatively that a particular stricture was of the variety that has been designated in previous sections as *primary* it would be the authors recommendation to avoid an operation Unfortunately, however such cases are often discovered by accident while exploring for other possible causes of extrahepatic biliary obstruction. The operator faced with a thickened narrowed duct and jaundice usually feels compelled to open the duct and explore it In the past it has been recommended practice to drain such ducts indefinitely with a small-caliber T tube, the rationale being that bile in the intestinal tract acts as a strong biliary secretagogue By diverting the bile via the T tube it was assumed that the activity of the liver would be decreased thereby encouraging subsidence of the inflammatory condition within the bile ducts Improvement in this condition has in fact been reported by this method of management

In the experience of the authors however primary stricture of the extrahepatic biliary system or obliterative cholangitis is part of a larger disease entity that includes as well its intrahepatic counterpart cholangiolitic hepatitis The etiology as previously indicated is unknown and the course is almost invariably progressive and downhill T tube drainage adds nothing beneficial to this situation and may even be considered harmful Certainly the irritation caused by a foreign material such as rubber upon an already inflamed duct cannot be of much benefit in this particular situation

## EVALUATION AND PREOPERATIVE PREPARATION

The preparation of the patient for operation is one of the most important considerations in the management of these cases The patient is often depleted both

physically and mentally as the result of a long and usually costly illness and will require the utmost of our skills as both physicians and surgeons If the disease has been long standing, the factor of liver damage will frequently limit whatever we might hope to accomplish for any particular patient Biliary cirrhosis in certain instances is so far advanced that very little may be gained by decompressing the biliary tree The authors have had the experience of being able to demonstrate very adequate biliary drainage from both lobes of the liver following intrahepatic cholangiojejunostomy but, because of damage incurred prior to this operation the patient remained jaundiced and finally succumbed to the complications of the disease Thus, it is part of the preparation of such a patient for surgery that the proper evaluation of his general status be determined

In a patient with benign obstruction of the extrahepatic biliary tract, an evaluation of preoperative status consists essentially of determining how much damage has been incurred by the liver Although there are numerous laboratory procedures available, the physical examination of the patient is more valuable prognostically than any liver function test If the patient is well nourished and well muscled, if he presents no evidence of peripheral edema ascites or ecchymoses and if he has no fetor hepaticus, one may be fairly certain that such an individual has satisfactory liver function If the patient has a good appetite during an afebrile period, particularly a good appetite for meat, and if he tolerates such a high protein diet without signs of impending liver failure, such as mental confusion, torpor, flapping tremor, and fetor hepaticus, it is evident that his liver is not so seriously damaged that he will not tolerate an operation safely In addition he will probably derive a satisfactory result from decompression of the biliary tree

The level of jaundice or serum bilirubin is of little significance prognostically The prothrombin time and, more significantly, its response to parenteral vitamin K is of considerable importance in establishing the degree of resiliency of the liver and its ability to restore itself The total serum proteins may reflect the inability of the liver to elaborate serum albumin but of much more importance is a direct measurement of the serum albumin itself Reversal of the ratio between albumin and globulin, classically incontrovertible evidence of cirrhosis and depressed liver function, is not as important as the level of serum albumin in establishing the efficiency of liver function The albumin may be normal and the albumin/globulin ratio reversed owing to elevation of the globulin fraction In the absence of jaundice, bromsulphalein retention is an excellent laboratory aid in the evaluation of liver function Values over 20 per cent are considered highly significant

Other preoperative procedures that may be of help are x ray studies of the upper gastrointestinal tract, intravenous cholangiography (cholografin), and esophagoscopy Each of these diagnostic tools has its place and under a given set of circumstances may be most valuable Esophageal varices may be discovered either by x ray study or esophagoscopy Cholografin studies although generally valueless in the presence of jaundice, may occasionally give considerable information

In the event that the patient does not measure out satisfactorily on evaluation for an anticipated procedure, certain measures may be taken to improve his status Obviously, until the stricture is relieved, all these measures are of temporary value only However, adherence to a regulated program for a few days to several weeks may improve the patient's chances considerably These measures are directed primarily at a poor nutritional state The patient is offered a high caloric high carbohydrate, low fat, and, if he tolerates it, a high protein diet with large vitamin supplements, particular attention being paid to the fat soluble vitamins A, D, and K These are specifically lost to the patient with complete obstruction owing to a biliary stricture because of the absence of bile in the enteric tract, and replace-

ment must be by the parenteral route The prothrombin time is an index of the effectiveness of the vitamin K, the others require no special measurement Patients with advanced biliary cirrhosis often manifest hypoalbuminemia This may be specifically replaced with serum albumin or whole blood, the latter probably being better if the individual is anemic and hypovolemic as well Antibiotics are reserved for the patient with cholangitis The authors have used Chloromycetin in the usual dosage with very gratifying results

## SURGICAL MANAGEMENT

### Basic Principles

In the surgical management of benign fibrotic stricture of the extrahepatic biliary tree, whatever type of procedure is utilized to re establish continuity between the biliary system and the gastrointestinal tract, certain principles must be observed

1 The stricture and all scar tissue with in the wall of the obstructed duct should be excised as completely as possible Any procedure that utilizes the stricture in the repair is predisposed to failure To remove *all* the scar tissue in the wall of the duct is usually an impossibility and, therefore, one must compromise somewhat in order to have a sufficient amount of bile duct with which to work

2 The anastomosis between the two structures must be made accurately The importance of a mucosa to-mucosa anastomosis has long been stressed by all authors in this particular field

3 The inner row of the anastomosis must be made with fine, interrupted, absorbable suture material Continuous sutures tend to draw up on the opening between the two structures and predispose to further stricture formation Nonabsorbable suture has been known to remain in place for long periods of time and to act as a nidus for the formation of stones Nonabsorbable material may be used for support in the outer row of the anastomosis

4 The anastomosis should be performed over some type of stent that may remain in place for protracted periods of time. Such splints should be readily removable at the desired time After six months, internal biliary splints probably cause more harm than good

5 Anastomoses between various portions of the biliary tract or the biliary tract and the bowel must be free of tension and properly drained Attention to small detail may make the difference between success and failure

### Technique of Exposure

The extrahepatic biliary stricture may be approached by a long right subcostal incision that crosses the mid line (Fig 13-1) Since the operation for the stricture often follows a previous cholecystectomy or a previous attempt to repair the stricture, there is usually some type of scar or several scars in the right upper quadrant of the abdomen If the existing scar happens to be in the line of the intended incision it should, of course, be excised However, one should not hamper his exposure for this procedure in any way and the existence of a previous scar should not necessarily determine where the new incision is to be placed Should the ordinary right subcostal incision prove to be inadequate one may extend the incision subcostally for a variable distance down the left side (Fig 13 2)

Certain patients with a narrow costal arch or with an unusually large and firm liver will offer great difficulty of exposure. There are two other incisions that may be used in these difficult cases. The Marwedel incision, originally described in 1903, has the advantage of allowing the operator considerably more exposure without the necessity of opening into the chest the other employs the thoracoabdominal approach

The Marwedel incision has been adapted for either side of the abdomen and has proved to be a most valuable adjunct in certain cases (see Fig 13-15 as applied to the left side) The incision used

today is much the same as that originally described by its author The skin and subcutaneous tissues are divided down to the costal margin The superior flap of the incision is dissected upward and the lower rib cage exposed In this flap are the lower fibers of origin of the pectoralis major muscle and slips of the rectus muscle The muscular attachments are freed from the costal arch with the exception of the fibers of origin of the diaphragm The sixth and seventh costal cartilages are divided anteromedially and the ninth and tenth costal cartilages laterally The ends of the intervening sixth, seventh, and eighth ribs are severed and the entire anterior costal arch is reflected superiorly as a flap without opening into the pleural cavity

The combined thoracoabdominal incision permits the superior displacement of an enlarged liver in such a manner that the porta hepatis is brought anteriorly into the wound One may employ a transverse abdominal incision that curves up and crosses the costal arch into the eighth interspace or the intercostal portion may be combined with a paramedian incision on the same side of the abdomen (Figs 13 3, 13 4 13 5, 13 6, 13 7) Whenever the chest is opened it is always drained to an underwater trap

The closure of any of these incisions must be carried out with great care Drains and tubes should not be brought through the incision but through stab wounds placed to one side of the main wound T tubes or catheters should be brought through the abdominal wall at points convenient to their exit from the structure that they are intended to drain Interrupted, fine nonabsorbable sutures are used for the closure of these wounds In the larger percentage of patients it will make little difference what type of closure is employed. However, the jaundiced, hypoproteinemic, and malnourished patient will usually require additional consideration and a careful, interrupted fine

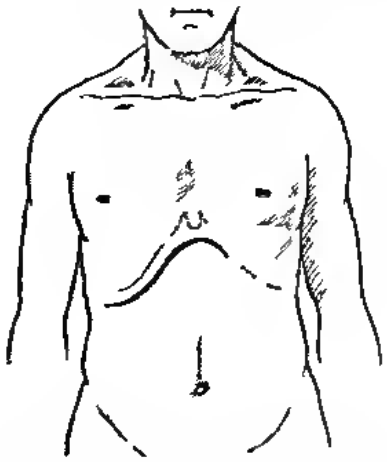

Fig 13 1 Benign biliary stricture The abdomen is usually entered through a right subcostal incision which crosses the mid line

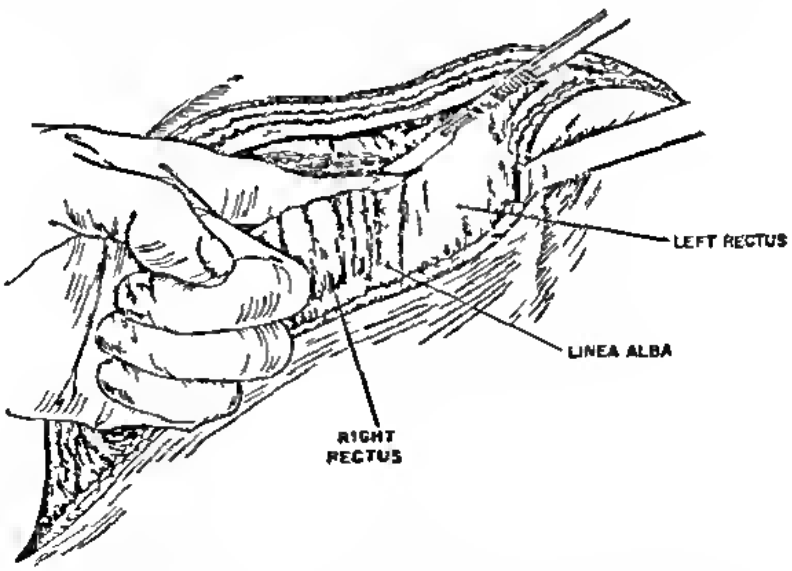


Fig 13 2 Benign biliary stricture When necessary, the incision may be extended a variable distance down the left side

silk closure serves this purpose Retention sutures are not used in these cases In recommending silk or cotton it is with the knowledge that more of these wounds will later reject some of the sutures than if cat gut had been employed However it is

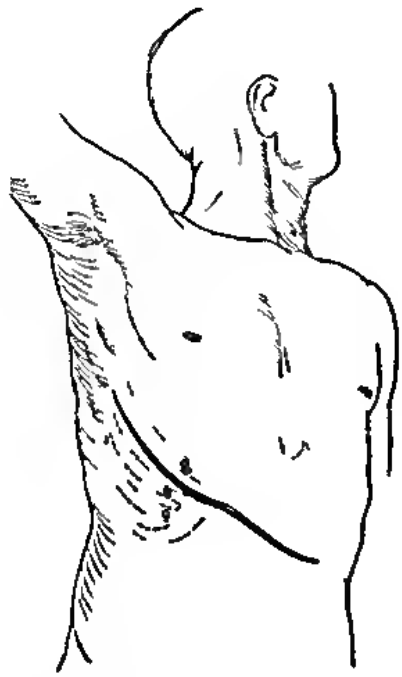

Fig 13 3 Benign biliary stricture right thoracoabdominal incision

felt that this additional risk is a fair exchange for the security of such a closure

## Technique of Dissection

The major problem in re exploring the right upper quadrant in many of these patients lies in the extensive adhesions through which one must dissect before reaching the real area of operation This is a matter of degree and is directly related to the number of previous explorations that have been carried out Anatomic landmarks are often of little significance and the adhesions may be particularly dense In approaching the porta hepatis one must first enter the abdomen laterally and discover the liver edge This edge is traced medially and anteriorly and then by sharp and often tedious dissection the inferior surface of the liver is freed from the adjacent colon duodenum stomach and omentum until the hepatoduodenal ligament is defined (Figs 13 8 13 9) If it is possible to locate the foramen of Winslow the problem is simplified considerably Anterior to a finger placed in the foramen are the three structures in which the operator is most interested the hepatic artery, portal vein and common bile duct Usually, the anatomic relationship of these three structures is considerably altered by scar tissue and adhesions so that their individual identification often depends upon other features A small gauge needle on a syringe may be of considerable assistance in this regard The hepatic artery may be identified by its regular pulsations It is generally the most anteriorly placed and the most readily recognized of the three structures Once located a piece of umbilical tape should be placed around the vessel in order to facilitate further dissection and mobilization (Fig 13 10) The portal vein is found at times with great difficulty It is the most posteriorly placed structure in the ligament and because of the density of the adhesions and the compressibility of the vein it may be opened inadvertently during this phase of the dissection If such an accident should occur the rent in the vein is simply oversewn with a running fine silk suture Once recognized the portal vein should be encircled with a nonocclude tape and carefully avoided (Fig 13 10)

Having identified two of the major structures in the porta hepatis discovery of the third is greatly facilitated The nature of the biliary channel which is located in the hepatoduodenal ligament depends upon the size and location of the stricture that is present this in turn is related to the etiology of the stricture Traumatic strictures are most frequently located in the common hepatic duct Strictures secondary to disease in the pancreas or duodenum are usually found within the distal (intrapancreatic) portion of the common bile duct Primary inflammatory strictures often involve the entire intrahepatic as well as the extrahepatic biliary tree and secondary non traumatic postoperative strictures may

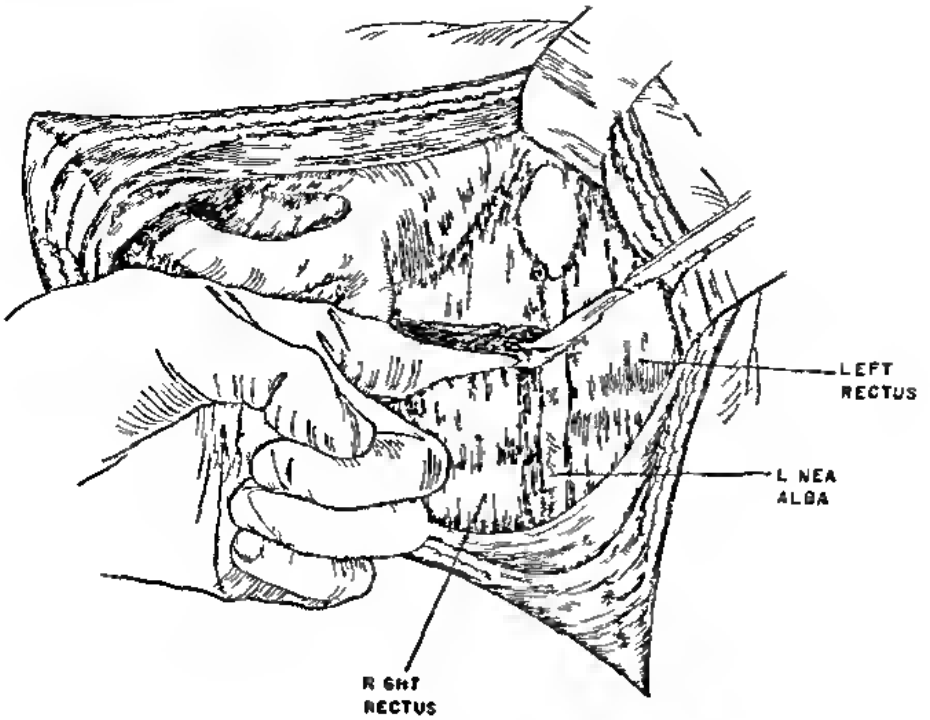


F g 13 4 Be gn b liary str ctu e right thoracoabdom nal nc s on The r ght rectus muscle is be ng d v ded

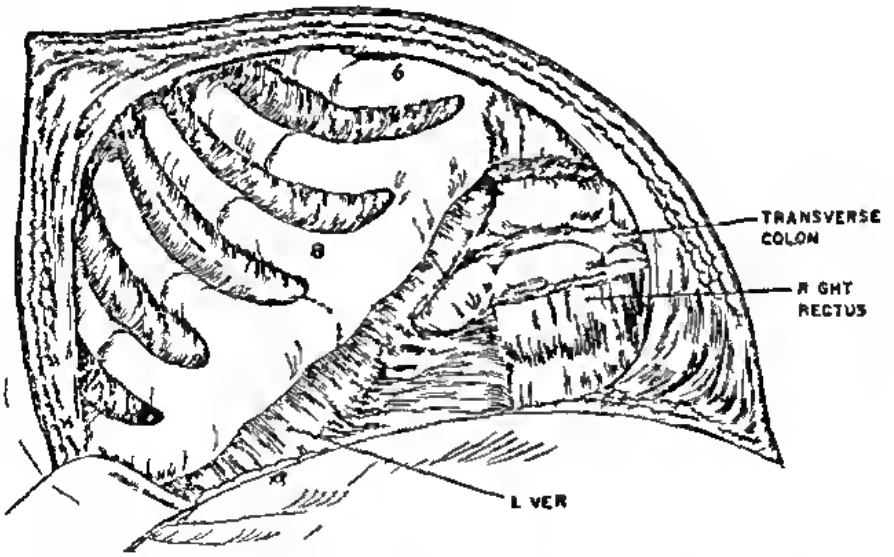


F g 13 5 Ben gn b l ary s ure rigl t tl oracoabdom nal nc s o i The abdo en has been entered and the costal n arg n s about to be d v ded to nter l e e ehth erco tal space

often impl cate tl e major portion of tl e extral epatic bil ary system If a stricture is localized and complete tl e duct above it will l e dilated and the duct below col lapsed Tl e d ct distal to tl e str cture is in fact often small and its identification may be exceedingly difficult or in pos s ble Tl e proximal end of the ob structed duct n ay usually be located by repeated a p irations in tl e porta l epatis and then by very careful dissection a bulbous tl umblike project on of variable size is def ned (Fig 13 11) Tl is bulbous structure is opened as close to its distal tip

as possible and the lumen explored The patency or lack of patency of the narrowed area as well as the distal portion of the duct is determined A malleable probe is passed as far as it will go in both directions and, if possible, it is passed into the duodenum through the papilla of Vater Under certain conditions, it may be necessary to open the duodenum in order to explore the common bile duct through the papilla of Vater

At this point, the decision must be made as to the manner in which biliary intestinal continuity will be reconstituted. If the discrepancy between the lumen above and below the stricture is not great, and if after complete excision of the stricture and scarred duct, the two ends may be approximated accurately without tension one may elect to perform an end to-end anastomosis. Obtaining sufficient usable duct distal to the stricture is the limiting factor in the performance of an end to end anastomosis. Additional length of the distal segment may be obtained by mobilizing the duodenum and the head of the pancreas This is done by incising the peritoneum along the border of the second part of the duodenum and bluntly dissecting the head of the pancreas from its bed in the retroperitoneal tissues a step that is accomplished with very little blood loss since it is performed in an embryonic plane of cleavage. Lahey and his associates have repeatedly emphasized the use of an end to-end anastomosis. In order to accomplish this procedure more often Lahey has advised dissecting the intrapancreatic portion of the common bile duct from its bed in the pancreas.

The proximal portion of the duct is usually dilated The major problem in its use for any type of anastomosis is related to the length of duct available which of course, is directly related to the proximity of the stricture to the point of bifurcation

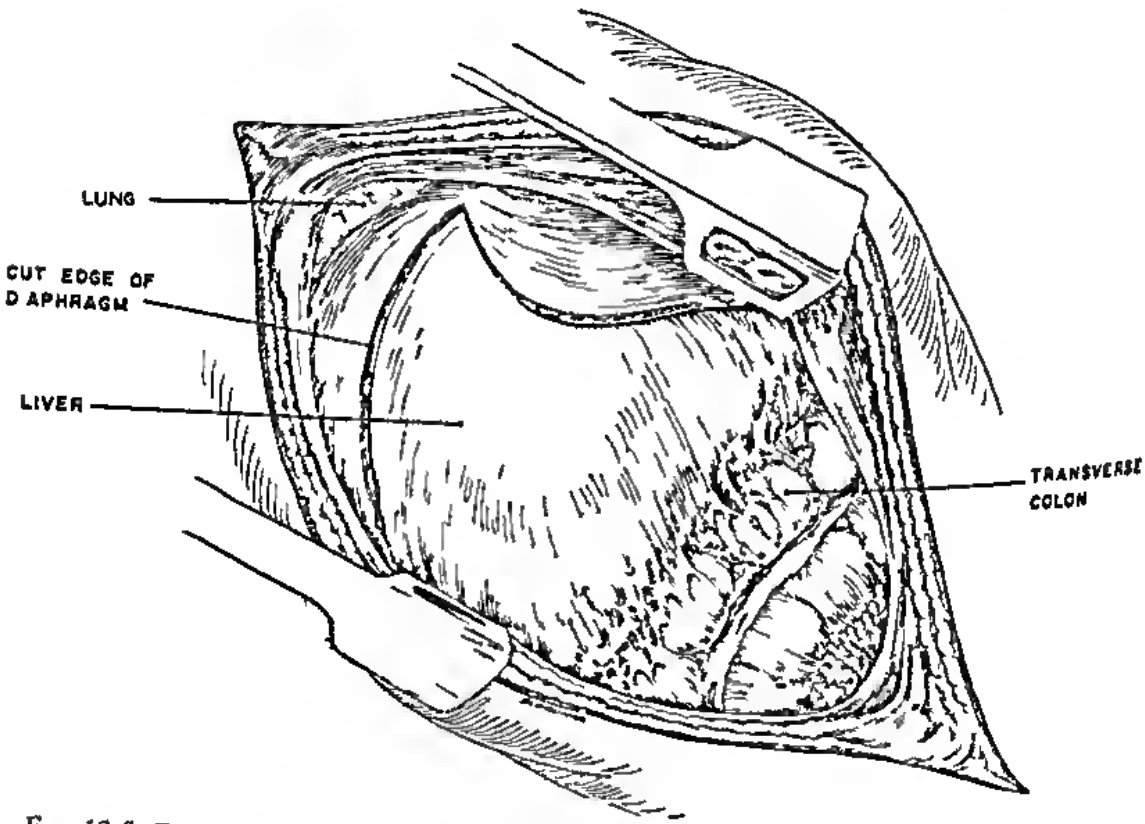


Fig 13 6 Benign biliary stricture right thoracoabdominal incision The right diaphragm has been divided and the pleural cavity entered

of the left and right intrahepatic ducts To obtain additional length of proximal duct, parenchymal liver tissue may be cored out" from around it The superior limit of such a dissection is usually the bifurcation Under certain conditions, however, an anastomosis may be accomplished with the two hepatic ducts separately or with the two ducts brought together first in a side to side anastomosis that provides a single proximal lumen

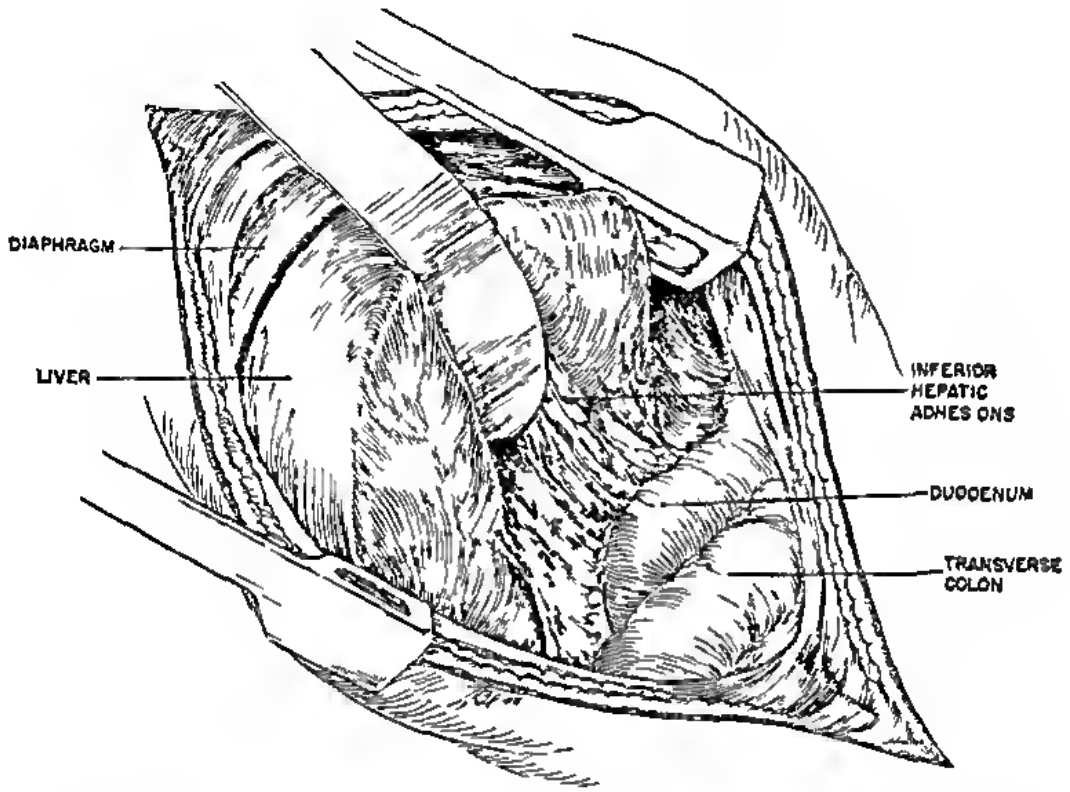


Fig 13 7 Benign biliary stricture right thoracoabdominal incision The liver has been displaced superiorly through the diaphragm into the right pleural cavity thus rotating the inferior surface of the liver and porta hepatis anteriorly

## End to End Anastomosis

The two ends of the prepared duct are carefully approximated with two rows of sutures (Fig 13 12) The outer row consists of interrupted No 4 0 silk sutures which are placed, for support only, in the adventitial tissues around the duct The inner row of sutures consists of interrupted No 4 0 gastrointestinal catgut on an atraumatic needle placed in such a way that the knots are tied on the outside of the lumen The two posterior rows are placed first, the stent is fitted into the lumen, and the anterior rows are placed last The stent in this case is a latex rubber T tube The elasticity and patency of the tube are tested, and then a hemisphere of rubber is cut out of the T portion at a point just opposite the long arm The ends of the short arm are cut off so that the tube does not traverse the papilla into the duodenum The long arm of the T tube is brought out of the duct through a linear incision made at a point at least one centimeter below the anastomotic site The linear opening in the duct is then closed snugly about the T tube with fine gastrointestinal catgut sutures. A moderate sized Penrose drain is placed to the foramen of Winslow and brought out through a separate stab wound placed inferior to the major wound on the lateral aspect of the abdomen The T tube is

brought out through another stab wound placed at a point convenient to the exit of the tube from the duct

## Choledochoduodenostomy

As one of several procedures designed to reconstitute biliary enteric continuity catgut sutures through the full thickness of the duct and the mucosa submucosal layer of the bowel, tied in such a way that the knots remain outside the lumen The outer row of fine silk sutures approximates the adventitial tissue about the duct to the seromuscular layer of the duodenum. The duodenum is anchored to the inferior

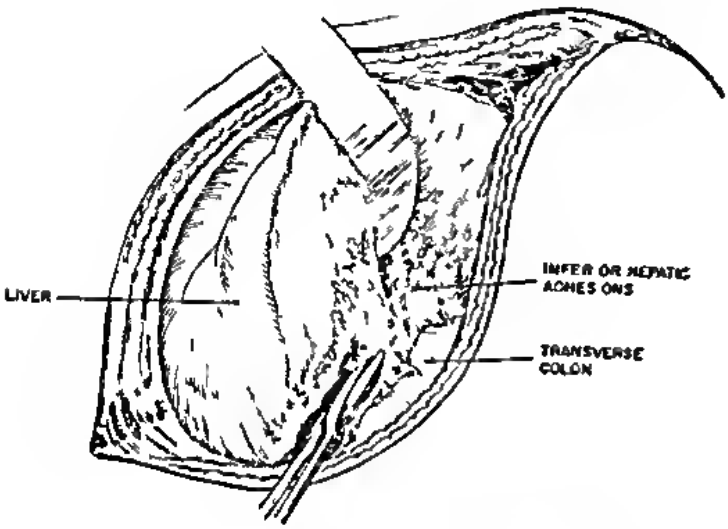


Fig 13 8 Benign biliary stricture The dense adhesions between the inferior surface of the right lobe of the liver and the underlying structures are cautiously divided

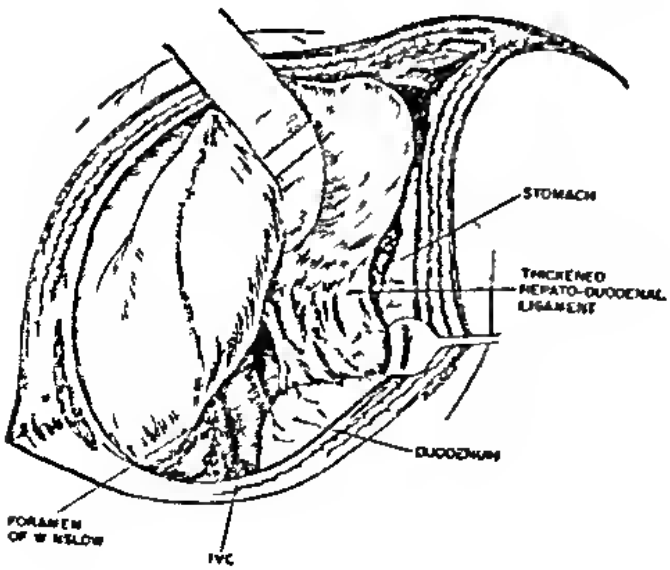


Fig 13 9 Benign biliary stricture The foramen of Winslow and the thickened hepatoduodenal ligament are defined

straight rubber catheter that is inserted through the anastomosis after the posterior rows of sutures are placed and before the anterior rows are completed The proximal end is anchored into the biliary duct remnant with a catgut suture placed at the anastomosis, and the distal end is allowed to transverse the duodenum for about 4 to 6 inches before it is brought through a purse string suture in the anterior wall of the bowel and then through a stab wound in the wall of the abdomen at a point convenient to the exit of the catheter At this point the duodenum is secured to the anterior parietes with a few silk sutures Additional holes are made in that portion of the catheter which traverses the duodenum in order to permit the bile from the duct to regain entry into the gastrointestinal tract Splints of this type are usually forced down the intestine by peristalsis within a relatively short period of time after operation If they have remained in place for one or two months, however, in all probability their purpose has been served

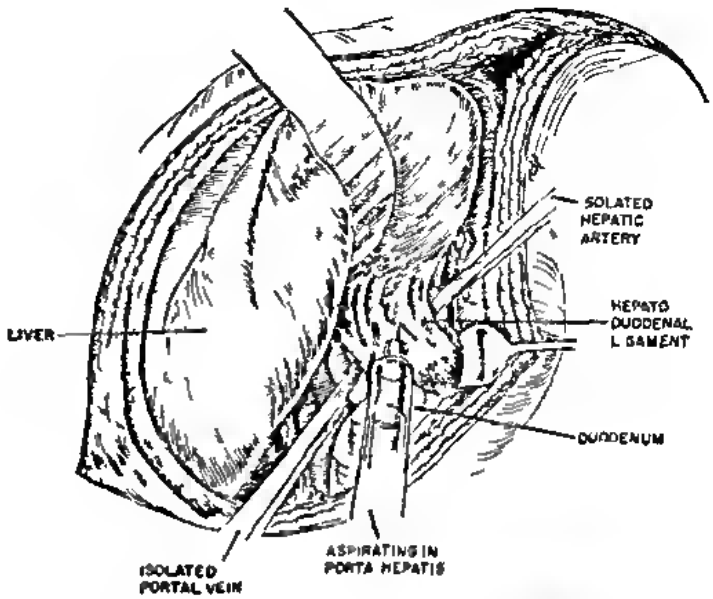


Fig 13 10 Benign biliary stricture The hepatic artery and portal vein have been isolated A syringe and fine gauge needle are used to probe the porta hepatis for the proximal remnant of the extrahepatic biliary duct

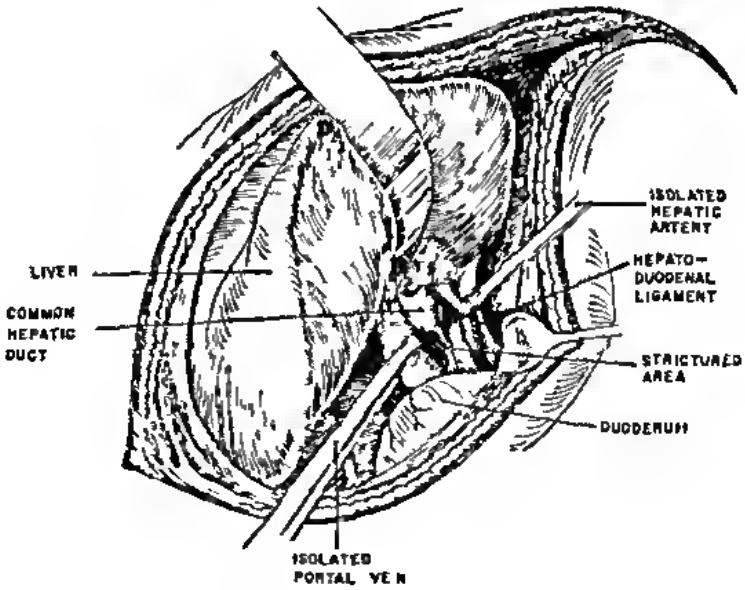


Fig 13 11 Benign biliary stricture The bulbous proximal remnant of the strictured extrahepatic biliary duct is identified

## Choledochojejunostomy

The jejunum is often utilized to conduct bile from the proximal ductile remnant at the hilus into the bowel There are two standard procedures by which this may be done In one, a loop of the first portion of jejunum beyond the ligament of Treitz is brought to the common hepatic duct or common bile duct either through the transverse mesocolon or in front of it, and the bowel content is short circuited by an enteroenterostomy proximal to the biliary anastomosis (Fig 13 14*B*) The biliary enteric anastomosis is made in exactly the same fashion as described above for the choledochoduodenostomy, and the enteroenterostomy is placed about twelve to fourteen inches proximally A rubber catheter is utilized for the splint as described previously, and here again it is not intended to remain in place much beyond one to two months

The second method employs the principle of the Roux Y limb of jejunum which provides a defunctionalized segment of small bowel, fourteen to eighteen inches in length, for anastomosis to the biliary remnant in the porta hepatis (Fig 13 14*A*) One may gain considerable length of bowel by dividing the jejunal blood supply so that the most distal point of the divided segment is still in direct vascular continuity with the major jejunal arteries This length of adequately vascularized jejunum can usually be obtained by the division of one set of primary vessels in the jejunal mesentery The distal end of the divided jejunum is closed in two layers by any appropriate technique and then brought through a small rent in the transverse mesocolon or anterior to the transverse colon The anti mesenteric surface of the bowel is brought to the porta hepatis and an end to-side anastomosis accomplished in two layers between the biliary duct and the bowel as described heretofore Again, a simple rubber catheter of suitable size is placed in the duct above the anastomosis, secured by a catgut suture at the anastomotic line and then brought through the anastomosis

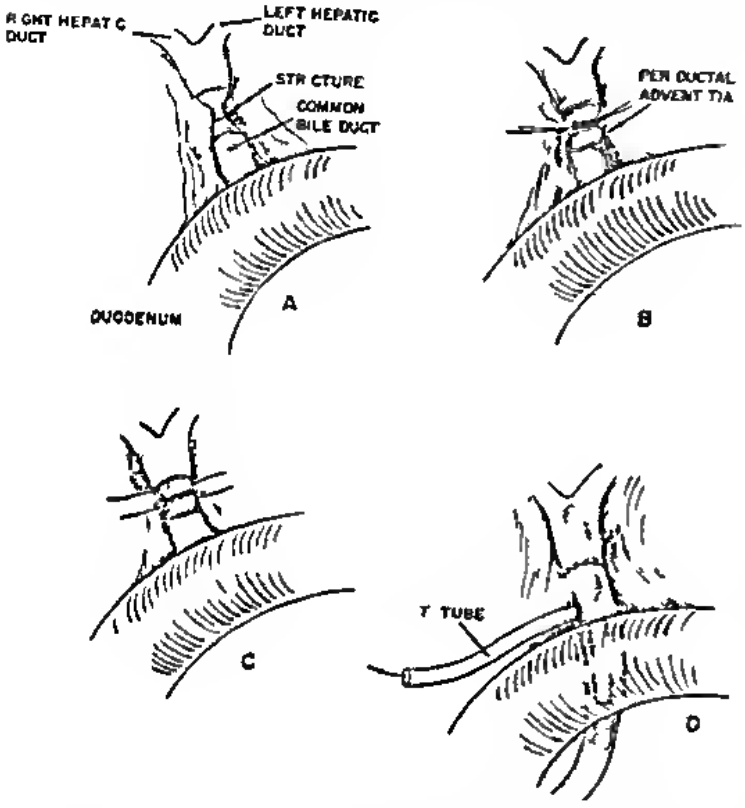


Fig 13 12 Technique for duct to-duct anastomosis (*A*) The strictured area is defined and appears to be localized and discrete Dotted lines indicate area of duct to be excised. (*B*) The first posterior row of sutures have been placed in the adventitia around the duct. (*C*) The posterior inner row of interrupted catgut sutures has been completed (*D*) The completed anatomosis with the T tube in place brought out below the line of anastomosis

and down the limb of jejunum to a point about eight inches beyond, where it is brought through a purse string suture in the bowel and out the anterior abdominal wall The jejunal limb is fixed to the parietal peritoneum at the point of exit of Supporting sutures are placed in the jejunal limb, anchoring it to the inferior surface of the liver, and the rent in the transverse mesocolon is closed about the bowel to prevent subsequent internal herniation

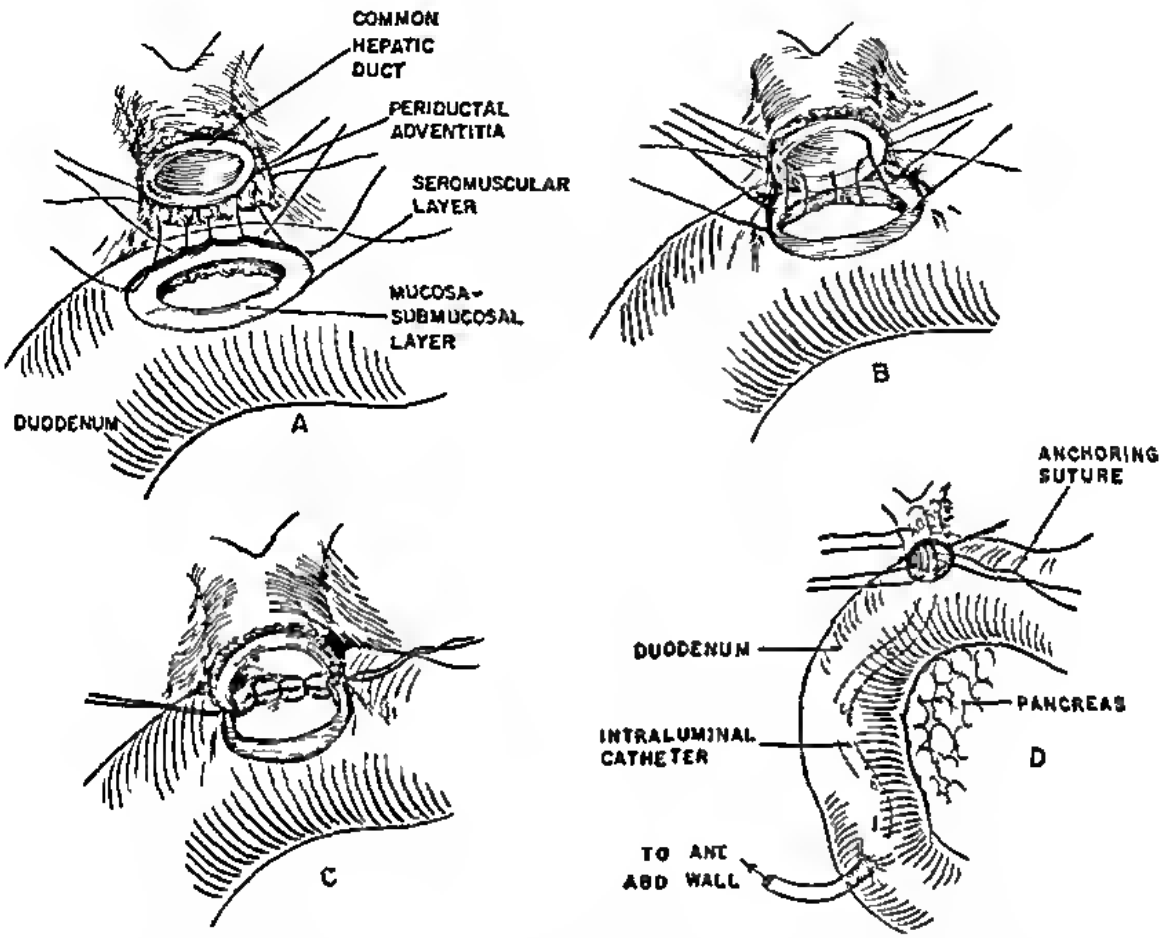


Fig 13 13 Technique for choledochoduodenostomy (*A*) The first posterior row of interrupted silk sutures approximates the adventitia around the proximal biliary segment and the seromuscular layer of the anterior aspect of the duodenum (*B*) The second posterior row approximates the full thickness of the duct and the mucosa submucosal layer of the bowel Note that the knots are on the outside of the lumen (*C*) The two posterior rows are completed (*D*) The intraluminal catheter is in place secured by a catgut suture at the line of anastomosis Note the extra holes in the catheter providing egress of bile to the bowel

the catheter in order to obviate any leakage around the opening in the bowel To restore gastrointestinal continuity, an end-to-side jejunojejunostomy is then performed distal to this point and at least fourteen to eighteen inches from the biliary anastomosis, in order to preclude the possibility of regurgitation of intestinal content into the extrahepatic biliary duct

## Intrahepatic Cholangiojejunostomy

As noted previously, the intrahepatic cholangiojejunostomy is designed for those patients in whom the other methods of reestablishing biliary-enteric continuity have proved to be inadequate The operation is performed on the left side of the abdomen, thus avoiding adhesions of pre-

viously attempted repairs The extended subcostal incision, the Marwedel (Fig 13-15), or combined thoracoabdominal incisions, which have been described previously, may all be adapted for use on the left side (Fig 13-16) The left lobe of the liver is mobilized by dividing the triangular ligament on that side This procedure should be performed with caution in order to avoid injury to the hepatic vein, which joins the inferior vena cava just beneath the diaphragm A piece of wide cotton tape is passed around the base of the left lobe and traction is applied to bring this portion of the liver forward and support it in the wound (Fig 13-17)

Starting just to the left of the round ligament at the anterior border of the left lobe, a pair of heavy silk mattress sutures is placed through the entire thickness of the liver parenchyma with a special 4.5-inch malleable liver needle These sutures are laid parallel to one another in the direction of the proposed line of incision into the liver substance, leaving about one centimeter of tissue between them (Fig 13 17) As an assistant compresses the proximal liver segment between the thumb and forefinger, the incision is made between the two rows of sutures and cautiously extended posteriorly (Fig 13 18) It is usually necessary to proceed in this manner to a depth of at least 2 cm. before the operator encounters anything suggestive of a major intrahepatic duct. As each new extension of the incision is made beyond the paired hemostatic sutures, the manual compression on the proximal side of the divided liver is momentarily released in order to inspect the cut surface

Biliary channels are identified by the flow of 'white bile' from their divided ends Suspected biliary ducts are catheterized with a rubber catheter from which the tip has been removed A duct suitable for anastomosis will usually permit the passage of a No 14 to 20 French catheter If no such duct is encountered, additional pairs of mattress sutures are placed through the liver in such a manner as to

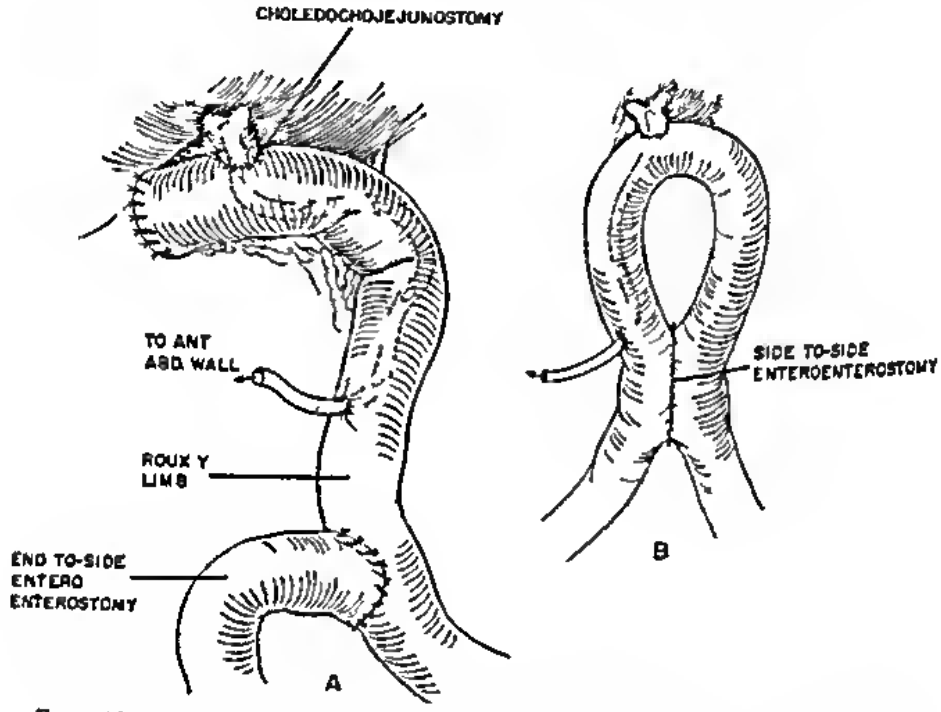


Fig 13 14 Technique for choledochojejunostomy (*A*) A completed Roux Y anastomosis is shown with the intraluminal catheter in place (*B*) A loop choledochojejunostomy is illustrated A side to-side enteroenterostomy partially defunctionalizes the bowel loop

overlap those previously taken, and the incision is extended posteriorly until a duct of suitable caliber is identified The larger intrahepatic biliary ducts are usually found in the inferior half of the central portion of the lobe The duct, with its accompanying interlobular artery and vein, is often first seen as a thickened fibrotic strand extending across the line of incision (Fig 13 19) When such a structure is noted, it should be carefully dissected from the surrounding liver parenchyma and the duct further identified before division by aspirating with a small caliber needle Additional length may be obtained by coring out the liver substance about the base of the selected duct One should avoid placing the hemostatic mattress sutures so as to obstruct the duct selected for anastomosis The interlobular artery and vein are individually clamped and ligated with fine suture material The duct is then divided, taking full advantage of any additional length that may have been gained

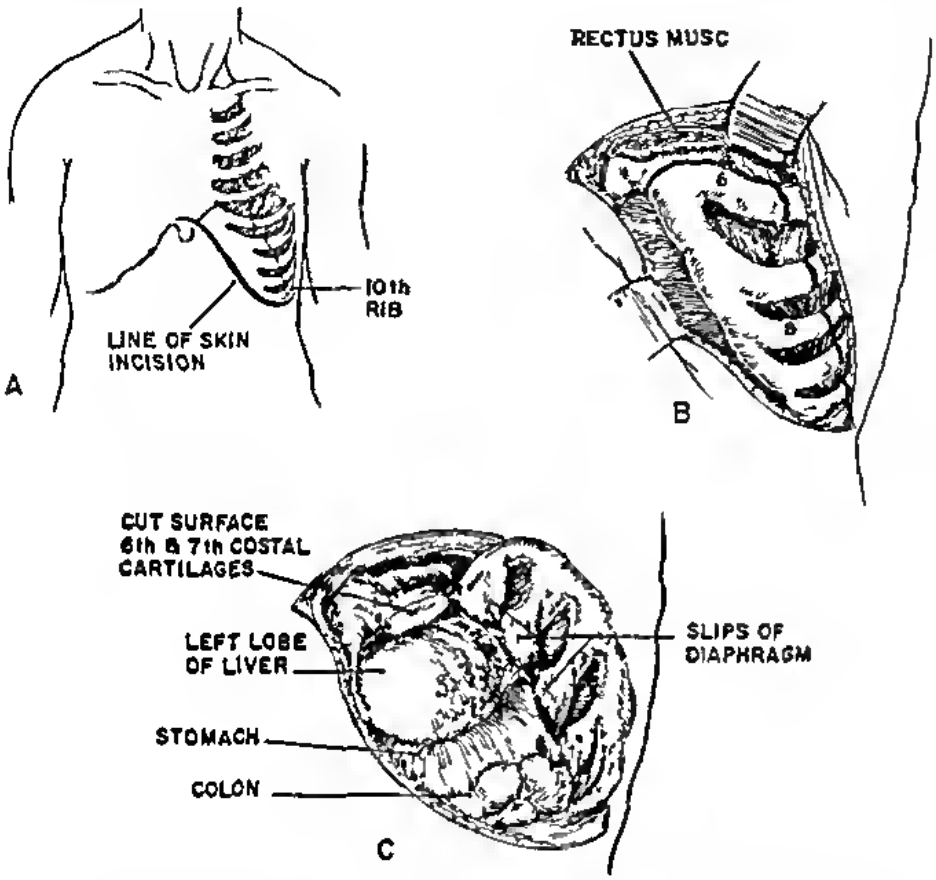


Fig 13 15 Benign biliary stricture steps in the Marwedel incision in this case placed on the left side for an intrahepatic cholangiojejunostomy (*A*) Incision is placed over the costal margin (*B*) Superior flap has been reflected exposing the lower rib cage the costal cartilages and ribs have been divided (*C*) The entire costal flap has been reflected superiorly Note slips of origin of the diaphragm on the posterior surface of the flap (*From* W P Longmire Jr and H N Lippman *Surgical Clinics of North America 36* 849 1956 *Courtesy* W B Saunders publisher )

The liver incision is now extended between paired hemostatic sutures to the nearest point on the edge of the lobe, and a wedge shaped segment of liver is resected (Fig 13 19) The catheter is then inserted into the selected duct for a distance of several centimeters, and an in

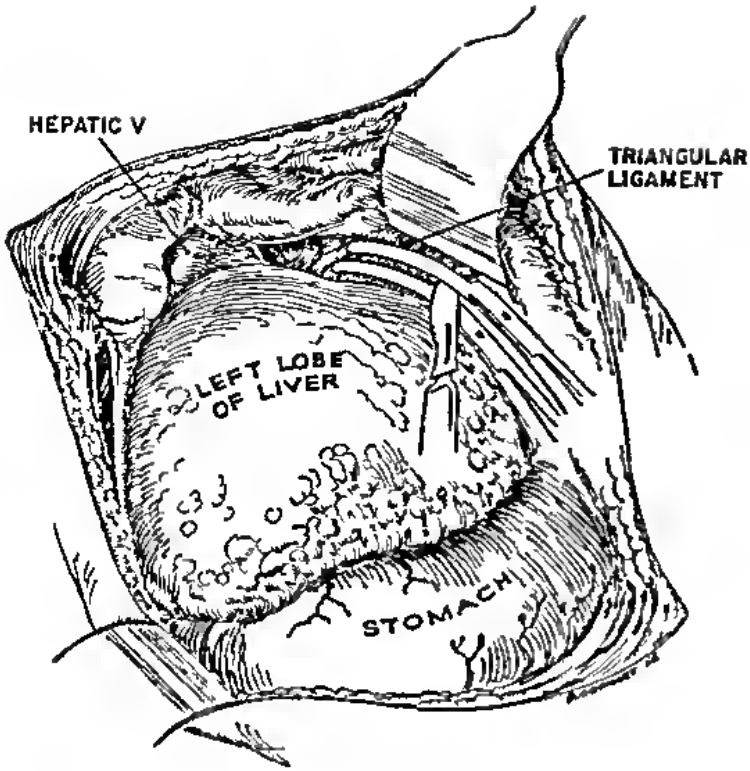


Fig 13 16 Technique for intrahepatic cholangiojejunostomy The left lobe of the liver is mobilized by dividing the triangular ligament. Note the proximity of the hepatic vein (*From* W P Longmire Jr, and H N Lippman, *Surgical Clinics of North America 36* 849, 1956 *Courtesy* W B Saunders, publisher )

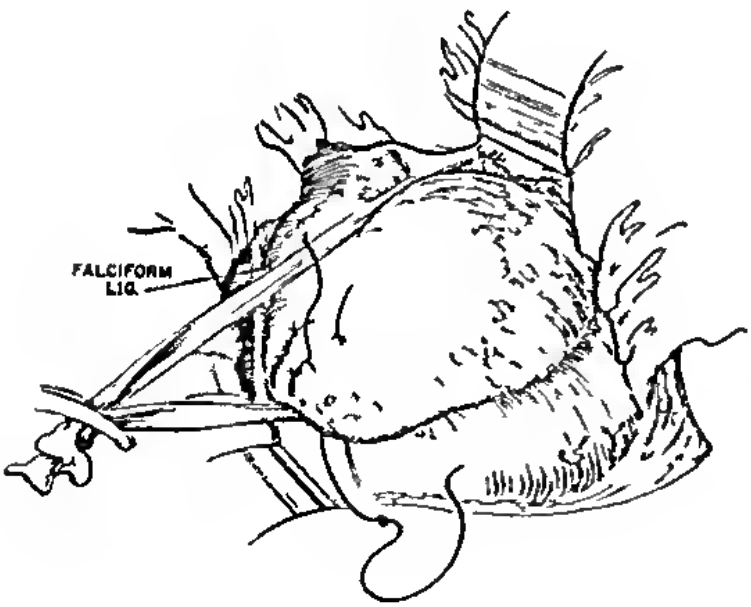


Fig 13 17 Benign biliary stricture, intrahepatic cholangiojejunostomy Overlapping pairs of heavy silk mattress sutures are placed by means of a special liver needle (*From* W P Longmire, Jr., and H N Lippman, *Surgical Clinics of North America 36* 849, 1956. *Courtesy* W B Saunders, publisher )

trahepatic cholangiogram is made (Fig 13-20) By injecting 20 cc. of 35 per cent Diodrast, it is possible to outline the entire intrahepatic biliary system through this catheter (Fig 13-21) Two purposes are served by this maneuver (1) The major left intrahepatic duct may be accurately identified in order that the largest possible anastomosis can be established between the biliary system and the bowel (2) It is possible to predict at once whether or not both the right and left hepatic lobes will drain through the exposed biliary duct.

A Roux segment of jejunum is constructed by dividing the bowel close to the ligament of Treitz, and the distal limb is carried superiorly through a small rent in

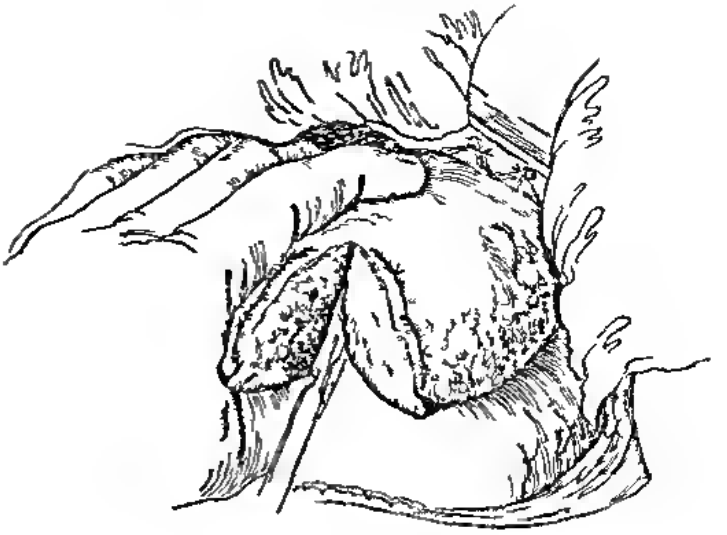

Fig 13 18 Benign biliary stricture intrahepatic cholangiojejunostomy Incision into the liver parenchyma is made between paired hemostatic mattress sutures (*From* W P Longmire Jr and H N Lippman *Surgical Clinics of North America 36* 849 1956 *Courtesy* W B Saunders publisher )

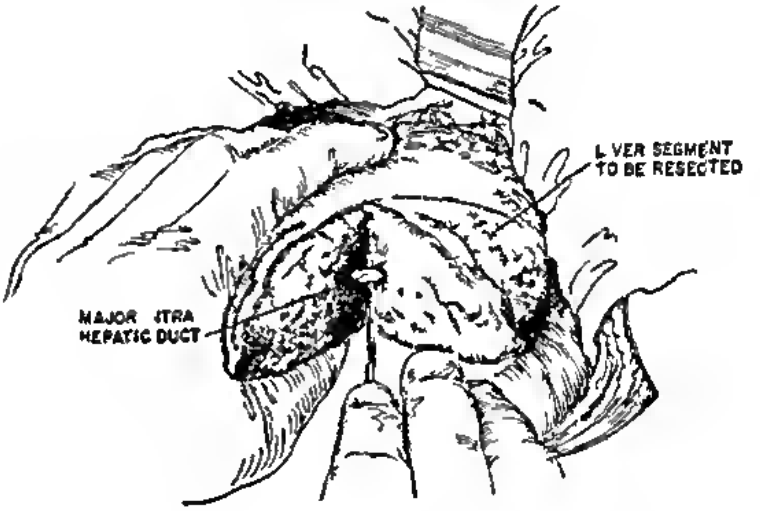


Fig 13 19 Benign biliary stricture intrahepatic cholangiojejunostomy A thick fibrotic strand extending across the line of incision is carefully dissected from the liver substance before further identification and division of the biliary duct The wedge shaped segment of liver to be resected is outlined (*From* W P Longmire Jr and H N Lippman *Surgical Clinics of North America 36* 849 1956 *Courtesy* W B Saunders publisher )

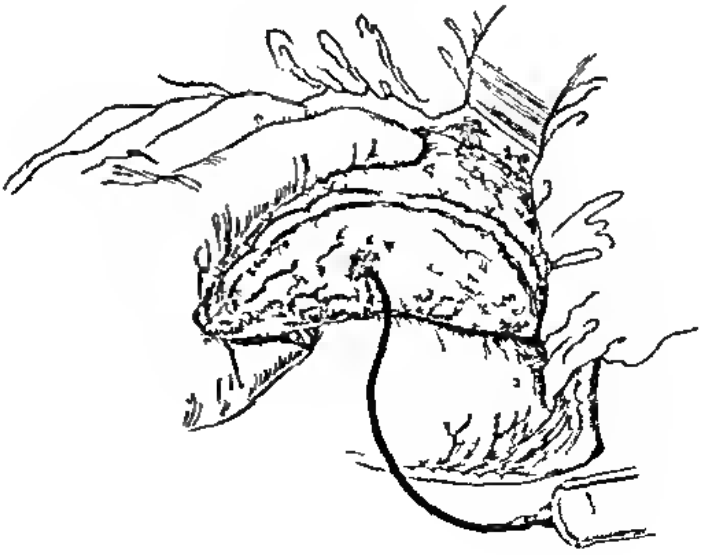

Fig 13 20 Benign biliary stricture intrahepatic cholangiojejunostomy A catheter is used to drain white bile from the selected duct and to make an operative intrahepatic cholangiogram

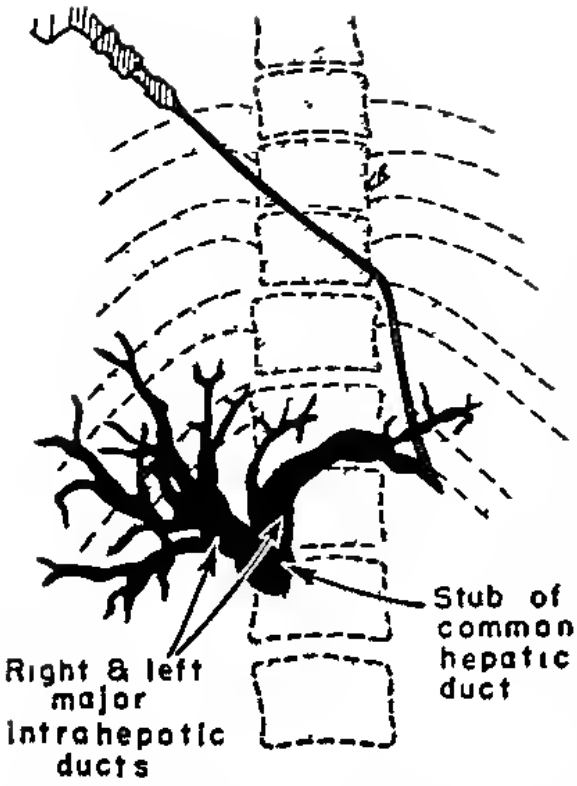


Fig 13 21 Benign biliary stricture, intrahepatic cholangiojejunostomy diagrammatic representation of an actual operative intrahepatic cholangiogram (*From* W P Longmire Jr and H N Lippman *Surgical Clinics of North America 36* 849, 1956 *Courtesy* W B Saunders, publisher )

the transverse mesocolon The open end of this limb is closed in two layers The side of the bowel is brought into position for anastomosis with the intrahepatic duct by suturing the inferior cut edge of the liver capsule to a line on the bowel adjacent to the mesenteric border (Fig 13 22) A small opening is made into the serosa and muscularis of the jejunum opposite the side of the selected duct The underlying mucosa and submucosa are grasped and 'buttonholed through the seromuscular layer, and a small circular opening is made into the lumen of the bowel (Fig 13 23) The duct wall is sutured to the mucosa and submucosa as a single layer over a rubber catheter using interrupted No 4 0 gastrointestinal catgut sutures tied so that the knots remain on the outside of the lumen (Fig 13 24*A, B*) A few additional sutures are taken between the edge of the opening in the seromuscular layer of the bowel and the cut liver surface adjacent to the duct in order to support the anastomosis (Fig 13 24*C*) The intraluminal catheter is brought out through the jejunal limb approximately four to six inches from the site of anastomosis and then through a stab wound in the anterior abdominal wall (Fig 13 25) Several small openings are made in that portion of the catheter which traverses the jejunum in order to permit free drainage of bile into the bowel The exit of the catheter is controlled by a purse string suture in the bowel, and its fixation to the parietal peritoneum is assured by several interrupted

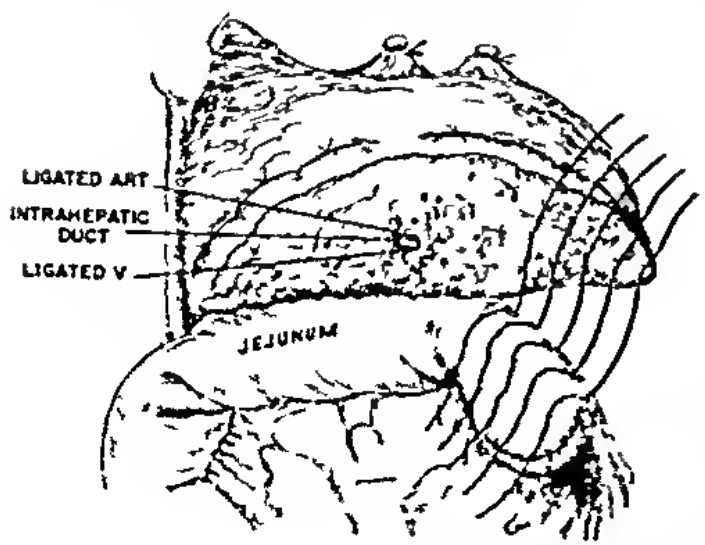


Fig 13 22 Benign biliary stricture, intrahepatic cholangiojejunostomy The distal limb of the divided jejunum is approximated to the capsule of the inferior cut margin of the liver in preparation for the biliary enteric anastomosis (*From* W P Longmire Jr, and H N Lippman *Surgical Clinics of North America 36* 849 1956 *Courtesy* W B Saunders, publisher )

sutures attaching the bowel to the anterior parietes

The antimesenteric surface of the jejunal limb is approximated to the superior cut edge of the liver capsule by a row of interrupted fine silk sutures This maneuver completely peritonealizes the raw surface of the liver and further reinforces the anastomosis Gastrointestinal continuity is re-established below the transverse mesocolon at a point about fourteen inches from the anastomosis by an end-to-side jejunojejunostomy The divided mesentery is secured at appropriate places with interrupted sutures in such a manner as to prevent any herniation of bowel about the Roux Y limb

## Prostheses

The use of permanent prostheses of various types in the repair of strictures of the extrahepatic biliary tree has with few exceptions been discontinued In general, these devices have proved unsatisfactory, and in many cases secondary operations have been necessary to remove them At the present time, if a stricture is of such

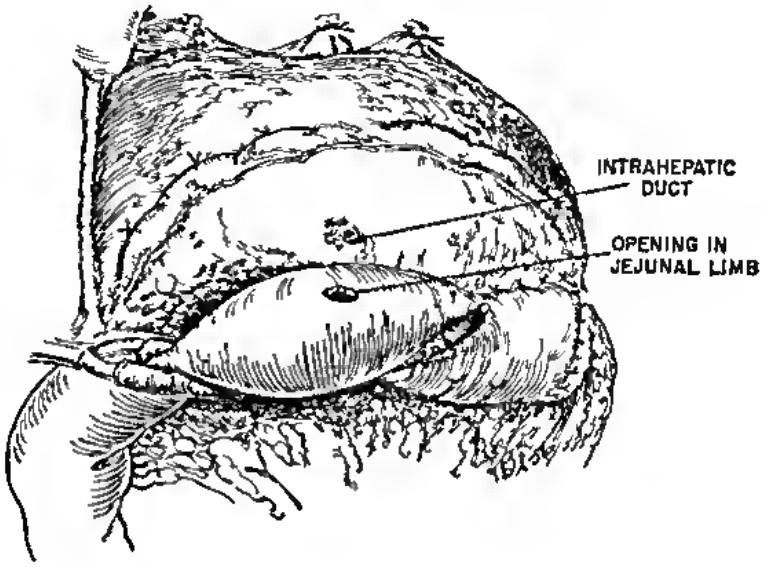


Fig 13 23 Benign biliary stricture intrahepatic cholangiojejunostomy The opening in the bowel is made directly opposite the selected intrahepatic duct (*From* W P Longmire Jr and H N Lippman *Surgical Clinics of North America 36* 849, 1956 Courtesy W B Saunders publisher)

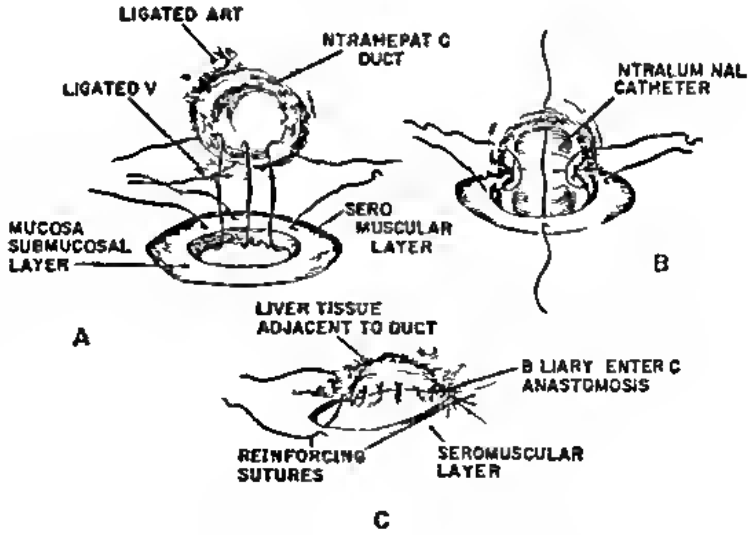


Fig 13 24 Benign biliary stricture intrahepatic cholangiojejunostomy The anastomosis (*A*) Posterior row of sutures is placed through the duct and the mucosa submucosal layer of the bowel Note that the knots will be extraluminal (*B*) Anterior row of sutures is placed with the intraluminal catheter in position (*C*) Edge of the opening in the seromuscular layer is approximated to the liver parenchyma adjacent to the duct (*From* W P Longmire Jr and H N Lippman *Surgical Clinics of North America 36* 849 1956 *Courtesy* W B Saunders publisher)

a nature that direct biliary-intestinal continuity cannot be restored by some procedure performed at the hilus of the liver, intrahepatic cholangiojejunostomy is utilized to conduct the bile back to the enteric tract Various metallic, rubber, and synthetic products have been used in the past, and there is no doubt that a certain number of patients still retain such prostheses without any difficulty whatsoever However, by and large, no matter what type of material has been employed, it almost invariably becomes plugged by bile salts and debris, so that eventually it has to be removed If continuity can be re-established without utilizing a permanent foreign body, there is no doubt that such a method should be preferred

Before dismissing prosthetic devices entirely, however, attention is called to recent observations by Donaldson and associates and McGoon and Clagett. The former group noted uniformly good results in eight patients who had plugged tubes of vitallium or polyethylene removed two to five years after insertion. The latter group noted that, of sixteen patients in whom it was necessary to remove a vitallium tube that had been placed on the average of about five years previously, twelve or 75 per cent had no further significant biliary or hepatic diffi-

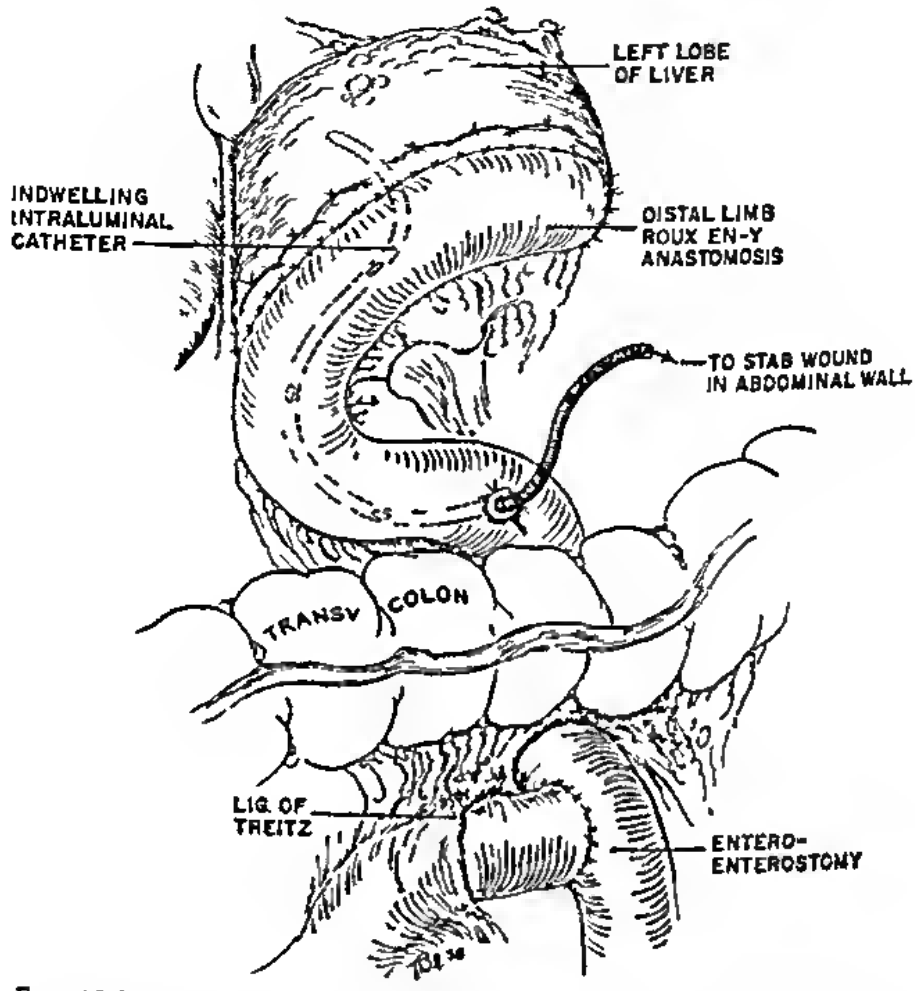


Fig 13 25 Benign biliary stricture, intrahepatic cholangiojejunostomy Anastomosis completed Intraluminal catheter is illustrated emerging from the duct, traversing the jejunal limb, exiting from the bowel to be brought out of the abdomen through a stab wound The completed enteroenterostomy is also seen (*From* W P Longmire, Jr, and H N Lippman, *Surgical Clinics in North America 36* 849, 1956 *Courtesy* W B Saunders, publisher)

culty The symptom-free interval since removal of the tube averaged four years and ten months The authors suggest that the use of vitallium tubes is not necessarily outmoded and should be strongly considered in those cases in which no superior segment of duct can be dissected from the scarred hilar surface of the liver It is also suggested that, although in about 31 per cent of their cases the tube was not removed, one should use only a vitallium tube if the need of a secondary procedure for its removal has been anticipated The second stage should be planned when and if the tube ceases to function properly Highly significant in this study was the observation that, when a tube had been in place a number of years, the inflammatory reaction about the site of the stricture had subsided and the scarring and induration in the wall of the duct had abated The mucosa of these ducts had regenerated and had formed a normal appearing unbroken ductile lining It is of interest that Pearse reported similar findings after prolonged use of the vitallium tube more than a decade ago The concept of a two stage procedure, however, is not readily accepted, although it may indeed have merit

## RESULTS OF OPERATION

The success or failure of any single attempt to correct a benign extrahepatic biliary stricture depends upon many things Within certain limits the choice of the particular operative procedure which is utilized to reconstitute biliary flow is probably the least important of those factors. The general condition of the patient and, in particular, the status of his liver will determine the final outcome in a large percentage of cases Some will not tolerate the anesthetic or the long and often tedious operation that is necessary in the difficult case, this number may reach as high as 12 per cent. A certain number may be discharged from the hospital after a successful operation only to die within a few months of hepatic insufficiency Biliary cirrhosis, however, often a concomitant problem in these patients, will usually respond well to extrahepatic biliary decompression unless the liver is decompensated and the patient already has ascites In patients with advanced biliary cirrhosis and portal hypertension, the question may arise as to the advisability of performing some type of portal decompressive procedure before decompressing the biliary tract, or possibly at the same time In general, the performance of two separate procedures of this magnitude in a patient with such poor visceral reserve probably constitutes a greater threat to life than that which exists from the possible complication of hemorrhage from esophageal varices

The extent of the local pathology within the extrahepatic ducts is a most important factor in determining the eventual outcome Primary, diffuse, obliterative, inflammatory disease of the biliary ducts, often called by various other names (see Etiology), may obviate from the start any possibility of a satisfactory surgical result The vast majority of cases, however, are caused by trauma incident to the performance of a cholecystectomy and the local pathology within the extrahepatic ducts is therefore limited Of necessity the location of the stricture in relation to the local anatomy in this area influences the type of surgery that can be accomplished in correcting this disorder as well as the anticipated outcome O Malley and associates found that the more distal the stricture the better would be the expected operative result

The tendency to recurrence of benign fibrotic stricture has been noted by many observers Lahey and others have repeatedly emphasized the fact that each unsuccessful attempt at repair progressively diminishes the chances of a lasting and satisfactory outcome Walter and Cameron have stated that the longer this group of patients is followed, the poorer will be the end results. Donaldson and associates, however, found that 82 per cent of the failures were apparent within one year after operation

By our present standards, a comparison

of results includes only a limited number of operative procedures that have survived the test of time For all practical purposes, the restoration of biliary flow may be accomplished by (1) a duct-to-duct anastomosis, (2) some type of duct-to-bowel anastomosis, and (3) an intrahepatic cholangiojejunostomy Included in the second category are (a) choledochoduodenostomy or hepaticoduodenostomy and (b) choledochojejunostomy or hepaticojejunostomy The latter procedures may employ a loop of jejunum with a proximal enteroenterostomy or a defunctionalized Roux-Y limb The third category stands more or less separately as the procedure to be utilized in the event that everything else has failed It is apparent from Table 13-1 that there is very little to recommend one procedure more than another Any differences of opinion appear to be based on theoretic considerations rather than fact Although it is theoretically unwise to anastomose the common duct in continuity with the bowel content, many patients alive and well with a choledochoduodenostomy would testify to the fact that this objection is largely academic Similarly, while the Roux Y limb of jejunum is designed to provide a completely defunctionalized section of bowel for attachment to the biliary tract the not infrequent occurrence of cholangitis in these patients would attest to the fact that such a device is not entirely effective

It would seem to be appropriate at this time to restate the authors' preference of method for reconstitution of biliary continuity in cases of benign extrahepatic biliary stricture For all practical purposes, it may be said that the defunctionalized Roux-Y jejunal limb is utilized whenever possible under these conditions

TABLE 13-1 RESULTS OF OPERATION FOR BENIGN BILIARY STRICTURE

| *Author* | *Procedure* | *Number of patients or operations* * | *Per cent satisfactory results* |
|---|---|---|---|
| Boren and Walters 1952–1954 † | Duct to duct | 2 | 50 |
| | Hepatic duct to duodenum | 16 | 50 |
| | Common duct to duodenum | 8 | 50 |
| | Hepatic duct to jejunum | 6 | 83 |
| Cole *et al*, 1938 1951 ‡ | Duct to duct | 10 | 62 |
| | Duct to duodenum | 10 | 40 |
| | Duct to Roux Y jejunum | 57 | 73 |
| Donaldson *et al* 1926–1955 ‡ | Duct to duct | 56 | 57 |
| | Duct to duodenum | 21 | 43 |
| | Duct to Roux Y jejunum | 40 | 50 |
| Lahey and Pyrtek, 1940 1948 † | Duct to duct | 73 | 78 |
| | Biliary intestinal § | 41 | 73 † |
| Longmire *et al* 1948 1956 ‡ | Duct to duct | 14 | 50 |
| | Duct to duodenum | 1 | 100 |
| | Duct to Roux Y jejunum | 7 | 42 |
| O Malley *et al* 1936–1949 † | Duct to duct | 14 | 71 |
| | Duct to duodenum | 34 | 70 |
| | Duct to Roux Y jejunum | 8 | 75 |

* Calculations are based on either one of two major variables *Number of patients* with variable numbers of procedures or *number of operations* performed The latter factor is always larger than the former therefore final calculations based on the number of patients appear in general to be better

† Calculations based on number of patients

‡ Calculations based on number of operations.

§ Includes duct to duodenum and duct to jejunum although most represent duct to loop of jejunum with proximal enteroenterostomy

to conduct bile from the extrahepatic biliary system, and indeed when necessary from the intrahepatic biliary system, to the enteric tract This would apply to most primary definitive procedures performed for accidental division of the common bile duct or common hepatic duct and almost without exception to the secondary procedures carried out for the correction of delayed benign stricture of the extrahepatic biliary system

## CONGENITAL ATRESIA OF THE BILIARY DUCTS

The authors have chosen to consider congenital atresia of the extrahepatic biliary ducts apart from the general discussion of biliary stricture since for all practical purposes the problems are clinically unrelated

Congenital atresia or aplasia of the biliary system is exclusively a problem of infancy and early childhood The most important symptom is jaundice It is usually present at birth or shortly thereafter, but once it appears, it is progressive and unrelenting—an important feature in its differentiation from other causes of jaundice at this age The stools are always clay colored or white from birth and the urine is highly colored and positive for bile pigments The serum bilirubin is characteristically high The liver is usually enlarged, as is occasionally the spleen

The differentiation between congenital atresia and obstruction of the biliary passages by inspissated bile or mucus may be very difficult or impossible It is not uncommon to make this distinction at laparotomy Patterson has devised a technique of biliary flush utilizing intravenous and oral choleretics, which is probably wisely employed in all patients before exploration for biliary atresia.

In the largest recorded series of cases of congenital biliary atresia, Gross found that only 27 out of 146 cases (18 per cent) were amenable to surgical correction. In the remaining cases, there was no proximal extrahepatic duct that could be utilized to restore biliary continuity The anatomy that was found determined the procedure performed In most instances in which a correctable lesion was discovered, the atretic area was located in the common bile duct, and restoration of biliary flow consisted of a choledochoduodenostomy or cholecystoduodenostomy The other correctable lesions were in the lower end of the common hepatic duct, and re-establishment of biliary continuity was accomplished by hepaticoduodenostomy

The over all results in this disorder are not encouraging However, slightly less than half of the infants in Gross's series who were "correctable" survived the procedure and are well One patient is living and well 24 years after operation

It is of interest that the original concept of intrahepatic cholangiojejunostomy was directed toward its possible use in the correction of congenital atresia of the biliary ducts in infants It was soon recognized, however, that in those cases in which there were no available extrahepatic ducts there were also no dilated intrahepatic ducts that could be utilized for anastomosis to the enteric tract It is the aplasia or atresia of the *intrahepatic* ducts which, in the last analysis, defeats the surgeon in his attempt to correct this disorder

## ACKNOWLEDGMENTS

Our appreciation to Sherman M Mellinkoff, M D, Department of Medicine, and Harrison Latta, M D, Department of Pathology, University of California Medical Center, Los Angeles, for their kind assistance in the preparation of material within their particular field of interest

The authors wish also to thank Mr Theodore Bloodhart, Medical Illustrator, University of California Medical Center, Los Angeles, for his very capable handiwork

## REFERENCES

ALLEN, A. W A method of re-establishing continuity between the bile ducts and the gastrointestinal tract *Ann Surg* *121* 412, 1945

BOREN, J A, and WALTERS, W Strictures of the bile duct and their treatment *Proc Staff Meet Mayo Clin 30* 245, 1955

COLE, W H, IRENEUS, C, and REYNOLDS, J T Strictures of the common duct *Ann Surg 133* 684, 1951

CRESSMAN, R D, and SNELL, A M Primary benign stricture of the extrahepatic bile ducts *Am J Surg 88* 117, 1954

DONALDSON, G A, ALLEN, A W, and BARTLETT, M K Postoperative bile duct strictures Their etiology and treatment *New England J Med 254* 50, 1956

DUBIN, I H Chronic idiopathic jaundice *Am J Med 24* 268, 1958

ELIOT, E, JR. Benign cicatricial strictures of the bile ducts *Ann Surg 104* 668, 1936

GRAY, H K Discussion on the repair of injuries to the common bile duct Benign strictures of the extrahepatic bile ducts *Proc Roy Soc Med Lond 44* 1005, 1951

GROSS, R E *The Surgery of Infancy and Childhood* Philadelphia & London, W B Saunders Company, 1953, pp 508-523

LAHEY, F H, and PYRTEK, L J Experience with the operative management of 280 strictures of the bile ducts *Surg Gynec & Obst 91* 25, 1950

LIPPMAN, H N, and LONGMIRE, W P, JR Intrahepatic cholangiojejunostomy for biliary obstruction *Surg Gynec & Obst 98* 363, 1954

LONGMIRE, W P, JR, and LIPPMAN, H N Intrahepatic cholangiojejunostomy—An operation for biliary obstruction *S Clin North America 36* 849, 1956

LONGMIRE, W P, JR, and SANFORD, M C Intrahepatic cholangiojejunostomy with partial hepatectomy for biliary obstruction *Surgery 24* 264, 1948

LONGMIRE, W P, JR, and SANFORD, M C Intrahepatic cholangiojejunostomy for biliary obstruction—Further studies Report of four cases *Ann Surg 130* 455, 1949

McGOON, D C, and CLAGETT, O T Vitallium tube method for repair of strictures of the bile ducts *Surg Gynec & Obst 106* 409, 1958

MONCRIEF, J A Extrahepatic biliary duct obstruction due to stricture *A M A Arch Surg 70* 519, 1955

O'MALLEY, R D, AUFSES, A H, JR., and WHIPPLE, A O Benign extrahepatic biliary tract obstruction *Ann Surg 134* 797, 1951

RANSOM, H K, and MALCOLM, K D Obstructive jaundice due to diffuse contracture of the extrahepatic bile ducts *A M A Arch Surg 28* 713, 1934

SULLIVAN, A G Reconstruction of the bile ducts *J A M A 58* 2026, 1912

WALTERS, W H Physiologic studies in cases of stricture of the common bile duct A 28-year survey with data on 254 patients *Ann Surg 138* 609, 1953

CHAPTER 14

# SURGERY OF THE PANCREAS

*Dan W Elliott, Roger D Williams, and Robert M Zollinger*

Some progress has been made in surgery of the pancreas, although the cause for most of its lesions remains unknown The pancreas may now be completely explored, laid open along its duct from end to end, and repaired primarily resected partially, or totally removed when necessary Factors contributing to general advances in surgery are especially important to pancreatic procedures (1) great care in preoperative preparation, (2) adequate and safe anesthesia, (3) freely available transfusions, and (4) very gentle operative technique An improved understanding of pancreatic physiology also deserves emphasis

## Ductal Anatomy and Embryology

A consideration of pancreatic embryology explains the anatomy of the ducts and their variations (Fig 14-1) The pancreas is formed from two primordia each containing its own duct Each arises from a separate outpouching of the primitive foregut The ventral pancreas arises in common with the liver and bile ducts It rotates with the common duct posteriorly around the duodenum to reach its adult position As it fuses with the smaller dorsal pancreas, the ventral portion takes over most of the ductal drainage

For these reasons, there are nearly always two pancreatic ducts Minor variations in embryologic development produce differences in size, in communication with each other, and in the relative proportion of pancreas each drains

The larger duct of Wirsung from the ventral pancreas, joins the common bile duct at the ampulla of Vater, and drains most of the pancreas The lesser duct of Santorini from the dorsal segment, enters the duodenum through its own small papilla In the adult, this is difficult to find It usually is about one inch proximal and slightly ventral to the ampulla of Vater and very near the duodenal bulb In 10 per cent of individuals this lesser duct of Santorini is the larger, more important duct It usually communicates freely with the duct of Wirsung, but occasionally the two ductal systems remain completely separate

### Annular Pancreas

Failure or variation in the normal rotation of the ventral pancreatic primordium probably explains the occurrence of an annular pancreas This encircles the second portion of duodenum completely or nearly so This tissue may vary from a thin fibrous band to a thick wedge of functioning parenchyma Symptoms are primarily those from compres

sion of the underlying duodenum, producing partial to complete obstruction

About one half of these become symptomatic within the first few weeks or months of life When this occurs, the underlying duodenum may be stenotic, atretic, or contain a diaphragm In this case, simple division of the pancreatic band fails to relieve the obstruction Division of the encircling pancreas always cuts across a duct communicating with the intrapancreatic ductal system Therefore a pancreatic fistula is invited, unless each of the divided ends can be completely closed For these reasons, bypassing the obstruction by anastomosing the proximal dilated duodenum to the first portion of jejunum should be considered When the proximal duodenum seems too small for this, it is probably decompressing itself in a retrograde fashion through the pylorus In this case, gastrojejunostomy is satisfactory Relief of obstruction relieves all symptoms

Many cases of annular pancreas are not diagnosed till adult life is reached A peptic ulcer is frequently found either just ahead of or beyond the constricting pancreas. It is probably secondary to the duodenal constriction and poor gastric emptying An obstructive ulcer in the descending duodenum by x ray should suggest the possibility of an annular pancreas preoperatively In some cases, partial duodenal obstruction can be identified with no ulcer

In adults, division of the constricting annular pancreas is more likely to relieve the duodenal obstruction Both ends of the divided pancreas must be controlled with nonabsorbable sutures to prevent ductal leakage The digestive enzymes in normal pancreatic secretions may lyse catgut before healing is complete. The appropriate bypassing bowel anastomosis, without pancreatic section, is also very satisfactory treatment

## Ectopic Pancreatic Tissue

Ectopic pancreatic tissue often is identified after it has been resected and examined microscopically It is usually found in round thick circumscribed plaques buried in gastrointestinal submucosa The most frequent sites are gastric antrum, descending duodenum, upper jejunum, and Meckel's diverticula. Outside bowel wall, this tissue occurs in the splenic hilum and along the superior border of the pancreas.

These locations become important during the search for a functioning islet adenoma Significant tumors have been found in aberrant pancreatic remnants at each of these common sites.

In the bowel wall these plaques produce no symptoms, unless by sheer size they compromise a lumen, or lead an intussusception However, resection is often required to establish their nature, or for treatment of other disease

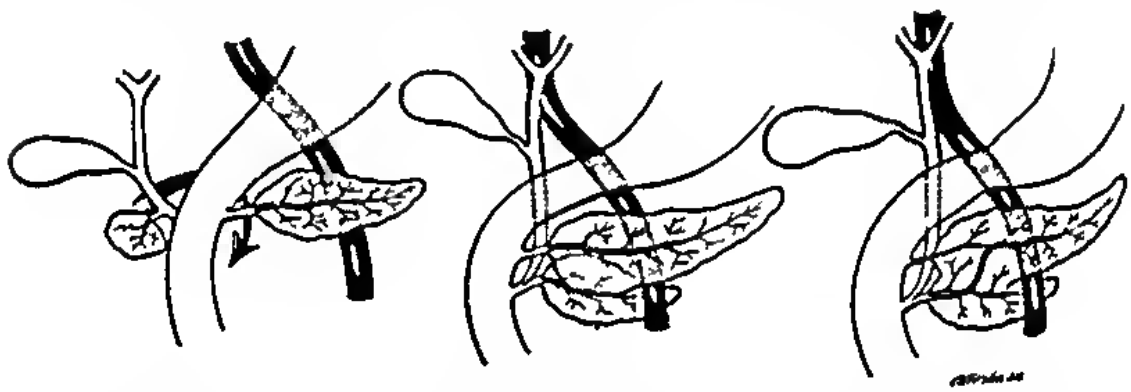

Fig 14 1 Embryologic development of the pancreas from two separate primordia The ventral primordia arises from the common bile duct and rotates with it behind the duodenum.

## ACUTE PANCREATITIS

Acute pancreatitis is now recognized as a frequent cause for the abrupt onset of upper abdominal pain The clinical picture may suggest a myocardial infarction, or more frequently an acute disease of the upper abdomen requiring emergency operation However, surgical intervention does little good for acute pancreatitis and should be avoided whenever possible Therefore, differentiating pancreatitis from lesions requiring emergency operation has become a matter of considerable practical importance to surgeons

The diagnosis of acute pancreatitis is not easily established There is nothing characteristic about the history except steady and persistent upper abdominal pain of recent origin The physical findings usually suggest some degree of peritoneal irritation and paralytic ileus In every such case acute pancreatitis must be suspected It can be supported by an elevated amylase in blood urine or ascitic fluid soon after the onset of pain Pancreatitis must then be confirmed by ruling out other causes of amylase elevations

Almost any acute injury or inflammation in the pancreas will cause its digestive enzymes to escape into a serous transudate within its capsule and into ascitic fluid within the abdomen Within an hour, absorption through both lymphatics and venous drainage will elevate these enzymes in the peripheral blood stream Of the four digestive enzymes, amylase is by far the easiest to measure A simple and reliable method for its determination was developed by Somogyi at the St Louis Jewish Hospital in 1933 Elman recognized its value as a test for acute pancreatitis With wide application of amylase determinations, it has become apparent that acute pancreatitis is not a rare disease

In our own 600 bed general hospital serum amylase is determined immediately in every patient presenting acute upper abdominal pain Between 30 and 40 cases of idiopathic acute pancreatitis are being recognized each year This averages three cases a month, and makes the incidence of pancreatitis somewhat higher than that of perforated peptic ulcer, which it often mimics In an active 250-bed general hospital serving mostly private patients, 45 cases of acute pancreatitis were recently identified by Grollman and associates in a 16 month period From such observations, it appears that a serum amylase should be determined whenever a patient complains of recent pain in the upper abdomen, or presents signs of paralytic ileus As a routine part of the initial diagnostic examination, an amylase determination is often far more useful than the white count

### Age, Associated Disease, and Etiology

Primary acute pancreatitis is most frequently a disease of middle life It has its highest incidence in men at around 40, and in women at 50 However, our patients include ages from 6 to 84

The earlier average age at which acute pancreatitis is seen in men may be due to its frequent association with alcoholism Among our own patients, about 12 per cent admit alcoholic excess, and these are mostly men

Approximately 65 per cent of our total cases have had proved gallstones Women predominate over men by a ratio of three to two This is consistent with the more frequent incidence of biliary tract disease in women Among patients with acute cholecystitis, 10 per cent to 18 per cent have pancreatitis as well, proved by operation as well as by amylase elevation

In childhood, acute pancreatitis is relatively rare, with only about 30 cases reported in the literature However, severe necrotizing pancreatitis can follow a trivial blow to the upper abdomen, since the rib cage is elastic, permitting the pancreas to be squeezed against the vertebrae Other cases in childhood have been secondary to such systemic infections as mumps, scarlet fever, and influenza These usually have been mild

Analysis of such relatively crude statistics in several large series generally supports the importance of biliary tract disease, alcoholism, and trauma in the pathogenesis of this lesion However, its exact cause remains speculative No specific bacterial or viral agent can be implicated Much of what is known has been learned from experimental animals In them, a lesion pathologically identical to the human disease can be reproduced in a variety of ways

Such data show that pancreatic ductal obstruction can cause mild edematous pancreatitis particularly if the gland is stimulated to secrete It cannot produce a severe or necrotizing lesion Both arterial and venous occlusions can induce severe pancreatitis However, these can rarely be identified as primary lesions in human cases

The common channel theory of Opie deserves re emphasis Most of the experimental objections to it have been overcome recently When bile and pancreatic secretions stagnate and incubate together in the biliary tree, they can infiltrate the pancreas at very low pressure This induces a severe pancreatitis Spasm in the sphincter of Oddi can initiate this reaction Such spasm can be produced by alcoholism gallstones operative trauma, or some other unknown cause and must be considered a likely etiologic agent

## Pathologic Features

In the earliest and mildest forms, edema of the pancreas is the principal finding Its capsule is distended by fluid that extends into the adjacent mesentery and omentum Microscopically, inflammatory infiltration and edema are apparent but the acinar tissue is well preserved

Fat necrosis appears as white chalky plaques in adjacent tissues containing fat. These are thought to result from lipase liberated in the edema fluid In severe cases it may be found in sites as remote as the posterior mediastinum pericardium, and microscopically in the bone marrow Both fat necrosis and edema can disappear in a few days time leaving no residual damage

Interstitial hemorrhage and parenchymal necrosis are evident also, in more severe cases The hemorrhage may vary from scattered diapedeses of red cells to widespread areas of infarction Marked destructive changes have been noted in the finer vasculature by many pathologists This probably represents a more severe stage in the same inflammatory process Clinically, it can be identified only by an increased severity of the illness

At operation or autopsy, gray white necrosis intermingled with black hemorrhage and infarction may occupy much of the gland When necrosis has been extensive, particularly in the body and tail liquefaction may fill the lesser peritoneal sac with secretions, hemorrhage and necrotic debris Secondary infection is frequent

Recovery from a necrotizing process brings progressive fibrosis and contraction of the remaining gland The acinar tissue that remains viable will undergo surprising amounts of regeneration After weeks or months, it may resume satisfactory digestive function

## Clinical Diagnosis

### *Pain*

The onset is characteristically rapid and acute The first manifestation is pain in more than 90 per cent of cases When a distinct pain is not complained of it is usually masked by another lesion such as a cerebrovascular accident, a coincident acute cholecystitis, or a recent upper abdominal operation.

Pancreatic pain is steady, ranging in intensity from mild to severe Classically it has been described as extending like a band across the upper abdomen and radiating into the back. However such an easily recognized pain pattern is rarely seen. When it occurs, a relatively severe lesion is present throughout the gland More frequently, and in milder cases

some portion of the pancreas is inflamed more severely than the rest In such cases the pain is localized by the patient to an area that corresponds regularly to the segment of the gland most inflamed

Pancreatic pain patterns in patients have been studied objectively by Zollinger and associates Three electrodes about the size of a No 2 catgut suture were implanted separately in the pancreas at abdominal operations, one each in the head, body and tail of the gland (Fig 14 2) A day or two later a barely detectable electrical stimulus, easily tolerated on the examiner s tongue was applied to each segment of the pancreas in turn The pain that arose from the head of the pancreas was regularly referred to the right upper quadrant Pain arising in the body was referred to the anterior mid line Pain from the tail of the pancreas was referred to the left flank, usually at a level well below its anatomic position This may explain the suprapubic pain observed by Paxton and Payne in pancreatitis which probably arises from the tail of the gland Only stimulation of all three electrodes at the same time would elicit the classical bandlike pain across the upper abdomen, with radiation into the back, supposedly characteristic of pancreatitis

These findings may explain why inflammation in the pancreas can mimic most of the disorders of the upper abdomen Bockus has pointed out that in only 57 per cent of his 82 pancreatitis patients was the initial diagnostic impression correct

Fig 14 2 X ray of patient with electrodes implanted in pancreas for objective study of pancreatic pain pattern Grids show areas to which pain was referred All these electrodes had to be activated at once to obtain bandlike pain (*Reproduced from* R M Zollinger, Pancreatitis in *Postgraduate Medicine 15* 323 1954 )

### *Past History*

The past history is of relatively little help Since about two thirds of pancreatitis patients have recurrent episodes, the history of a previous bout may be uncovered A majority of the patients have gallstones, and therefore food intolerances, or colic, are common A

history of known gallstones or of an alcoholic bout increases the suspicion of pancreatitis

At least one third of the patients will have had no previous abdominal pain In such patients the current attack is likely to be severe At least one half of the deaths occur during the first bout

*Vomiting*

Vomiting follows early upon the appearance of abdominal pain It is per



Fig. 143 Abdominal x ray with patient supine, 12 hours after onset of acute pancreatitis Localized dilatation of jejunum suggests jejunal obstruction

sistent, and contains bile, but becomes fecal late Emptying the stomach does not relieve the pain or stop the vomiting which appears reflex in nature at first A few hours later it reflects a developing paralytic ileus

## Physical Findings

The physical findings are fairly characteristic for pancreatitis, but they are not specific, and rarely permit a diagnosis to be made at the completion of the physical examination

Generalized upper abdominal tenderness, with resistance to palpation appears early It may be localized in either the right or the left upper quadrant Rigidity with rebound tenderness follows shortly Punch tenderness in the left costovertebral angle is rather suggestive of pancreatitis when it accompanies appropriate abdominal findings

Paralytic ileus and progressive abdominal distention correspond in degree to the severity of the lesion About one third of the patients with mild pancreatitis escape without a significant ileus In the remainder, it is an ominous sign of a severe illness to follow

Pulse rate elevations are often marked, and reflect in degree the severity of the lesion Fever remains persistently elevated until improvement occurs

In the deteriorating patient, fever tachycardia, increasing distention and impaired respirations are followed by cyanosis, hemoconcentrations and shock Hypotension has been noted in about 10 per cent of cases Although always a danger, it occurs far less frequently than the classic descriptions of this disease would suggest Oliguria or anuria may follow hypotension, but otherwise are usually not observed

Some classical physical signs are seen late in pancreatitis, if at all Grey Turner described induration in the left flank followed by ecchymosis Warren has emphasized that flank edema precedes this Cullen has described a bluish discoloration of the umbilicus. All these signs retroperitoneal dissection of hemorrhage exudate, and indicate a severe lesion.

## Roentgenologic Evaluation

There are no x ray findings that specifically indicate acute pancreatitis. However immediate films of the abdomen and chest are extremely valuable in ruling out other diseases requiring emergency operation

The usual x ray picture of acute pancreatitis is one of peritoneal irritation and paralytic ileus evident within a few hours after the onset (Fig 14 3) Occasionally these manifestations appear largely in the left upper quadrant However

Fig 14 4 Abdominal x ray with patient supine 36 hours after onset of acute pancreatitis Colon distention suggests obstruction

ever this is so variable in appearance as to be merely suggestive Distention of the colon may predominate since the pancreas lies at the root of the mesocolon When colon obstruction is suggested (Fig 14 4) an emergency barium enema becomes necessary before laparotomy

Since the pancreatic tail approaches the posterior left diaphragm small pleural effusions in the left costophrenic angle may be recognized (Fig 14 5) Rarely such effusions may be observed on the right side as well

Calcification within the pancreas can be seen in only about 10 per cent of acute pancreatitis but always indicates pancreatic inflammation of long standing The identification of gallstones is also helpful because of their frequent association with pancreatitis

Cholecystography with oral dye often fails to visualize a perfectly normal gallbladder for several weeks after pancreatitis However intravenous cholangiography will opacify a functioning gallbladder during an attack of acute

Fig 14 5 Upright chest x ray of 71 year old woman 36 hours after onset of acute pancreatitis Marked left pleural effusion is noted

pancreatitis but not cholecystitis and may prove worthwhile

## Laboratory Aids

### *Serum Amylase*

Like most laboratory procedures the serum amylase must be interpreted with care The recent surgical literature is filled with reports that appear to question its accuracy in the diagnosis of pancreatitis Nevertheless without it most current cases would require a futile laparotomy to establish the diagnosis

There are clinical situations in which (1) pancreatitis is present although the amylase is normal or (2) pancreatitis is not present although the amylase is tremendously elevated Another disease may require operation Both of these confusing clinical situations can usually be recognized.

In acute pancreatitis, amylase-rich fluid collects around the pancreas and weeps into the peritoneum, from where it is quickly absorbed. Within 48 hours the edematous gland is recovering, and the serum amylase returns to normal. Within 48 hours the badly damaged gland is no longer making enzymes. Therefore, it is in the patient first seen after 48 hours of sickness that the serum amylase may be normal, though the pancreatitis is severe (Fig. 14-6). In this situation diagnostic paracentesis becomes extremely useful.

The fluid from a mildly edematous pancreas is as rich in enzymes as the fluid from a necrotic gland. Therefore the elevation that amylase reaches in the serum, urine, or ascitic fluid is not related to the severity of the disease, nor to the prognosis.

Since amylase elevations are transitory the test should be run immediately, day or night, whenever pancreatitis is suspected. If the laboratory is not available for this, a sample of 10 ml. of blood can be allowed to clot in a clean dry test tube and placed in the refrigerator. A reasonably accurate amylase can be determined as long as 24 hours later if this blood is kept cold in the meantime.

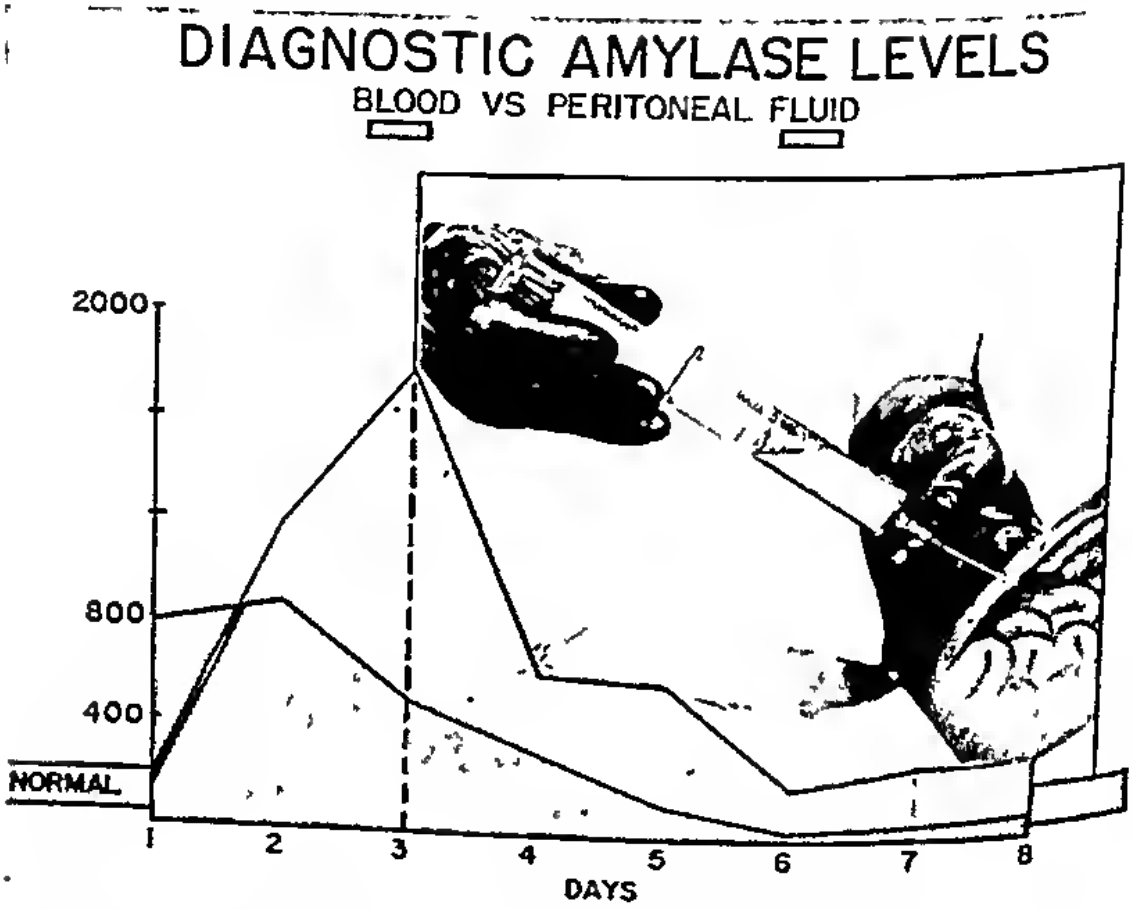


Fig. 14-6. Diagnostic amylase levels. Average serum and peritoneal amylase values in 14 patients with acute pancreatitis. After 48 hours, to the 6th day, only the peritoneal amylase remained diagnostically elevated.

Marked elevations of serum or peritoneal amylase may be observed in other lesions requiring prompt operation. If a peptic ulcer perforates, gastrointestinal secretions normally rich in amylase pour out into the peritoneum. A perforated gallbladder may pour out bile that is

extremely rich in amylase when a common channel is functioning Compromised small bowel, owing either to obstruction or mesenteric infarction, may leak amylase rich contents through permeable walls within a few hours Peritoneal absorption occasionally elevates serum amylase to high levels in all these situations The urgent need for laparotomy must be recognized from x-ray, diagnostic paracentesis, or a failure to improve promptly under therapy A high serum or peritoneal amylase level must not be allowed to interfere with this judgment

Very low serum amylases have been found in some liver diseases, in far-advanced pancreatic atrophy, or late after acute necrosis However, attempts to attach diagnostic significance to this generally have proved groundless

Despite all the exceptions, serum amylase elevations will be found to reflect pancreatic disease in 75 per cent to 85 per cent of all cases in which it is abnormal In the remainder, mechanisms responsible for elevation are generally quite understandable They include (1) absorption from intestinal fluids not normally present in the peritoneal cavity, (2) drugs, such as morphine, codeine, or T tube cholangiograms, temporarily interfering with pancreatic drainage, (3) systemic diseases affecting the pancreas incidentally, such as mumps, periarteritis nodosa, and lupus erythematosus, (4) interference with normal urinary excretion by uremia, or rarely, in kidney disease without uremia

Serum lipase behaves in a manner similar to amylase, serum trypsin is difficult or impossible to measure

### *Urinary Amylase*

When renal abnormality is suspected or the serum amylase elevation is inconsistent with the clinical picture, urinary amylase should be measured A casual urine specimen is not enough Urine must be collected over a time interval of two to eight hours Normally, urinary excretion of amylase *per hour* should equal the serum level A urinary excretion rate definitely below this level suggests a renal cause for serum amylase elevation

### *Diagnostic Paracentesis*

Paracentesis of the acute abdomen with a small gauge No 18 or No 20 spinal needle is a safe and useful diagnostic procedure It is indicated when, following examination, amylase, and x rays, the clinical diagnosis remains in doubt It should also be performed whenever acute pancreatitis is not followed by prompt clinical improvement

One half cubic centimeter of ascitic fluid or less may be useful for diagnosis Its color and odor are important regardless of any amylase elevation (Fig 14 7) A foul odor is suggestive of compromised bowel, and is not found in pancreatitis The presence of bile indicates a perforated viscus The fluid should be shaken, distinctly yellow foam can be seen when bile is present

One drop should be smeared and stained for bacteria These are rarely evident in pancreatitis, but they may be found within four hours after vascular compromise of bowel A frankly acid pH on Nitrazine paper is indicative of a perforated ulcer, although a neutral response is more frequent

A few drops of fluid may be diluted to a considerable extent for an amylase determination A high level will support the diagnosis of acute pancreatitis during at least the first five days of illness However, a reliable finding of a low level makes the diagnosis of acute pancreatitis extremely unlikely

## Treatment of Acute Pancreatitis

### *Replacement of Fluid Losses*

The treatment of choice is nonoperative and supportive The most important factor in assuring survival is adequate replacement of fluid losses There are at least three areas for loss (1) Edema of the pancreas is always marked, and extends throughout the retroperitoneal

tissues (2) The formation of ascites may be extremely rapid (3) As ileus develops, fluid accumulates in the walls and lumen of the static bowel Although this fluid is completely lost to the circulation, and can total three liters within a few hours, the only external evidence is increasing abdominal distention Losses are reflected, however, in an early hemoconcentration, a rising hematocrit, and a rising pulse rate They may be confirmed by blood volume measurement

Normal saline has been administered intravenously for a number of years to combat this hemoconcentration and tachycardia However, with an inflamed pancreas weeping fluid, saline infusions may be lost into the abdomen almost as rapidly as they are given. Colloid in some form must be administered early in the treatment program This may be difficult to appreciate, especially when the hemoglobin and hematocrit are high Yet these patients are in desperate need of plasma and whole blood

It is possible to divide acute pancreatitis patients into two groups according to the severity of the lesion In the mildest attacks, with pain and a high amylase but no ileus, blood volume deficits measured by the radioactive tagged albumin technique have not been marked. Large quantities of colloid are not needed Such patients have made up about one third of the total experience. In the more severe group, characterized by tachycardia and ileus, repeated determinations have demonstrated blood volume deficits averaging 1,500 ml in the first 24 hours

In the first few hours of sickness it is impossible to determine whether a significant paralytic ileus will develop It is probably better to treat all such patients as though a severe attack had occurred Since 1953, it has become routine to administer 1,500 ml of protein containing solution within the first 24 hours Since hemoconcentration is present whole plasma appears best Plasma stored for six months at room temperature or properly treated and irradiated can now be administered without fear of hepatitis virus

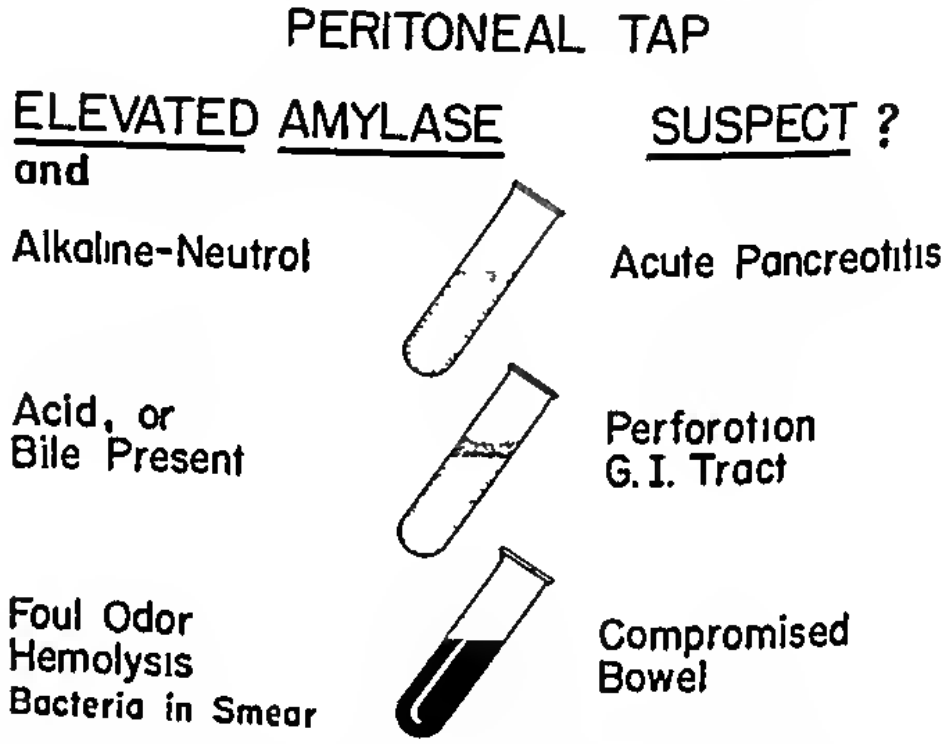


Fig 11 7 At diagnostic paracentesis, the gross characteristics of the fluid are important, regardless of its amylase values

Concentrated human serum albumin may be administered instead of plasma It has the advantage of containing no salt For this reason, it is p actically impossible to administer too much albumin Saline can then be regulated to the individual patient s needs If no plasma or albumin is available, or if the hemoglobin is low, whole blood should be given instead Treatment with 1,000 ml of colloid is continued daily until the pulse rate is normal, dependent veins are filled, and abdominal distention is decreasing Of course, the usual needs for water, salt, and potassium are also provided intravenously

Hemoglobin frequently falls to surprisingly low levels after three or four days of adequate treatment with albumin or plasma. Circulating trypsin may be responsible in part for this It is known to increase the fragility of red cells, and Berridge has elicited evidence that red cell destruction takes place As the hemoglobin level falls, the colloid therapy should include transfusions of whole blood

The early and liberal administration of plasma, albumin, and whole blood, beginning in 1953 in our own hospital, has materially lowered the death rate (Fig 14 8) When colloids are given routinely, they are given early, without awaiting the appearance of hypotension This greatly increases their effectiveness, and has lowered the incidence of shock as well

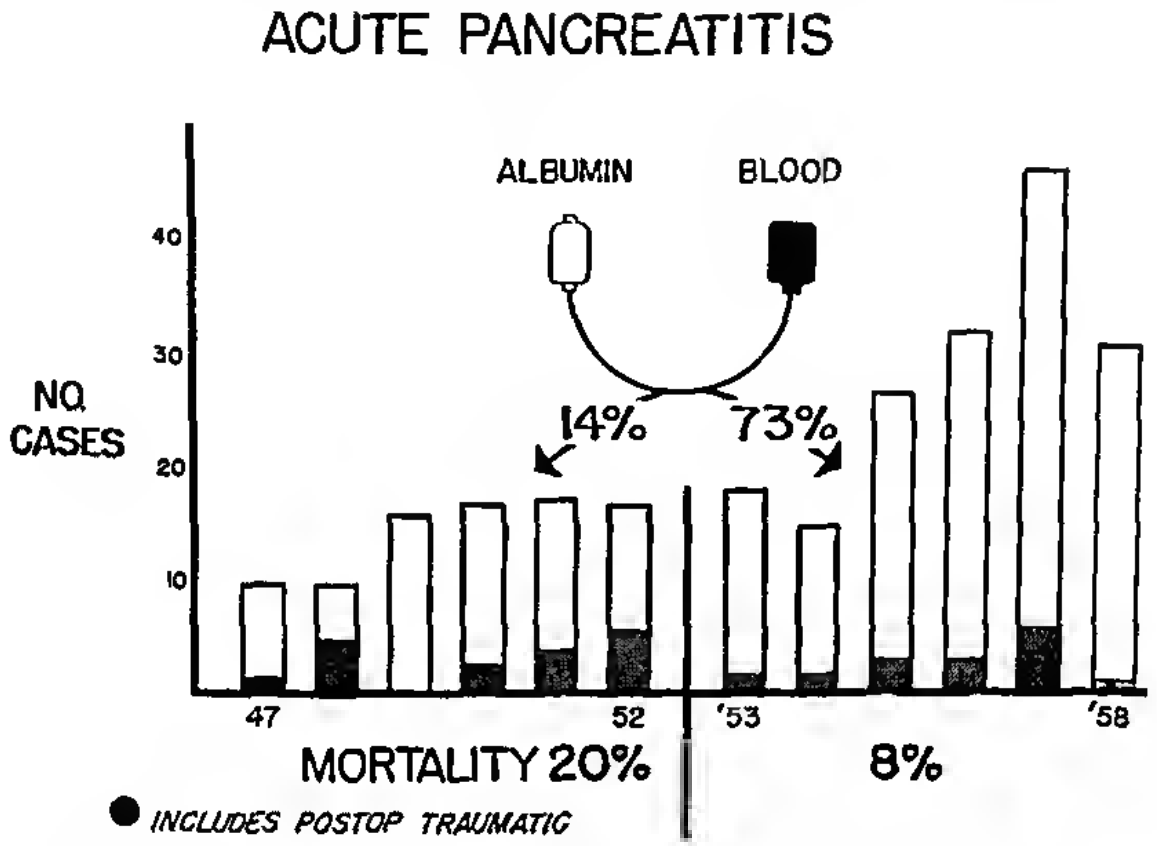


Fig 14 8 Acute pancreatitis The early and routine use of blood and albumin since 1953, to replace acute blood volume deficits, has materially lowered the mortality in all forms of acute pancreatitis The relatively severe postoperative and traumatic varieties are included Increasing numbers of cases correspond to increasing admissions as new beds are opened

*Rest*

As in the treatment of any inflammation, rest for the inflamed pancreas is extremely important Gastric suction not only relieves the paralytic ileus, but also minimizes the entry of gastric acid into

the duodenum, a normal stimulant of pancreatic secretion

In addition to gastric suction, vagal stimuli should be blocked by parenteral atropine Vagal stimulated pancreatic secretions are particularly rich in enzymes Inhibiting their release with atropine seems more important than any disadvantage from the drying effects of atropine on secretory volume

### *Pain Relief*

Pancreatic pain is notoriously resistant to the usual doses of narcotics However, their effects are much improved when stimuli for pancreatic secretion have been effectively blocked Morphine should be avoided, because of spasm in the sphincter of Oddi, which can interfere with pancreatic and biliary drainage Meperidine hydrochloride (Demerol) does not produce this spasm, and has been effective

When pain is intractable, procaine injection of splanchnic nerves bilaterally has been effective This is rarely necessary in our experience, and definitely increases the danger of hypotension

### *Corticosteroid Therapy*

The rationale for treatment with cortisone is attractive, since pancreatitis is a self limited, sterile, inflammatory process, with no more specific therapy

When cortisone has been used in patients, it has been almost impossible to determine whether or not it has helped since much other therapy has also been employed For these reasons we have investigated the benefits of cortisone therapy in experimental animals

In a series of dogs an acute pancreatitis was induced that is 100 per cent fatal if untreated If adequate albumin or plasma is administered 100 per cent survival can be regularly achieved Cortisone alone produced 50 per cent survival Cortisone combined with half the usual amount of colloid produced no additional survivals Examination of the surviving animals showed no difference in pancreatic damage between those treated with cortisone and those treated with colloids

Cortisone administration is not without danger It increases the risk of gastrointestinal hemorrhage, which is already a danger In the animals treated with cortisone for 48 hours, there was a 33 per cent incidence of ulcer and hemorrhage

Cortisone may be lifesaving when there is clear indication of adrenal insufficiency This should be suspected when large quantities of plasma, whole blood, or albumin bring little response In less critical clinical situations, cortical steroids probably should not be used

### *Prevention of Complications*

INFECTION While pancreatitis undoubtedly begins as a sterile inflammatory process, secondary bacterial invasion is common At operation or autopsy late in its course, cultures have shown coliform organisms, staphylococci, and streptococcal variants For this reason, the administration of antibiotics with as broad a spectrum as possible appears justified

HEMORRHAGE Whenever a patient is treated with both gastric suction and antibiotics, prothrombin levels fall Secondary hemorrhage from acute erosions in the stomach or duodenum accounted for half of the deaths in one series They occurred in 8 per cent in the 307 cases reported by Paxton and Payne Therefore, prothrombin times should be checked vitamin K given parenterally and evidence of hemorrhage watched for

Gastric retention is an important cause of acute secondary peptic ulceration Pancreatitis provokes this by interfering with peristalsis in the adjacent duodenum Therefore it is important to maintain gastric suction until effective peristalsis has clearly resumed

CALCIUM DEFICIENCY Significant quantities of calcium may be deposited in areas of fat necrosis as calcium soaps Serum calcium usually falls If it reaches 7 0 mg per cent or lower, this is an ominous prognostic sign

Serum calcium should be measured before calcium therapy whenever possible, since a high level can be a diagnostic clue to hyperparathyroidism Acute pancreatitis may be secondary to this, as Cope has shown

One Gram of calcium gluconate per day may be added to the intravenous fluids If tetany is a problem, parathyroid hormone as well as calcium may be necessary

DIABETES MELLITUS In susceptible individuals or in particularly severe pancreatitis, frank diabetes mellitus may be produced In most cases this disappears with recovery of the patient However, during the acute phase blood sugars are elevated in at least 10 per cent of patients, frequently without glycosuria They should be determined every 48 hours

JAUNDICE Edema in the head of the pancreas produces transient jaundice in 10 per cent to 20 per cent of cases Persistent or deepening jaundice suggests a pseudocyst in the head of the pancreas or an abscess in the lesser peritoneal sac These can be demonstrated by roentgen study of the stomach and duodenum

### *Convalescent Management*

In the average case of moderate severity, gastric suction can be removed on the fourth to fifth day of treatment Caution is required, a bland ulcer type diet should be employed Peaks of gastric acidity must be avoided Atropine is continued, using oral preparations Small meals, between meal feedings, and regular antacids in generous quantity are all important

The well known stimulants of gastric acidity must be withdrawn Coffee, tea and cola beverages, with their high caffeine concentrations, are frequent unsuspected trouble makers Cigarettes are stimulants to gastric acidity in some individuals Obviously, alcohol is contraindicated Narcotics must be withdrawn as rapidly and effectively as possible

SURVEY FOR PRECIPITATING FACTORS An x-ray survey of the gastrointestinal tract should be made to rule out lesions that may precipitate further attacks Oral dye is given for cholecystography If the gallbladder is visualized, gallstones may be demonstrated If the gallbladder fails to visualize, this is not evidence of gallbladder disease for three to four weeks following acute pancreatitis Intravenous cholangiography should then be considered This technique will regularly visualize the biliary tree despite pancreatitis unless jaundice or cholecystitis is also present

Alkaline phosphatase should be determined It can be a sensitive indicator of a persisting partial biliary obstruction, possibly by a common duct stone

A barium contrast examination of the upper gastrointestinal tract should be performed Postbulbar ulcer may cause pancreatitis through spasm at the sphincter of Oddi Special attention is given to the second and third portions of the duodenum, where enlargement of the C loop, a changing pattern in the mucosa, or displacement of the ligament of Treitz may indicate a pancreatic mass or pseudocyst In the patient with recurrent symptoms, quantitative 12 hour measurements of gastric acidity can show surprisingly high values in the absence of ulcer Antacid therapy may be indicated

## Indications for Operation

A prompt and satisfactory response should be expected when nonoperative treatment has been adequate The principal indication for operation is a reasonable doubt of the diagnosis, whether or not the amylase is elevated

### *Diagnostic Laparotomy*

When pancreatitis is found at diagnostic laparotomy, operative trauma should be minimal Drainage of the pancreas is effective only when there are cystic fluid accumulations or a pseudocyst in the lesser peritoneal sac The biliary tree should be decompressed, whether stones are present or not, simply by placing a tube in the gallbladder

on and dye injection, and the trauma of strumentation

Opening the duodenum is avoided, unss there is genuine evidence of am ullary disease, especially when residual iflammation is evident in the pancreas lowever, when patency of the ampulla in doubt, the duodenum should be nobilized, opened, and the sphincter livided under direct vision The pan reatic duct can then be gently explored o rule out any other obstruction sphincterotomy is performed at operation or biliary disease only to rule out all obstructions in the common bile or pancreatic ducts When no biliary disease is present, neither sphincterotomy alone nor in combination with other biliary pro cedures has been effective in preventing subsequent attacks

When no precipitating cause for the attack of pancreatitis can be demon strated, the prognosis for the future must remain guarded Surgery of any kind has little to offer The hazard of recurrent attacks is significant A careful ulcer program with a bland diet, an oral atropine preparation, and regular antacids, ap parently holds the best hope for the future

## POSTOPERATIVE PANCREATITIS

A particularly dangerous and insidious form of acute pancreatitis occurs after upper abdominal surgery, usually about 24 to 48 hours following operation It is not easily recognized at first, being marked by incisional pain and postoperative changes in vital signs The cardinal symptoms are (1) unusual up per abdominal pain, especially when referred into the back, or (2) unexpected paralytic ileus with abdominal distention Marked tachycardia usually accompanies this development Once suspected, post operative pancreatitis can almost always be confirmed by finding a very high serum amylase

The same regimen of treatment employed for acute idiopathic pancreatitis has seemed best for these difficult cases. Gastric drainage, parenteral atropine, and antibiotics are helpful Particular care must be devoted both to keeping the lungs clear and to giving sufficient plasma albumin, or whole blood to re place the protein lost into the retroperitoneal tissues The pulse rate is a helpful guide to colloid replacement Despite all known measures the mortality remains high, approaching one third of the patients with this dread complication

Although the cause is debatable, certain preventive measures appear worthwhile In biliary surgery, instrumentation of the common duct must be very gentle Solu tions for irrigation or cholangiography must be injected with very slight syringe pressure Indwelling tubes in the sphinc ter of Oddi should be avoided, unless it has been cut Then they are probably unnecessary At gastrectomy, when dis section must be carried beyond the duo denal bulb, injury to the lesser pancreatic duct of Santorini should be carefully avoided When edema in the duodenal walls can be expected, a decompressing tube in the gallbladder or common duct is logical and worthwhile At splenec tomy or left nephrectomy the likelihood of injury to the pancreatic tail should be appreciated When it has been cut the raw surface should be closed with nonab sorbable sutures to avoid leaking secre tions

## TRAUMATIC PANCREATITIS

Blunt trauma to the abdomen can induce a diffuse pancreatitis that is sur prisingly severe This is uncommon and easily overlooked, when there are severe injuries elsewhere. Automobile accidents are a frequent cause, with steering wheel injuries providing half the cases In children, where the ribs are more elastic, severe pancreatitis has followed falls over bicycle handlebars

In all cases, peritoneal irritation, para lytic ileus, and tachycardia were present Perforation of a viscus or hemorrhage must be ruled out by x ray and diagnostic

paracentesis When traumatic pancreatitis can be confirmed by amylase elevation, laparotomy in a critically injured patient may be deferred For these reasons, serum amylase has been measured routinely following any blunt trauma to the abdomen

The principles of treatment are the same The loss of plasma into retroperitoneal tissues may be severe, and requires compensation The mortality rate is high, approaching one third, but major associated injuries have complicated all deaths

Pseudocysts are regularly observed in recovering patients, since the original trauma usually ruptures a major duct within the gland Simple drainage of the cyst by catheter to the exterior is satisfactory treatment This is not usually followed by a troublesome fistula since the remaining ducts are normal They usually can resume function once edema subsides

At laparotomy for penetrating wounds of the abdomen, pancreatic injury may be encountered Pancreatitis will not extend beyond the area of immediate injury unless there is interference with ductal drainage or major blood supply In placing sutures for the control of bleeding the position of the major ducts should be avoided Unless the tear in the capsule lies along the margin of the gland, effective closure is not possible, and the effort is not justified However, drainage to the surface should always be employed Pancreatic secretions escaping freely into the abdomen when not adequately drained can produce widespread fat necrosis and severe peritonitis.

## CHRONIC PANCREATITIS

Pancreatic inflammation can become slowly progressive, with acute flare ups and remissions continuing through many months or years Progressive pancreatic destruction and fibrosis results yet the cause remains conjectural Comfort and his associates [1] the several clinical stages together to delineate a natural history for the disease This was characterized as chronic relapsing pancreatitis

In most patients, a beginning can be traced from a typical bout of acute pancreatitis Recovery ensues, but this is followed after an interval of weeks or months by another acute attack, and then by another If following the first bout of acute pancreatitis a precipitating cause such as a common duct stone can be found and removed, pancreatitis recurs in less than 10 per cent of patients However, when no such cause can be identified and corrected, two thirds of patients will have subsequent attacks Each successive recurrence appears to make another more likely

At first, patients seem well between acute episodes, and present no objective evidence of disease Later, as the interval between attacks shortens, chronic dyspeptic symptoms emerge, and bouts of pain merge into one another These patients may be treated for suspected ulcer and respond temporarily to intense antacid therapy Eventually this fails, as pain becomes aggravated by eating

The patients develop food idiosyncrasies and limit dietary intake more and more As pancreatic destruction progresses secretions reaching the intestine become insufficient for normal digestion of what food is eaten This results in the steatorrhea, weight loss, avitaminosis, and cachexia, which mark the late stages of the disease Discouragement for both the patient and his physician leads to increased dependence upon narcotics In some series, as many as one third to half of the patients are addicted

Chronic pancreatitis rarely if ever directly causes death even in acute exacerbation It is rather a crippling insidiously progressive disease with an irregular and prolonged course subject to numerous complications.

### Criteria for Diagnosis

It is particularly difficult to determine whether a patient who has had one or

wo bouts of acute pancreatitis is develop ng chronic disease It is sometimes neces ary to be arbitrary in this Between attacks the disease defies diagnosis until uch far advanced changes as calcifica ons cysts or steatorrhea have appeared However any one of the following criteria eem sufficiently objective to establish the presence of progressive and chronic pan creatitis

1 Three or more attacks of acute pancreatitis proved by high amylase elevations during pain

2 Demonstration of the typical patho log c changes in the pancreas usually by x ray of calcification or chronic pseudo cyst format on

3 Steatorrhea and cachexia o ing to dim nished pancreatic enzymes when tl ere are no other reasons to suspect carcinoma

The association of diabetes mellitus with this clinical entity has been empha sized It may appear at any time and does so in about half of the patients perhaps because of islet destruction How ever it is too irregular in incidence and onset to be considered an essential part of the disease

The middle decades of life are pri marily involved with three quarters of the cases observed between the ages of 30 and 60 Unl ke acute pancreatitis males predominate over females two to one This probably reflects the higher incidence of alcoholism n males and the alcohol c factory in etiology The race distribut on corresponds to the hosp tal populat on

Fig 14 9 Far ad anced fibros s squeezes the rema n ng ac nar cells and contr butes to secre tory stas s and calc ficat on.

## Pathology of Chronic Pancreatitis

Tl e n ldest permanent patl ologic change includes fibrosis (Fig 14 9) with

generalized increased firmness and exaggerated lobulations

### *Calcification*

Calculi appear eventually in about half the cases These range from a few fine flecks to multiple stones a centimeter or more in diameter When present, they can be visualized by x ray, because of their high calcium content Edmundson has shown that they are always found in cavities lined by ductal epithelium Some patients are symptomatic for months or years before calcification appears, and in others they may be visualized before any pain or other symptoms have appeared

### *Cyst Formation*

Pseudocysts develop in 20 per cent to 25 per cent of patients in the course of chronic pancreatitis The earliest are necrotic cavities within the pancreatic substance, filled with inflammatory debris and stagnant secretions Sometimes the cavity appears to be a remarkable dilatation along the main duct More often, it suggests a 'blow out' along one wall of a major duct, and extends outward from it Its wall is made up by a chronic fibrotic and inflammatory membrane with no epithelial lining This wall grows thick and strong as the mass enlarges beyond the pancreas A remarkable size can be reached requiring drainage, before the underlying pancreatitis can be treated reported by Zollinger, DuVal and Peustow

### *Pathogenesis*

The cause for progressive pancreatic inflammation remains in doubt The commonly associated lesions are the same as in acute alcoholism, biliary disease and trauma

Alcoholism is more frequent and important, appearing in one third of our cases In these the disease is severe with a high incidence of calculi and pseudocysts In most histories, alcoholic excess precedes pancreatitis In chronic alcoholics, pancreatitis is found at autopsy in 20 per cent to 47 per cent Such facts suggest that alcohol can induce 'cirrhosis' in the pancreas just as it appears to do in the liver

Biliary disease is less frequent, appearing in about one third of the cases In very few, a traumatic onset can be defined In the remainder, ductal inflammation and secretory stasis offer the best current explanation Causes for this need much further investigation

## Clinical Diagnosis

### *Pain*

Upper abdominal pain is the outstanding complaint It may predominate in the epigastrium or in either upper quadrant Mid dorsal back pain is frequent but not always found The distribution probably corresponds to the area of pancreas most involved In each patient, the pattern remains remarkably constant through the course of the disease

### *Serum Amylase*

It can be extremely difficult to prove that pain is pancreatic in origin early in the disease, before calculi or cysts have appeared Between attacks, patients appear well Amylase is elevated in both serum and urine only during pain, and it may return to normal within 24 hours

To find objective evidence of pancreatic disease between attacks, many substances have been injected and the serum amylase measured Small doses of secretion or Urecholine can stimulate the pancreas to secrete If its outflow is obstructed, serum amylase should rise within two hours Morphine can increase spasm at the sphincter of Oddi during the digestion of food Presumably pain and amylase elevation would indicate chronic pancreatitis

Diagnostic responses to these tests are extremely irregular in proved pancreatitis Acute exacerbations have been precipitated by these drugs Transitory serum amylase elevations can be produced in normal individuals Therefore, not much diagnostic significance can be attached to these maneuvers

A persistently elevated serum amylase does not necessarily indicate chronic pancreatic disease Abnormalities of renal function, without uremia, may prevent normal amylase excretion, and elevate serum levels This possibility is rare but it can be ruled out by finding that urinary amylase excretion *per hour* equals the serum level

Lipase parallels amylase Many other enzymes have been investigated in the hope of developing a blood test for chronic pancreatitis So far, none is more specific than amylase, and this is of value only during episodes of pain

### *X-Ray*

Plain films of the abdomen should be obtained before contrast medium is given, so that the finer calcifications will not be missed Whether or not symptoms are present, calculi indicate some degree of chronic pancreatitis

Upper gastrointestinal examination with contrast media is important, to localize the calculi to the pancreas In addition, changes in contour of the stomach or duodenal C loop can indicate a pseudocyst, but only when it is sizable (Fig 14-10) Peptic ulcer must be ruled out as the cause for symptoms

The biliary tract must be fully evaluated When the gallbladder appears

Fig 14 10 Upper gastrointestinal examination in a 46-year old man with persistent back pain Mass arising in pancreas presents superiorly to stomach, through gastrohepatic ligament and proved to be a pancreatic pseudocyst

normal intravenous cholangiography should be performed to visualize the common duct If this is dilated or stones are proved operation is indicated

Disease in the tail of the pancreas is more difficult If a cystic mass is particularly large, displacement of the left kidney may be found on intravenous pyelography This is nearly the only way to establish its presence The survey for abdominal sources of pain should be completed by a barium enema to rule out colon lesions.

### *Loss of Digestive Enzymes*

A decrease in the pancreatic enzymes reaching the intestine can indicate pancreatic disease In a few patients this may be its only objective evidence However, before this loss is detectable, the ducts must be completely obstructed or the parenchymal destruction far advanced

Pancreatic function tests are usually worthwhile only when significant weight loss has occurred They can point to the pancreas as a cause for symptoms, but they cannot differentiate between inflammation and carcinoma

### *Duodenal Aspiration*

For quantitative duodenal aspiration to be of value, precise techniques are necessary A double lumened tube is positioned under fluoroscopic control so that while one lumen aspirates the duodenum, the second aspirates the stomach This prevents admixture of gastric juice to the duodenal samples

Intravenous secretin is administered and elicits from the normal pancreas within 80 minutes several hundred milliliters of watery secretion rich in bicarbonate with some amylase If the volume is sharply reduced pancreatic ductal obstruction is present owing to cancer or pancreatitis Disease limited to the body or tail does not reduce the volume, since the head may still respond If a good volume of secretions is obtained but the bicarbonate or amylase is reduced, destruction of the secreting parenchyma is implied suggesting pancreatitis

This test is uncomfortable, limited in value and too infrequently utilized in most clinics to be reliable

### *Steatorrhea*

With a normal pancreas not more than 5 per cent of ingested fat appears in the stool This may rise to 50 per cent or more with loss of pancreatic lipase and can be measured by direct stool analyses.

More subtle losses of pancreatic lipase can be detected by administering whole fat tagged by 50 to 100 microcuries of radioactive iodine If pancreatic lipase is normal, radioactivity in the serum will rise to a peak of at least three times the initial level within three hours Radioactivity in the stools should remain low If pancreatic lipase is diminished radioactivity remains low in the serum and high in the stools Similar but less precise results can be obtained with proteins such as radioactive iodine-tagged albumin

Steatorrhea owing to intestinal malabsorption syndromes can be ruled out by giving tagged fatty acids rather than whole fat In pancreatic disease, tagged fatty acids will be normally absorbed since they are the end products of lipase activity

These techniques are precise, easily performed, and do not require messy stool analyses They promise to be of genuine usefulness, and have been described in detail by Shingleton and others

The oral starch tolerance test in which blood sugar levels are measured after the ingestion of a standard starch meal, has proved much less reliable in the detection of pancreatic amylase deficiencies.

## Complications of Chronic Pancreatitis

### *Jaundice*

Obstructive jaundice has been reported in as many as 20 per cent of patients with chronic pancreatitis Benign pancreatic encroachment upon the common duct may be due to transient edema fibrosis and contraction or a pseudocyst If the latter, effective drainage should clear the biliary tree

### *Cirrhosis*

After normal enzyme production has been lost, hepatic cirrhosis is a frequent finding A diffuse fatty infiltration is followed by inflammation and then [illegible] These changes are similar to those [illegible] regularly observed following total pancreatectomy

In their early stages they can be prevented or reversed by the oral administration of supplemental pancreatic enzymes or by adding lecithin choline or methionine to the diet

### *Peptic Ulcer*

Peptic ulceration is seen in 10 per cent to 15 per cent of patients with chronic pancreatitis, and usually appears late in its course Hypersecretion of gastric acid, as measured by 12-hour overnight resting aspirations, can be found in additional patients without ulcer Antral stimulation from delayed emptying of the stomach and ineffective duodenal peristalsis, may explain this It can be a rational basis for antacid therapy

Acute duodenal obstruction has also been precipitated by chronic pancreatitis, almost always through the rapid enlargement of a pseudocyst encroaching upon the duodenum

### *Tuberculosis*

The coexistence of pulmonary tuberculosis or its reactivation in the course of chronic pancreatitis occurs with surprising frequency, much more than would be expected as a coincidence

## Management of Chronic Pancreatitis

### *Medical Therapy*

In the absence of specific surgical indications, a vigorous attempt at medical management seems indicated before operation is considered This is essentially the program used for convalescence after acute pancreatitis It is designed to (1) prevent peaks of pancreatic stimulation, and (2) supplement failing function

Vagal stimuli are inhibited by parasympatholytic drugs, such as atropine, belladonna, or Pro-banthine In addition, antacids should be employed vigorously after meals

The objective of dietary control is to eliminate strong stimulants of gastric acid An ulcer program is used, except that fat must be limited to individual tolerance

Caffeine is a strong stimulant of gastric acidity Coffee, tea, and colas must be avoided, particularly between meals Cigarettes and aspirin taken on an empty stomach are similarly irritating These are more frequent sources of trouble than alcohol, which obviously must be eliminated for any therapy to succeed Until a definitive cure for chronic pancreatitis is developed, prescribing narcotics leads only to addiction

Remarkable improvement in food tolerance and nutrition can be achieved with oral enzyme therapy Hog or beef pancreas, desiccated and powdered, seems superior to more refined preparations, as well as less expensive Several teaspoonfuls, rather than capsules, should be taken with each meal High dosage is important for the best results The equivalent of 4 to 8 Gm of pancreatin, U S P, may be necessary The only disadvantage to these preparations is an unpleasant taste until each patient learns which foods disguise this for him Fruit juices, cereals, and meats seem most effective Enzyme therapy can be improved by adding bile salts in capsules Fat soluble vitamins and hematinics should not be neglected

### *Surgical Indications*

A clear cut indication for operation may be any one of these

1 Evidence of gallstones or a dilated common duct on cholangiography

2 Obstructive jaundice

3 A mass or pseudocyst within the pancreas, excepting only those that appear immediately after acute or traumatic pancreatitis and quickly subside

4 Reason to suspect carcinoma onset of symptoms after the cancer age has been reached, with unremitting pain and weight loss, regardless of amylase elevations

5 Duodenal obstruction or peptic ulceration

6 Failure of a serious effort at medical therapy, manifest by recurrent acute pancreatitis, or pain with weight loss despite good management

## Operations for Chronic Pancreatitis

### *Preoperative Preparation*

Weight loss brings contraction of the actual circulating blood volume and

plasma proteins even when the hemoglobin concentration is normal Preoperative transfusions provide the most important systemic support that can be offered Two to four pints of blood may be required, an average of one for each ten pounds of weight lost

Prothrombin activity is frequently below normal Parenteral vitamin K can correct this unless liver function is seriously impaired

*Pancreatic Exploration Biopsy*

INCISION The commonest incision is the vertical right paramedian since the operation will always include exploration of the biliary tree When the principal lesion is known to lie in the body or tail of the pancreas, a mid line or left paramedian incision may be used. The xyphoid may be removed to improve exposure

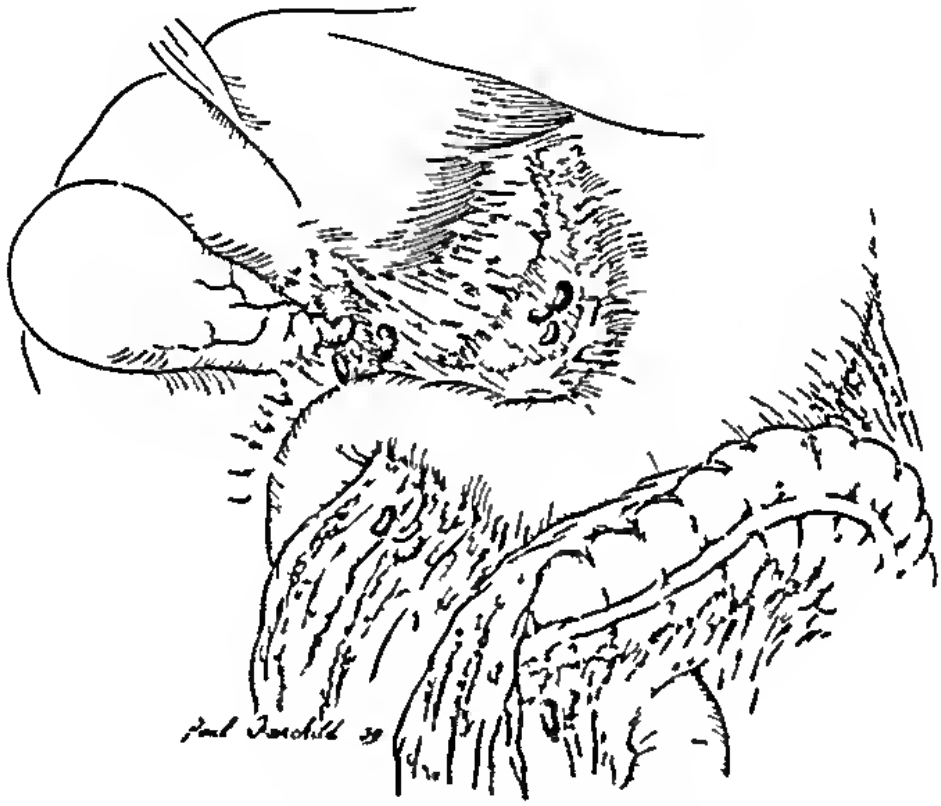

Fig 14 11 Four frequent sites of lymph node metastases from carcinoma of the pancreas are more readily biopsied than is the pancreas itself

EXPLORATION Carcinoma must always be suspected The areas of likely lymph node metastases are more readily examined and biopsied than the pancreas itself Four sites are commonly involved (Fig 14-11) (1) along the common bile duct just above or behind the duodenum (2) in the omentum where it arises from the head of the pancreas (3) around the superior mesenteric artery at the inferior pancratic border and (4) about the coeliac axis This is best exposed through the gastrohepatic omentum

The pancreas can feel diffusely indurated, owing only to benign inflammation If doubt remains after palpation and examination of the regional nodes the pancreas should be fully exposed for evaluation This may be accomplished readily by reflecting the omentum superiorly, and dividing its avascular attachments to the colon

BIOPSY Biopsy of the pancreas is unnecessary to confirm chronic pancreatitis However, a gross diagnosis of carcinoma requires direct biopsy for support when no metastases provide this proof The area of firmest consistency is most likely to yield tumor tissue If a cancer is present, confusing inflammation is to be expected distally along the obstructed ducts Therefore, when the precise site for biopsy is in doubt, the most proximal area of suspicious tissue should be selected

When the head of the pancreas is involved, it should be mobilized from its lateral peritoneal attachment (Kocher maneuver) This permits bidigital palpation and ready control of bleeding A narrow but deep and adequate wedge of tissue can then be safely obtained with a No 15 pointed scalpel The capsule of the gland is closed by one or two compressing mattress sutures of silk Complications of this procedure have not been a problem

### *Stage of the Disease*

Operations for chronic pancreatitis may range from simple choledochostomy to extensive resections entailing a major risk of mortality Similarly, the disease may range from mild edema and fibrosis to major cystic or calculous degeneration Accordingly operative therapy must be individualized and adapted to the pathology found Its results should be evaluated in this light The simplest effective operation obviously will be best Therefore a simple, rational classification of chronic pancreatitis according to its severity is needed as a guide to therapy Such a classification by stage, based on the pathologic situation in the pancreas is proposed in Table 14 1

TABLE 14 1 STAGES OF SEVERITY IN CHRONIC PANCREATITIS BY PATHOLOGY FOUND

| *Stage* | *Pathology* | *Usual clinical findings* |
|---|---|---|
| 1 Mild | Fibrosis or edema<br>No intrapancreatic degenerative changes or ductal obstructions | Recurrent acute pancreatitis |
| 2 Progressive | Degenerative changes<br>Calcification<br>Pseudocyst formation<br>Ductal obstructions | Chronic pain with acute exacerbations dyspepsia |
| 3 Severe | Far advanced atrophy<br>Severe calcification<br>Shrunken gland | Cachexia 20% body weight lost<br>Steatorrhea<br>Addiction<br>Frequent diabetes |

STAGE 1, MILD The mildest gross manifestations of chronic pancreatitis are edema swelling, and increased firmness in the gland The clinical diagnosis is usually based on recurrent attacks of acute pancreatitis Although alcoholism

TABLE 14-2 OPERATION FOR CHRONIC PANCREATITIS

| *Operation* | *Indication or rationale* | *Limitations or precautions* |
|---|---|---|
| A. INDIRECT | | |
| 1 Biliary | | |
| *Cholecystectomy* / *Choledochostomy* | Stones, cholecystitis, or jaundice | Beneficial only if biliary disease present |
| *Sphincterotomy* (cholecystectomy also necessary) | Sphincter stenotic, or for exposure of ampulla, pancreatic duct | Intrapancreatic ductal obstruction, cysts must be ruled out or treated |
| *Choledocho-enterostomy*, to duodenum or jejunum, directly or by Roux-en-Y | Obstruction of common bile duct within the pancreas | Pancreatic ductal obstructions, cysts, may also be present |
| 2 Gastric | | |
| *Subtotal gastrectomy* | Decreases stimuli to pancreas by lowering gastric acidity, or bypassing duodenum | Pancreatic symptoms usually recur, helpful only when ulcer present |
| *Gastroenterostomy* | Decreases stimuli to pancreas through bypassing duodenum | Ineffective alone, except for duodenal obstruction |
| *Vagotomy*, and gastroenterostomy or pyloroplasty | Decreases both vagal and gastric stimuli to pancreas | Helpful ancillary procedure but does not attack progressive intrapancreatic disease |
| 3 Neurectomies | | |
| *Splanchnicectomy*, unilateral or bilateral, coeliac ganglionectomy | Relieves abdominal pain uncontrolled by any other means | Does not alter progressive pancreatic disease, pain usually recurs later |
| B. DIRECT ON PANCREAS | | |
| *Sphincterotomy-ductal dilatation, lithotomy* | Local ductal obstruction at sphincter or close to it | Relatively few obstructions so well localized, pancreatograms needed |
| *Subtotal resection* | Disease limited to body and tail of gland | Only occasionally removes all disease |
| *Retrograde anastomosis* tail to jejunum, direct or *Roux-en-Y* | Duct dilated in tail of pancreas obstructed proximally | Multiple ductal obstructions within pancreas must be cleared |
| *Pancreatic duct opened longitudinally*, closed, or anastomosed to jejunum | Clears multiple ductal strictures and large calculi | Extensive procedure, value not yet proved |
| *Total pancreatectomy*, pancreatoduodenectomy | Far advanced destruction of pancreas, intractable symptoms | Lifelong supplementary therapy, diabetes mellitus |
| *Ligation pancreatic ducts* (no longer performed) | Intended to produce complete atrophy of acinar tissue | Atrophy incomplete, pain recurs |
| *Cysts*: *Excision* | Modest size in body or tail | Only occasionally possible |
| *Internal drainage*, to stomach or bowel directly or Roux-en-Y | Satisfactory for nonresectable inflammatory cysts with firm walls | Other intrapancreatic ductal obstructions may need clearing |
| *External drainage* | Satisfactory if ducts open<br>Poor risk patients<br>Other extensive surgery<br>Friable cyst walls | Temporary pancreatic fistula formed, will not close if ducts obstructed |

may be a cause, biliary disease is much more frequent. In this stage, the pancreatic changes are largely reversible. The surgical correction of biliary disease may be expected regularly to achieve a good result. However, when biliary disease is not present, pancreatic ductal obstruction must be sought, either at the sphincter or within the gland itself. If cysts or obstructions within the pancreas are

found, more severe Stage 2 disease is present, and biliary surgery alone will be ineffective

STAGE 2, PROGRESSIVE Evidence of deterioration of a generally progressive nature in the pancreas itself marks off Stage 2 Calcification, cystic degeneration, and inflammatory changes in the major ducts are evidence of this Whether or not biliary disease is present, it is apparent from sad experience that biliary operations or sphincterotomy alone do not arrest the inflammation There is a wide choice of additional procedures The most effective appear to be those that truly improve pancreatic secretory drainage

STAGE 3, SEVERE In the very late end stages of pancreatitis, functioning parenchyma is almost completely replaced by fibrosis, calcification, or cyst formation Contraction and atrophy of the whole gland may be present Cachexia identifies this stage clinically It has been defined arbitrarily as loss of at least 20 per cent of normal body weight Extensive resections of irreversibly diseased tissue, even to total pancreatectomy, appear justified in an effort to relieve pain

### *Procedure of Choice*

Generally, the many procedures that have been employed for chronic pancreatitis can be divided into two groups (1) *indirect,* not upon the pancreas but upon the adjacent biliary tree, intestinal tract, or pancreatic innervation, and designed to influence pancreatic function, and (2) *direct,* attacking pathology within the pancreas itself These procedures have been classified in Table 14 2, together with an attempt to summarize the rationale and limitations for each

## Indirect Operations

### *Operations on Biliary Tract*

CHOLECYSTECTOMY AND CHOLEDOCHOSTOMY Gallstones will be encountered in about one third of the patients, and cholecystectomy is clearly indicated

An operative cholangiogram should be taken in every patient, whether or not gallstones have been found Free and easy flow of dye into the duodenum, under low pressure, should be assured Unless the common duct is too small to be opened safely, it should be explored The complete elimination of biliary disease may be expected to relieve chronic pancreatitis when (1) stones have been found and removed, (2) free flow of bile into the duodenum has been assured, and (3) the pancreatitis is mild, showing only the edema and induration of Stage 1 disease

SPHINCTEROTOMY PANCREATOGRAPHY Sphincterotomy is performed only under direct vision through the open duodenum There are at least two general indications (1) any doubt about the wide open patency of the sphincter, or (2) any suggestion that pancreatic ductal obstruction may also be present Such obstruction should be suspected whenever (a) the biliary findings do not explain mild (Stage 1) pancreatitis, or (b) more severe (Stage 2 or 3) pancreatitis is apparent from pseudocysts large calculi, or previous steatorrhea

Sphincterotomy alone can yield little benefit when the intrapancreatic duct is obstructed by strictures or calculi These have been found in 75 per cent of our cases in which they have been looked for (usually the more severe Stages, 2 and 3) Therefore, after sphincterotomy the pancreatic duct is always fully explored In a majority of cases, sphincterotomy will be merely the first step in approaching intraductal disease, and additional procedures will be required for its relief Obstructions usually can be demonstrated by gentle probing within a few centimeters of the ampulla Calculi may be removed and strictures dilated when feasible Usually they must be bypassed by anastomosis of the distal pancreas to the gastrointestinal tract Cysts must be effectively drained

If intrapancreatic ductal obstructions are not present and a truly stenotic sphincter is divided, pancreatic and biliary drainage will be improved and

stages The left side is resected first, since this innervates the major portion of the gland If pain relief is incomplete, the right side is approached Since these thoracic procedures cannot readily be combined with pancreatic exploration, the diagnosis must be clear beforehand

Less definitive denervation can be performed in combination with direct pancreatic procedures Bilateral coeliac ganglionectomy interrupts the principal sympathetic and sensory pathways Autonomic nerves entering the pancreas on its posterior surface around the superior mesenteric artery can also be divided

Admittedly, these procedures for sensory denervation do not alter the underlying disease process Unlike vagotomy, they produce no important changes in enzyme production or secretory activity

In 70 patients treated primarily by left splanchnicectomy, Mallet Guy reports 91 per cent good results after fifteen years In the experience of many others, pain initially relieved is very prone to recur, sometimes early, and is due to the expected progression of the disease Pseudocysts, abscesses, or extension of inflammation into adjacent tissues seem most often to blame

## Direct Pancreatic Procedures

Direct surgical attack on the pancreas can correct (1) ductal strictures or calculi, which may be removed or bypassed (2) localized diffuse fibrosis, which may be resected, or (3) cysts, which may be removed or drained The principles underlying all these procedures are (*a*) conservation of functioning parenchyma with (*b*) free secretory drainage for all parts of the gland (Fig 14-12) Although total pancreatectomy is feasible the permanent metabolic defects which follow discourage its use

### *Sphincterotomy–Ductal Dilatation, Lithotomy*

After sphincterotomy, an obstructing calculus may be encountered within a few centimeters of the ampulla Sometimes this can be gently fragmented and flushed out, opening the major duct for dilatation A pancreatogram is important to rule out further obstructions or significant cyst formation

When it cannot be dislodged, the calculus may be palpated from the anterior pancreatic surface Sometimes a tensely dilated distal duct can be felt A short incision may be made through the gland directly over one of these landmarks in an effort to enter the major pancreatic duct Instruments may be passed in either direction to insure ductal patency into the open ampulla

The pancreatic incision may be closed primarily with silk, sealing only the surface of the gland The duct will repair itself if it drains well When there is doubt about good ductal drainage it is better to anastomose a small opening to the adjacent stomach

If no distinct landmark can be found to guide the knife into the ductal system this type of exploration should not be attempted It is suited only for well-localized ductal obstructions When there is extensive calcification, advanced fibrosis, or any other reason to doubt its efficacy more definitive ductal exposure is indicated

### *Subtotal Resection*

In a fortunate few cases the principal disease appears confined to the tail of the pancreas, where it can be readily resected Pancreatitis that follows blunt abdominal trauma is likely to have this distribution

Excellent results may be expected from resection, but only when nearly all the disease can be removed However, the islets of Langerhans are most numerous in the tail The more tissue resected, the greater must be the calculated risk of diabetes

The remaining gland must be assured of good secretory drainage From its distal cut end, the duct should be gently catheterized into the duodenum to assure patency If the duct is dilated, or obstructed proximally, it should not be

closed, but implanted in the jejunum for retrograde secretory drainage.

*Retrograde Anastomosis*

Most pancreatic ductal strictures are firm and fibrotic. Many are jammed with calculi. Establishing permanently good function as long as the duodenal outlet remains occluded.

The tail of the pancreas is mobilized with the spleen, which is usually removed. The pancreas is transected four or five centimeters from its end to expose the dilated major duct. Calculi and debris

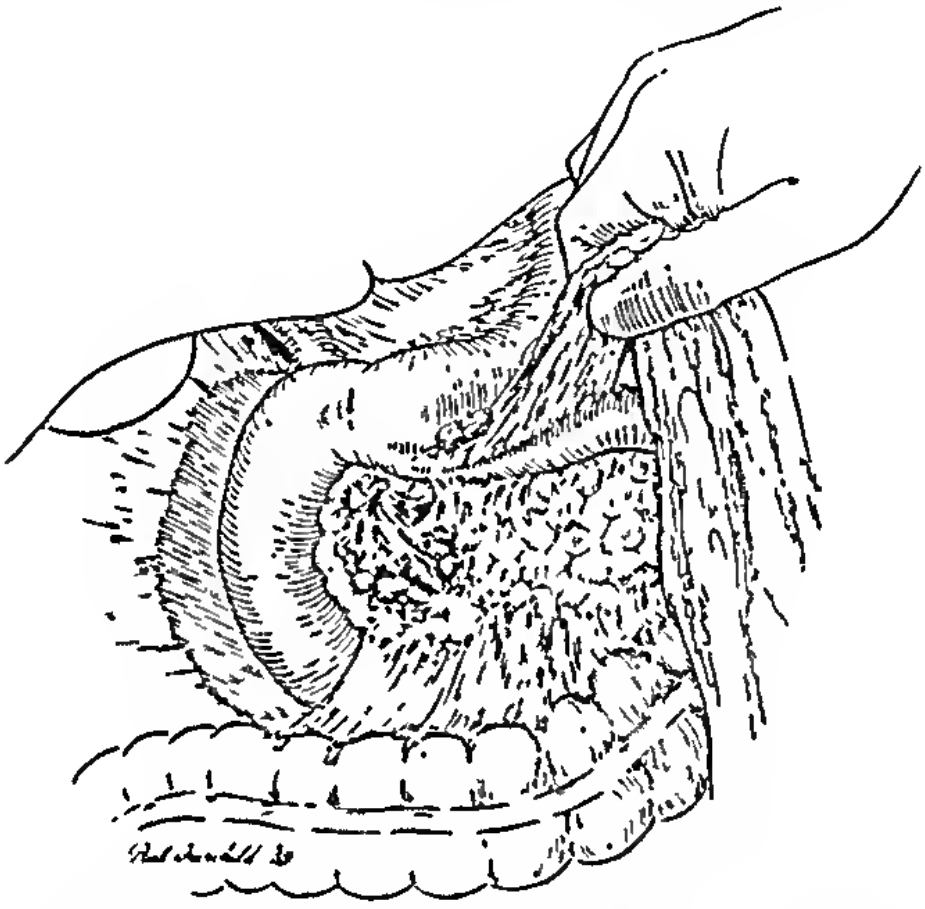

Fig. 14-12. For procedures directly on the pancreas, good exposure is essential. This can be obtained for the head of the pancreas by (a) mobilizing the hepatic and transverse colon inferiorly, (b) elevating the duodenum from its lateral peritoneal reflections (Kocher maneuver), and (c) reflecting the omentum superiorly, by dividing its avascular adhesions to the transverse colon.

Some defunctionalize a jejunal loop in the Roux en-Y manner and implant the pancreas in its open end We have not thought this necessary The tip of the pancreas can be brought through the left mesocolon nicely and anastomosed to the side of the upper jejunum Longmire states that he performed this operation in 1951 and abandoned it because of poor results Jordan and Howard have had a discouraging experience with nine alcoholic patients However, among DuVal s twenty six patients followed for at least three years, twenty, or 77 per cent, are free of pain With some encouraging experience, both Puestow and Zollinger have modified and extended this procedure

*Pancreatic Duct Opened Longitudinally*

Ductal strictures and calculi may be encountered at multiple points along the duct To free it of obstructions, working through its open ends, may be difficult or impossible Undrained central segments of pancreas may account for some of the failures of retrograde anastomosis to relieve all symptoms

In this situation, Puestow has laid the pancreatic duct open longitudinally for much of its length He has found a chain of lakes appearance, in which multiple strictures alternate with dilatations Calculi are easily removed, and strictures divided For closure, a defunctionalized loop of jejunum is opened lengthwise along its antimesenteric side This is sutured longitudinally over the opened duct

We have laid open the pancreatic duct longitudinally from the tail of the gland to within one inch of the duodenum to remove large ductal calculi (Fig 14-13) The duct is easily freed of all obstructions We have closed the pancreatic capsule primarily over a catheter in the duct to preserve its lumen This is removed during anastomosis of the tail to the side of the first jejunal loop Satisfactory healing and good results have been obtained

The healing of the longitudinally opened pancreatic duct has been studied extensively in dogs When only the pancreatic capsule is closed, the duct wall regularly heals with a good lumen, provided only that free secretory drainage is available

This procedure has been only recently applied to a relatively few patients The operation is extensive, but seems well tolerated In difficult cases it offers nearly the only means of preserving the pancreas, yet assuring it good drainage The early results are promising

*Pancreatoduodenectomy, Total Pancreatectomy*

In serious cases, degenerative inflammation seems most severe in the head of the pancreas Discouragement with all other procedures has led some to advocate pancreatoduodenectomy for chronic pancreatitis, just as it is done for operable cancer

The procedure may be somewhat more difficult after pancreatitis because of adhesive inflammation For carcinoma, the mortality has ranged from 12 per cent to 30 per cent, and the morbidity has been considerable Fewer patients have undergone this procedure for pancreatitis, but a similar risk is probably involved However, excellent symptomatic relief has been reported by Cattell in fifteen out of twenty patients, and by Longmire in seven out of eight

In some of these patients the distal pancreas could be preserved and reimplanted into jejunum This is an advantage nutritionally Diabetes may be avoided or is milder, less brittle,' and easier to manage

Altogether, the experience is small, the risks moderate, the lifelong metabolic handicaps considerable It appears that radical pancreatic resection should be reserved for those patients in whom the pancreas seems nearly destroyed (Stage 3 disease), and not amenable to any procedure short of this

*Ligation of Pancreatic Ducts*

Sound experimental evidence shows that if all ducts could be completely

ligated, total atrophy would ensue, sparing the islets. Progressive inflammation and pain should cease. When this procedure was tried in six patients by Cannon, only one benefited.

### *Pancreatic Cysts*

PSEUDOCYSTS. Pseudocysts of inflammatory origin make up 75 per cent to

Some of these cysts have been attributed to remote pancreatic trauma. This is difficult to understand, since pancreatic injury produces acute fluid collections within a few days. Rarely, a carcinoma obstructing the proximal ducts will produce a benign pseudocyst distally. Chronic pancreatitis is a much more frequent cause. Both must be suspected

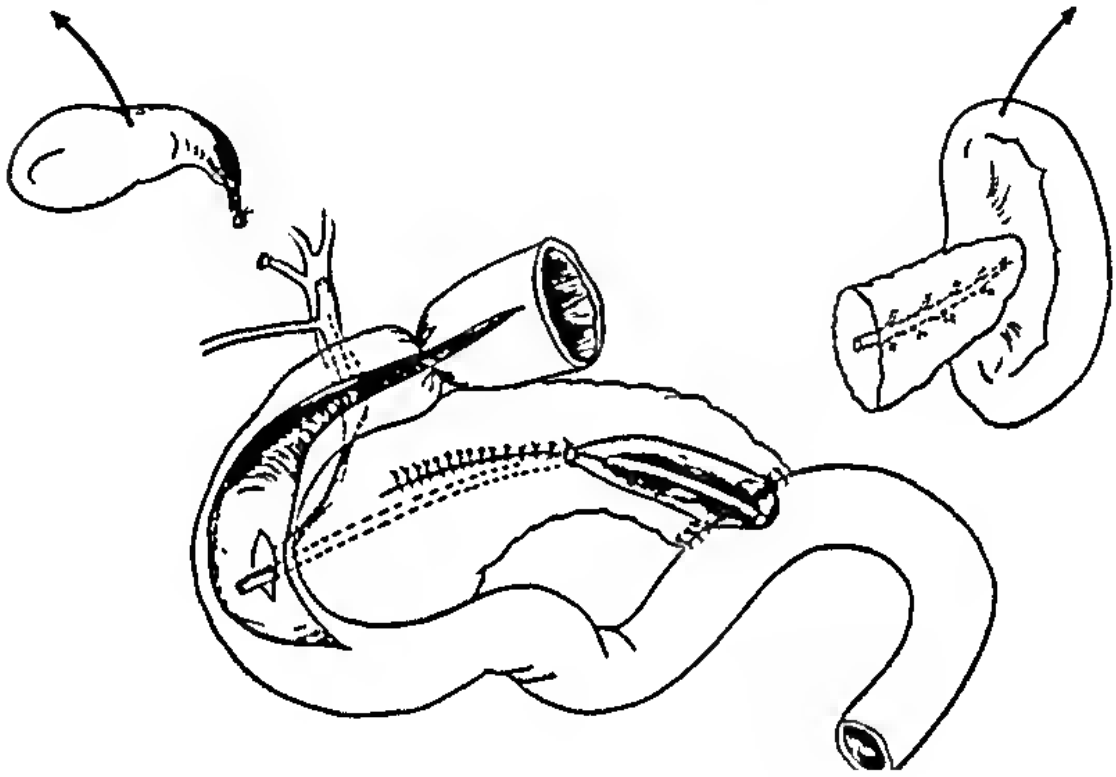

Effective surgical treatment can be provided by (1) total excision (2) internal drainage by anastomosis to adjacent gastrointestinal tract, or (3) external drainage by catheters, or by marsupialization of the cyst wall to parietal peritoneum

EXCISION Excision of the cystic mass provides the most definitive treatment, with least risk of recurrence Generally this is most applicable to pseudocysts of modest size, arising from the distal half of the gland, and easily separable from adjacent viscera The entire distal pancreas should be mobilized, together with the spleen It can then be transected cleanly proximal to the mass The attached and distal portions of pancreas should be removed with the cyst, since they drain into its cavity Usually this necessitates incidental splenectomy Ductal patency for the remaining pancreas should be assured

INTERNAL DRAINAGE Pseudocysts will also respond to effective drainage for their contained secretions Since their walls are fibrous they have an intrinsic tendency to contract Even very large cysts close down to narrow tracts This seems a better form of treatment (1) for cysts arising in the proximal half of the pancreas (2) when inflammation makes resection unduly difficult, (3) in poor risk patients and (4) when other extensive surgery has been performed

Internal drainage is generally preferred since this avoids a period of escaping secretions onto the skin surface The capsule itself must be sufficiently durable to permit a secure two layer anastomosis Upon opening the cyst, loose fibrous loculations may be cleared, and available debris removed

Some prefer to drain the cyst into a loop of jejunum that has been defunctionalized by either the Roux Y technique or proximal enteroenterostomy This more complicated procedure is probably unnecessary Attachment to either the stomach or the side of a jejunal loop has proved equally satisfactory The completed anastomosis should admit two to three fingers

A few late recurrences of pain and pseudocyst formation have been noted after this procedure These are probably related to progression of the underlying pancreatitis, with persisting or recurrent ductal obstructions

In most cases the cyst cavity communicates with the major pancreatic ducts (Fig 14 14) This may be demonstrated by x ray after injection of contrast media into its lumen Cyst fluid high

Fig 14 14 X ray taken at operation in R R Contrast medium injected into a pseudocyst in the head of the pancreas demonstrated communication with the tortuous and dilated distal ductal system The proximal duct was obstructed so that no medium entered the duodenum

in amylase confirms the connection When distortion or debris has closed off the ducts fluid amylase approaches normal serum levels

Partial ductal obstruction proximal to the cyst elevates secretory pressures in it and promotes growth as pointed out by Doubilet and Mulholland They have advocated the combination of sphincterotomy with operative drainage for pseudocysts, particularly for those near the head of the gland Sometimes a catheter may be threaded through the sphincter directly into the cyst cavity, providing

by operation, though this is rarely necessary The fibrous tract is followed down to its pancreatic origin If only a small portion of distal pancreas drains into the fistula, this may be resected together with the tract When inflammation prevents resection, or the proximal pancreatic ducts are obstructed, the fistulous tract should be transected close to the pancreas and anastomosed to adjacent stomach or jejunum

### *Other Pancreatic Cystic Masses*

Certain other much less common cysts must be differentiated at operation from chronic pseudocysts

DEVELOPMENTAL OR TRUE CYSTS These are rare and can be recognized from their thin membranous walls, true epithelial lining, and the lack of adjacent inflammation The cavity may be multilocular and completely isolated, or it may communicate in portions with the ductal system, and contain enzyme-rich secretions This latter finding has led to the term "retention cysts ' These probably represent embryologic faults in development They are usually solitary, except in the syndrome of congenital cystic fibrosis of childhood However, they can be accompanied by simple cysts in other organs, notably the kidneys Dermoid inclusion cysts are also occasionally encountered in the pancreas, and resemble those found elsewhere

Complete enucleation or local excision is the treatment of choice In the absence of inflammation, this can be relatively easy For the true cysts, drainage is less satisfactory The cavity persists, because of the communication with the ductal system and the intact epithelial lining Destruction of the epithelium with various chemicals has been tried without much success

Secondary infection can occur, erode the endothelial lining, and produce thickened, inflamed walls with marked adhesions A true cyst is then grossly indistinguishable from a pseudocyst, and its treatment is much the same

NEOPLASTIC CYSTS Cystadenomas fortunately are very rare, only 57 cases could be compiled from the literature by Zintel in 1954 They are truly proliferative and locally invasive They can be recognized from their thick smooth capsules and very gelatinous contents The adjacent pancreas may appear normal, except for obstructed portions distal to the tumor Multilocularity is the rule the contents may resemble a bunch of grapes

Malignant cystadenomas occur, but benign tumors outnumber them by at least two to one Papillary projections into the cavity suggest malignancy but do not necessarily indicate this For some unknown reason, these tumors occur in women by a ratio of six or seven to one Resection is the only satisfactory treatment

PARASITIC CYSTS Echinococci can incite an inflammatory and proliferative pancreatic cyst resembling the pseudo cysts of chronic pancreatitis Persistent eosinophilia should provide a clue to this preoperatively, and the diagnosis can be confirmed by serologic agglutination tests Upon opening the abdomen, the true situation can be surmised from the appearance of other cysts in the liver The pancreas is almost never involved alone Sometimes the scolices can be seen through the cyst walls

Proper treatment is surgical but great caution must be observed to avoid spilling the contents Following closed aspiration, the cyst cavity should be filled with absolute alcohol or 2 per cent Formalin for five minutes It is then safe to open the cyst and strip out the endocystic lining membrane The fibrous outer walls will collapse Permanent obliteration can be expected from this treatment

## TUMORS OF THE PANCREAS

### Carcinoma

Carcinoma of the pancreas is second only to common duct stone as a cause of obstructive jaundice and accounts for 2 per cent of all cancers Almost all are adenocarcinoma and are ductal in origin

tion averages over twice that from simple biliary bypass procedures

Prognostic factors have recently been emphasized in relation to jaundiced patients that are important in patients suspected of having carcinomas Jaundice increases surgical risk as evidenced by lowered blood volume and a poor tolerance to operative and postoperative hypotension Blood volume deficits are closely related to weight loss and usually approach a deficit of 100 cc per pound of weight lost in the severely jaundiced, malnourished patient Unless this deficit is replaced, comparatively minimal blood loss during surgery or even anesthesia alone may lead to hypotension, which is frequently followed by renal failure and uremia

Other prognostic factors include laboratory evidence of liver damage and a tendency to postoperative hemorrhage A prothrombin value of less than 50 per cent after vitamin K therapy, cholesterol esters of less than 30 per cent, and a lowered total protein with reversal of the albumin/globulin ratio signify a poor tolerance to major surgery These changes usually occur with prolonged biliary obstruction but may result from repeated episodes of cholangitis The evidence of poor liver function should be weighed against operability Radical surgery primarily for palliation is probably not justified when the signs of poor prognosis exist Postoperative hemorrhage from the gastrointestinal tract occurs from either failure to maintain adequate prothrombin levels uremic changes following hypotensive episodes, or increased fibrinolytic activity following pancreatic surgery

### *Preoperative Preparation*

Preoperative preparation must include attention to details of nutrition, blood volume replacement, vitamin K therapy and correction of existing pulmonary and renal disease Intravenous feedings except to correct fluid and electrolyte deficits, are inadequate nutritionally While diagnostic studies are being completed, a high protein and caloric diet can usually be taken orally, if supplemented with pancreatin and bile salts its utilization will be greatly improved An average of three whole blood transfusions will be required to replace chronic blood volume deficits This requirement cannot be evaluated without blood volume determinations Vitamin K should be given both before and after surgery, since inadequate intestinal bile prevents absorption preoperatively and the frequently used antibiotics prevent intestinal production following surgery Cessation of smoking and aerosol inhalations to clear the tracheobronchial tree aid in preventing postoperative pulmonary complications Satisfactory renal function must be assured before major pancreatic resection is undertaken Since renal failure following hypotensive episodes has been a common postoperative complication, kidney function is of great importance in the jaundiced patient

### *Technique*

Pancreatic surgery is usually performed through a right paramedian incision extending from high in the xiphocostal angle to below the umbilicus Several preliminary steps in addition to an initial abdominal exploration are necessary to determine operability If the tumor arises in the body or tail of the pancreas, the lesser sac is entered by reflecting the omentum from its attachment to the transverse colon For lesions in the head of the pancreas the duodenum is freed laterally by incising the posterolateral peritoneal reflection from the common bile duct to just proximal to the ligament of Treitz Resectability is determined by the presence or absence of distant metastasis and size of the tumor (Fig 14-16) Extensive infiltration of surrounding tissues or the superior mesenteric artery and vein and widespread node involvement preclude all but decompression of the biliary tract except in rare cases when radical surgery may be carried out in a good risk patient.

A tissue biopsy should be obtained to avoid subsequent confusion as to the diag-

nosis This should be taken preferably from an involved node but direct biopsy of the tumor is preferable to an unconfirmed diagnosis Needle biopsy has been advocated by some surgeons, however, these biopsies are often difficult to interpret pathologically

At least four possible situations may be encountered The tumor may be so ex-

comparable palliative results The easiest procedure should be performed. When the tumor is large or encroaches on the duodenum, a gastroenterostomy should be performed also. If subsequent tumor resection is anticipated a long loop of jejunum that can be displaced later from the operative field should be anastomosed to the gallbladder

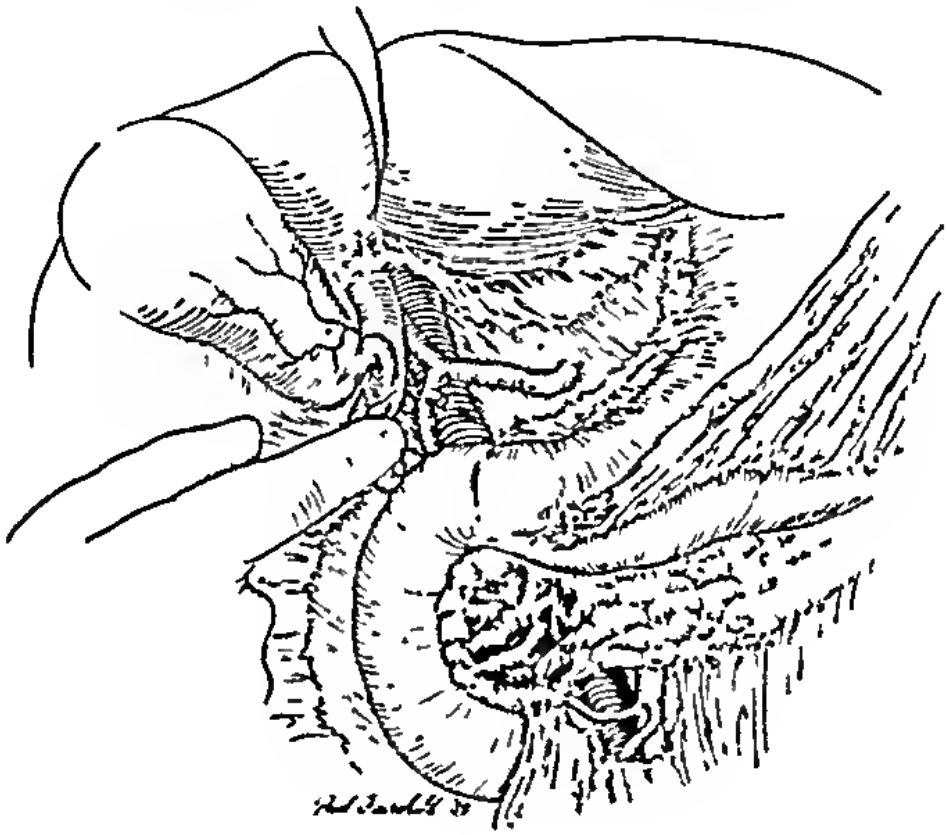

From this approach to the inferior border of the pancreas, invasion of the superior mesenteric artery can be determined prior to ligation of any major vessels or division of the bile duct

With operability established the lateral incision is continued superiorly and medially close to the liver ligating the gastroduodenal and right gastric arteries close to their origins The hepatic artery is displaced superiorly The stomach is then transected near its mid portion The common hepatic duct may also be transected at this point just below its origin This usually requires removal of the gall bladder in order to excise enough of the common duct.

Ligation of the pyloric vein, the only large vein draining the superior border of the head of the pancreas allows further blunt dissection beneath the pancreas peeling it from the superior mesenteric vein (Fig 14 17) while encountering only a few very small veins until the pancreas is lifted downward exposing the inferior pancreaticoduodenal vein and artery at its inferior border The pancreas is then lifted off the superior mesenteric artery with care to prevent injury to the middle colic artery Generally the pancreas is transected just medial to the superior mesenteric artery unless a more extensive pancreatectomy is necessary

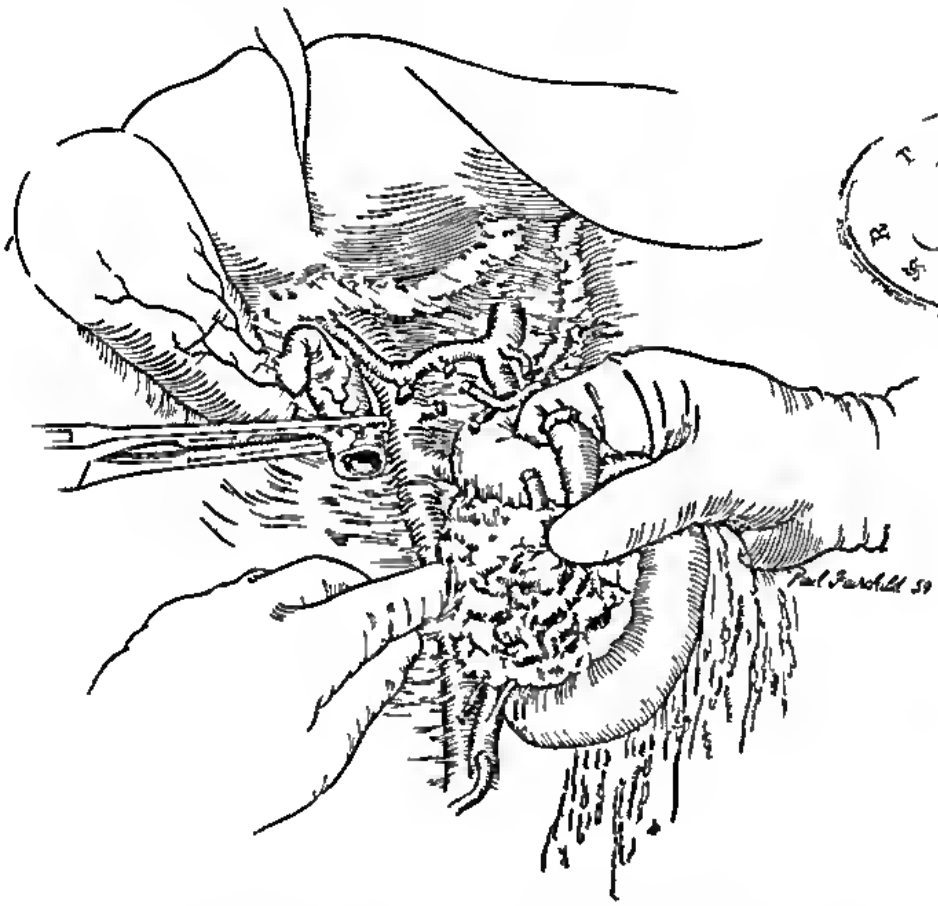

MEDICAL LIBRARY UDAIPUR

Fig 14 17 Separation of the pancreas from the underlying superior mesenteric vein can generally proceed by blunt dissection after the portal vein has been clearly identified at the superior pancreatic border

An alternate procedure is to transect the body of the pancreas in its mid portion and dissect laterally ligating the superior and inferior pancreaticoduodenal arteries and veins as they are encountered

Anastomosis of the pancreas and bile duct to jejunum should be performed

output may offer the only hope for survival in the immediate postoperative period The use of a gastrostomy or jejunostomy to facilitate intestinal decompression will aid in decreasing pulmonary complications as well as suture line leakage, since a nasogastric tube will not be required

## Tumors of the Ampulla of Vater

The foregoing discussion of carcinoma of the pancreas pertains in large measure to tumors of the ampulla of Vater and lower end of the common bile duct The latter lesions differ in several diagnostic aspects Painless jaundice is commoner and when pain occurs it is of relatively shorter duration Chills fever, and vomiting occur in nearly half of the patients with ampullary tumors while these symptoms are uncommon with pancreatic carcinoma A positive test for blood (guaiac) in the stool or duodenal aspirate strongly suggests an ampullary lesion

The prognosis of ampullary carcinoma also differs from that of pancreatic cancer Despite frequent invasion of the lower portion of the common bile duct, half of these ampullary lesions are resectable Less than a third of pancreatic carcinomas are so limited at the time of surgery Consequently the five year survival for ampullary carcinoma has been reported between 28 and 39 per cent The relatively poor prognosis with pancreatic carcinoma has led some surgeons to limit the Whipple operation to lesions of the lower bile duct and ampulla Since it is often difficult to delineate pancreatic from ampullary carcinoma even at the time of surgery, resection is recommended for all localized lesions

## Islet Cell Tumors

Until recently attention had been given only to the beta cells of the pancreatic islets The relationship between islet cell tumor and hyperinsulinism was established in 1927 Subsequently the alpha cell has been found to secrete glucogen, an antagonist of insulin The so called beta and gamma cells may be precursors of alpha or beta cells or separate cells having as yet unknown function Recent reports have confirmed a relationship between nonbeta cell islet tumors and a syndrome of ulcer diathesis associated with a marked increase in gastric secretion In addition, the association of both forms of islet cell tumor in the same patient as well as multiple tumors of other endocrine organs requires surgical consideration

### *Islet Cell Tumor and Hyperinsulinism*

DIAGNOSIS The diagnosis of hyperinsulinism requires a consideration of all causes of spontaneous hypoglycemia Several organic and functional causes may be encountered The signs and symptoms of hypoglycemia are similar regardless of the cause The time of onset relief by food or other medication, and relation to other diseases differ Generally the symptoms vary from mild pallor, flushing, dizziness, or sweating to definite personality changes, convulsions and coma

Functional hypoglycemia occurs more often in patients with psychosomatic disorders A similar form, alimentary hypoglycemia is more familiar to surgeons This is essentially a relative hyperinsulinism and occurs following gastric resection or gastroenterostomy Hypoglycemia occurs not in the fasting state but three to four hours after a meal An excessive insulin response occurs with the rapid absorption of high carbohydrate foods and an abnormal glucose tolerance curve is seen with marked lowering of the blood sugar three to four hours after a glucose meal In most cases symptoms decrease with time or can be greatly ameliorated by a high protein and fat and a low carbohydrate diet

Organic hypoglycemia may be due to hypopituitarism, hypoadrenalism, or an islet (beta) cell tumor of the pancreas Hypopituitarism and hypoadrenalism rarely present a diagnostic problem since other stigmata of these diseases are usually noted Incomplete recovery of symptoms with the administration of glucose

creas total pancreatectomy may be necessary for relief of symptoms in the rare case This probably serves little purpose if the tumor is malignant and metastases have already occurred Finally, if after local excision of a tumor in the head of the pancreas or excision of the tissue This, however, is usually found most commonly in young children Fourth, one should again re evaluate the various causes of hypoglycemia to be assured that the diagnosis has not been missed Re exploration is reindicated if Whipple's triad remains positive

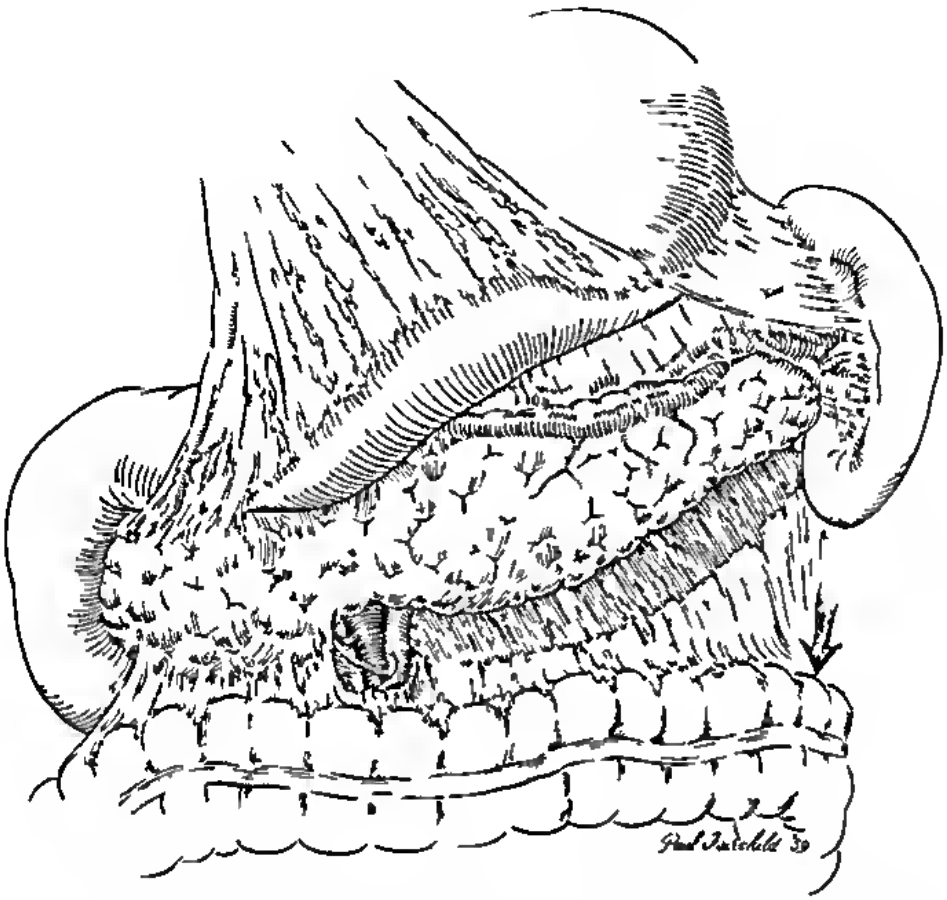

Fig 14 19 In the search for a functioning islet adenoma the body and the tail of the pancreas can be palpated bidigitally before dividing any important structure The arrow points to the incision in peritoneum along the inferior pancreatic margin where fingers can be introduced by blunt dissection The pancreas and splenic vessels are elevated together for palpation of their posterior surface

body and tail of the pancreas tumor recurs at a later date several factors must be considered First, an adenoma may have been overlooked that is either primary in another portion of the pancreas or aberrant in the stomach or intestinal tract. Second, the tumor may have been malignant and functioning metastases are present Third, the tumor may have been overlooked and in a rare case there may be functioning hyperplasia of the islet

## Islet Cell Tumor and Peptic Ulcer

Peptic ulceration that is intractable to all known therapy can be produced by an adenoma arising in the pancreatic islets This adenoma is distinctly different from the insulin producing pancreatic tumors It is composed of alpha cells, or nonbeta cells, and resembles the islet adenomas formerly called 'nonfunctioning Rarely does it produce excess insulin

hyperplasia or adenomatous changes are found in a majority of the islets, the process is probably diffuse throughout the pancreas Such a finding also suggests multiglandular disease, in which the pituitary, parathyroids, or adrenals also contain adenomas, or are functioning abnormally

If there is strong clinical evidence of an ulcerogenic tumor, yet none can be found by careful exploration, a section of the distal pancreas probably should be removed for histologic study The chances are good that this tissue will contain a tumor if it is present This tissue may also show diffuse hyperplasia in the islets, preponderantly in the alpha cells Recent isolated cases suggest that such hyperplasia may be as effective as an adenoma in producing this syndrome

Two thirds of the ulcerogenic adenomas have had the microscopic appearance of malignancy In about one third of the cases metastases have been found when the tumor was first discovered These are usually in the liver About half of the metastases function In the remainder, the ulcer diathesis regresses after resection of the primary tumor At present, there are no characteristics by which functioning tumor tissue can be distinguished from nonfunctioning The growth and spread of metastases appear to be slow Therefore, resection of the primary tumor appears indicated, even in the presence of early metastases

In some cases, resection of an ulcerogenic adenoma has been followed by remission of the profound ulcer diathesis In others it has not, presumably owing to functioning tumor or metastases left behind This is extremely difficult to avoid, in view of the multiple primary adenomas found, their small size, the chances of diffuse islet disease, the high rate of malignancy, and of tiny occult functioning metastases There is no way to know whether all functioning tumor has been removed until gastric acidity is measured in the postoperative period

All these factors suggest that when the diagnosis of ulcerogenic adenoma of the pancreatic islets has been clearly established, a total gastrectomy should be performed The primary tumor should also be resected whenever this is possible

The first living patient reported with this syndrome had a malignant alpha cell adenoma with one metastasis These were removed and a total gastrectomy carried out Four and one half years later she is living and well Generally, these patients have done surprisingly well

When a functioning ulcerogenic adenoma can be resected, it should be quickly frozen for future extraction Its tissue should be made available for every histochemical technique that might identify the active agent In all likelihood these tumors spring from pancreatic islet tissue, which secretes the same agent in normal amounts If so, the nature of this substance is unknown Its identification might yield new knowledge concerning the role of the pancreas in gastric function This would benefit not only the rare patient with an ulcerogenic tumor, but the many with benign peptic ulcer as well

## REFERENCES


Berens J J, Baggenstoss, A H and Gray, H K Ductal changes in chronic pancreatitis *A M A Arch Surg 68* 723, 1954

Bowers, R F Choledochojejunostomy Its ability to control chronic recurring pancreatitis *Ann Surg 142* 682, 1955

Cannon, J A Experience with ligation of pancreatic ducts in treatment of chronic relapsing pancreatitis *Am J Surg 90* 266, 1955

Coffey, R C Pancreato enterostomy and pancreatectomy A preliminary report *Ann Surg 50* 1238, 1909

Cope, O, Culver, P J Mixter, Charles G, Jr., and Nardi, G L Pancreatitis, a diagnostic clue to hyperparathyroidism *Ann Surg 145* 857, 1957

Doubilet, H, and Mulholland, J H Pancreatic cysts Principles of treatment *Surg Gynec & Obst 96* 683, 1953

Doubilet, H, Poppel, M H, and Mulholland, J H Pancreatography indications and observations *J.A.M.A 163* 1027, 1957

CHAPTER 15

# SURGERY OF THE SPLEEN

*M. S. DeWeese and Frederick A Coller*

The spleen presents a unique challenge to the surgeon Total removal is the only operation of importance to which it is primarily subjected, although it may be involved by or related to many diseases Its physiologic functions, though very real, are not well understood by either surgeons or hematologists Its extirpation is only moderately difficult by present technical methods, and the postoperative management presents few serious problems But except for the universally recognized need for immediate operation in cases of traumatic or spontaneous rupture of the spleen, precise knowledge of the absolute indications for splenectomy and of the therapeutic benefits to be derived from the operation in various diseases has evolved slowly

Most of the knowledge of the role of splenectomy in the treatment of hematologic disorders has resulted from clinical investigation through the coordinated efforts of surgeons and hematologists Much has come of necessity through trial and error Such accumulated clinical experience has demonstrated that some diseases formerly treated by splenectomy, such as pernicious anemia and Banti's syndrome, are not benefited by the operation Conversely, other diseases, such as primary splenic neutropenic and panhematopenia, have been discovered that do benefit dramatically from removal of the spleen

## ANATOMIC STRUCTURE

The normal spleen is a friable, vascular, ovoid organ in the left upper quadrant of the abdomen It is approximately 12 × 7 cm in size in the normal adult male but may be enormously enlarged in some diseases It lies in close apposition to the inferior concave surface of the left hemidiaphragm, where it is completely protected by the lower three ribs Its long axis parallels the course of the tenth rib The organ is bounded anteromedially by the stomach, posteromedially by the tail of the pancreas posteriorly by the left kidney, superiorly by the diaphragm, and inferiorly by the colon

The splenic artery and vein course along the upper border of the pancreas and enter the spleen at its hilum on the gastric or medial surface The splenic artery originates as the largest branch of the coeliac axis It gives off small pancreatic branches in its central portion, a large pancreatica magna artery at the junction of the middle and distal thirds of the pancreas, short gastric branches and caudal pancreatic arteries distal to this The left gastroepiploic artery arises still more distally As the main splenic artery approaches the hilum of the spleen within the lienorenal ligament, it breaks up into multiple small branches that enter the spleen without communicating one

This ligament supports the spleen inferiorly and may or may not have direct attachments to the spleen

Microscopically, the capsule and trabeculae of the spleen contain smooth muscle fibers that are contractile and permit the storage or rapid release of a volume of blood disproportionately large as compared to the size of the organ The splenic pulp is composed of sinuses or pulp spaces, and various cellular elements such as erythrocytes, monocytes, and macrophages Its arterioles are surrounded by lymphatic nodules There has been considerable controversy as to whether the splenic circulation is "open" or "closed" The "open" view (Mackenzie, Whipple, and Wintersteiner) holds that open splenic pulp spaces—tortuous channels lined by reticulum, and fixed and wandering cells—provide the one and only link between the arterial and venous systems in the mammalian spleen The "closed" view (Knisely) contends that blood courses through the spleen in preformed vascular channels consisting of arterioles, venous sinuses, and veins, and that there are contractile sphincters at both the entrance and exit of the sinuses Current studies suggest that both open and closed circulatory mechanisms may coexist in the spleen In any event, the organ acts much as a sponge that can store a large volume of blood or rapidly discharge it into the general circulation Its unique vascular architecture also permits the radiologic visualization of the portal venous system Radiographic contrast media injected percutaneously into the splenic parenchyma may be observed to pass rapidly into the splenic vein, thence into the portal vein and its hepatic ramifications (Fig 15-1, *Left*)

## PHYSIOLOGIC FUNCTION

It is generally believed that the spleen is an "expendable" organ and that its removal is not followed by serious physiologic derangements This does not presuppose, however, that the spleen is a supernumerary organ without physiologic activity Knowledge of its functions has accumulated slowly and, as previously noted, is based primarily on clinical investigation, since the spleen does not lend itself easily to objective experimental study Neither does it produce specific hormonal or metabolic products that can be readily assayed

The known functions of the spleen may be summarized (Hayhoe and Whitby) as follows (1) It provides a reservoir for erythrocytes and a potential mechanism, particularly in abnormal conditions, for the destruction of red cells (2) It has a hemopoietic function that is particularly important in embryonic life, and in some diseases of later life (3) It has definite phagocytic and reticuloendothelial activity and is capable of phagocytizing dead cells, parasites, and particulate matter (4) It exerts a hormonal influence that regulates the maturation and release of the cellular elements of the blood from the bone marrow (5) It is an important site of antibody production and may contribute to the immunoallergic mechanisms that are important in the pathogenesis of some hematologic disorders As these functions are closely related to those of other systems, especially the hemopoietic and reticuloendothelial systems, it is difficult to assess the precise contribution that the spleen makes to each

## PATHOLOGIC PHYSIOLOGY HYPERSPLENISM"

Functional abnormalities of the spleen are not associated with characteristic morphologic changes that can be observed microscopically Although the organ may be markedly enlarged in some hematologic diseases, in others it may be normal in size Congestion and nonspecific hyperplasia are the only consistently recognizable histologic changes Some order has arisen from the confusion that formerly existed concerning the relationship of the spleen to associated hematologic disorders since the introduction and general recognition of the concept of hypersplenism (Fig 15-2)

The term hypersplenism was used in 1929 by F Parkes Weber, who predicted that

They might just as properly be discussed with the hematologic disorders as they become important only when they become functionally hyperactive and perpetuate hypersplenism following removal of the spleen itself

Accessory spleens are represented as small masses of splenic tissue that resemble the spleen in color and consisteney Their gross appearance is typical al along the tail of the pancreas Less frequently they may occur in the greater omentum the mesentery of the colon or small bowel or in the phrenicocolic ligament They have also been reported in the body of the pancreas the left adnexa in the female or the left scrotum in the male They are seldom observed in more than two of these locations in an individual patient Even when multiple they

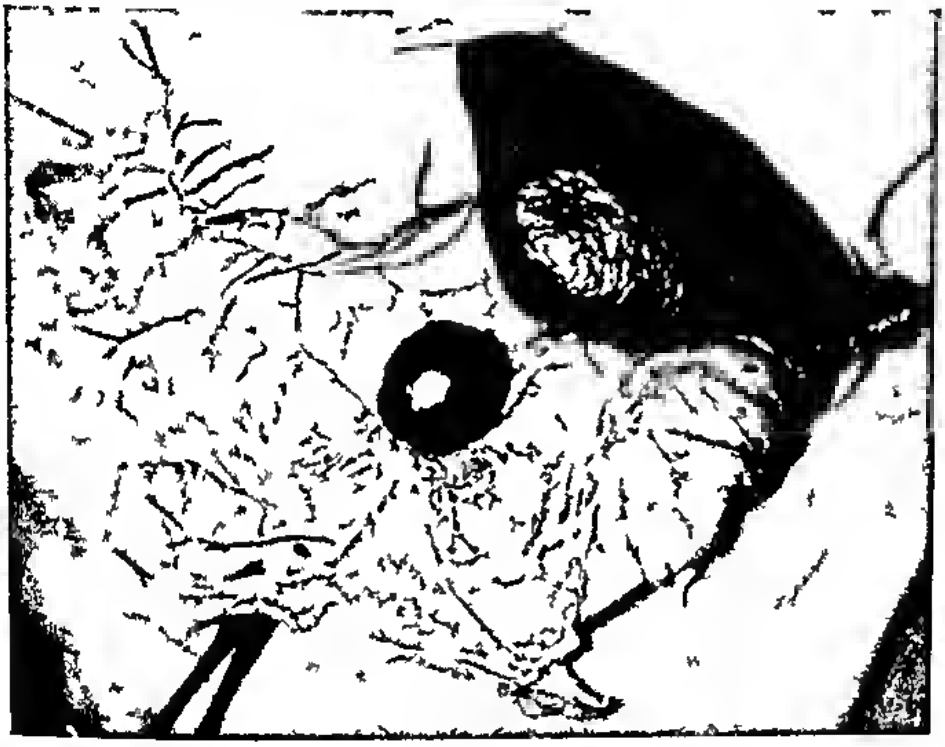

F g 15 3 Accessory spleen in gastro col c l gament

though they may be confused with lymph nodes or hemolymph glands during operation They vary in diameter from a few millimeters to several centimeters and may be single or multiple They are observed more frequently in children than in adults As many as ten have been reported in a single patient They have been discovered in 15 per cent of the patients who l ave undergone splenectomy for hematologic disorders in our own hospital Others have reported a rate as high as 31 4 per cent

Accessory spleens may be found widely dispersed throughout the peritoneal cavity They are most commonly found in the splenic hilum the lienorenal ligament or are most usually found grouped together in a single location

It is extremely important to search for and remove those accessory spleens that may be present particularly when splenectomy is performed for idiopathic thrombocytopenic purpura or congen tal hemolytic anemia If they are overlooked reoperation may be necessary because of continuing hypersplenism Their presence and position may sometimes be identified radiolog cally after tl e injection of Thorotrast a radiopaque contrast medium that is concentrated in the reticuloendothelial cells of the accessory splenic tissue

ECTOPIC (WANDERING) SPLEEN The

Fig 15 4 Splenic cysts (*Top*) Hydat d (ecchinococcus) cyst (*Bottom*) Hemorrhagic cyst

occurs in approximately 0 038 per cent of autopsies and report that the diagnosis was made preoperatively in only 14 of 198 cases reported prior to 1953 Concomitant with a generally increased aggressiveness in the diagnosis and treatment of vascular lesions during recent years aneurysms of the splenic artery have been recognized with increasing frequency

Splenic artery aneurysms are usually arteriosclerotic congenital or traumatic in origin They may also be related to arterial embolism or syphilis They occur twice as frequently in females as they do in males whereas aneurysms of most other arteries are more common in males Many have appeared following pregnancy They may be single or multiple

The diagnosis may be suspected on the basis of pain in the upper abdomen splenomegaly and a palpable pulsatile tumor or bruit over the spleen Gastrointestinal bleeding has been an early manifestation in some cases evidences of portal hypertension have been observed in 20 per cent. The incidental discovery of a calcified oval density in the left upper quadrant during abdominal radiologic examination may lead to the diagnosis initially (Fig 15 5 *Left*) A pulsatile filling defect of the posterior gastric wall has occasionally been observed fluoroscopically Aneurysms can be clearly visualized by translumbar aortography if the diagnosis remains in doubt after other diagnostic measures have been exhausted (Fig 15 5 *Right*)

Operation should be advised once the

are associated with painful perisplenitis Many small central abscesses doubtless heal spontaneously, whereas others remain dormant, becoming apparent only after a latent period of many months Splenic abscesses are usually found in association with abscesses of other organs

The diagnosis of splenic abscess should be suspected on the basis of the simultaneous occurrence of splenomegaly and sepsis X-ray examination may reveal evidence of a space filling lesion in the left upper quadrant, or limitation of motion of the left hemidiaphragm Needle aspiration of the spleen may support the preoperative diagnosis, but is better deferred until laparotomy, when it will aid in localizing the abscess Preoperative percutaneous aspiration may lead to septic complications

Removal of the spleen should be accomplished if it is technically possible Incision and drainage of the abscess preferably through a counterincision posteriorly, is indicated if there are dense perisplenic adhesions or if the patient is too ill to withstand splenectomy

Antibiotic therapy has markedly reduced the incidence and mortality of splenic abscess Previously the mortality rate in surgically treated patients was 25 per cent, and much higher in untreated patients

### *Rupture of the Spleen*

Splenic rupture is the most frequent indication for splenectomy in most hospitals Massive intraperitoneal hemorrhage may occur immediately after injury or it may be delayed for a variable period of time In so-called delayed rupture parenchymal hemorrhage is confined initially within the splenic capsule or perisplenic tissues and becomes manifest only after an interval of 48 hours or more This interval is known as the 'latent period of Baudet.' Although delayed hemorrhage usually occurs within two weeks after injury, the latent period may be of many months duration in some patients

Splenic rupture is most usually caused by blunt abdominal trauma Automobile accidents produce the greatest number of these lesions in civilian life Concurrent injuries of other organs are frequently produced and these may obscure the early diagnosis of splenic injury Fractures of the left lower ribs or transverse vertebral processes, contusions of the left kidney or pancreas, and rupture of the diaphragm are frequently seen concomitantly The spleen is injured by blunt trauma more often than are the other intra abdominal organs, being lacerated almost twice as frequently as the liver Penetrating abdominal wounds produce splenic injury less commonly, particularly in civilian life, but they are even more prone to cause concomitant injury of the other intra abdominal organs

Spontaneous rupture of the spleen may occur after minimal trauma in patients with pre existent splenomegaly owing to such diseases as malaria or infectious mononucleosis Although spontaneous rupture of the normal spleen has been reported occasionally, this is exceedingly rare and most such incidents probably represent delayed hemorrhage from a spleen that has previously been traumatized Lacerations of the spleen may occur inadvertently during the course of other surgical procedures such as gastrectomy or left colectomy It is usually wise to remove the spleen under such circumstances, as attempts to obtain splenic hemostasis by more conservative measures are unreliable

The clinical evidences of rupture of the spleen are frequently obscure and the diagnosis may be overlooked unless the entity is kept constantly in mind Shock resulting from intra-abdominal bleeding may be the only indication of the severity of injury Abdominal pain, usually localized to the left upper quadrant, is a common but inconstant symptom. Pain in the left shoulder as a result of diaphragmatic irritation (Kehr's sign) is found in about half the patients The abdomen is usually distended, but the signs of peritoneal irritation may be minimal and therefore misleading A "doughy" resistance to abdominal palpation is more characteristic than overt rigidity Shifting dullness

disease, secondary hypersplenism, although usually present, may be absent Splenectomy characteristically produces dramatic improvement in this disease, but it is seldom indicated in the other two metabolic disorders

TUMORS BENIGN AND MALIGNANT Benign tumors of the spleen are exceedingly rare Although fibromas, leiomyomas, and hemangiomas have been reported as arising in the spleen, only the cavernous hemangiomas are of surgical importance The latter lesion may produce a bruit over the splenic area that leads the clinician to its ante mortem detection Splenectomy is advisable if these lesions are discovered, as malignant degeneration of the tumor may occur

Primary malignant tumors of the spleen are as rare as benign tumors Fibrosarcomas are encountered most frequently but they usually are far advanced at the time of recognition Although splenectomy should be attempted if the lesion is operable, the operation seldom results in control of the neoplasm The spleen may be involved along with other organs in generalized neoplastic diseases of the lymphoid and reticuloendothelial systems Splenectomy is contraindicated in the absence of secondary hypersplenism as it has no beneficial effect on the generalized disease

## Hematologic Disorders

Splenectomy is frequently indicated for hematologic disorders that are related to splenic hyperactivity Classification of these diseases is somewhat arbitrary, but it is helpful to consider them as related to primary or secondary disturbance of the spleen, i e "primary' and 'secondary' hypersplenism There are still other disorders that defy accurate classification in either of these categories but display hematologic evidences of abnormal splenic function We have grouped these in a separate category, which we call "unclassified hypersplenism

Precise diagnosis of these diseases is difficult and is possible only after careful hematologic study, which requires special knowledge and skills For this reason, splenectomy should be advised only after consultation with a physician who has a broad knowledge of these diseases, otherwise many operations will prove fruitless, and the mortality rate will be needlessly high

Enlightened preoperative examination of the bone marrow and of the peripheral blood is mandatory, and must be correlated with the clinical findings in arriving at an accurate diagnosis The diagnosis of hypersplenism is tenable only if hyperplasia of the bone marrow occurs in the cellular components that are deficient in the peripheral blood Other laboratory examinations such as the Coombs test, which aids in differentiating congenital and acquired hemolytic anemia are equally as important Cytologic examination of the splenic pulp obtained by percutaneous needle aspiration is particularly helpful in the diagnosis of neoplasms or of agnogenic myeloid metaplasia, a disorder that strongly contraindicates splenectomy Percutaneous splenoportography is valuable in establishing preoperatively the site of portal obstruction in patients with congestive splenomegaly (see Fig 15 1, *Right*)

### *Primary Hypersplenism*

IDIOPATHIC THROMBOCYTOPENIC PURPURA This is a disease characterized clinically by a tendency to hemorrhagic episodes of varying severity, absence of splenomegaly, a significant reduction of platelets in the peripheral blood, and increased megakaryocytosis with deficient platelet budding in the bone marrow The tourniquet test is positive for increased capillary fragility Bleeding time is prolonged clotting time is normal but clot retraction is deficient In the acute form, which is more common in children than in adults, the disease has a fulminating course, but spontaneous remissions occur frequently A chronic form, which is less prone to undergo spontaneous remission, is more frequent in adults. Idiopathic thrombocytopenic purpura is the most

rent infection, splenomegaly, decreased granulocytes in the peripheral blood, and myeloid hyperplasia of the bone marrow It was first described by Wiseman and Doan in 1939, after a deliberate and successful search for a disorder in which granulopenia could be demonstrated to be specifically related to splenic hyperactivity Splenectomy is curative

PRIMARY SPLENIC PANHEMATOPENIA In this uncommon disorder, first described by Doan in 1945, splenic hyperactivity induces a simultaneous reduction in all three of the cellular elements of the peripheral blood The disease is characterized by splenomegaly and a tendency to develop anemia, recurring infections, and spontaneous hemorrhages The bone marrow reveals hyperplasia of the three cellular elements Again splenectomy is curative

### *Secondary Hypersplenism*

CONGESTIVE SPLENOMEGALY Congestive splenomegaly is a manifestation of portal hypertension and is caused by intrahepatic or extrahepatic obstruction of the portal vein It is characterized by splenomegaly accompanied by esophageal varices and distention of other collateral venous channels that link the portal and systemic system Although splenectomy was at one time considered to be the operation of choice in patients with bleeding esophageal varices, the results were generally poor Since Whipple clarified the pathogenesis of portal hypertension by his classical fundamental studies of the pathologic anatomy of the portal venous system splenectomy has been supplanted surgically by the portal systemic venous shunting procedures These provide more rational and effective therapy (see Chap 10) The performance of splenectomy alone is ill advised in these patients, particularly in those with extrahepatic portal obstruction, as it may permanently destroy the opportunity to establish a successful venous shunt

In some patients, congestive splenomegaly induces secondary hypersplenism, which is manifested by characteristic cytopenia and specific bone marrow hyperplasia The surgeon must be aware of this possibility and obtain appropriate hematologic studies before any operation is undertaken Lack of awareness of existent granulopenia or thrombocytopenia may lead to unwarranted septic or hemorrhagic complications following operation If the cytopenia is severe, it is usually wise to remove the spleen as an adjunct to the shunting procedure In our own experience hypersplenism has persisted following the relief of portal hypertension by a direct porto caval shunt and responds only to splenectomy This matter is somewhat controversial at present and must await the accumulation of more data for final clarification The presence of hypersplenism should, however, be considered in the choice of the surgical procedure for a patient with portal hypertension Exact localization of the site of portal obstruction, another important consideration, is aided by the judicious use of percutaneous splenoportography

These patients obviously present a complex surgical problem, and the prognosis depends on many variables At the risk of oversimplification, we can say that splenectomy is successful in controlling hypersplenism secondary to congestive splenomegaly but that it should supplement, not replace venous shunting procedures in the surgical treatment of portal hypertension

HYPERSPLENISM SECONDARY TO OTHER CHRONIC DISEASES Involvement of the spleen by other chronic benign or malignant diseases occasionally results in secondary hypersplenism Generalized neoplasms of the hemopoietic, lymphatic, or reticuloendothelial systems, specific and nonspecific infections, and the lipoid storage disorders are the primary diseases most usually responsible More specifically, secondary hypersplenism has been observed in various types of leukemia, Hodgkin's disease and other lymphomas, reticuloendothelial cell sarcoma, Gaucher's disease, sarcoidosis, and tuberculosis All may produce hemolytic anemia, granulopenia, thrombocytopenia, or panhematopenia. The diagnosis of secondary hypersplenism

commonly related clinical findings It is not clear whether the neutropenia is primarily hypersplenic in origin or whether it represents a secondary splenic response to chronic infection, hence our classification of the disorder in this category

Patients with Felty's syndrome may be helped by steroid therapy but the relief is seldom sustained Splenectomy usually results in prompt control of the neutropenia and of secondary infections, it may also ameliorate the joint symptoms but this is not constant

HYPOPLASTIC ANEMIA WITH HYPERSPLENISM Splenectomy has no value in the treatment of most patients with hypoplastic anemia, which is caused by a primary defect in erythropoiesis rather than by hypersplenism Occasional patients with this disease, however, may develop granulopenia or thrombocytopenia, which is of hypersplenic origin While it does not influence the course of the hypoplastic anemia itself, splenectomy may offer palliation to selected patients with associated cytopenias The results are seldom brilliant but the operation may increase the comfort and lengthen the survival of these patients

## PREOPERATIVE PREPARATION FOR SPLENECTOMY

The preoperative preparation of individuals for splenectomy offers some special problems that must be considered in addition to those general measures which have been discussed in Chapter 1 This is particularly true in hematologic disorders

STEROID PREPARATION The value of steroid therapy in the definitive management of patients with idiopathic thrombocytopenic purpura and with acquired hemolytic anemia has been mentioned It is equally valuable in the preoperative care of patients with these two disorders who have not obtained sustained clinical remissions following the initial course of therapy and in patients with Felty's syndrome. By the judicious use of cortisone and/or ACTH, the severe cytopenias and symptomatic manifestations of these diseases can usually be controlled and the patients brought to operation in optimal condition Since the introduction of this therapeutic adjunct in 1949, the mortality rate associated with splenectomy for these disorders has been considerably reduced Some authorities prefer to use these agents only for preoperative and never for definitive therapy

The mode of action of the steroids is not clear They apparently modify the cytoimmunologic function of the spleen and reticuloendothelial system, and decrease capillary fragility to some extent

RESTORATION OF DEPLETED BLOOD VOLUME An occult depletion in circulating blood volume may occur in patients with thrombocytopenic purpura as a result of repeated hemorrhagic episodes Zollinger has demonstrated by careful blood volume determinations that this deficit may be as great as 40 per cent of the total blood volumes Patients with hemolytic anemia may have an alarming deficit in red cell mass as a result of hemolysis although there may be a compensatory increase in plasma volume The importance of replacing the overt blood loss that results from splenic rupture is obvious

It is important to recognize these qualitative and quantitative deficits preoperatively and to correct them if it is possible to do so This may be difficult to accomplish, particularly in patients with hemolytic anemia as the hemolytic tendency may persist despite steroid therapy, and the incidence of transfusion reactions is high Fortunately these patients tolerate operation well if they are managed carefully, and the erythrocyte deficit is more easily corrected postoperatively

Patients who are suffering from an acute hemolytic crisis are particularly difficult to manage and consultation with a skilled hematologist is invaluable during this period If possible the operation should be avoided until the crisis has subsided Steroid therapy, transfusions of carefully matched blood, and other supportive measures are usually effective in helping the patients over this dangerous period The proper selection of the most

especially if the operation is performed for primary hypersplenism It is well to do this before the peritoneal surfaces have become obscured by edema and hematomata incidental to operative trauma At this point in the operation, the following areas should be carefully examined for accessory spleens the greater omentum, transverse mesocolon, small bowel mesentery broad ligament (by palpation only as it cannot be visualized through this incision), and the gastrocolic gastrosplenic, and phrenicocolic ligaments

The gastrosplenic ligament is next incised so as to visualize the lesser omental space and the tail of the pancreas The search for accessory spleens is continued as they may occur in or along the pancreas, or in the lienorenal ligament If accessory spleens are found in any of these locations they should be removed immediately or carefully marked for later removal

The splenic artery is next palpated as it courses above the pancreas The peritoneum overlying the artery is incised and a right angle clamp placed beneath it taking care to avoid the splenic vein which produces troublesome bleeding if traumatized The artery is doubly ligated distal to the pancreatica magna artery (Fig 15 6) This maneuver serves two purposes It reduces the amount of bleeding encountered during the completion of the splenectomy and it also permits the return of the blood contained within the spleen to the general circulation through the still patent splenic vein If the spleen is large, a considerable volume of blood may be salvaged that would otherwise remain sequestered in the spleen and removed from the body with it A third ligature may be placed about the splenic artery at this time and the artery divided or this may be deferred until later in the procedure

The gastrosplenic ligament is next divided upward to the upper pole of the spleen taking care to avoid injury to the stomach The blood vessels within this ligament usually require ligation This line of transection is then carried down to the lower pole of the spleen by dividing the remainder of the gastrosplenic ligament and the adjacent gastrocolic ligament (Fig 15 7) The spleen can now be rotated medially and delivered into the wound The splenic attachments of the phrenicocolic ligament are severed if they are present The posterior leaf of the lienorenal ligament is brought into view as well as the superior phrenicolienal ligament both of which are carefully divided (Fig 15 8) In the absence of perisplenitis or of portal hypertension there are few blood vessels in these ligaments that require ligation The major branches of the splenic veins which course through the splenic hilum are clearly visible at this point They are doubly ligated taking care to avoid injury to the tail of the pancreas The splenic artery is also transected if this was deferred earlier in the procedure Any remaining fibers of the medial leaf of the lienorenal ligament are divided and the spleen is removed (Fig 15 9)

A more thorough search for accessory spleens is now possible These may be present in the splenic pedicle in the other peritoneal attachments of the spleen or overlying the left kidney If gallstones have been detected the surgeon must decide whether it is prudent to extend the incision and perform a cholecystectomy We do not hesitate to do this if the patient is in good condition but one should feel no chagrin in postponing cholecystectomy until a later time if it seems wise Finally as emphasized by Zollinger it is frequently helpful to obtain biopsies of the liver lienopancreatic (retroperitoneal) lymph nodes and mesenteric lymph nodes Inflammatory or neoplastic diseases may occasionally be disclosed that result in the reclassification of the disorder from primary hypersplenism to secondary hypersplenism More importantly for the patient and his family, the ultimate prognosis for life may be greatly altered by such a disclosure

In our opinion surgical drainage of the splenic area should always be instituted following splenectomy There is usually

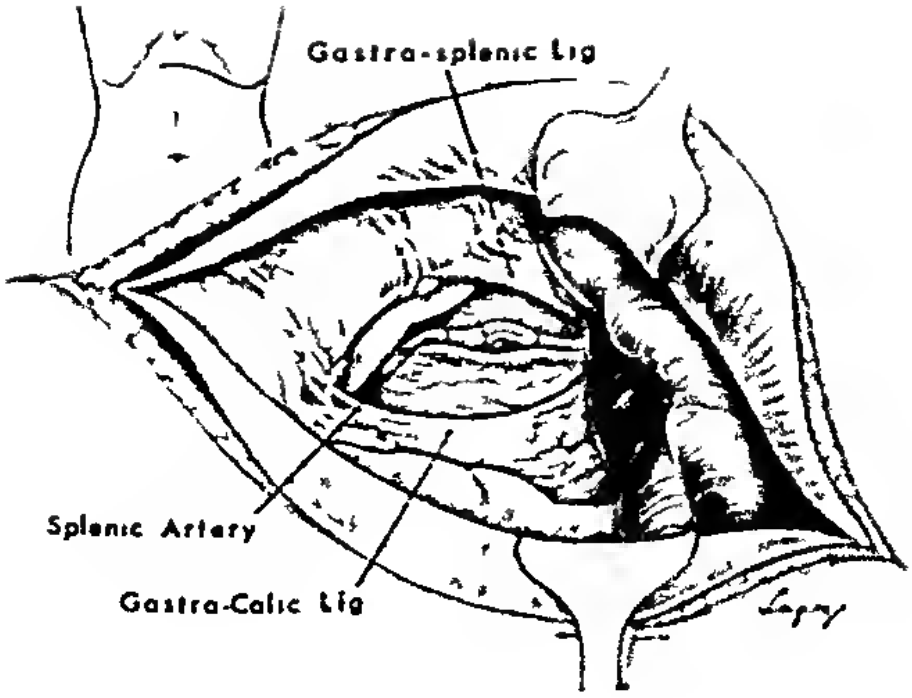


Fig. 15.6. A modified transverse incision is utilized (*inset*). Following abdominal exploration, the gastro-splenic ligament is incised and the splenic artery ligated.

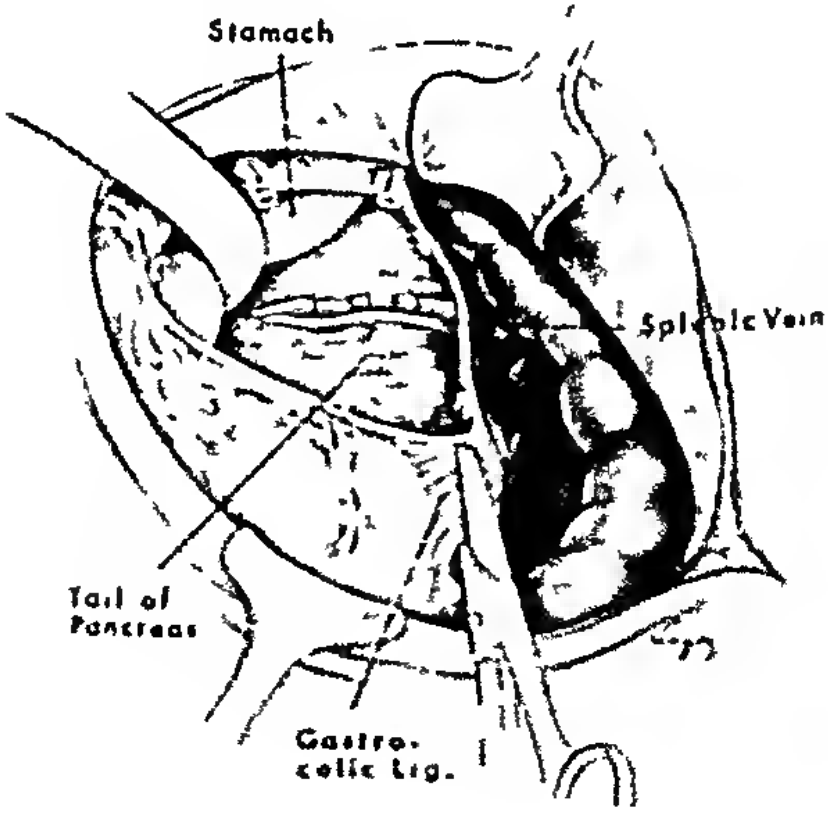

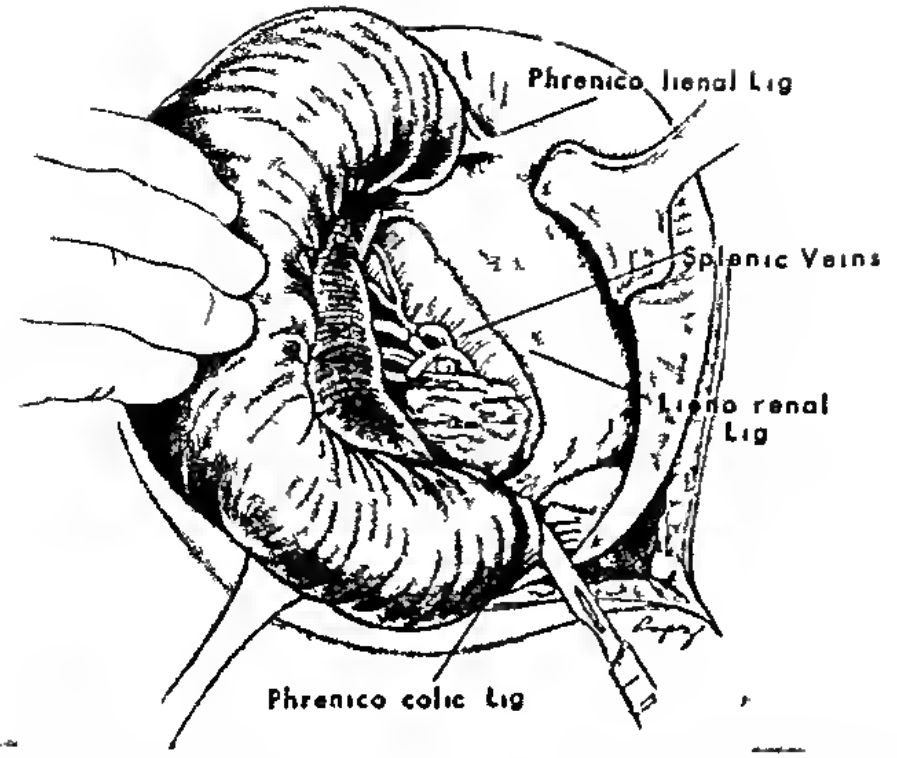


Fig 15 8 The spleen is rotated medially The lateral leaf of the lieno renal ligament the phrenicolienal ligament and the splenic attachments of the phrenicocolic ligament are incised The branches of the splenic vein are doubly ligated and divided

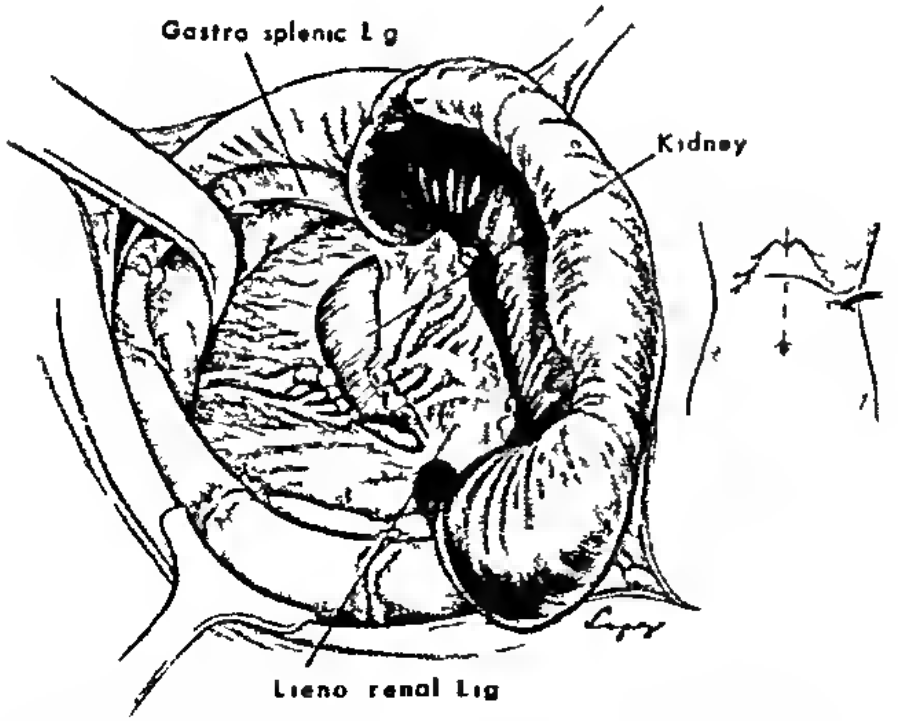


Fig 15 9 The remaining fibers of the lieno renal ligament are divided and the spleen removed. Surgical drainage of the subphrenic space is instituted during closure (*inset*)

bosis of the splenic vein have occasionally been reported following splenectomy This is rare in our experience Anticoagulant therapy is not ordinarily instituted unless the platelet counts exceed one million per cubic milliliter

Subphrenic abscess is a relatively frequent complication of this operation It should be anticipated and proper surgical drainage instituted if an abscess becomes manifest or is strongly suspected Atelectasis of the left lower lobe is a relatively common pulmonary complication that usually responds to early and aggressive enforced coughing, tracheal aspiration, or bronchoscopy

Recent observations have indicated that infants may develop an increased susceptibility to systemic infection following splenectomy This has not influenced us to withhold the operation when it is otherwise indicated It is prudent to observe patients in this age group frequently and to institute prompt treatment if an infectious process does occur Antibiotics should not be used indiscriminately, either in children or in adults They should, however, be used judiciously to combat specific inflammatory complications or to protect patients with neutropenia from infection until a satisfactory leukocytic response is apparent

## RESULTS OF SPLENECTOMY

The results of splenectomy in the various splenic diseases have been alluded to throughout the chapter To supplement this information we present in Table 15-1 our recently reported results in 297 patients treated for nontraumatic splenic lesions in the University of Michigan Hospital from 1934 to 1957

Those disorders which we have listed as

TABLE 15 1 RESULTS OF SPLENECTOMY*
(University of Michigan Hospital 1934–July 1957)

| | *Number patients* | *Good result* | *Fair poor result* | *Death early and delayed* |
|---|---|---|---|---|
| Primary hypersplenism | | Per cent | Per cent | Per cent |
| Idiopathic thrombocytopenic purpura | 86 | 88 4 | 3 5 | 8 1 |
| Congenital hemolytic anemia | 64 | 95 3 | 1 6 | 3 1 |
| Primary splenic neutropenia | 2 | 100 0 | 0 0 | 0 0 |
| Primary splenic panhematopenia | 2 | 50 0 | 0 0 | 50 0 |
| Total | 154 | 90 9 | 2 6 | 6 5 |
| Secondary hypersplenism | | | | |
| Congestive splenomegaly | 43 | 44 2 | 27 9 | 27 9 |
| Gaucher's disease | 4 | 100 0 | 0 0 | 0 0 |
| Sarcoidosis with hypersplenism | 2 | 0 0 | 0 0 | 100 0 |
| Neoplasm | 9 | 33 3 | 44 5 | 22 2 |
| Infection | 2 | 100 0 | 0 0 | 0 0 |
| Total | 60 | 46 6 | 26 7 | 26 7 |
| Unclassified hypersplenism | | | | |
| Idiopathic acquired hemolytic anemia | 46 | 56 5 | 23 9 | 19 6 |
| Felty's syndrome | 16 | 87 5 | 0 0 | 12 5 |
| Hypoplastic anemia | 6 | 16 7 | 16 7 | 66 6 |
| Total | 68 | 60 3 | 17 6 | 22 1 |
| Splenic lesions without hypersplenism | | | | |
| Splenomegaly, idiopathic | 3 | 100 0 | 0 0 | 0 0 |
| Cyst | 3 | 100 0 | 0 0 | 0 0 |
| Sarcoidosis without hypersplenism | 2 | 0 0 | 0 0 | 100 0 |
| Miscellaneous | 7 | 0 0 | 14 3 | 85 7 |
| Total | 15 | 40 0 | 6 7 | 53 3 |
| Total all indications | 297 | 72 4 | 11 1 | 16 5 |

* Reprinted from DeWeese, M S. and Coller F A. Splenectomy for hematologic disorders. *Western Journal of Surgery Obstetrics and Gynecology* 67 129 1959

PUGH, H L. Splenectomy, with special reference to its historical background *Internat Abs Surg 83* 209, 1946

REID, S E, and LANG, S J Abscess of the spleen *Am J Surg 88* 912, 1954

ROUSSELOT, L. M, and STEIN, C Malignant neoplasms of the spleen, primary and secondary *S Clin North Amer 33* 493, 1953

STURGIS, C C *Hematology* 2d ed Springfield, Ill, Charles C Thomas, 1955

TERRY, J H, SELF, M M, and HOWARD, J M Injuries of the spleen *Surgery 40* 615, 1956

WHIPPLE, A O The problem of portal hypertension in relation to hepatosplenopathies *Ann Surg 122* 449, 1945

ZOLLINGER, R M, and WILLIAMS, R D in DAVIS, CHRISTOPHER, *Textbook of Surgery* 6th ed, Philadelphia, W B Saunders Company, 1956

syndrome, or the symptoms that follow perforation and peritonitis A history of periumbilical crampy pain is typical of small bowel disease, especially when it is associated with vomiting The relationship of cramps to meals is helpful since symptoms may occur postprandially at the height of small bowel activity

Steady pain usually means vascular compromise, true infarction of an obstructed bowel loop, or perforation with peritonitis The location of the pain may be a clue to the level of the involved loop of bowel Strangulation often leads to reflex pain in the back at the level of the lumbar vertebrae because of pull on the mesentery

If vomiting occurs, the relation to onset of illness and the type of vomitus must be determined With high small bowel obstruction, recently ingested food is vomited soon after onset and frequent vomiting continues With low small bowel obstruction there is usually vomiting at onset, then a free period followed by the appearance of copious feculent vomitus

When distention has been noted by the patient it is important to ascertain whether it is persistent and increasing or intermittent, and whether or not it is localized

In obtaining the past history, it is essential to elicit any history of previous surgery since postoperative adhesions are the commonest cause of small bowel obstruction

The history of small bowel disease in other members of the family or in previous generations may be of help since polyps, and probably diverticula, are known to have a familial occurrence

It may be inferred from the above discussion that the important symptoms that have been mentioned are those of small bowel obstruction On the other hand, careful questions involving the less common symptoms must not be neglected Diarrhea may be due to an active enteritis, either acute, as with a gastroenteritis, or chronic, such as may be observed with regional ileitis. Melena may be observed ranging from profuse bright red to tarry stools, depending upon the rapidity of the blood loss The bleeding may vary from massive hemorrhage to intermittent microscopic blood loss The symptoms of deficiencies of absorption are variable but include those of loss of weight anemia, various vitamin and electrolyte deficiencies

### Physical Examination

The findings on physical examination usually are related directly or indirectly to obstruction However, metabolic abnormalities or the peritoneal signs of perforation and inflammation either may accompany those of obstruction or be present alone

In the examination of the patient with small bowel disease, areas peripheral to the abdomen should be evaluated first Severe prostration and a state of shock suggest strangulating obstruction The state of hydration is noted since it influences the calculation of fluid replacement An examination of the central nervous system is helpful, for the pains of a tabetic crisis can mimic the severe pain of mesenteric thrombosis, small bowel colic, or peritonitis

The condition of the cardiovascular and pulmonary systems is of importance for several reasons This examination aids evaluation of the anesthesia risk, the management of fluid therapy, and may contribute to diagnosis since mesenteric arterial emboli occur with irregular cardiac action and often are associated with other embolic phenomena Other items of importance include inspection of the mucous membrane of the oral cavity for pigmented areas suggesting intestinal polyposis (Peutz-Jeghers syndrome), or for hemangiomas that may occur simultaneously with similar intestinal lesions (Osler-Vaquez' disease) Furthermore, peripheral lymph nodes may suggest widespread lymphoma or metastatic cancer, or the signs of serotonin poisoning make the diagnosis of a carcinoid tumor

supine is worthy of meticulous study by both the surgeon and the radiologist In the general examination of the film one may see the ground glass appearance of intraperitoneal fluid the obliteration of the psoas shadows associated with retro peritoneal edema the obliteration of the peritoneal fat lines associated with peri tonitis or perhaps an ileus producing bony injury

The x ray shadows of the bowel itself may reveal the gas filled and fluid filled loops of full blown low small bowel ob struction or this condition may only be hinted at by the presence of one dilated gas filled loop These shadows typical of intestinal obstruction usually appear from four to six hours after the onset of acute simple mechanical obstruction It cannot be emphasized too strongly however that when the obstruction is strangulating from the onset these typical shadows may never appear *A negative x ray examination therefore does not exclude the diagnosis of intestinal obstruction*

To demonstrate dilated loops in the presence of strangulating obstruction Wangensteen and co workers have used a pneumoperitoneum We have not used this method though it should be of value in any clinic that approves of an ex tended trial of therapeutic intubation

Theoretically in acute mechanical ob struction gas and fluid levels are seen in the intestine while the colon is empty In paralytic ileus gas and fluid levels are seen indiscriminately at various levels in stomach small intestine and colon In practice however any differentiation of these two types of ileus is extremely d f ficult on the basis of x ray studies alone

Films of the abdomen and chest taken in the upright position are helpful in delineating air fluid levels as well as sho ving free intraperitoneal air under the diaphragm With the patient in the supine position under certain circum stances when there is a good deal of intraluminal fluid the flat film may not be particularly instructive, and yet on upright examination the typical ladder like appearance of small bowel obstruc tion may be noted Air fluid levels in abscess cavities are also visualized in this manner

The routine aspiration of the stomach with a radiopaque nasogastric tube is done in our hospital before such x ray study and the tube left in place This not only identifies the location of the stomach by the presence of the tube but also eliminates confusing gas and fluid shadows

Radiopaque contrast material is com monly used in the study of the unob structed small bowel but in the presence of obstruction may be used with care Barium sulfate by mouth may be hard to remove at operation if such is neces sary and also may completely plug a partially obstructed bowel or a long intestinal tube that previously was func tioning well A small amount of this solu tion on the other hand may be very helpful though it should not be used when the obstruction is in the colon

In recent years the use of water soluble radiopaque substances has been described by Canada and Schatzki and seem to be perfectly safe for use in gastro intestinal radiology at any time The use of this new technique in our hospital has helped to establish the diagnosis and level of bowel obstruction on several occasions

In the absence of obstruction elucida tion of the finer details of the small in testine are carried out in several ways In the simplest and most commonly used the patient drinks several glasses of ice water to stimulate small bowel activity after ingestion of barium The barium column then is observed both by fluoro scope and by films taken at regular intervals until the barium reaches the cecum Thus the appearance of the bowel as well as the transit time from mouth to cecum can be determined

Schatzki s small intestinal enema tech nique allows the entire length of the small gut to be studied carefully under the fluoroscope A Rehfuss tube is passed into the duodenum and 500 to 1 000 cc. of 1 to 20 barium sulfate suspension is

agent Local applications of a vasoconstrictor are sometimes of help in the introduction The tube with the balloon collapsed is passed through the nose and into the stomach It is important to avoid introducing an excessive length of tube at this stage or it will coil in the stomach, preventing progress of the tip through the pylorus Passage of the tube through the pylorus is facilitated by placing the patient on his right side with the foot of the bed elevated on low shock blocks, by fluoroscopic manipulation, and by cold drinks, after the stomach has been aspirated and the tube placed on suction

Once it is determined that the tip has passed the pylorus, either by x ray picture or fluoroscopy, the balloon may be inflated with air and advanced eight inches every hour Suction is continued during the advance and the tube is irrigated with 30 cc of saline every hour in order to keep it open

The major problem with the use of the tube has been to pass it through the pylorus Smith reported 219 failures in 1,000 attempts Because of this, numerous techniques have been employed to maneuver the tip past this crucial point Grafton Smith has used a tube that can be directed by a long stilette, he has found it most effective Others have utilized metallic mercury as a method of weighing the balloon so that gravity may be made to assist the forward motion of the tip Mercury, once introduced, cannot be withdrawn from the balloon and thus the one advantage of the Miller Abbott tube over other types of long intestinal tubes is negated It is a simple matter to stop the forward motion of this type of tube once the tip has reached the desired level The air is withdrawn, the balloon collapses, and the bolus that provides motive power disappears With mercury in the bag, it is impossible to remove the bolus and thus arrest progress of the tube In fact, mercury has been known to prevent the withdrawal of air by plugging the lumen of the tube that communicates with the balloon.

Therefore, if a weighted balloon is desired, if the ability to stop the progress of the tube is not important, or if more effective intestinal decompression is desired, it is better judgment to select a single lumen tube such as those described by Harris or Cantor They are no more difficult to introduce through the nose than the Miller Abbott tube pass the pylorus with greater ease than the unweighted Miller Abbott tube and, since

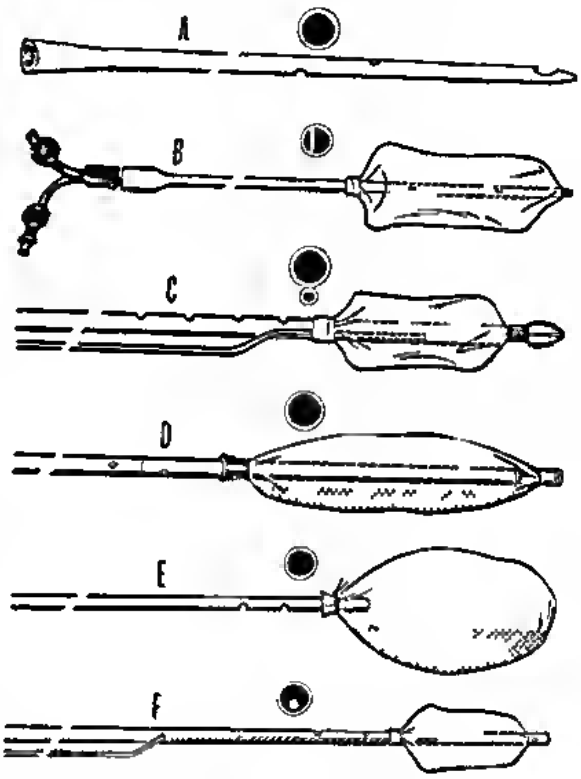


Fig 16-1 Types of tubes for intestinal suction (*A*) Levin (*B*) Miller Abbott (*C*) Johnston (*D*) Harris (*E*) Cantor (*F*) Grafton Smith

they have a single lumen provides more effective suction for the same outside diameter

Decompression of the small bowel with one of the long tubes has several obvious advantages First, in preparation for operation the patient may be carried to a point where operation is least dangerous Relief of obstruction and deflation of the bowel make intra abdominal procedures easier and, while decompression is being carried out, fluid and electrolyte regulation may be conducted In addition,

peritonitis Usually, however, an end ileostomy is done in conjunction with a total colectomy for ulcerative colitis or multiple polyposis

In this operation the terminal ileum is identified and divided between clamps, using the cautery In the absence of complete obstruction, the distal end is turned in with a double layer of catgut reinforced with cotton but, if obstruction is complete, it is safer to bring the distal end out of the abdomen through a separate stab wound, forming a mucous fistula

The ileostomy stoma should be placed in the right lower quadrant about 6 cm below the umbilicus, and 3 cm lateral to it In this area there is room enough to cement one of the various types of bags designed to catch the ileostomy discharge It is better to bring out the ileostomy through a separate incision made by removing a small button of skin and fascia, rather than through the laparotomy incision

Complications of ileostomy include prolapse, herniation of a loop of ileum through the trap behind the stoma, ileostomy dysfunction, late stricture, and fistula formation Prolapse and herniation have become rare since the mesentery of the ileum has been secured carefully to the lateral abdominal wall Likewise, ileostomy dysfunction and late strictures have been essentially eliminated by Brooke's technique of primary eversion of the mucous membrane of the ileostomy stoma and suture to the skin Fistulas about ileostomies result from penetration of sutures too deeply into the bowel, or from damage to the bowel wall by instrumentation at the time of surgery or postoperatively, or from an active ileitis in the distal ileum Catheter ileostomies will be discussed below under intestinal obstruction

### Fluid, Electrolyte, Plasma, and Blood Replacement

The adequate preoperative replacement of fluid, electrolytes, protein, and blood in a patient who enters the hospital in a depleted state from chronic small bowel disease is comparatively easy, but may be difficult or impossible in the presence of acute small intestine obstruction The management of fluid and electrolyte therapy in a patient who enters the hospital after several days of vomiting from small bowel obstruction will therefore be considered in detail

Blood is drawn for immediate determination of serum sodium potassium, chloride, carbon dioxide levels, blood pH, and hematocrit An indwelling catheter is placed in the bladder and hourly recordings of urine output are begun An accurate account of all intake and output is also started The replacement of electrolytes is begun immediately with a 5 per cent glucose in normal saline The administration of potassium is withheld until a good urine output has been established for when this ion is administered in the absence of good kidney function the serum level can rise rapidly and dangerous myocardial complications result

In the absence of dehydration the fluid and electrolyte needs may be calculated mathematically, using the method of Coller and Maddock Intravenous fluid should be given to produce a minimum of 1,000 cc of urine a day This means in the average patient that 2,000 to 2 500 cc of fluid will be required daily for urine and insensible water loss In the patient with obstruction there must be added the amount lost by intestinal drainage and by excretion into the distended gut, as a rough guide this must be replaced volume for volume with normal saline solution This means that in a depleted patient as much as 8 to 10 liters of fluid may be required for replacement, for in clinical severe dehydration a patient may lose 10 per cent of body weight in fluid

The restoration of electrolytes is carried on simultaneously with fluid administration We prefer the use of normal saline in most electrolyte deficiencies, although the judicious use of 3 per cent saline solution in 250 cc. amounts in cases where the serum sodium level is below 125 mEq per liter has been ex-

may be aspiration of regurgitated contents not only from the stomach but from the small bowel during manipulation and a fatal obstruction of the airway, or later aspiration pneumonia may result

At the present time, in the Massachusetts General Hospital, Pentothal combined with relaxants and nitrous oxide–oxygen inhalation seems to be well suited to shorter cases Cyclopropane, with its short induction period, is often very satisfactory

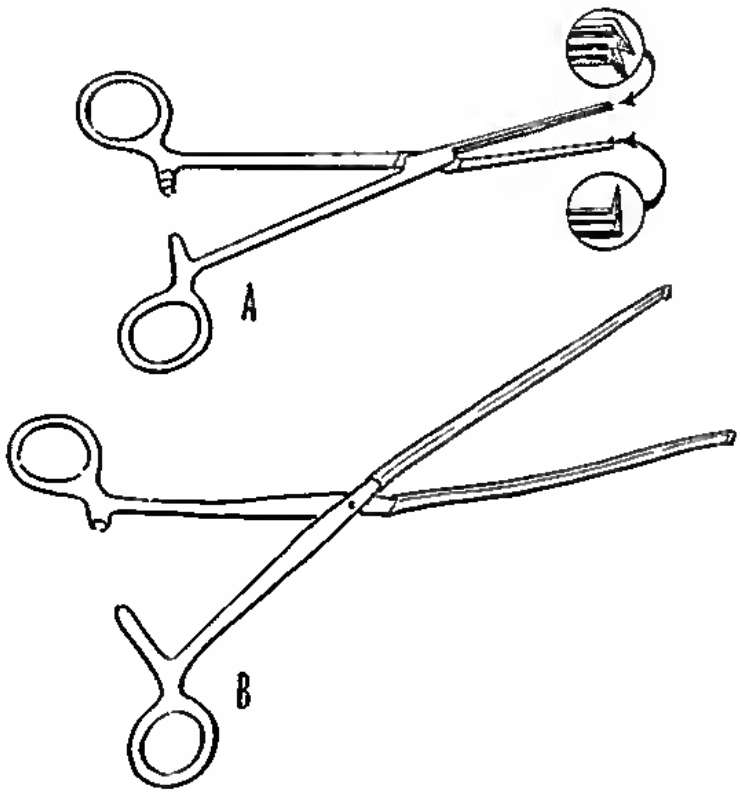


Fig 16-2 Clamps used for intestinal anastomosis (*A*) Allen clamp (*B*) Rubber covered clamp

The use of spinal anesthesia seems of little advantage in the face of present-day relaxants It is definitely contraindicated in patients who are very ill, who have been obstructed for several days, or who have hypertension, since the sudden fall of blood pressure may result in a fatality Local anesthesia may be indicated in critically ill patients for performing an ileostomy or enterostomy

*Incisions*

Though the surgeon's choice of an abdominal incision must be decided by many considerations for operation on the small intestine, a paramedian incision has great advantages Although it is more time consuming, it devitalizes no muscle, does not destroy motor nerves to the rectus muscle, and in wound closure interposes muscle between the incisions in peritoneum and fascia These factors aid in the avoidance of postoperative wound disruption, infection, weakness, and hernia

The site of the incision is an important consideration, and is influenced by the type and location of pathology expected In doubtful cases, a mid abdominal opening just to one side of the mid line, which may later be extended upward and downward, is advisable For intrinsic lesions of the upper small bowel, a left middle and upper abdominal incision is preferable, while in lower lesions a right sided incision in the middle and lower abdomen is indicated In intestinal obstruction based on an adhesive band, or from burnt-out inflammatory processes, a long, centrally placed incision that will allow

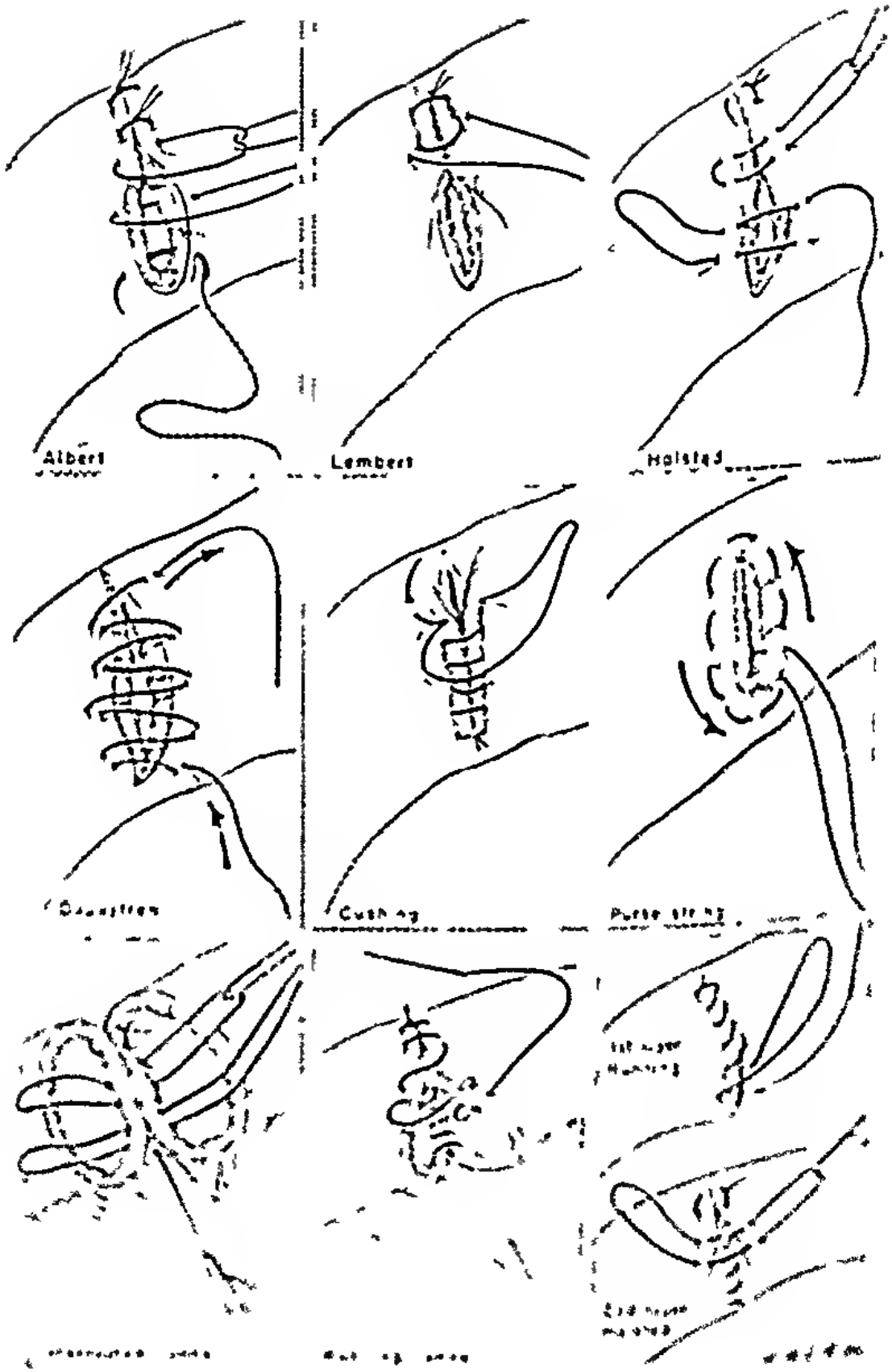
Albert
Lembert
Halsted
Cushing

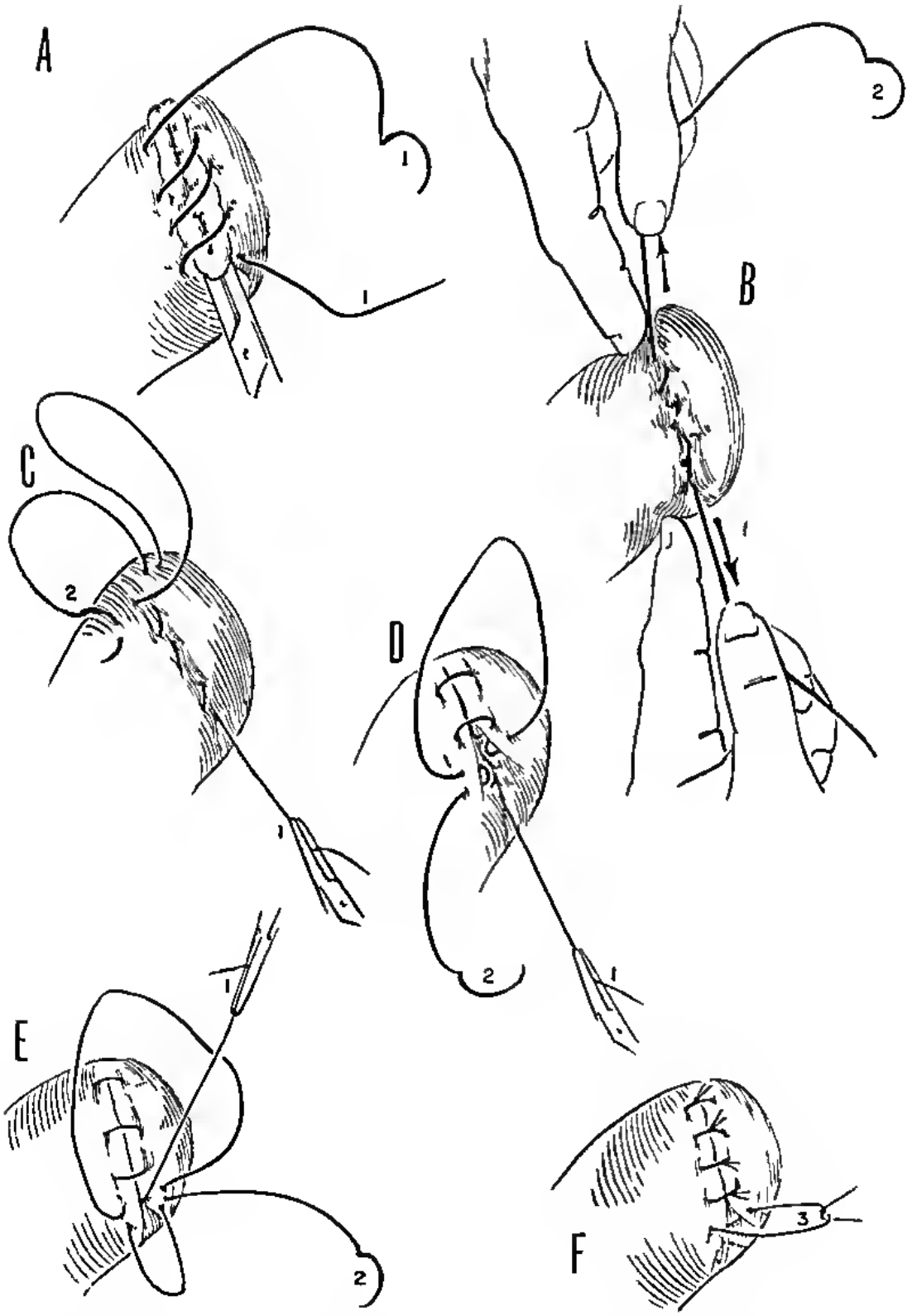


Fig 16-4 Closure of an open end of intestine (*A*) The bowel is divided between Allen clamps with a cautery and a running suture is placed around the clamp (*B*) Clamp is removed as assistant tightens the suture (*C, D, E*) The suture is returned to point of origin as a running Cushing suture, and tied (*F*) The closure is re-enforced with a layer of interrupted Lembert sutures

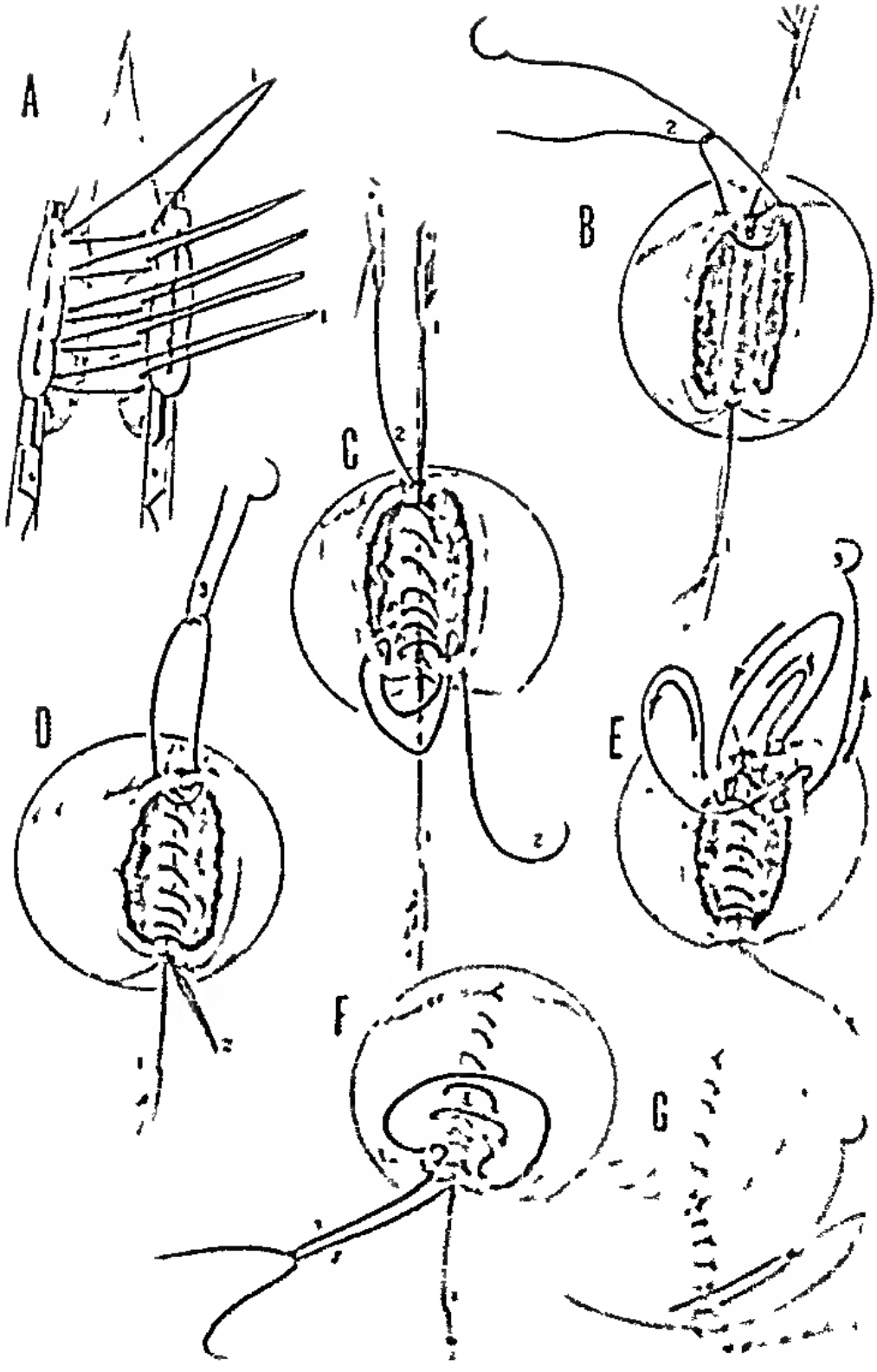
A
B
C
D
E
F
G

access to the most likely point is necessary

In making an incision for intestinal obstruction, the possibility of further operations must be considered If the first operation is being done for temporary decompression by enterostomy or a short-circuiting procedure, the incision should, if possible, be placed well away from those which will be planned for the second or third procedures to correct the situation Also, in general terms, ileostomy and colostomy stomas should not be made in the laparotomy incision, but preferably are brought out through separate short incisions

Laparotomy incisions are closed with No 0 chromic catgut to the peritoneum, nonabsorbable (No 30 cotton or No 000 Surgaloy wire) in the fascia, heavy non absorbable sutures through skin, fat, and anterior rectus sheath, and silk in the skin

### *Instruments*

Many instruments have been designed to facilitate intestinal anastomosis Nearly all of them are of historical interest only Since an open technique of bowel anastomosis is employed regularly in the Massachusetts General Hospital, only two different types of instruments are in common use These are the Allen modification of Kocher's clamp and light-weight rubber covered intestinal clamps (Fig 16 2)

The Allen-Kocher clamp is a long narrow, thin bladed clamp with longitudinal striations and a toothed end It is suitable either for closure of an open end or anastomosis, and its use will be described later Very frequently simple rubber-covered intestinal clamps such as those pictured may be used to protect the area of anastomosis from soiling, particularly if there is distention of the proximal bowel Caution is advised in the use of this instrument, however, since injury to the circulation of the segment may take place, particularly in edematous bowel, if it is left in place for a protracted period

### *Intestinal Suture and Anastomosis*

Certain fundamental principles must be observed to insure satisfactory healing of an intestinal suture A water-tight approximation of the serous coats of bowel that has good circulation must be done in such a way that the finished suture line lies without distracting tension being exerted by the segments that have been joined together Since healing in the bowel occurs in the serosa only, the mucosa must be inverted very carefully at the cut edge in order to prevent leakage

There are many ways to arrive at this goal (Fig 16 3), but generally we prefer an open, two layer end to end anastomosis using an interrupted row of fine chromic catgut (No 00 or No 000) as an inner layer, and interrupted suture of No 40 cotton as an outer row This technique provides a satisfactory inversion of mucosa and approximation of the serous coats without producing a constriction or diaphragm If the lumen is wide, the inner suture may be made of continuous catgut, this is more rapid, but is more likely to lead to early postoperative edema and obstruction Finally, the rent in the mesentery must be closed carefully to prevent formation of a "trap" that might allow later herniation of a loop of bowel

The technique of closure of an open end of intestine is illustrated in Figure 16 4 The bowel is cross clamped at the appropriate spot, using the Allen Kocher

---

lized by traction on the end sutures The inner posterior row is started. (*C*) The inner posterior row is completed and the corner of the anastomosis is rounded (*D*) The inner anterior row is started (*E*) The anterior inner row Connell suture is illustrated (*F*) The inner row is completed This has been shown as a running suture, but interrupted technique is used if there is considerable disproportion between the sizes of the two ends. (*G*) The mesentery is closed with a running suture on each side and the outer anterior layer is completed

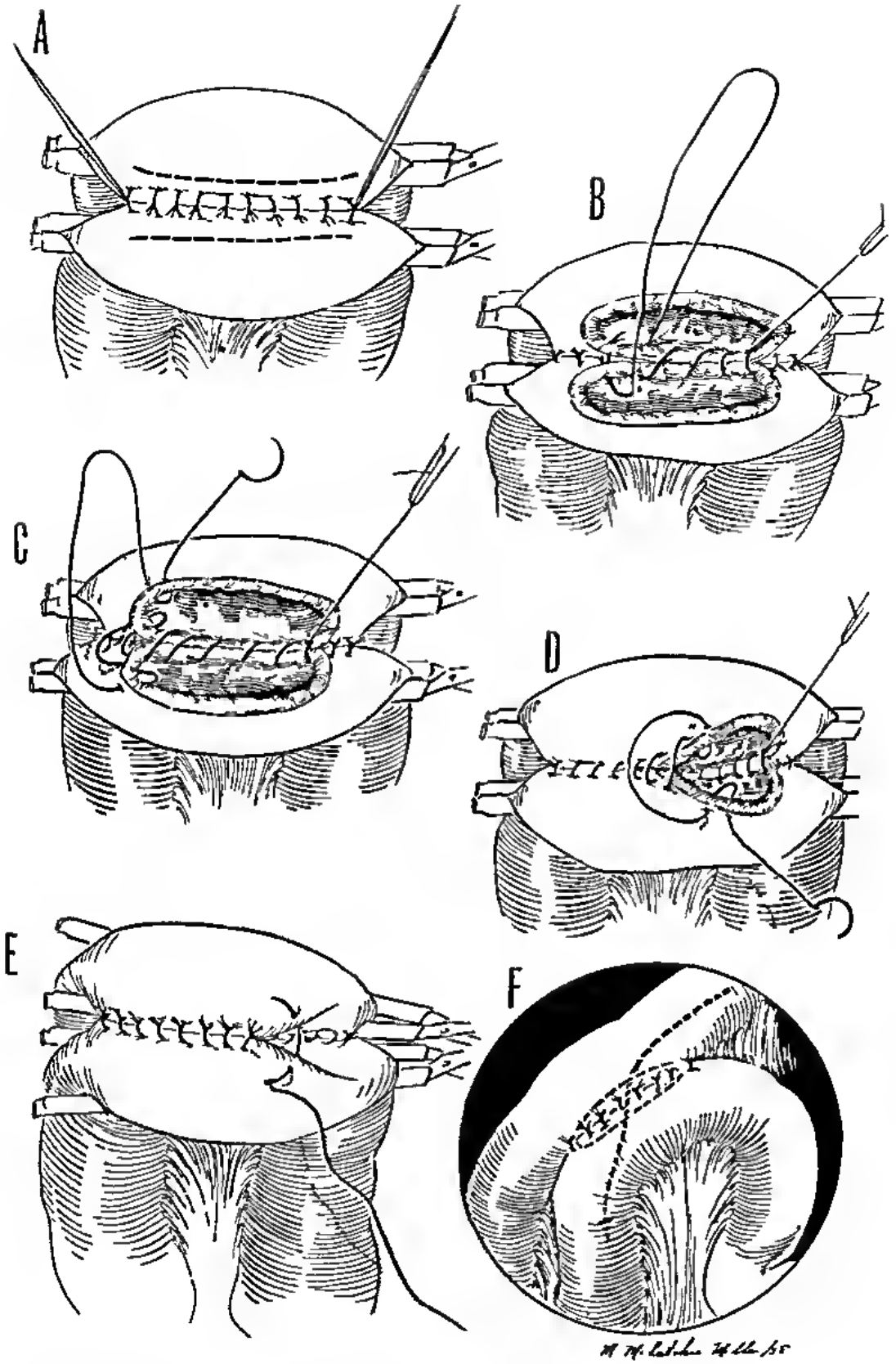


Fig 16-6 Open lateral anastomosis. (*A*) The two segments of intestine may be occluded with rubber shod clamps if there is considerable distention the outer posterior row of interrupted Lembert sutures is placed (*B*) The intestine has been opened and the inner posterior row started (*C*) The method of rounding the corner of the anastomosis with a Connell suture is shown. (*D*) The inner anterior row is completed. (*E*) The clamps have been loosened and the outer anterior row is being placed (*F*) Completed anastomosis

(including external hernia) and (*c*) with acute colonic obstruction accompanied by severe dilatation of the cecum, i e, a diameter of 9 cm or more on the flat plate In all these cases the stomach is decompressed by a Levin tube and operation carried out as soon as possible

If the history indicates the obstruction has a duration of longer than forty eight hours, and the presence of strangulation seems very unlikely, there is definite evidence that prognosis is improved by a period of decompression and administration of fluid and electrolytes

In this group, decompression is effected by an intestinal tube that is manipulated through the pylorus as soon as possible This method of preparation requires very careful observation, since lack of progress of the tube, failure to reduce distention, or onset of symptoms suggesting onset of strangulation will indicate the need for immediate operation

Other patients who usually respond well to conservative measures have obstructions that appear early after surgery such as appendectomy or hysterectomy These obstructions are usually insidious in onset, pain and cramps may be absent and vomiting or distention the only diagnostic clues Diagnosis is suggested by x ray of the abdomen Intestinal suction is the most effective method of prevention and treatment of these cases, since a certain element of infection usually is present and at least part of the distention is due to paralytic ileus The exudate will subside and intestinal function will be reestablished if decompression is maintained and angulation from distended bowel thus avoided

Early postoperative obstruction, however, is treacherous Obstruction may be strangulating, particularly after operations in which a colonic or iliac stoma has been produced that allows prolapse of a loop of intestine through the trap Prolonged therapy by intubation is very dangerous and must be abandoned for operation unless there is rapid improvement

The third group of patients includes those in whom preparation for operation by intubation or therapy of an early postoperative obstruction believed to be due to plastic adhesions has had to be interrupted because of deterioration of the patient s condition Many of them present a terrific problem in surgical management because of the fact that the presence of peritonitis causes or increases the severity of the obstruction while the depletion attendant upon long standing obstuction contributes to the chronicity of the peritonitis

With these factors in mind, Welch has recently advocated a more aggressive direct surgical attack for obstruction, unrelieved by conservative measures, in the presence of peritonitis He has suggested the concept of refunctionalization of the intestine as the only measure that will relieve these very ill patients Such an operation includes a full-scale laparotomy with drainage of abscesses and the establishment of a patent gastrointestinal tract that includes as much functional intestine as possible. This may involve resection of the bowel, anastomoses between obstructed loops, or other short circuiting procedures as well as the creation of an artificial anus such as an ileostomy or colostomy When this group of cases has been brought into as good physiological condition as possible under the circumstances and the surgical procedures well covered with appropriate antibiotics, the results have justified the logic of the basic concept

### *Conduct of Operations for Intestinal Obstructions*

Such operations are carried out under general anesthesia supplemented by muscle relaxants for reasons previously mentioned Incisions are planned and made in accordance with principles discussed above

Two cardinal principles must be kept in mind when a decision to operate is made First, the patient either must be in condition to stand the procedure planned or there is no reasonable alternative, and in the second place the opera-

tion with neomycin solutions have been followed by respiratory arrest

The *operative methods* available for relief of obstruction include enterostomy, lysis of adhesions, resection, and enteroanastomosis The use of the *enterostomy* for decompression in the modern day of preoperative preparation with fluids, electrolytes, and intestinal suction is very rarely necessary for several reasons First, it is now possible to carry out more extensive procedures that are designed not only to correct the obstruction but also to remedy the causative factor as well In addition, the use of a simple tube enterostomy for decompression of an obstructed bowel is not an effective method of accomplishing this end and, when the stoma is placed at a high level, the fluid losses from the small bowel may be of such magnitude that replacement therapy is difficult or impossible The use of an enterostomy, however, may have some application in an extremely ill patient in whom one definite point of obstruction can be identified since this procedure can be done very quickly and expeditiously, even under local anesthesia if necessary For example, edema may occlude a small bowel anastomosis and relief can be secured by enterostomy

A favorite form of enterostomy was described by Witzel By his method a catheter is inserted into a small opening in the bowel The wall of the intestine then is sutured over the catheter, making a tunnel through which the tube passes The formation of the tunnel may diminish the lumen of the bowel more than is warranted unless the intestine is distended The technique of the Witzel enterostomy is depicted in Figure 16 7

Enterolysis is a common operation for relief of obstruction If obstruction is due to a single band adhesion, it is usually sufficient to divide such a band at either end, controlling the stumps of the band with hemostatic ligatures and if possible resecting loose ends in order to prevent their becoming adherent to some other surface and causing further difficulty from obstruction This type of procedure is one of the simplest and most satisfactory that can be carried out in the many different types of intestinal obstruction The operation is not complete, however, until the surgeon is certain there are no other adhesions involving the intestine Often multiple obstructing points may be found If this is the situation, one must begin carefully and systematically to free all the involved areas of bowel so that an intestinal tract completely mobilized from the ligament of Treitz to the ileocecal valve is obtained After this maneuver has been completed the bowel is inspected for areas of questionable viability, perforation, or severe damage to the bowel wall, and if such exist, these segments must be excised and anastomoses carried out

We feel strongly that in situations such as this, limited operations for lysis of adhesions are to be decried, for the rate of recurrence of intestinal obstruction following these minimal procedures is notoriously high, and one cannot be fully convinced that the operation has accomplished its purpose, that is, completely to restore the function of the intestinal tract, unless one has carefully inspected the entire length of the small bowel from one end to the other, and made sure that no obstructing areas remain It is obvious that such an extensive procedure as the one outlined above must be reserved for those patients who are in the best possible physical condition and that more limited procedures are perforce necessary in those cases which cannot be brought to optimum physiologic status In these patients it is often possible to bypass the obstructing area by performing an enteroanastomosis This may be done between adjacent loops of small bowel or between the distal small bowel and transverse colon This method of bypassing a point of obstruction is also of value when the causative factor is of such a nature that it cannot be dealt with by primary attack An example of such an instance is found with acute small bowel

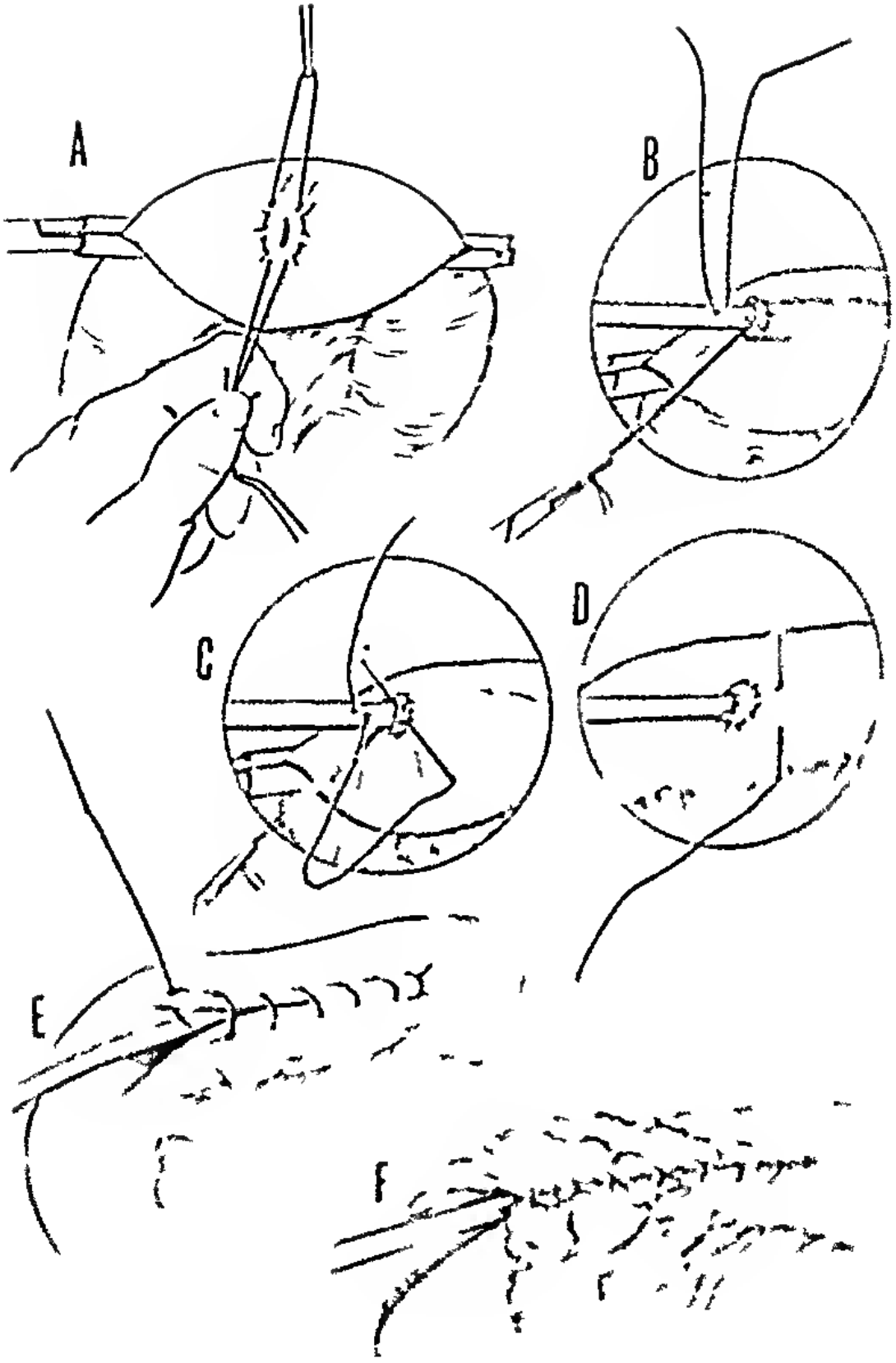
A
B
C
D
E
F

obstruction following obstruction owing to a pelvic abscess or to cancer of the colon

Methods for end-to end and lateral anastomoses have previously been discussed Special applications of these techniques may become necessary when a high intestinal resection has to be carried out Carter's method involves opening the transverse mesocolon over the third portion of the duodenum and performing a side to side duodenojejunostomy Following Lahey's method, after a sleeve resection of the involved bowel at the ligament of Treitz, the distal duodenum is freed up and lifted from its bed and brought in front of the colon where a lateral duodenojejunostomy is made These procedures are satisfactory when dealing with benign lesions, but theoretically are not suitable operations for the resection of malignant disease occurring in the upper jejunum, since they are too limited in scope In the latter instance a Whipple operation may be a more logical procedure

## Paralytic Ileus

Patients with paralytic ileus ordinarily should not be subjected to surgical attack It is seen as a physiologic reaction of the bowel after most abdominal surgery and frequently is due to an acute peritonitis It may also accompany other extraperitoneal diseases such as ureteral stone, fractured pelvis, and traumatic shock If paralytic ileus is anticipated with any of these diseases, the accompanying distention and physiologic imbalance resulting therefrom usually may be avoided by the use of nasogastric suction with a Levin tube The diagnosis is distinguished from that of mechanical intestinal obstruction by absence of peristalsis and pain Some help may be obtained from the x ray film if generalized distention of both small and large bowel are seen

The treatment of paralytic ileus is directed toward the primary pathology If peritonitis is present then maneuvers designed to stimulate peristalsis such as enemas and Prostigmin are contraindicated These measures, on the other hand, may be used if infection is absent The most valuable instrument in the surgeon's therapeutic armamentarium is intestinal decompression, preferably by an intestinal tube This type of suction should be maintained until peristalsis is resumed and the patient passing gas by rectum

Enterostomy is mentioned in connection with paralytic ileus only to be condemned It does no good as a method of decompression because of the adynamic situation of the bowel and has been shown repeatedly on a statistical basis to carry an extremely high mortality in this condition On the other hand, it must be recognized that cecostomy can be life saving when the colon is enormously distended Also many patients believed to have paralytic ileus often have mechanical obstruction so that operation should not be delayed indefinitely in a patient with supposed paralytic ileus The small bowel should be emptied by aspiration and, in many instances, obstructing adhesions then can be found

## Adhesions

Adhesions are a very common cause of intestinal obstruction They most frequently develop after pelvic surgery or appendectomy but may be due to intra abdominal inflammatory disease or may be congenital The commonest type consists of adhesions that bind the terminal ileum to the cecum, or to the abdominal wall, or to the right pelvic gutter Intestinal obstruction developing after abdominal operations will nearly always be due to adhesions about the operative field or the incision Therefore, when such a condition is suspected, the incision should be made away from the previous operative site so that the chances of entering the free peritoneal cavity are increased Omental adhesions are usually relatively easy to free from the bowel but occasionally adhesions may be extremely dense and dissection to free

a relatively short period of time The operative procedure is concerned primarily with detorsion of the bowel If the bowel is viable, a causative factor should be searched for and, if present, removed or corrected If gangrene is noted, the involved segment must be resected and anastomosis carried out

The complications associated with volvulus may be divided into two groups Peritonitis is the usual cause of death immediately after operation, and if the patient survives there is a high chance of recurrence of the volvulus, unless the causative lesion has been removed or corrected

## Congenital Abnormalities

Congenital abnormalities of the intestinal tract are uncommon Some are asymptomatic, being discovered only at autopsy Approximately half of the cases with developmental abnormalities that lead to intestinal obstruction occur in the newborn infants The remainder may occur at any age The abnormalities may be divided into two groups In the first group obstruction is due to intrinsic disease of the bowel such as stenosis atresia, reduplication, or cysts The second group include the abnormalities of rotation Intrinsic obstructions are twice as common as other forms and include stenosis, various forms of atresis, and diaphragms Stenoses vary considerably in extent and occasionally may be so marked that the intestine is reduced to a fibrous cord A distinct blind loop of intestine is formed by an atresia and 10 per cent to 15 per cent of atresias are multiple Diaphragms may be complete or incomplete and are most commonly found in the duodenal and ileocecal regions

Abnormalities of rotation include nonrotation, malrotation, and reversed rotation With nonrotation of the intestine all the small bowel lies on the right and the colon on the left side of the patient

In a second group there is malrotation of the intestine and obstruction follows abnormal intestinal fixation The partially rotated cecum may fuse to the duodenum, producing high intestinal obstruction Lack of fixation of the mesentery may lead to volvulus of the small intestine or entire mid gut Peritoneal bands may be found about the ileocecal region, producing obstruction of the distal ileum (Lane's kink), as well as about the duodenum where they cause high intestinal obstruction

In a third group of cases there is reversed rotation with acute obstruction of the colon The transverse colon lies behind the duodenum and the superior mesenteric vessels and is trapped by these structures Some of the patients with any type of abnormal rotation have volvulus of the entire mesentery, and others torsion of the small intestine or right half of the colon on its primitive mesentery

### *Diagnosis*

The symptoms are usually those of obstruction, although bleeding can occur with reduplications The obstructive symptoms in infants always occur within the first week of life and pain vomiting and obstipation are combined with variable degrees of distention, dehydration and shock X ray studies are helpful and will reveal the characteristic gas filled loops of intestine and stomach If the patient is not too ill, a barium enema may be obtained in order to evaluate the patency of the colon A small amount of barium by mouth may be helpful in ruling out pyloric obstruction or in locating the level of an atresia

The failure to find keratinized epithelial cells in the stools in an infant (Farber's test) is indicative of atresia of the intestine The diagnosis of volvulus is sometimes difficult to make, and sometimes can be made only at the operating table with certainty

### *Treatment*

Operative treatment is undertaken as soon as the diagnosis is made and the patient is prepared for surgery It may be

to a tube the size of the intestinal canal and nearly a foot long They contain all the layers of the intestinal tract, and on histologic examination may be found also to contain gastric mucosa or pancreatic rests

### *Complications*

While the presence of a Meckel s diverticulum is a fairly uncommon occurrence, as noted above, the percentage of them that are symptomatic is far less common However, they are subject to many and serious complications so that we believe that the uninflamed structure should be removed when it is incidentally discovered at laparotomy Most Meckel's diverticula are discovered at the time of appendectomy for presumed acute appendicitis The appendix is found to be less inflamed than is expected, and further search is likely to show an inflamed or gangrenous Meckel's diverticulum It is the policy at our clinic, when an operation for appendicitis is performed and the appendix shows no obvious signs of inflammation, to examine the lower six feet of ileum for a Meckel s diverticulum and also to note the condition of the lymph nodes in the mesentery of the small bowel

The complications of Meckel s diver ticulum include inflammation, perforation, hemorrhage, obstruction, or tumor formation Hemorrhage is the pre dominant symptom in children and is probably the most common cause of gastrointestinal bleeding in this age group Symptoms of intestinal obstruc tion are more common in adults

It has been noted above that these tumors may contain ectopic gastric mu cosa and it is ulceration in these islands of mucosa that leads to bleeding It has been stated that bleeding or rupture probably occurs only when gastric mucosa is present These ulcerations on rare occasions can cause vague intestinal symp toms but the outstanding and usually single symptoms is the passage of large amounts of brick red blood by rectum in patients who are between the ages of one and six years Obstruction usually occurs from bands that are numerous about the base of the diverticulum, and has also been described in association with diverticula that become heavily loaded with fecal material so that mechanical compression of the surrounding bowel is produced

Enteroliths have been reported as a rare finding in Meckel's diverticulum Tuberculosis has also been found as pri mary in a diverticulum while polyps, adenocarcinoma, leiomyosarcoma, and fibrosarcoma are rare pathologic changes

### *Treatment*

The treatment of choice is excision, and this may be done in several different fashions, depending upon the size of the structure Small diverticula may be re moved by placing an Allen Kocher clamp across the base of a diverticulum in an oblique fashion The diverticulum is then removed with a cautery, and a running Cushing stitch is taken over the clamp, the clamp is removed and the suture tied This suture line is then reinforced with a second row of interrupted sutures The principle of longitudinal excision and transverse closure cannot be done with this method, so that with a large diver ticulum excision in a longitudinal fashion with an open transverse closure is to be recommended in order to prevent the intestine from being compromised

Resection of a small segment of contiguous bowel may be necessary when dense adherent bands occur between the base of the diverticulum and the bowel or when gangrene is present.

Umbilical fistulas are removed by making an eliptical incision about the umbilicus and carrying dissection down to the peritoneum, which is opened The involved loop of ileum is then freed from the abdominal wall if adherent, and de livered through the incision where the connection of the fistulous tract to the bowel is divided by the method most appropriate to the size of the base of the fistula (see above)

Mesenteric cysts usually can be re-

*Diagnosis*

Since the mortality increases rapidly with the duration of the intussusception, it is obvious that early recognition is imperative The characteristic history and physical examination should lead to the diagnosis in about 95 per cent of cases Usually a well nourished child previously in good health suddenly develops paroxysmal abdominal pain followed by vomiting and as the obstruction continues, pallor, sweating, dehydration and shock follow The passage of bloody stools occurs in about 85 per cent of cases but may not be found in the first twelve to fourteen hours Palpation of the abdomen usually reveals the presence of a mass that is firm and as a rule not tender It may occasionally be felt to become harder during a paroxysm of pain The right lower quadrant may appear to be empty when palpated (Dance s sign) because of the invagination of the cecum up into the ascending colon Blood is found on rectal examination in a majority of patients and occasionally the examining finger may detect the advancing portion of the bowel within the rectal lumen

X ray examination is valuable in obtaining a diagnosis, especially in the small percentage of cases where the nature of the difficulty is not completely clear On a scout film a narrow rim of gas may be seen between the intussusceptum and the intussuscipiens This may be confirmed by barium enema, which in ileocolic intussusceptions will reveal obstruction to the retrograde injection of barium and the presence of a mass within the bowel Gaseous distention of the ileum just proximal to the intussusception is also seen

*Treatment*

There have been numerous discussions of nonoperative methods for the reduction of intussusception of the ileo colic type by the colonic injection of fluids or air Others have advocated reduction with barium enema under the fluoroscope However, the routine treatment by colonic inflation is inadvisable for several reasons First, a good number of these patients come to operation later because of irreducibility or because of uncertainty that complete reduction has been accomplished It is obvious that operation therefore has been delayed and the child has been subjected to manipulations that further deplete an already narrowed margin of reserve Secondly, any existing mechanical causes for the situation are in all probability completely overlooked, and therefore not removed In addition, this type of reduction is not without the theoretical hazard of rupture of the bowel from overdistention

Operative therapy, therefore is the treatment of choice The patient is prepared for operation by administering parenteral fluids or blood if dehydration is marked or shock is present The stomach is deflated to reduce the dangers of aspiration of vomitus, and the child s extremities are wrapped with cotton batting and a warm water bag is placed to the back The abdomen is then opened through a right paramedian incision, which is made in the lower abdomen, and intussusception is identified, and reduction is attempted by general pressure with the fingers just distal to the head of the intussusception Extreme gentleness is essential at all times to avoid intestinal disruption and resultant peritonitis The incarcerated bowel is often hemorrhagic, friable, or gangrenous so that traction of the invaginated segment of the ileum is to be avoided When the head of the intussusception is milked back to the cecum or ascending colon, the entire mass may then be delivered outside the abdomen where it can be more gently and thoroughly manipulated Reduction is continued with the process of milking back, or taxis, and the technique of annular pressure with the hand is often helpful Bathing the swollen intestine with warm saline will help in relaxation This process is one in which delicacy and persistence are the keys to success, and 90 per cent to 95 per cent of intussusceptions can be manually reduced if these

glass, bone, and masses of inspissated meconium in infants The preoperative diagnosis of obturation obstruction is usually made only if the offending agent is radiopaque enough to be noticed on a flat film in association with the usual roentgenologic findings of small bowel obstruction If the obstruction is due to boli of food and is not complete, the situation may resolve with conservative therapy If the obstruction is severe, however, operative therapy is indicated This includes laparotomy and enterotomy with the extraction of a foreign body The obstructing foreign body is if possible milked back into the distended bowel above the site of obstruction and the intestine is then opened with a longitudinal incision Care is taken to avoid contamination of the operative field with intestinal contents and after the removal of the foreign body the intestine is closed transversely

One of the most common and interesting causes of obturation obstruction owing to foreign body is a gallstone It most commonly occurs in elderly females and should be suspected when such a patient has a prolonged attack of upper abdominal or right upper quadrant pain and tenderness, which is followed days later by small bowel obstruction On x ray examination occasionally one will see air in the biliary tree and the administration of thin or water-soluble radiopaque material by mouth may demonstrate a fistulous opening between the gallbladder and the duodenum The scout film of the abdomen may also show a shadow in the right lower quadrant suggestive of a gallstone in approximately half the cases At the operating table, the gallstone is usually palpated in the low ileum, although it may be found in the jejunum or even in the colon The bowel wall at the area of impaction is unusually friable, and must be handled with gentleness It is usually possible to push the stone upward into the distended bowel where enterotomy can then be done with safety Following closure of the enterotomy, it is important to search the portion of the intestine above for other gallstones since they are sometimes multiple and the occurrence of second attacks of gallstone colic in the postoperative period have been described

## Inflammatory Lesions

### *Regional Enteritis*

In spite of the fact that over twenty years have elapsed since the disease or group of diseases known as regional enteritis, regional ileitis, or Crohn's disease was first described, its etiology and treatment are still clouded by lack of information The symptom complex is variable and depends upon the complications that may be contributing to the symptoms There is usually intermittent abdominal discomfort, often worse in the right lower quadrant that may be associated with diarrhea, emaciation, and anemia, intestinal obstruction, perforation, or fistula formation On physical examination the patients may show no more than the signs of a chronic nutritional disease or they may have signs of acute intra abdominal disease with peritoneal irritation as a result of acute inflammation in the bowel, and a right lower quadrant mass may be palpated The patients may describe symptoms of ulcerative enteritis with frequent foul stools, which are sometimes bloody, that may be associated with perianal or perirectal fistulas They may present the symptoms of chronic or acute small bowel obstruction X-ray and physical examination will be confirmatory The findings of persistent and intractable fistulas in the right lower quadrant following previous drainage of abscess or appendectomy are contributory findings Crohn is of the opinion that appendectomy is contraindicated in regional enteritis and that the avoidance of appendectomy has prevented the right lower quadrant fistulas that he formerly observed in his patients Others contend that these fistulas do not occur from the appendiceal stump, but from the ileum that has

therapy directed toward such perforations resulted in only rare recoveries

### Zollinger-Ellison Syndrome

The syndrome of primary peptic ulcers of the jejunum associated with nonspecific islet cell tumors of the pancreas was first described by Zollinger and Ellison in 1955 They presented a group of patients who complained of severe burning and epigastric distress occurring one to two hours after meals Gastrointestinal bleeding and diarrhea were also found, and weight loss was noted in all cases These patients without exception gave laboratory evidence of massive gastric hypersecretion and hyperacidity Peptic ulceration was demonstrated in all by subsequent operations The ulcerations tend to occur in unusual locations such as low in the duodenum, small bowel, esophagus, or near a gastroenterostomy

Nonspecific islet cell tumors of the pancreas or islet cell carcinomas of the pancreas were found in their cases Since their original publication many other cases have been described It is worthy of note that many have associated tumors of other endocrine glands

It is hypothesized that a hyperglycemic-glycogenolytic factor, similar to glucagon, which is present in normal pancreatic islet cells may be secreted in excess by these tumors and serve as a direct stimulant to the gastric secretory mechanism and the atypical ulcerations are the result

## TUMORS OF THE SMALL BOWEL

If small bowel tumors are symptomatic, they cause obstruction from intussusception, local encroachment on the bowel lumen, bleeding, or symptoms owing to local irritation that are felt as intermittent abdominal cramps, increased peristalsis, or 'ulcerlike' pains when the tumors are located in the duodenum Other tumors may be entirely asymptomatic and discovered incidentally at laparotomy When these growths are found at operation it is of prime importance to determine the nature of the lesion Benign tumors are commonest in the duodenum and in the area just distal to the ligament of Treitz Benign growths are usually small, often are multiple, and may be polypoid They show no metastases and there is no puckering of the serosa of the bowel or infiltration beyond the tumor itself Malignant lesions are usually larger, single and frequently exhibit involvement of lymph glands in the area or direct extension to the mesentery Malignant lymphoma and carcinoid tumors, however, may occur in multiple sites

### Carcinoma

Carcinomas are about twice as common as sarcomas The ileum has the lowest incidence of carcinoma but the highest incidence of sarcoma Metastasis from carcinoma of the small bowel is early, and in order of frequency is found in the mesenteric lymph nodes, peritoneum, liver, lungs, and long bones Preoperative x rays of the lungs and long bones are indicated and the lymph nodes and liver must be inspected carefully at the time of operation About one third of all cases will be found to have metastases at the time of operation

### Malignant Lymphoma

*Malignant lymphoma is one of the* most common tumors of the small bowel, occurring most frequently in the terminal ileum They may be secondary or multiple and may give the appearance at the operating table of an inflammatory lesion such as terminal ileitis

### Sarcoma

Sarcoma may occur in various forms, the commonest type being the leiomyosarcoma These tumors develop within the lumen of the intestine and often erode large vessels, which can cause massive hemorrhage Fibrosarcoma and

acetic acid in the urine by chemical analysis

## Operative Approach

Solid tumors of the intestine may be removed in several ways Tiny benign tumors that involve only the serosa and muscularis of the bowel may be removed by enucleation A short incision is made over the surface of the tumor, the mass is shelled out, and the serosa closed over the defect (Fig 16 8*A*, *B*) Benign tumors located in the deeper portions of the intestinal wall may be removed by an elliptical incision of the bowel wall including the tumor, with closure of the bowel in a transverse direction (Fig 16 8*C*, *D*, *E*, *F*) An enterotomy is performed for intraluminal tumors such as adenomas or lipomas Polyps are often difficult to palpate and when identified, the area where the stalk arises must be located with certainty The polyp will nearly always arise from the mesenteric margin of the bowel In order to remove it an incision is made immediately opposite the point of origin of the polyp in a longitudinal direction and the polyp is grasped with Allis forceps (Fig 16 9) The base is identified and is removed with the actual cautery over a curved clamp placed well on normal mucosa The defect in the base is then closed with one layer of fine chromic catgut sutures The polyp is submitted immediately to the pathologist for examination The enterotomy is closed in the usual fashion Several polyps located close together may be treated by resection of a segment of bowel

With larger tumors, or if there is suspicion of malignancy, resection should be performed This may be done by any of the methods outlined previously The essential feature consists of the removal of a wide area of mesentery together with regional lymph nodes Carcinoids also demand resection of the intestine If the tumor is located high in the jejunum, special methods of an anastomosis may be necessary Carter's and Lahey's methods of duodenojejunostomy have been described above and are applicable

Tumors located in the terminal ileum can be removed most safely by right colectomy The terminal ileum, cecum, and ascending colon are resected together with the corresponding portion of the mesentery and regional nodes The operative mortality following surgery for malignant disease of the small intestine varies between 30 per cent and 44 per cent and five year survivals are less than 10 per cent because of the early and wide metastases

A rare form of multiple small cysts of the intestine known as pneumatoides intestinalis is characterized by the presence of numerous gas filled bubbles on the serosal surface of the bowel It occurs commonly in the Orient, though also is seen universally The cause of the disease is unknown but probably follows the escape of intestinal gas through a minute break in the mucosa into regional lymphatics or perhaps may be seen in connection with duodenal ulcer Operation is usually performed for obstruction or because of the finding of intraperitoneal air on x ray examination The cysts can be collapsed by pricking them at the time of operation The condition usually is self-limited and fibrous tissue healing finally results

## Vascular Lesions

Several related lesions may be grouped under the heading of mesenteric vascular occlusion They include arterial thrombosis or embolism, venous thrombosis, or combined occlusions The commonest is venous in type and may result from a variety of predisposing causes Intra abdominal infection, hernial adhesions, torsions, or previous liver disease may lead to venous occlusion, while other cases may exhibit no etiological factor Venous thrombosis is often seen after splenectomy with thrombosis of the splenic vein, which propagates to form a superior mesenteric thrombosis Thrombosis of the superior

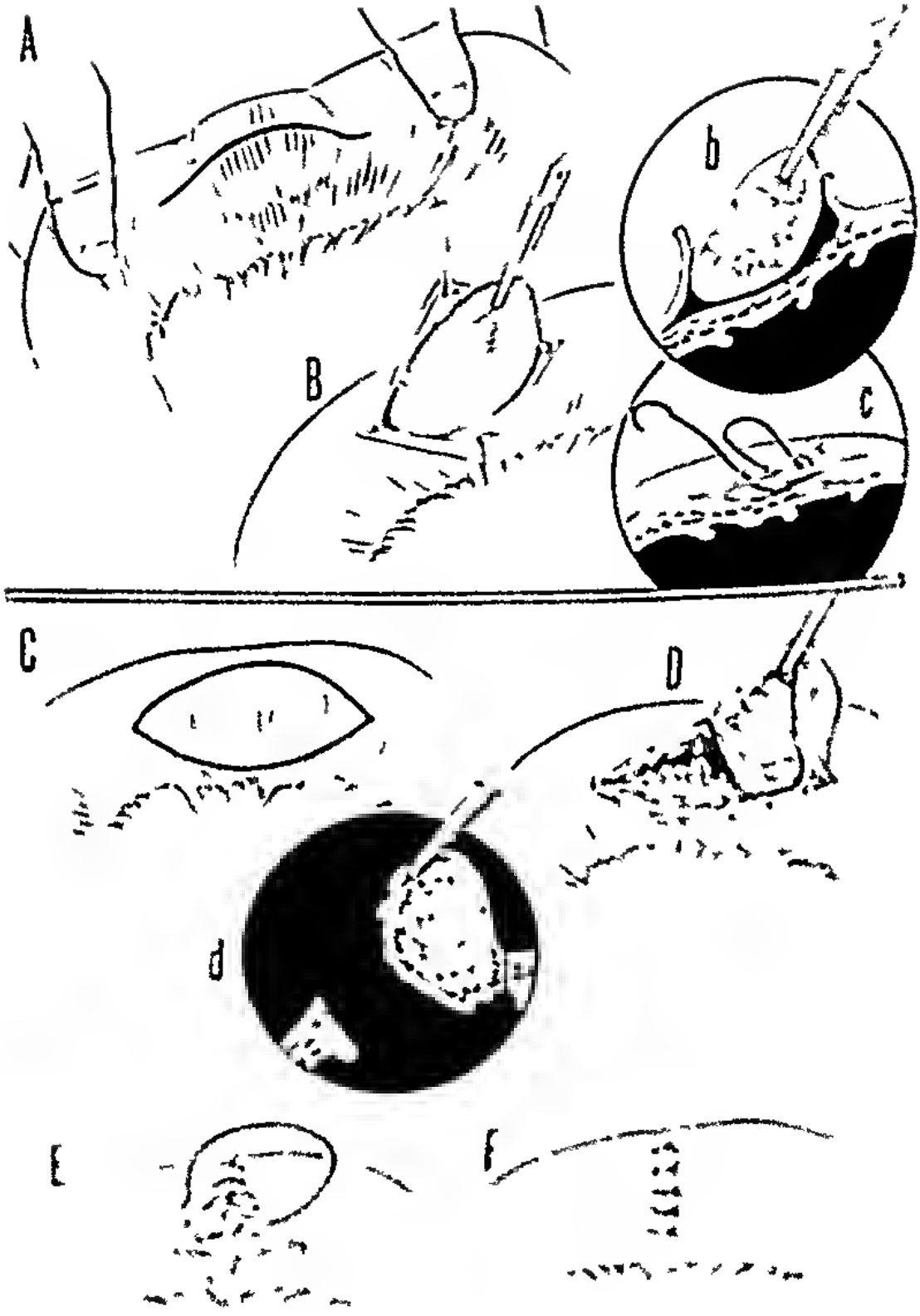
A
b
B
c
C
D
d
E
F

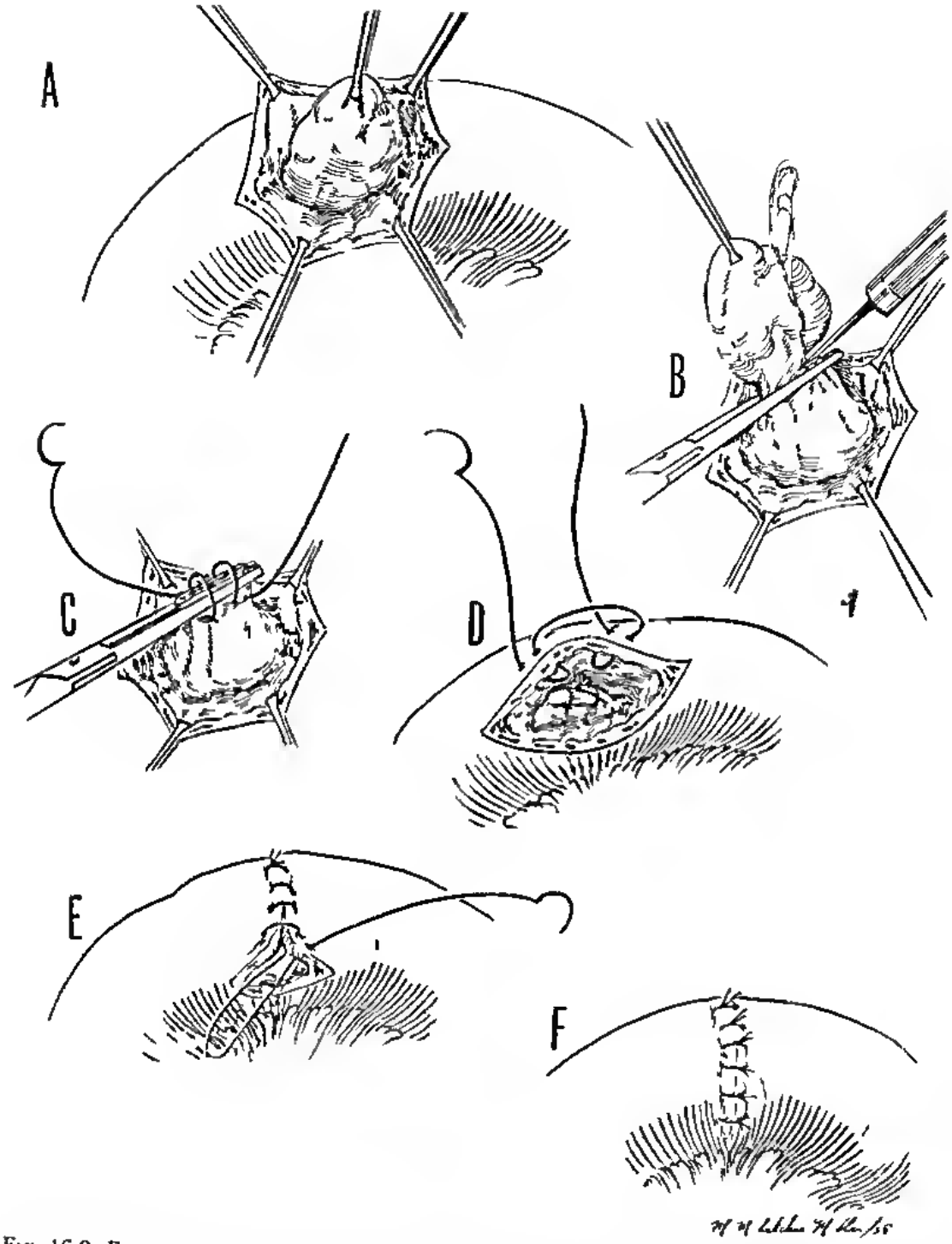


Fig 16-9 Excision of an intestinal polyp (*A*) The intestine has been opened through a short longitudinal incision The polyp is grasped with Allis' forceps (*B*) An Allen clamp is placed across the base of the stalk and the polyp removed with cautery (*C*) The defect is controlled with a running suture (*D, E*) The bowel is closed transversely with a running Connell suture (*F*) This is re-enforced with a row of interrupted sutures

membrane about the site of ligature and spontaneous closure may be expected The presence of chronic granulomata must be suspected and tuberculosis, regional enteritis or actinomycosis should be ruled out A foreign body may also be discovered, such as gauze sponges, fecaliths, or nonabsorbable ligatures Late sloughs and fistula formation also occur when the blood supply to a portion of bowel may have been compromised at the time of surgery or when drains have been left in contact with the bowel for a protracted period, producing pressure necrosis Spontaneous intestinal fistulas occur following tuberculosis, actinomycosis, or regional enteritis Fistulas may also be posttraumatic following crushing injuries of the abdominal wall and intestine, gunshot wounds, or stab wounds They also may follow the operation of jejunostomy or enterostomy but are rare if attention is given to the proper establishment of these openings into the bowel

## Symptoms

The symptoms of intestinal fistulas are both general and local The general symptoms depend upon the level and size of the fistulas and are produced by the loss of fluid, electrolytes, vitamins, and calories from the intestinal tract These losses are most serious in the upper part of the small bowel and death may occur rapidly from dehydration unless the fluid is returned to the intestinal tract. For this reason high jejunal fistulas are extremely dangerous, while a patient will tolerate a low ileal stoma indefinitely The amount of fluid loss of course is proportional to the size of the fistula. If the intestinal fistula persists and the patient survives, the lack of absorption of food will lead to malnutrition Loss of vitamins is especially important as deficiency states stimulating beriberi and pellagra with attendant polyneuritis develop

The local area of discharge from an intestinal fistula is difficult to manage because of the irritating nature of the intestinal contents. Skin digestion with maceration, ulceration, and coexistent infection must be zealously avoided by meticulous care of the skin about the stoma

## Diagnosis

The diagnosis of an intestinal fistula is usually easy In questionable cases the administration of carmine by mouth or Lipiodol injections of the sinus tract will help An attempt should then be made to establish the cause of the fistula If tuberculosis is suspected, a biopsy of the wall of the tract should be taken A search may be made for the sulphur granules characteristic of actinomycosis

## Treatment

A fistula may be treated either by operative or nonoperative means Most high fistulas with profuse discharge will need early surgery, while those arising from the low ileum with only minimal discharge can be followed more deliberately Closure will not occur as long as there is any persistent obstruction below the fistula, so that resection of a distal obstructing lesion may be necessary

### *Nonoperative Treatment*

Three features are important in the nonoperative treatment They are the collection of the small bowel discharge, its reintroduction into the intestinal tract, and the prevention of digestion of the skin in the area adjacent to the stoma The multitude of methods that have been described to control the discharge from the small bowel fistulas testify to the fact that no one system is entirely satisfactory The success of handling this problem depends upon the cooperation of the patient and the ingenuity of the surgeon The simplest method, perhaps, is the use of an ordinary glass douche nozzle connected to suction, which an intelligent patient may use himself to pick up the discharge as it appears. If the patient is not able to do this, the nozzle may be taped to the abdominal wall, so that the tip is approximated to

is unlikely because of the condition of the skin that usually prevails, infection, however, is not apt to be serious in the abdominal wall and good results are obtained with a delayed primary closure of the skin and fat, in forty-eight hours The danger of peritonitis from the anastomosis is negligible because these patients are somewhat immune to their own intestinal flora Any attempts at closure of well established fistulas within the abdominal wall are doomed to failure since the fixation of the edges of the bowel does not allow an adequate amount of bowel wall to turn in without tension on the suture line Consequently, the sutures cut through and the fistula soon re establishes itself

INDIRECT OPERATIVE PROCEDURE In direct operative attacks on fistulas are indicated under several circumstances Widespread infection of the abdominal wall may contraindicate an incision directly about a fistula Multiple fistulas cannot usually be encompassed in one incision In these cases an incision is made in another part of the abdomen The limbs of intestine involved in the fistulas are then identified This is often a difficult procedure and may be facilitated by the introduction of catheters through the fistulas into the bowel If possible, the limbs of intestine are then divided with the cautery and an anastomosis is performed about them The proximal ends of the fistulous bowel are turned in After this procedure, the discharge ceases from the fistula and the abdominal wall improves rapidly The excision of the remnants of the bowel originally involved in the fistula may be done at an optimum time Lesser operations such as a side to side anastomosis about the fistula, or diversion of only the proximal loop of bowel that enters the fistula are not likely to be successful Any operative procedure must, of course, take cognizance of the underlying pathologic process Thus, fistulas arising from regional ileitis can be cured only by resection of all the involved bowel or by ileocolostomy with exclusion of the terminal ileum well above the area of the disease

## NUTRITIONAL DISORDERS OF UNKNOWN ETIOLOGY

Patients with sprue and Whipple's disease may present with symptoms suggestive of small bowel disease The treatment of these conditions is primarily medical, but the diagnosis is often difficult to make on a clinical, x ray, or laboratory basis, and exploratory laparotomy may be used not only to rule out intestinal pathology such as regional enteritis or lymphosarcoma of the small bowel mesentery, but also to establish the diagnosis by biopsy of the involved bowel Sprue may also mimic acute intestinal obstruction

### Whipple s Disease

Whipple's disease, or intestinal lipodistrophy, is a rare disorder occurring predominantly in males It is considered by some to be one of the collagen diseases, while others believe it is a true metabolic disorder in the primary functions of the intestinal mucosa The symptomatology includes abdominal pain of episodic nature, diarrhea, steatorrhea, tenesmus, and emaciation At laparotomy one may find considerable chylous ascites, marked lymphadenopathy occurs in the distribution of the superior mesenteric artery and may be generalized although areas of the bowel may be uninvolved The bowel in the affected areas is thickened and laced with milky distended lymphatics running down over the mesentery On the antimesenteric surface of the involved bowel the lymphatics assume small varicose forms, and scattered milky plaques representing subserosal rupture and leakage of the chyle may be seen

### Sprue

Sprue is characterized by asthenia, loss of weight, abdominal distention, steator-

mesenteric artery embolectomy in the treatment of massive mesenteric infarction *New England J Med 257* 595, 1957

SMITH, G K Noble plication procedure Application to acute and chronic recurrent small bowel obstruction *A M A Arch Surg 70* 801, 1955

SNYDER, W H, and CHAFFIN, L Malrotation of the intestine *S Clin North America 36* 1479, 1956

TURNBULL, R B, JR Management of ileostomy *Am J Surg 86* 617, 1953

WANGENSTEEN, O W *Intestinal Obstructions Physiological Pathological and Clinical Considerations with Emphasis on Therapy, Including Operative Procedures* 3d ed Springfield, Ill, Charles C Thomas, 1955

WELCH, C E *Intestinal Obstruction* Chicago, The Year Book Publishers, Inc, 1958

ZOLLINGER, R M, and ELLISON, E H Primary peptic ulcerations of the jejunum associated with islet cell tumors of the pancreas *Ann Surg 142* 709, 1955

MEDICAL COLLEGE
LIBRARY
UDAIPUR

In patients with "Situs inversis" and acute appendicitis, the symptoms are referred to the right in 50 per cent

The appendix may be found in a femoral or inguinal hernia sac Incarceration and strangulation of the intestine within an inguinal hernia may be precipitated by perforation of an acutely inflamed appendix lying within the hernial sac Distention owing to generalized peritonitis of appendiceal origin may do the same thing

The appendix is occasionally found in locations utterly foreign to it, i e, prolapsed through a hole in the uterus made during a criminal abortion or at the end of a proctoscope inadvertently pushed through a friable sigmoid Goldstein reports rupture of the urinary bladder following fulguration of an intravesical excrescence caused by extravesical pressure of the appendix

## ACUTE APPENDICITIS

### Incidence

In the United States, appendicitis is the most frequent reason for abdominal surgery in general hospitals and second only to trauma as a cause of morbidity in young adults

Men (61 per cent) have acute appendicitis more frequently than women (39 per cent)

Acute appendicitis may occur at any age, although difficulties in diagnosis in the very young and the very old may make it appear less frequent in these ages Almost 10 per cent of the patients with acute appendicitis seen at the Charity Hospital in New Orleans were less than 10 or more than 60 years of age Acute appendicitis has been reported in an infant of three weeks by Pope The incidence increases yearly until a peak is reached about the twentieth year, thereafter to decrease slowly

### Etiology

Acute appendicitis is caused by either obstruction or infection or a combination of both

Infection may occur independent of obstruction and primary bacterial invasion with inflammation probably causes many attacks of acute appendicitis, particularly those which subside

Obstruction, either by intraluminal impaction of a fecalith or foreign body, by external constriction from a band or kink, or even perhaps by spasm of the proximal portion precipitates the majority of attacks of acute appendicitis

The etiologic role of trauma in the initiation of acute appendicitis is debatable. External trauma may, however, aggravate an already existing acutely inflamed appendix, particularly if there is an abscess

### Pathology

The pathology of acute appendicitis is similar to that of acute inflammation elsewhere

Progression of inflammation is favored by obstruction and particularly by interference with blood supply (Administration of a cathartic does both by increasing intraluminal pressure and stimulating peristalsis ) The appendix increases in size, varies in consistency, and changes its color from white, to red, to 'green,' to black as inflammation progresses

Inflammation may progress further until it extends through the muscularis to the peritoneum and the appendix may ultimately perforate The progress of the inflammation is very variable and may take days When obstruction is present, the process is hastened

### Signs and Symptoms

Pain is the outstanding symptom in acute appendicitis, it is sometimes insidious and muted, but more characteristically is definite in onset and progressive in severity In the very old, symptoms tend to be less intense

The onset is related neither to rest or physical activity, nor to eating or abstinence, nor to any other factor that we know

other reasonable diagnosis can be made and localized tenderness persists in the right lower quadrant, exploration of the abdomen is, in my opinion, almost obligatory It is more important to remove an acutely inflamed appendix prior to rup ture than to be overly conservative in laparotomy When the appendix is not in flamed, some other intra abdominal lesion best treated by surgery is discovered in a significant number and in less than one fifth of the patients so treated is the exploration "negative '

X ray examination of the abdomen is usually not helpful in the diagnosis of acute appendicitis

### *Differential Diagnosis*

Differential diagnosis of acute appendicitis encompasses the entire gamut of gas trointestinal disease In the very young, gastroenteritis and mesenteric adenitis are easily confused with appendicitis In both, nausea is apt to precede pain Tenderness tends to follow the root of the mesentery rather than being sharply localized in the right lower quadrant Characteristically the white count is within normal limits and there is a lymphocytosis rather than a shift to the left Hyperactive peristalsis is characteristically present in both and is the best differential point

Infection or obstruction to the urinary tract may simulate appendicitis Demon stration of formed elements in the urine may be helpful in diagnosis and a flat x ray of the abdomen may show a ureteral stone in those patients in whom mechanical obstruction prevents cells from appearing in the urine (Infection or dis tention of the renal pelvis may cause ileus ) Seminal vesiculitis or prostatitis may mimic appendicitis. Localized tenderness on rectal examination alone may allow differentiation

The patient with pelvic inflammatory disease tends to be more prostrate, the fever tends to be higher, the white blood count is apt to be 20,000 or more, and the sedimentation rate is usually increased Characteristically, the tenderness is low in the abdomen and frequently bilateral, but pain on both sides of the abdomen provoked by manipulation of the cervix is the best differentiation point and is almost pathognomonic of pelvic inflammatory disease The recovery of diplococci on cervical smear strongly suggests pelvic inflammatory disease but failure to find them does not rule it out at all Difficulties in differential diagnosis must be re solved by laparotomy when other methods leave doubt

Recognition of infarction of a fibroid or twisting of an ovarian cyst may depend upon palpation of the pelvic tumor on vaginal examination Rupture of a corpus hemorrhagicum is common and differenti ation is difficult Mittelschmerz may be associated with right lower quadrant pain, localized tenderness, and fever The white count may be normal

A history of gallbladder disease suggests acute cholecystitis, but if the gall bladder lies low in the abdomen or the appendix is high, it may be impossible to differentiate the two preoperatively Per foration of a peptic ulcer usually can be demonstrated by x ray When air is not present, diffuse boardlike rigidity of the abdomen suggests perforation of a peptic ulcer, but where the perforation is small and irritating fluid has drifted to the right lower quadrant, it may mimic acute appendicitis exactly Differentiation between Meckel's diverticulitis and acute appendicitis may be impossible The signs and symptoms are identical and usually only by finding an inflamed Meckel's diverticulum on exploration of the abdomen is diagnosis made This must be looked for if the appendix is not inflamed on ex ploration

The characteristic peristalsis of intestinal obstruction may help differentiation unless the patient has received morphine or atropine prior to examination Either of these two drugs will lessen peristalsis and may make differential diagnosis almost impossible

Diffuse abdominal pain, elevation in the serum amylase, and particularly recovery of serosanguineous fluid on abdominal tap all suggest pancreatitis. A sentinel

perforation and peritonitis have already occurred there has been, and continues to be, some discussion about the timing of surgery Restoration of physiologic deficits is necessary

*Choice of Anesthesia*

Either regional or general anesthesia may be used I personally prefer spinal anesthesia

*Location of the Incision*

The incision should be directly over the inflamed appendix, the exact position of which is suggested by the point of maximal abdominal tenderness (one finger) and by palpation under anesthesia The base of the appendix most frequently lies at McBurney's point which is the junction of the outer and middle thirds of a line joining the umbilicus and the anterior superior spine In infants and young children, the base of the appendix is apt to lie cephalad and the incision should be higher

*Type of Incision*

The McBurney or gridiron muscle splitting incision can be made rapidly and easily However, even when the McBurney incision is enlarged by any one of several maneuvers, the incision is still too small for adequate exploration or the removal of some technically difficult appendices In older individuals, particularly females, I prefer a transverse incision (Fig 17 1) Such an incision extended laterally is large enough to permit manual exploration of the entire abdomen and the direct access it affords facilitates appendectomy Vertical muscle splitting incisions are used with ever decreasing frequency I reserve the vertical incision for 'exploratory laparotomy' with incidental appendectomy rather than vice versa.

*Appendectomy*

If the appendix is not visible upon opening the abdomen and no mass is palpable, the lower end of the cecum should be elevated into the incision and the taenia followed to the appendix If the appendix is acutely inflamed, further exploration is omitted except to make certain that it is not part of a periappendiceal process rather than an intrinsic one Should some other disorder requiring surgery be found, it should be taken care of first, after which prophylactic appendectomy may be considered if conditions warrant

Division of the avascular peritoneal attachments between the cecum and the lateral peritoneal wall facilitates exposure and delivery of the appendix Resuturing is not necessary unless the cecum becomes mobile, when it should be held in place with interrupted sutures peritoneum to peritoneum A volvulus has been reported in a patient in whom this was not done

Exposure is gained by introduction of packs and semicircular retraction of abdominal contents away from the tip of the appendix Should even more exposure be needed, the appendix may be divided at its base, the stump secured and the cecum replaced within the abdomen This gives more usable space in the incision Appendectomy is also facilitated by division of mesentery and peritoneal adhesions from above down, with ligation of each segment of tissue as soon as it is divided, otherwise the incision will become so filled with hemostats that further manipulation is impossible

Should friability of the mesentery make hemostasis difficult, bleeding can be controlled with a continuous over-and over hemostatic suture of No 00 chromic catgut on an atraumatic needle Tension on the suture will elevate the bleeding point, too, so that it can be seen and sutured more readily Continuous aspiration by an assistant is essential

The base of the appendix is crushed, divided, and sterilized with phenol or the cautery, and the appendix discarded The stump of the appendix is then ligated and dropped, ligated and inverted, or inverted without ligation If the stump of the appendix is not peritonealized by inversion, some other viscus including the small intestine may become attached to it and intestinal obstruction result Although such

distance back from the appendix and then to roll the whole indurated mass into the mesentery of the terminal ileum, keeping it there with a few interrupted sutures Drains are *not* placed down to this area and in my experience there have been no fecal fistulas

Intraperitoneal drainage is used only when necrotic or gangrenous tissue has been left behind or a definite walled off abscess has been entered Subcutaneous drainage down to a tightly closed peritoneum has been used frequently On occasions, the subcutaneous tissues have been left completely open and then closed secondarily in a few days Intraperitoneal drainage, when used is led out through the outer edge of the incision or preferably through a stab wound directly over the area drained

Omentum enveloping the acutely inflamed appendix is amputated rather than peeled away so that an abscess if present, is not spilled into the general peritoneal cavity

Prior to closure of the abdomen a spooge and lap count is made and the appendiceal area is inspected again to make certain that hemostasis has been complete Vessels that do not bleed under traction may do so when the cecum is replaced within the abdomen and final inspection is desirable

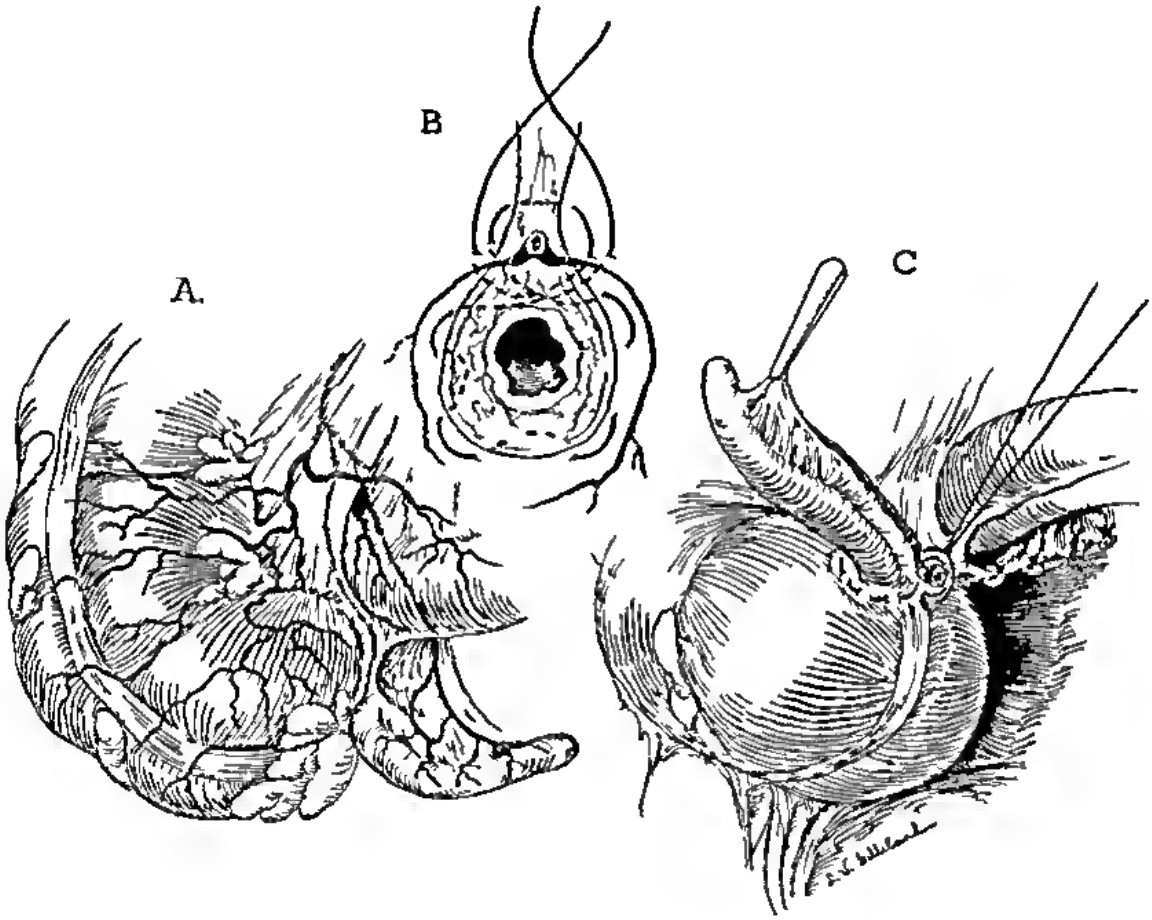


Fig 17 2 (*A*) Vascular supply of the appendix (*B*) An extra loop of suture is placed around the appendical artery to secure it as the purse string suture is introduced (*C*) Same as *B* above

## Treatment of Patients with Appendiceal Peritonitis

Local peritonitis owing to contiguous spread is of little significance and such patients are best treated by immediate appendectomy Patients with perforation of the appendix and generalized peri

early diagnosis and treatment The diagnosis in the extremes of life is difficult. In infancy the history is indefinite or absent and physical findings obscured by the apprehension and crying of the patient Rectal examination, however, may be more revealing than in adults, and should not be omitted Older patients seem less sensitive to pain and become so conditioned to vague aches and pains, including abdominal distress, that they temporize, and so occasionally do their physicians, until perforation makes the diagnosis clear Under these circumstances abdominal pain not inconsistent with appendicitis should be considered acute appendicitis until proved otherwise, and exploratory laparotomy should be used frequently in the extremes of life

## CHRONIC AND RECURRENT APPENDICITIS

Resolution of inflammation of the appendix may leave no trace of its presence More frequently there is scar tissue varying from slight fibrosis of submucosa to replacement of a part or all of the appendix with obliteration of the lumen

These changes, particularly stenosis of the lumen favor recurrence Ten per cent of the patients with appendiceal peritonitis treated conservatively had recurrence of acute appendicitis within six months of their peritonitis and almost 50 per cent *had recurrent acute appendicitis within* five years We recommend removal of the appendix during the quiescent stage in all patients who have had appendiceal peritonitis Since it requires three months for maximal resolution of inflammation to occur, this interval is allowed to elapse prior to interval appendectomy Should symptoms occur before three months have elapsed, immediate appendectomy is done Patients who have recovered from one episode of appendiceal peritonitis either because of adhesions or increased resistance to bacteria tend to do well in a second episode

While recurrence of acute appendicitis is an established clinical fact, "chronic" appendicitis is controversial Lymphoid tissue is abundant in the appendix and the presence of lymphoid tissue and histologic variations in nerve fibers has been used in support of the concept of 'chronic' appendicitis This may explain the chronic discomfort in the right lower quadrant of which some patients complain Relief of such pain has followed appendectomy Diagnosis is not always easy So many other conditions of the genitourinary and reproductive systems, of the gastrointestinal tract, and of the bones and joints, as well as all the psychosomatic complaints of personality and minor psychiatric difficulties may simulate chronic appendicitis so exactly that the diagnosis of chronic appendicitis has fallen into disrepute Indeed the diagnosis of "chronic appendicitis' has come to be considered evidence of 'unnecessary' surgery by some tissue committees Yet patients with chronic severe abdominal pain need every diagnostic aid Should diagnosis remain indeterminate, exploratory laparotomy is not only justified but also prudent During this diagnostic laparotomy, incidental appendectomy is proper Removal of a 'chronic" appendix without exploration is to be deplored In the patients in whom relief does not follow, diagnosis remains uncertain and neither patient nor physician is certain that some other lesion does not remain within the abdomen

## *CYSTS AND NEOPLASMS OF* THE APPENDIX

Cysts and neoplasms identical to those found in the colon also occur in the appendix The most frequent of these is a carcinoid Such tumors are found with a frequency in proportion to the extent of microscopic examination with a maximum of 0 2 per cent. They occur characteristically as a drumstick shaped yellow tumor at the tip of the appendix Carcinoids of the appendix rarely if ever metastasize or produce serotonin, in contradistinction to those found in the small intestine or elsewhere in the gastrointestinal tract

Mucocele of the appendix is said to be due to obstruction of the lumen of the

CHAPTER 18

# PRIMARY TUMORS OF RETROPERITONEUM, MESENTERY, AND OMENTUM

*Shaun Purdy Holman and Emile F Holman*

## TUMORS OF THE RETROPERITONEUM

### Definition

The retroperitoneal space extends from the thoracic diaphragm above to the brim of the true pelvis below, at the level of the base of the sacrum and iliac crest, and lies between the posterior peritoneum in front and the muscles of the abdominal wall behind Its lateral margins are the peritoneal leaves of the intra abdominal mesenteries, corresponding to the lateral borders of the quadratus lumborum muscles While the retroperitoneal space actually includes the pancreas, duodenum kidneys, ureters, abdominal aorta, and inferior vena cava, tumors from these organs are not usually classified as retroperitoneal tumors" Consideration here is restricted to those tumors which are contained in the potential retroperitoneal space, namely, fat, muscle, blood vessels, lymphatics, nerves and their ganglia, and fibrous connective tissue In so doing, we agree with Herdman's definition of retroperitoneal tumors as 'those tumors, solid or cystic, found in the retroperitoneal space, but having no anatomical connection with any of the organs in that region Various types of malignant lymphoma, though manifestations of generalized disease, may be most conspicuously present in the retroperitoneum, and will be included without further concern whether or not they are primarily of retroperitoneal origin

### Incidence

Primary neoplasms of this potential space are relatively rare However, if renal and adrenal tumors are added to the classification, retroperitoneal growths form the most frequent abdominal tumor of childhood

### Classification

Neoplasms of the retroperitoneal space fall into one of three broad categories (1) primary tumors (unattached), (2) tumors arising in organs normally present in the retroperitoneal space, and (3) primary or metastatic tumors involving the retroperitoneal lymph nodes

Primary tumors may be benign or malignant, solid, cystic, or a combination of the two, and single or multiple. Most of these are believed to arise from embryologic remnants of the urogenital tract, but they can and do arise from the intrinsic

gin, with interference of both motor and sensory function of the lower extremities, sphincters, and genitalia

Hematologic abnormalities are inconstant and nonspecific. Laboratory studies have been of little value except in special tumors such as heterotopic adrenal cortical tumors, pheochromocytomas, and the lymphomata

Table 18-2. Malignant Retroperitoneal Tumors in Laboratory of Surgical Pathology, Columbia University, 1905 to 1951 Inclusive*

| | *Retroperitoneal* | *Mesenteric* | *Omental* |
|---|---|---|---|
| Sympathicoblastoma | 18 | | |
| Malignant schwannoma | 3 | | |
| Lymphosarcoma | 51 | 2 | 2 |
| Hodgkin's disease | 26 | | |
| Plasmocytoma | | 1 | |
| Leukemia | 2 | | |
| Fibrosarcoma | 4 | 6 | |
| Liposarcoma | 35 | 2 | 2† |
| Leiomyosarcoma | 29 | 2 | 4 |
| Hemangiopericytoma | 18 | 1 | 2 |
| Rhabdomyosarcoma | 5 | | |
| Mesenchymoma | 5 | | |
| Myxoma | 3 | | |
| Teratoma | 6 | | |
| Embryonal carcinoma | 24 | | |
| Suprarenal cortical carcinoma | 1 | | |
| Metastatic carcinoma of unknown origin | 13 | | |
| Malignant melanoma (metastatic) | 1 | | |
| Chordoma | 2 | | |
| Dysgerminoma | 1 | | |
| Undiagnosed tumor | 18 | 1 | 4 |
| Total | 265 | 15 | 14 |

* From Ackerman L V "Tumors of the Retroperitoneum, Mesentery, and Omentum" *Atlas of Tumor Pathology*, Sect. VI, Fasc. 23 & 24 Washington, Armed Forces Institute of Pathology, 1954

† Three more attached to kidney capsule

## Diagnosis

Definitive diagnosis usually awaits surgical exploration and microscopic studies, but radiography has been of great value in defining the tumor. Extraperitoneal pneumography, as introduced by Ruiz Rivas in 1947, consists of injecting gas, preferably oxygen, into the areolar tissue between the rectum and sacrum and allowing the gas to spread throughout the extraperitoneal tissue. The technique has been particularly useful in detecting diseases of the adrenal gland. Abdominal aortography has been used to differentiate renal from extrarenal tumors, and to determine the malignancy of renal neoplasms Arteriography, pyelography, both intravenous and retrograde, barium swallow, and barium enema have all been used in the demonstration of retroperitoneal tumefaction imposing upon adjacent viscera and disrupting the normal intra-abdominal geography. We include films (Fig 18-1, 18-2) of a greatly displaced sigmoid colon, and a small but obvious deformity of the left ureter imposed by extrinsic, retroperitoneal neoplasm.

## Treatment

Prompt and complete surgical extirpation followed by immediate, adequate postoperative radiation is the desired treatment of most retroperitoneal tumors. Preoperative determination of the limits of the neoplasm may be suggested by the

Fig 18-1 Displacement of sigmoid colon by a malignant retroperitoneal schwannoma

roentgenographic studies, but final judgment depends upon exposure of the tumor and its gross examination, aided by frozen section studies The surgeon should be prepared to interrupt the ureter and large blood vessels, including the aorta and vena cava, and possibly replace them, to facilitate complete extirpation of the tumor Incomplete removal may occasionally bring striking palliation, particularly if the tumor is radiosensitive For this reason, histologic diagnosis at the time of surgery is important

Fortunately the majority of retroperitoneal tumors are radiosensitive and will respond to radiation therapy

## Prognosis

The prognosis of malignant retroperitoneal tumors like that in any other part of the body, depends upon early diagnosis and adequate treatment. Since diagnosis often awaits accidental discovery of the mass because of its size or interference with neighboring structures, the tumor is far advanced when first discovered and the prognosis is ominous In benign retroperitoneal tumors, technical difficulties may prevent complete removal and local recurrence with mechanical interference with vital function may present formidable problems.

Fig 18-2 Displacement of left ureter by retroperitoneal sarcoma

## TUMORS OF THE MESENTERY AND OMENTUM

### Characteristics

Primary tumors of the mesentery and omentum have their origin in peritoneal endothelium (very rare) in mesothelium in blood and lymph vessels and in the connective and nervous tissue of these structures. They are usually slow growing and do not give rise to symptoms until they attain a large size They may be benign or malignant Of the benign variety, cystic tumors are more common than solid and include lymphangiomata, hemangiomata and hemorrhagic cysts The commonest solid tumor is the lipoma, fibromata, ganglioneuromata leiomyomata, and desmoid tumors have been described

Although the commonest malignant tumors of the omentum and mesentery are metastatic, arising in the stomach, colon, pancreas and ovaries only primary neoplasms are under consideration here Liposarcomata and fibrosarcomata, of exclusively mesodermal origin, are the

commonest primary malignancies Occasionally a carcinoma or teratoma, arising from embryonal rests, is encountered

## Treatment

Treatment consists of complete extirpation, if possible, with resection of intestine when necessary because of direct extension of tumor into the bowel wall, or because removal of the primary tumor will interfere with blood supply to the involved segment Solitary cystic tumors may be enucleated, or, if the tumor is large or multilocular, marsupialization may be preferred Postoperative irradiation, particularly when the tumor has not been completely resected, may improve the results The intraperitoneal instillation of colloidal gold, and more recently of chromic phosphate, is credited with relieving ascites in slightly more than half the patients to whom it is given Finally, the intravenous administration of colloidal metallic salts hormones, and folic acid derivatives is said to give beneficial results

## REFERENCES


Ackerman, L. V 'Tumors of the Retroperitoneum, Mesentery, and Omentum *Atlas of Tumor Pathology*, Sect VI, Fasc 23 and 24, Washington, Armed Forces Institute of Pathology, 1954

Cosotlow, W E, and Wisdom, W R. Radiation therapy in retroperitoneal tumors *A M A Arch Surg 70* 199, 1955

Donnhauser, J L, and Bigelow, N H Primary retroperitoneal tumors *A M A Arch Surg 71* 234, 1955

Dorfman, R I, Hertz, R, and Kirschbaum, A Symposium on hormones and cancer therapy *Am J Med 21* 659, 1956

Engel, W J Classification of retroperitoneal tumors as a guide in clinical diagnosis *A M A Arch Surg 70* 156, 1955

Jaffe, H L. Treatment of malignant serous effusions with radioactive colloidal chromic phosphate *Am J Roentgenol 74* 657, 1955

Klingerman, M N, and Habif, D V The use of radioactive gold in the treatment of effusion due to carcinomatosis of the pleura and peritoneum *Am J Roentgenol 74* 651 1955

Steinbach, H L, and Smith, D R Extraperitoneal pneumography in diagnosis of retroperitoneal tumors *A M A Arch Surg 70* 161, 1955

Tidrick, R T, and Goldstein, M S Surgical treatment of retroperitoneal tumors *A M A Arch Surg 70* 203, 1955

Toennies, G, Frank, H G, and Gallant D L Blood folic acid activity of normal humans, cancer patients, and non-cancer patients *Cancer 9* 10, 1953

CHAPTER 19

# NEOPLASMS OF THE COLON

*Joel W Baker and George Hugh Lawrence*

The discriminate selection of the surgical approach to tumors of the colon depends upon a knowledge of their pathologic behavior The anatomic extent of bowel resection must be responsibly selected in full recognition of a spectrum of biologic propensity which extends from that of the usually benign adenoma and the sometimes metastasizing carcinoid to the malignant adenocarcinoma The ideal resection must furthermore be adapted to the patient in recognition of individual limitations imposed by coexistent disease, body habitus, and the secondary effects of the tumor itself The apparent advantages obtained by early diagnosis must be reinforced by these basic considerations, for cancer in this area may be cured in over half of all cases This rate of survival is approximately double that for such equally prevalent carcinoma as that occurring in the lung or stomach At the same time, excepting carcinoma of the rectum, the surgical resection is unaccompanied by any significant alteration in normal function or appearance

## BENIGN TUMORS

### Adenomatous Polyps

#### *Pathology*

Polyps constitute the commonest benign tumors of the colon Attempt at rigid classification is clinically impractical Several histologic types may be seen in the same polyp More important considerations lie in their number, their gross configuration, and of greatest importance is their ability to invade and metastasize The etiology of these lesions is unknown It is postulated by Dukes that they arise in the deep, glandular, epithelial cells of the crypts of Lieberkuhn in the intestinal mucosa Their number varies from single or multiple polyps to the diffuse involvement of familial polyposis with the inevitable development of malignancy in the latter The differentiation between a sessile or pedunculated polyp is of less practical importance in the colon than in the rectum, especially in view of the low incidence of the more malignant papillary or villous polyp above the rectosigmoid level Microscopic evidence of malignancy in the polyp is based upon the histologic evidence of intraglandular budding, stratification of the lining cells, and loss of nuclear polarity in the epithelium itself, but these often subtle changes assume true significance when associated with invasion into the muscularis mucosa

Evidence accumulated by Dukes, Helwig, and others provides good indication that these polyps or adenomata are precursors of colonic carcinoma The distribution of polyps in the various portions of the colon corresponds to that of carcinoma (Table 19 1) Likewise the racial and sex variations in the incidence of

TABLE 19-1 DISTRIBUTION OF POLYPS AND CANCER OF THE COLON*

| | *Polyps, autopsy studies* (%) | *Cancer, clinical findings* (%) |
|---|---|---|
| Rectum and sigmoid | 66 | 61 |
| Descending colon | 10 | 5 |
| Transverse colon and flexures | 19 | 13 |
| Ascending colon and cecum | 8 | 11 |

* Stone C S., Banamer G and Conroy W The significance of adenomatous polyps of the colon and rectum and their behavior pattern *Bulletin of The Mason Clinic* 11 100 1957

carcinoma of the colon parallels the same variations in the incidence of polyps There is abundant histopathologic proof to substantiate the transition of adenomatous polyps into cancer While the incidence of both carcinoma and polyps increases with age, there is an apparent time lag between the peak incidence of the two lesions indicating the evolution of one into the other (Fig 19-1)

*Diagnosis*

Recognizing the malignant potentiality of polyps, the responsibility for their discovery becomes an important consideration to the clinician While most colonic polyps are relatively asymptomatic, they may be heralded by rectal bleeding or crampy abdominal pain Sigmoidoscopy should be considered a part of the complete physical examination In a sampled series of sigmoidoscopic examinations at The Mason Clinic, adenomatous polyps were found in 5 3 per cent of 2,793 patients and of these polyps 14 per cent were malignant Those lesions lying beyond the reach of the sigmoidoscope are best identified by contrast air-barium enema technique and this should be repeated when an explanation of suggestive symptoms is not found Too often the roentgenologist is given insufficient information to arouse his diagnostic zeal above the level of a routine monotony If he is told that the sigmoidoscopic examination showed bloody mucus above the reach of the instrument, it becomes

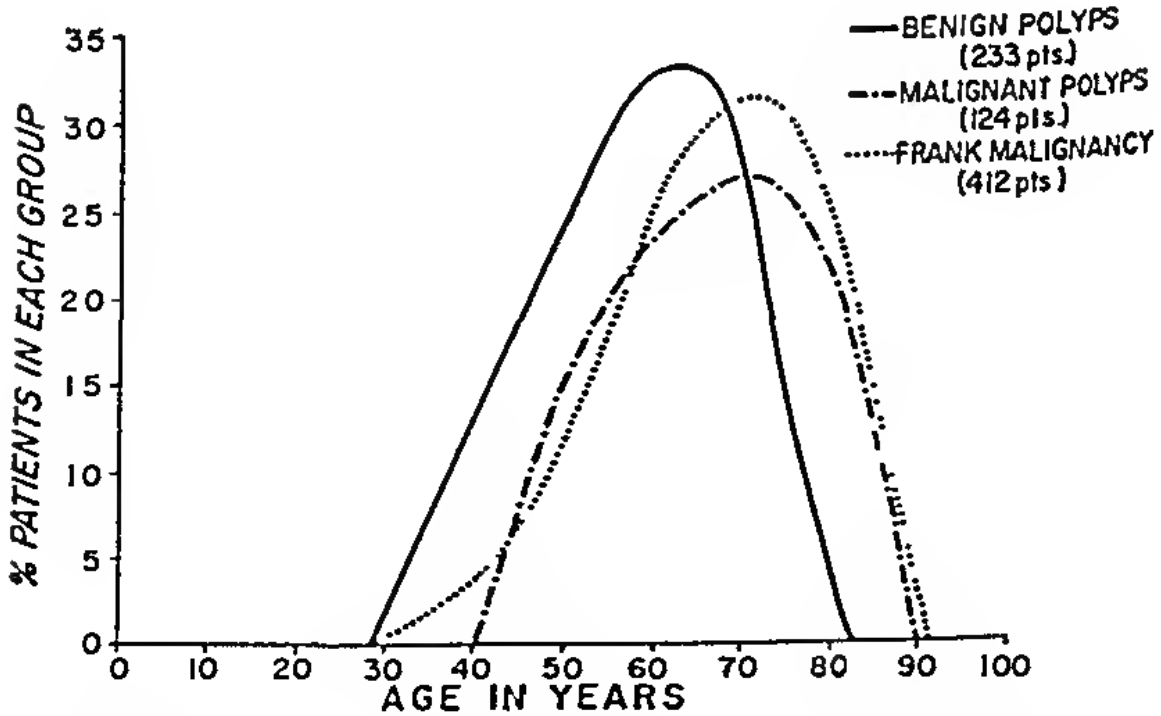


Fig 19-1 Incidence of carcinoma and polyps determined by age at time of diagnosis 760 patients

his responsibility to prove its source The air contrast method of x ray examinations reveals those lesions which would be otherwise concealed by the dense opacity of a barium filled colon Following evacuation of barium, air is introduced to distend the colon so that the semitranslucent barium covered polyp may be demonstrated lying free in the air filled colon The detailed perfection of the technique of this examination and the patient s preparation cannot be overemphasized This study is especially indicated following the finding of rectal polyps or carcinoma by sigmoidoscopy

*Treatment*

While the long pedicle of a polyp may seem to provide good protection against local recurrence, it does not guarantee freedom from lymphatic metastasis This important point has been illustrated by Scarborough, Welch, and others Treatment, therefore, must be directed toward not only the local lesion but also the underlying mesentery Another characteristic of mucosal polyps is their multiplicity Satellite polyps have been encountered in 30 per cent of cases at The Mason Clinic, an incidence similar to that reported in

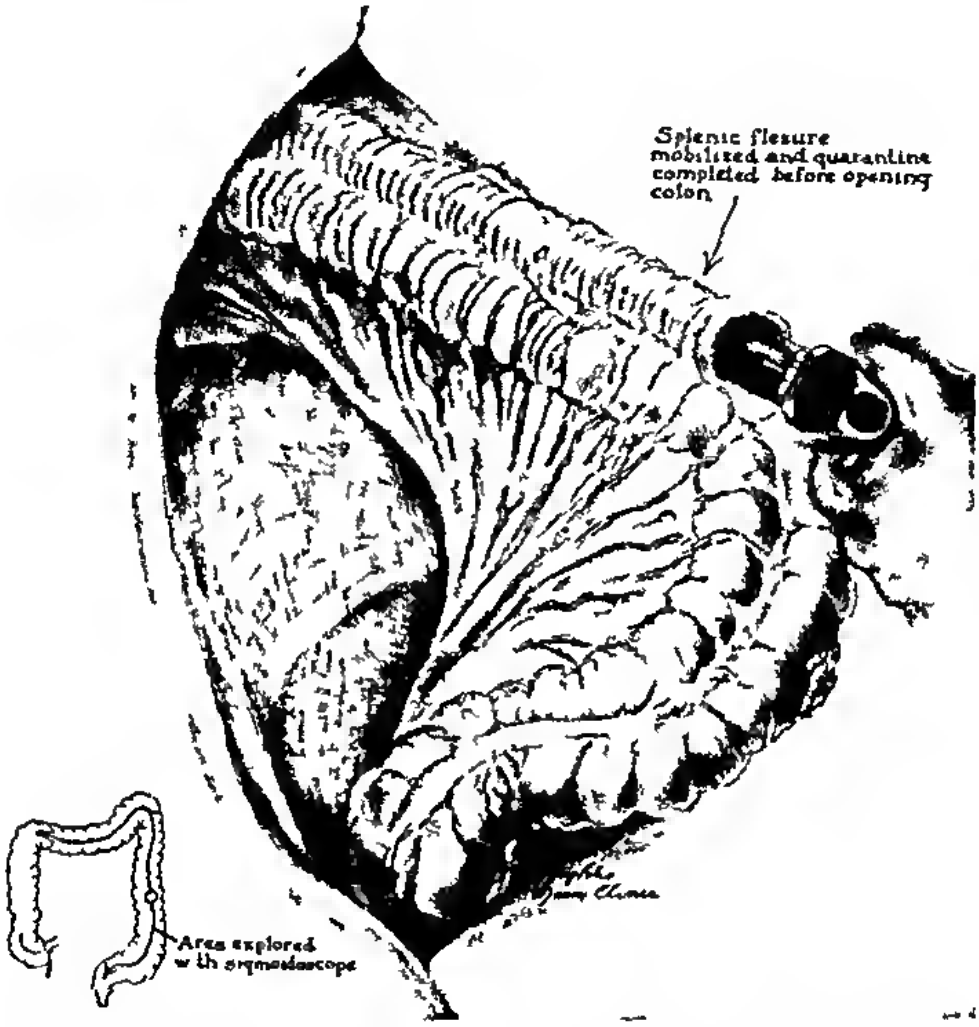


Fig 19 2 At operation the colon is endoscoped over to the hepatic flexure in search of secondary polyps This becomes of particular importance if the ideal of total left colectomy is not achieved (*From* Baker, J W The distal and proximal margin of resection in carcinoma of the pelvic colon and rectum *Annals of Surgery 141*:693, 1955 )

other series For this reason, endoscopy of the proximal and distal regions of the colon at the time of colotomy is of value The roentgenologist cannot be relied upon to discover the small budding satellite polyp Prior to deciding upon sleeve resection, the operative field is carefully quarantined and the prepared bowel is opened and endoscoped as illustrated in Figure 19 2 Not only must an adequate margin of surrounding bowel be removed but also at least the first zone of underlying lymph nodes must be resected and examined for metastasis (Fig 19 3) As the commonest site of predilection for polyps is in the sigmoid, resection of the redundant sigmoidal loop removes that portion of the colon where recurrent polyps are most likely and also permits subsequent inspection of the descending colon by office sigmoidoscopy Should one be faced with several polyps in separated portions of the colon, he must carefully consider the necessity of a more radical colectomy, realizing the potentiality of the intervening mucosa to develop new growths In the exceptional case, impaired surgical risk or technical factors may lead the surgeon to abandon the ideal resection of bowel and mesentery in favor of simple colotomy with excision of the polyp and fulguration of its base When one is forced

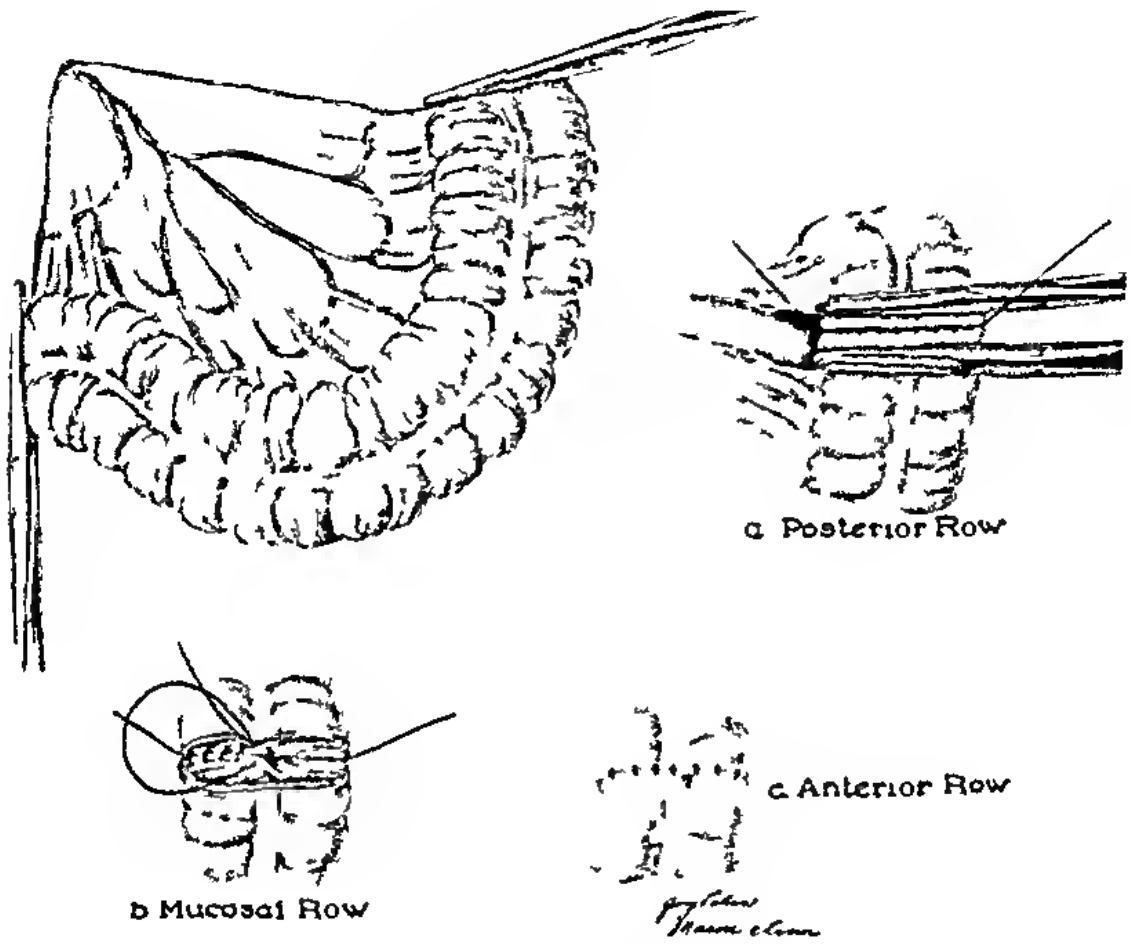


Fig 19 3 Technique of partial segmental colectomy for polyps with end-to-end anastomosis A wedge shaped resection of the first zone of mesenteric lymphatics is included The anterior and posterior rows of the anastomosis are made using No 3-0 interrupted silk (*a* and *c*) A *running No 3-0 chromic catgut suture is used for the mucosal layer (b)* It is tied at both corners to prevent purse-string narrowing of the lumen

to select this lesser procedure, the services of a pathologist experienced in frozen section interpretation is necessary to rule out malignant change

At laparotomy recognition of the exact site of the polyp may prove difficult and lead to a vexing dilemma Attention to the preoperative radiographic localization plus endoscopy via colotomy will usually prove rewarding where the lesion cannot be palpated and where stripping fails to produce dimpling on the antimesenteric serosal surface Transillumination has also been employed as an aid in this search but it cannot be depended upon for discovering the small polyp

FAMILIAL POLYPOSIS—PEUTZ-JEGHERS SYNDROME Two heredofamilial types of polyposis are of particular importance Both are inherited through the Mendelian dominant genes and may sporadically affect members of a given family but usually are transmitted only by those manifesting the disease Familial intestinal polyposis is a hereditary disease characterized by the development within the colon and rectum of large numbers of adenomatous tumors While these polyps are not histopathologically different from single adenomatous polyps, their development into malignant carcinoma is probable Total colectomy and ileoproctostomy followed by frequent proctoscopic examination of the residual rectal stump with diathermic removal of any recurring polyps is the treatment of choice prior to the development of malignancy As Dukes has postulated, total colectomy and permanent ileostomy is indicated in those cases with overt or suspected carcinoma in the rectosigmoidal area In those cases who have developed the malignant degeneration of a polyp above the area of the rectosigmoid, preservation of the rectum and ileoproctostomy may be justified The importance of very frequent proctoscopic examination of the remaining rectum cannot be overemphasized In the less responsible patient, the initiative of automatic notification of the patient might well be assumed by the physician All blood relatives of the patient should be sought and investigated This will usually result in the discovery and protection of others so affected

More recently the Peutz-Jeghers syndrome of multiple polyposis of the gastrointestinal tract associated with melanin pigmentation of the mucocutaneous area has attracted attention The *sine qua non* clinching the diagnosis is the finding of brown pigmented buccal mucosal lesions in a patient with crampy abdominal pain often associated with chronic melena and anemia In addition to the small and large bowel, which are the primary sites of predilection for the polyposis, coincident polyps may be found in the stomach Surgical excision should be directed toward those identified colonic lesions which could conceivably undergo malignant degeneration and also to those lesions of the small intestine or stomach which are causing blood loss, pain, or intussusception

## Other Benign Tumors of the Colon

*Benign lymphomas* consist of a proliferation of lymphoid tissue in the mucosa producing an often minute polyp They are found in the sigmoid and lower rectum and if confined to the mucosa are usually benign *Lipomas*, usually solitary, are located in the submucosa, often in the area of the ileocecal valve Excision is required for diagnosis but also when they are associated with intussusception or chronic blood loss Lipomatous infiltration in the region of the ileocecal valve may be the source of unexplained gastrointestinal hemorrhage as documented by Seabrook The radiologist should be alerted to this possibility when searching for the source of bleeding *Endometriomas* may produce obstruction as they undergo sclerosis, particularly in the rectosigmoid at the level of the uterosacral arch Occasionally, they may bleed at the time of the menses Short of obstruction or bleeding, it may not be necessary to resect the rectal involvement. *Leiomyomas* arise in the muscularis mucosae and in the true muscle coat of the bowel, and on occasion may produce a pedunculated tumor as they

grow into the lumen More commonly ulceration occurs over their luminal surface and produces hemorrhage *Reduplication of the bowel and hemangiomata* are rarer in occurrence Simple excision of these benign tumors with a sleeve of bowel and adjacent mesentery is all that is indicated

## MALIGNANT TUMORS OF THE COLON

### Occurrence

In the usual hospital population carcinoma of the colon ranks with carcinoma of the stomach as the commonest malignant neoplasms of the gastrointestinal tract with 16 5 per cent of all cancer deaths resulting from cancer in the extra rectal colon It may occur from the second to eighth decade, those patients under the age of thirty five having an extremely grave prognosis In general, of all malignancies of the large bowel approximately half occur in the rectum below the peritoneal reflection one quarter occur in the sigmoid colon with the remainder distributed equally in the ascending transverse and descending colon (see Table 19 1)

ETIOLOGY As in cancer elsewhere the exact cause of cancer of the colon is unknown As previously mentioned, there is abundant evidence indicating the importance of polyps in the development of carcinoma To support this evidence is the finding at The Mayo Clinic of a 30 per cent incidence of satellite polyps in cases of colonic carcinoma Helwig in autopsy studies found a 50 per cent incidence of satellite polyps in patients with colonic carcinoma Pre-existing long-standing *inflammation* may be a *factor* in the later development of cancer of the colon for while there is no increased incidence in diverticulitis the incidence in chronic ulcerative colitis is increased and its occurrence in these patients is at a younger age Colcock states that of those patients having *chronic ulcerative colitis* for a few years or longer one of three develops carcinoma Approximately one quarter of all patients with carcinoma of the colon have a family history of the disease and this is after excluding those with true familial polyposis in which approximately half of the children seem to inherit the abnormality

### Pathology

ADENOCARCINOMA Approximately 95 per cent of all tumors of the colon are classified as *adenocarcinoma* Adenocarcinoma may arise from a pre existing adenoma or polyp or directly from the mucosa as demonstrated by Helwig A rigid classification of these lesions serves little practical significance save where the variants have gross or microscopic distinctions that implicate a divergent clinical course and prognosis, such as the colloid or mucous secreting carcinoma with its extremely grave outlook The two commonest methods of estimating the degree of malignancy of the adenocarcinoma are that of Dukes based on the penetration into the bowel wall and the presence of nodal metastases, and that of Broders based on the histologic content of differentiated as compared to undifferentiated cells A combination of these two methods serves as the best guide for estimating the prognosis The majority of colonic lesions fall into the two lower grades of cellular anaplasia, grow slowly, and metastasize distantly late in their course Extremely large tumors, often with a papillary component, may not be associated with metastasis and may, therefore, still have a good prognosis In general, tumors located in the rectosigmoid area have a slightly poorer prognosis than in the right colon and are associated with a higher degree of cellular anaplasia

Cancer of the colon disseminates by *lymphatic, venous,* and *perineural* channels as well as by *local implantation* and *direct extension* Vascular metastases occur most commonly in the liver and lung occasionally in the thyroid or adrenal and more rarely in the kidney and spleen Direct extension may involve the bladder,

ureter, sacrum, duodenum, and pancreas as well as the pelvic adnexa in the woman While longitudinal spread along the wall of the bowel is rarely greater than 5 cm, the majority of tumors have spread through all muscle layers by the time the patient is operated upon Less than 4 per cent of tumors that have not extended through the muscle wall will have positive nodes while of those that have invaded the muscle, Gilchrist has found approximately half to have lymphatic metastases It may be difficult to determine grossly whether a given node contains tumor, but the error is small if the nodes appear negative Of all resectable tumors, roughly two thirds may be expected to have lymph node involvement as shown by Coller A useful adjunct to the pathologist may be the introduction into the submucosa near the tumor of sky blue dye prior to its resection This dye will be picked up in the adjacent lymph nodes and provide a more ready and practical identification of them than may be obtained by the painstaking clearance methods Without resort to special techniques or painstaking search by the pathologist, involved nodes may be missed and the prognosis therefore erroneously classified

Lymphatic metastases usually follow a predictable pattern Once a node is involved by tumor, embolic spread to adjacent nodes occurs through collateral lymph channels On occasion there may be skip areas of normal nodes between the primary lesion and the involved nodes In general, the metastasis is upward in the direction of the lymph flow In a small percentage of cases, as pointed out by Gilchrist, retrograde metastases may occur below the level of the tumor when the proximal lymphatic pathways have been blocked by tumor This has been demonstrated to occur up to 5 cm below the tumor Both of these facts justify wide en bloc excision of the primary lesion and its mesentery Conveniently, in planning surgical excision of the lesion one may remember that lymphatic channels accompany the principal venous drainage for a given region

Less common than lymphatic invasion is perineural involvement This has been correlated with the degree of cellular anaplasia and local recurrence Venous invasion occurs with about the same frequency as perineural involvement or roughly in one fourth of the cases of colonic carcinoma Nerves and veins are seldom invaded before the primary tumor has invaded the muscle wall

More recently, attention has been directed by Cole and others to local implantation at the site of anastomosis and to the appearance of tumor cells both in the free bowel lumen and the systemic circulation Cole and others have demonstrated the occurrence of viable malignant cells in both the proximal and distal bowel in approximately half of cases and have recommended occlusive ligatures about the bowel so as to isolate the tumor prior to surgical manipulation He believes the presence of these viable cells may be correlated with the 10 per cent local recurrence rate at the suture line The presence of viable tumor cells in the peripheral circulation has likewise led to the adoption of ligature control of venous outflow prior to manipulation of the tumor (Fig 19-4)

CARCINOID TUMORS These constitute roughly 2 per cent of malignant tumors of the large bowel The commonest site of these argentaffin cell tumors is in the appendix, approximately three fourths of all carcinoid malignancy being reported in this location At The Mason Clinic in the past seven years, twelve of twenty-five carcinoid tumors occurred in the appendix In the course of the usual exploration at the time of laparotomy, it is easy to overlook the small asymptomatic carcinoid Two such lesions were recently discovered in the terminal ileum in the course of exploration prior to cholecystectomy Ninety per cent of all carcinoids occur either in the appendix, the terminal ileum, or cecum, and the remainder may arise anywhere along the gastrointestinal tract, including the rectum The malignant nature of carcinoid tumors has been reemphasized by Pearson, who has demonstrated that roughly one third of these

tumors metastasize While spread from appendiceal lesions are rare, metastases do occur although less commonly than elsewhere, possibly owing to the early apprehension of these lesions following appendiceal obstruction and acute appendicitis In the authors' experience, three cases exhibited metastasis to the mesoappendix and yet on extended resection of the right colon and its mesentery no further metastasis was found Metastasis from carcinoid tumors of the colon occurs to the regional lymph nodes to the liver, and rarely to other viscera Extension into and along the serosa is often more apparent than into the mucosa, with resulting puckering of the surface of the bowel contracture of the mesentery, and adherence to other loops of bowel The clinical picture may be that of chronic, slowly progressive, or recurring obstruction with cramps and eventual weight loss Because of minimal or late mucosal involvement, x ray examination may miss the lesion The diagnosis should be entertained in unexplained chronic intestinal obstruction, even without weight loss

When carcinoid is extensive it may be associated with a syndrome of cutaneous flushes, cyanosis, respiratory distress, and valvular heart disease Thorson *et al* have suggested that the syndrome might be due to production and release of serotonin (5 hydroxytryptamine) by the tumor Serotonin has a potent pharmacologic effect on the smooth muscle of blood vessels bronchi, and intestine Serotonin is apparently derived from the essential amino acid tryptophane The end product of serotonin metabolism is 5 hydroxyindol acetic acid which is excreted in the urine and may serve as a quantitative index of an increase in serotonin production by the carcinoid tumor In patients with carcinoid

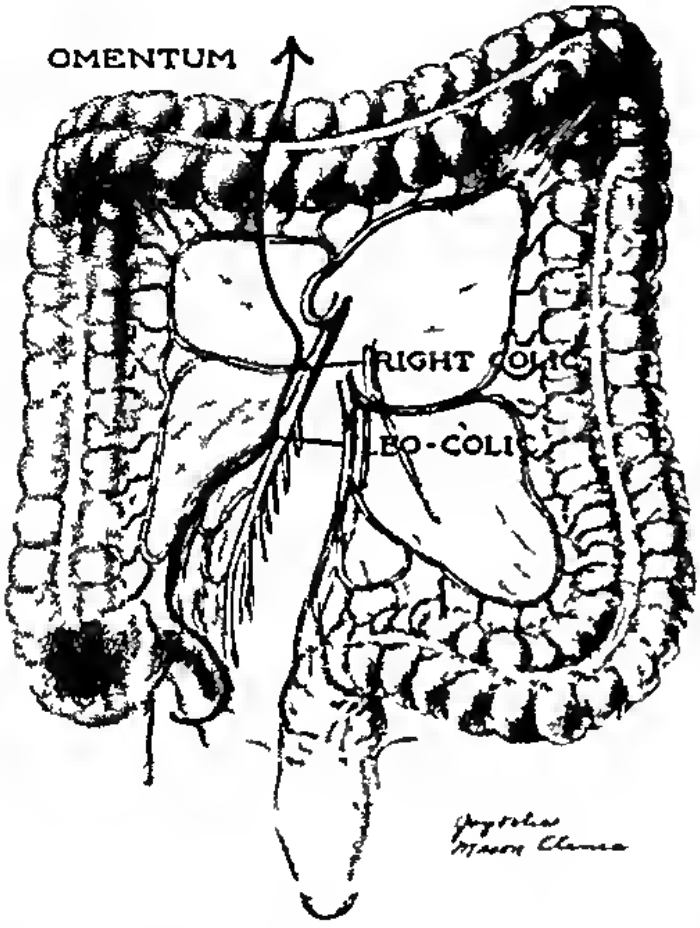


Fig 19-4 Carcinoma of the cecum The extent of resection is indicated by the shaded area The resection should include the omentum in the area of the hepatic flexure as well as the entire mesentery up to the ileocolic vessels

tumor, as much as 60 per cent of ingested tryptophane may be diverted to this metabolic pathway as compared to the usually small amount of approximately 1 per cent of tryptophane that is converted into serotonin in the normal individual This increased utilization of tryptophane by the carcinoid tumor may produce a deficiency of that essential amino acid Since elevated urinary serotonin excretion usually occurs only in the presence of liver involvement or after extensive mesenteric metastasis the measure of excretion has not proved as clinically helpful as it is scientifically interesting In view of the malignant nature of carcinoid particularly in the extra appendiceal lesion the extent of resection should follow that suggested for adenocarcinoma In the appendiceal lesion one may be guided by the gross extent of the lesion nevertheless recognizing that this lesion likewise may occasionally metastasize

LYMPHOSARCOMA This occurs less frequently in the colon than elsewhere in the gastrointestinal tract save for the duodenum and is often associated with the generalized involvement of malignant lymphomas including peripheral adenopathy The lesions may form large asymptomatic polypoid masses located submucosally Ulceration may produce massive hemorrhage Surgical resection wherever feasible should be carried out and supplemented by radiotherapy Radiotherapy or chemotherapy is indicated in unresectable lesions

OTHER MALIGNANT TUMORS *Leiomyosarcoma fibrosarcoma* and *angiosarcoma* occur with such rarity as to only deserve mention *Sacrococcygeal chordoma* may involve the rectosigmoid area causing extrinsic obstruction and later mucosal ulceration X rays usually reveal sacral destruction Local resection may prove impossible and proximal decompressive colostomy may prove necessary in this locally invasive but seldom metastasizing tumor Biopsy of the irresectible frank malignancy should not be neglected both for obvious reasons and because the patient s life expectancy is predictably longer in the case of chordoma and in carcinoid than in adenocarcinoma

## Diagnosis

A high index of suspicion and careful scrutiny should lead to the discovery of most carcinomas of the colon Any change in bowel habit the discovery of blood in or near the stool and an unexplained secondary anemia are cardinal warning signs that justify a thorough search While carcinoma of the colon occurs more often in those beyond 40 years of age younger people enjoy no immunity and this is particularly true of precursor polyps While bleeding from the left colon may yield bright red blood in or on the stool the slow ooze of a lesion in the right colon may result in such a mixture of dark stool as to go unnoticed Because the blood loss may be gradual symptoms therefrom are so insidious that the patient may accept mild syncope dyspnea and fatigue before presenting himself to the doctor with an astonishingly low hematocrit It is not uncommon to see the patient who has continued at work with a hemoglobin as low as 5 Gm per cent All patients who exhibit rectal bleeding regardless of obvious hemorrhoids or fissure should have both sigmoidoscopy and colon x ray studies

Any change in bowel habit must likewise be carefully examined This holds particular importance in lesions of the left colon This may be reflected in a gradually increasing tendency to constipation constipation alternating with diarrhea a frequent but unrewarding urge to empty the rectum or tenesmus Only rarely is an abdominal mass palpable waxing and waning with the degree of associated obstruction It is this obstruction that may also cause the cramplike pain associated with the lesion particularly in the left colon where the firmer consistency of the stool requires less compromise of the lumen by the tumor before obstruction takes place Should the patient ignore the early insidious symptoms his physician may first see him in the emergency of complete

obstruction The surgical problems are then exaggerated and the five-year survival rates of such obstructed lesions has been found to be lowered Diagnostic variations depending upon the site of the carcinoma will be discussed under Complications

Once suspicion of colonic involvement is aroused, an organized approach to diagnosis is in order Rectal examination, sigmoidoscopy, and barium x ray examination constitute the basic triad of investigation While the knee-chest or prone jackknife position is ideal for sigmoidoscopy, neither permits the occasional palpation by the rectal finger through redundant bowel of a rectosigmoid lesion Digital examination is best conducted with the patient in the supine or erect position, the finger then reaches higher and the patient can be made to strain and prolapse his rectosigmoid against the palpating finger Sigmoidoscopy should be performed on all patients suspected of having a colonic carcinoma because of the not infrequent occurrence of a second rectal carcinoma or polyp This permits scrutiny of an area of bowel that is below the level of reliable x ray evaluation In order for the examination to be rewarding and tolerable, proper equipment and positioning are necessary The knee-chest position drops the sigmoid forward and straightens its course for easier advancement of the scope The prone jackknife position over an inverted table constructed for this purpose is more comfortable and less fatiguing to the patient but is not essential A well-illuminated 25 cm sigmoidoscope made of bakelite, to permit insulated cauterization of polyps, is used Effective suction and long biopsy forceps with a snare are essential A bipolar diathermy unit is used for cauterizing the base of the removed polyp Once the lubricated scope is inserted within the anus, its obturator is removed and the scope is advanced under direct vision using suction The hydrostatic effect of water proves useful in straightening out the bowel and is safer than air introduced under pressure The suction tip should not be advanced beyond the end of the scope as its small point may perforate the wall of the rectosigmoid when stretched tightly across the opening of the scope Effort is concentrated in safely passing the instrument to its full reach and inspection is then carefully conducted as the scope is withdrawn, paying particular attention to the blind areas in the folds of the valves, which must be flattened out as the scope is withdrawn Biopsy is made wherever necessary

Barium enema x ray remains the most effective method of investigating the colon above the rectosigmoid junction The main contraindication to its use occurs in the lesion suspected of actual or impending obstruction In these more advanced cases the roentgenologist should be forwarned not to force the barium beyond the lesion where it may become inspissated and add to the problem or even precipitate an emergency operation The suspicion of obstruction may be confirmed by demonstrating the distended proximal colon on a preliminary plane abdominal x ray film A second contraindication to barium x ray occurs in the case of a suspected perforation of the lesion A reliable x ray evaluation depends upon the proper preparation of the patient's colon and a close liaison between the roentgenologist and the examining physician Digital examination and sigmoidoscopic examination should always precede the colon x ray and the roentgenologist should be given the advantage of all pertinent information before he fluoroscopes the patient To order a 'routine colon x ray' is a disservice to the patient and the roentgenologist Despite competent examination, a colon lesion may be overlooked, particularly in the cecum, hepatic and splenic flexures and in the redundant sigmoid The examination should be repeated whenever suspicion indicates. To depend on a less thorough examination may indeed delay discovery more than had it not been attempted

### *Differential Diagnosis*

The differential diagnosis of colon carcinoma lies mainly between diverticulitis, benign tumors, and secondary

ulcerative colitis In the right colon fecal impaction and appendiceal abscess may be mistaken for the filling defect of a cancer Diverticulitis, however, produces the greatest challenge to diagnostic acumen for despite careful attention to history, x ray findings, and even the use of colon cytology, the differentiation may prove difficult. Indeed, the lesions may prove indistinguishable even at surgery and the two may co exist

### *Complications*

The *complications* of large bowel neoplasms are (*a*) *obstruction,* which may prove acute and require emergent relief, or chronic allowing an elective one-stage resection, (*b*) *ulceration* and *bleeding,* which only rarely is massive in amount, (*c*) *perforation,* which may allow free fecal contamination of the peritoneum or produce a localized abscess or occur into an adjacent viscus to form a fistula such as a rectovesical fistula, and (*d*) *intussusception,* in which the neoplasm forms a leading point of the intussuscipiens

Likewise acute small bowel obstruction may result from encroachment on the ileocecal valve by a cecal carcinoma When the ileocecal valve continues continent behind a completely obstructing cancer of the colon, the clinical and x ray picture is one of a closed loop obstruction with the fecal stream trapped between the valve and the tumor On the other hand if the valve becomes incontinent, the small bowel becomes increasingly distended If the lesion is at the ileocecal region, the distention will be apparent only in the small bowel Intestinal decompression is of no aid whatsoever in the *closed loop* type of obstruction

## Treatment

While Reybord performed the first successful bowel resection and anastomosis by suture in 1832, few substantial contributions were made until the last decade of the 19th century when Murphy of Chicago described his button technique of anastomosis and Paul of Liverpool recommended exteriorization of the tumor, with resection and anastomosis being accomplished extraperitoneally in stages It remained for Miculicz to popularize this method of exteriorization Rankin contributed his method of exteriorized obstruction reresection and anastomosis, using a specially designed clamp Closed aseptic methods of anastomosis were developed by Stone, Parker, and Kerr These 'closed' techniques as well as staged multiple operations are used with decreasing frequency in this era of antibiotic bowel preparation and blood replacement having given way to primary open anastomosis (see under Technique of Anastomosis)

### *Preoperative Preparation*

Whenever possible, the patient should be provided with optimal nutrition a normal circulating blood volume, and in particular a bowel that is nondistended and free of feces In the evaluation of the patient s general condition in addition to routine urine and blood cell determinations, extensive laboratory work will be unnecessary However, an x ray of the chest, electrocardiogram, prothrombin time, and, in the patient with severe weight loss, a blood volume determination are usually indicated Intravenous pyelography, cystogram, and cystoscopy are indicated when extension to the genitourinary tract is suspected Should carcinoid be suspected, a determination should be made of the 5 hydroxyindol acetic acid excretion in the urine If the serum alkaline phosphatase is elevated, liver metastasis may be suspected An elevated value is not sufficiently pathognomonic, *however, to rule out surgical* exploration

Should anemia or a defect in circulating blood volume exist prior to surgery, this is corrected by whole blood or packed red cell transfusion The patient is placed on a low residue diet, and in the absence of a significant obstruction castor oil is given the afternoon prior to surgery Unless rapid preparation with neomycin alone is indicated, the authors have preferred the use of Bacimycin (2500 units Bacitra-

cin and 25 mg neomycin, tablets four by mouth, four times a day for two days) because of its lower cost and practical effectiveness as evidenced by bowel cultures at the time of surgery A thorough enema is given the evening before surgery and rectal suction employed for an hour or more the morning of surgery

Whenever temporary or permanent colostomy may prove necessary the patient should be aware of this possibility prior to operation Reassurance that this is a small inconvenience in the experience of others does much to dispel fear The opportunity of meeting a patient who has become accustomed to his colostomy is by far the most effective reassurance a patient may have

Only rarely is a significant degree of large bowel obstruction relieved by Miller Abbott or similar intestinal intubation and time should not be lost in experimenting with this tube Two exceptions to this rule should be mentioned, however The first is the occasional lesion at the ileocecal valve which creates obstruction of the terminal ileum and gives the x ray picture of small bowel obstruction The other is the advanced obstruction farther along the colon in which the ileocecal valve becomes incontinent and the distention involves the small bowel as well as the colon proximal to the cancer In both these instances the long intestinal tube may be used to decompress the obstruction and permit a one stage resection of the lesion with primary anastomosis

In general however, the ileocecal valve continues continent even behind a completely obstructing cancer of the colon and the clinical and x ray picture is then one of a closed loop obstruction with the fecal stream trapped between the valve and the tumor In these it is obvious that gastric or small bowel suction will avail nothing In these colostomy is to be preferred to cecostomy as the latter only deflates rather than defunctions the bowel This is particularly true when examination of the plane film of the abdomen reveals inspissated feces proximal to the obstruction In general, the colostomy should be placed in the right upper quadrant in lesions of the left colon, provided there is no biliary pathology

Should the obstructing lesion be located in the rectosigmoid and the proximal bowel be packed with inspissated feces a colostomy distal to the splenic flexure may be preferred, provided the sigmoid is sufficiently redundant and/or the patient s abdominal wall reasonably thin With complete obstruction of the closed loop type from a cancer at or proximal to the splenic flexure with a continent ileocecal valve so that small bowel is not distended there is no reason to stage the operation Rather the involved colon and terminal foot of ileum should be resected and lifted unopened from the abdomen and the ends of normal bowel anastomosed There is less hazard of infection and cancer implantation and further delay in cancer resection is avoided

If the distention has overcome the ileocecal valve and backed into the ileum then the operation should be staged unless a Miller Abbott tube promptly reaches and relieves the distention For the obstructing carcinoma at the cecum with small bowel distention that is not decompressed by a tube, exteriorization of the large and small bowel after the method of Lahey may be resorted to The presence of the ileostomy delays the time of reestablishment of alimentary continuity and creates additional problems in fluid and electrolyte balance in the postoperative period Usually staged procedures in the definitive treatment of carcinoma of the colon are indicated principally for obstruction which because of its severe or emergent nature, prevents bowel preparation and safe anastomosis Staged procedures also are indicated in the case of a suspected or frank perforation of the carcinoma or for superimposed infection that might be disseminated by radical resection Staging is not indicated in the definitive treatment of carcinoma of the colon because of the patient s obesity body build or other constitutional disease that

will not be physiologically improved by staging Technically, the second stage resection may be made more difficult by surgical adhesions from the first stage operation

## The Operation

Certain basic principles govern the technical performance of colon resection with primary anastomosis in addition to the preoperative preparation Adequate exposure is essential It is obtained by a vertical paramedian incision, retracting the rectus muscle The length of the incision may be extended from symphysis to ensiform cartilage when difficulty is encountered in freeing the splenic flexure or in exposing the origin of the major mesenteric arteries However if the incision is extended too far toward the ensiform, the small bowel can no longer be packed away as easily and may best be delivered outside the abdomen and controlled by encompassing packs For lesions of the right and transverse colon a transverse incision is used by some Tension on the anastomotic suture line is to be avoided by adequate mobilization of the bowel and reapproximation of the mesenteric edges This is particularly true in lesions of the left colon where mobilization of the splenic flexure may prove necessary Equally important is the preservation of an adequate blood supply to both ends of the bowel to be anastomosed As vascular anomalies are frequent, it is important to test the adequacy of the arterial supply under question by visualizing actual arterial flow through the marginal vessel Should borderline vascularity or technical difficulty in performing a satisfactory tension free anastomosis obtain, the level of resection should be reconsidered A proximal decompressive loop colostomy in order fully to divert the fecal stream may occasionally be used as a safeguard, but this is not a substitute for a convincingly adequate anastomosis with demonstrated arterial supply to each end and approximation without tension Decompressive tube gastrostomy performed at the time of colon resection has proved a valuable adjunct to those cases in which prolonged postoperative ileus may be anticipated, as following resection for obstructing carcinoma or where extensive mobilization has left unperitonealized surfaces

### *The Technique of Anastomosis*

In addition to the principles of adequate exposure, preservation of arterial supply and a tension free anastomosis are equally important Prior to performing the anastomosis it is essential that the operative field be quarantined This will reduce the incidence of wound infection and ileus secondary to peritonitis The exposed edges of the incision should be covered with large gauze pads, which are also used to wall off the surrounding peritoneum in the area of the anastomosis All instruments used in the performance of the anastomosis are quarantined during its performance and removed once the anastomosis is closed At the completion of the anastomosis the quarantine packs are removed and all members of the surgical team change gown and gloves In the actual performance of the anastomosis, a two-layer technique is carried out using an outer layer of interrupted nonabsorbable No 3 0 silk and an inner mucosal layer of No 3 0 chromic catgut (see Fig 19 3) The mucosal layer is primarily hemostatic and aids in inverting the mucosa and thereby approximates serosa to serosa The anastomotic mucosal stitch is started at either the center or a posterior corner of the bowel after the posterior serosal stitches have been tied A single suture may be used for the entire circumference of the anastomosis provided it is tied halfway around so as to prevent pursing or narrowing of the bowel lumen The anastomosis is completed by an anterior layer of interrupted silk serosal stitches An open anastomosis is used in all cases Those in which a closed anastomosis might be considered are just the ones where an expeditious open anastomosis by the method most familiar to the surgeon

is indicated Assuming the operative field is adequately quarantined by packs, peritonitis does not result from infection at the time of anastomosis but rather from continued leakage from an imperfect anastomosis Where decompression or preparation of the bowel has proved at laparotomy to be disappointing and the lumen is obviously not empty then gross spillage may be avoided by an occlusive ligature of large catgut placed temporarily around the bowel a few inches proximal to the line of resection The atraumatic needle carrying this ligature should be placed precisely through the mesentery between the gut and the marginal artery so as not to injure the latter Long ends should be anchored so the surgeon cannot possibly forget to remove the ligature after the anastomosis is accomplished

*Type and Extent of Resection for Cure*

This depends upon the nature of the lesion and its location Since adenocarcinoma comprises the vast majority of colon neoplasms, these lesions will be considered in detail Peculiarities in resection for carcinoid familial polyposis and lymphomas have been mentioned in connection with these lesions.

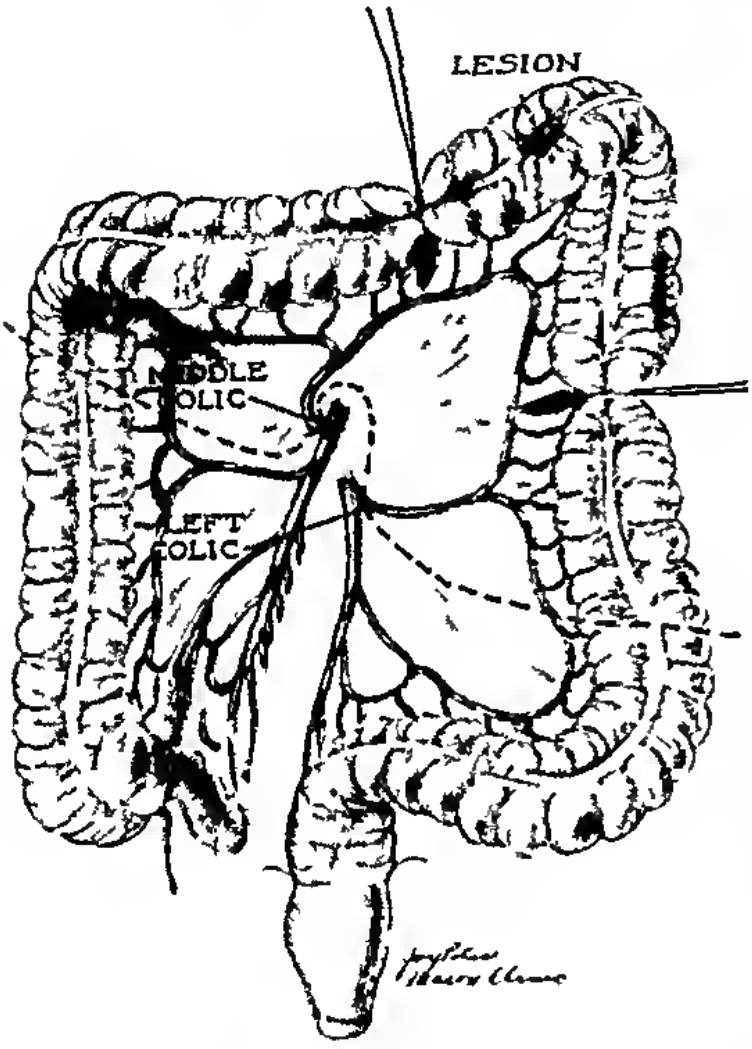


Fig 19 5 As illustrated in a lesion at the splenic flexure, prior to manipulation and mobilization of the tumor the bowel lumen proximal and distal to the tumor is closed by ligature and the venous drainage is occluded to prevent the dissemination of tumor cells

*Resection of Carcinoma of the Cecum and Ascending Colon*

This resection should ideally encompass the lymphatic drainage that accompanies the ileocolic and right colic vessels. This

resection should include the entire mesentery up to the midcolic vessels (Fig 19-4) In the face of obvious lymphatic metastasis and in the absence of distant irresectible spread, one may wish to encompass the midcolic vessels and lymphatics as well Prior to mobilization of the tumor itself the lesion is isolated against intraluminal implants by circumferential ligatures above and below the tumor and the venous outflow is occluded by ligation and division of the veins usually in accompaniment with the arteries at their origin (Fig 19 5) Included in the en bloc resection are 10 to 12 cm of the terminal ileum, the cecum, ascending colon, and hepatic flexure with adjacent omentum and mesentery The right colon is mobilized by division of the lateral peritoneal reflection along the right iliac gutter This is avascular Dissection is carried into the retroperitoneal space with visualization and protection of the ureter, the right kidney, the duodenum, and the superior mesenteric arterial trunk The omentum is freed from the stomach, preserving the gastroepiploic vessels An end to-end ileotransverse colostomy is performed unless a discrepancy in the diameter of the bowel lumen renders an end-to-side anastomosis more feasible In this case the distal end of the transverse colon is closed and the end of the ileum anastomosed to the side of the colon within a few inches of the closed end The bowel mesenteries are approximated with interrupted silk sutures This prevents herniation of small bowel through the mesentery and also protects against tension on the suture line Reperitonealization of the lateral gutter may usually be satisfactorily accomplished, although this is held by many to be unnecessary

### *Carcinoma of the Hepatic and Splenic Flexures*

Carcinoma in these locations as well as of the *transverse colon* has been managed with variable extents of resection and a resulting discouraging survival rate This may be in part due to the close proximity of the duodenum, stomach, and pancreas, as well as to the contiguous rich network of disseminated lymphatics The ideal resection should encompass the ascending and transverse colon, including the splenic flexure with adjacent omentum and entire mesentery (Fig 19 6) In a lesion of the splenic flexure (Fig 19 7) one should ideally resect all structures from the terminal ileum to a point distal

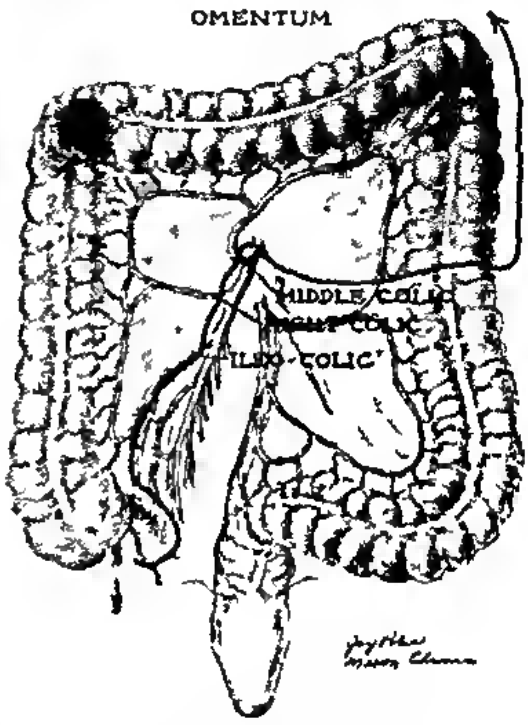


Fig 19 6 Carcinoma of the ascending colon and hepatic flexure As indicated by the shaded area, the resection should include the ascending and transverse colon including its mesentery and the omentum

to the left colic vessels and perform an ileo descending colostomy As an alternative, should impaired risk or technical difficulties dictate, the surgeon may limit the resection to a point immediately to the right of the midcolic vessels thereby preserving the ascending colon for easier anastomosis

### *Lesions of the Descending Colon and of the Mid-sigmoid and Upper Sigmoid*

In these lesions the performance of a total left colectomy has been advocated

by Rosi, Ault, and others Ligation of the inferior mesenteric artery at its origin offers the distinct advantage of removing additional secondary zones of immediate lymphatic spread although certain technical difficulties are posed by this extended resection Mobilization of the high splenic flexure particularly in the obese, adds technical difficulty By freeing the reflections of both the descending and transverse colon before attempting to free the more inaccessible apex of the splenic flexure the mobilization is facilitated Preoperative threading of the small bowel on a long intestinal tube will afford further technical advantages and a less encumbered operative field However a greater problem is the limited reach for anastomosis of the distal transverse colon after radical left colectomy The reach of the remaining transverse colon into the pelvis depends upon the length of the midcolic artery In some cases it is necessary to preserve a part of the splenic flexure and the descending colon to afford adequate length of proximal bowel so that a tension free secure anastomosis may be performed (Fig 19-8) In so doing the proximal lymphatic resection is not compromised and an adequate blood supply to the colon is provided by the midcolic artery via the marginal artery The compromise is not, therefore, one of lymphatic excision but rather one of reduced marginal

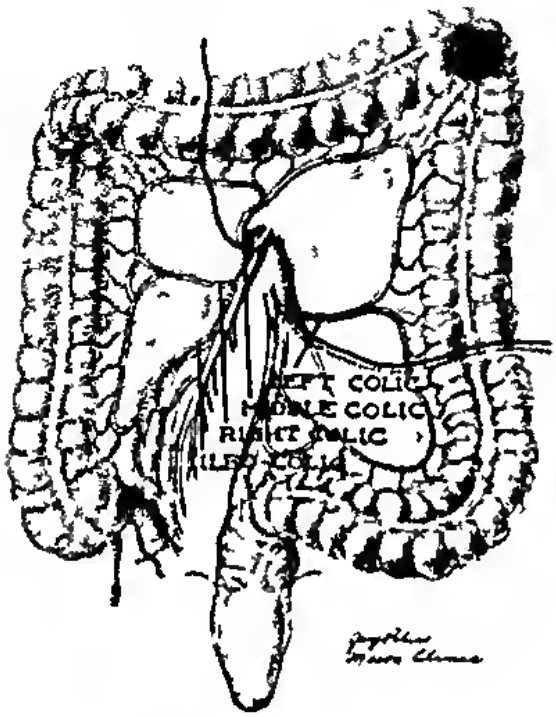


Fig 19 7 Carcinoma of the splenic flexure Ideally the extent of resection should include all structures from the terminal ileum to a point distal to the left colic vessels including the omentum As an alternative, should an impaired risk or technical difficulties dictate the resection may be limited proximally to a point to the right of the midcolic vessels, thus preserving the ascending colon for easier anastomosis

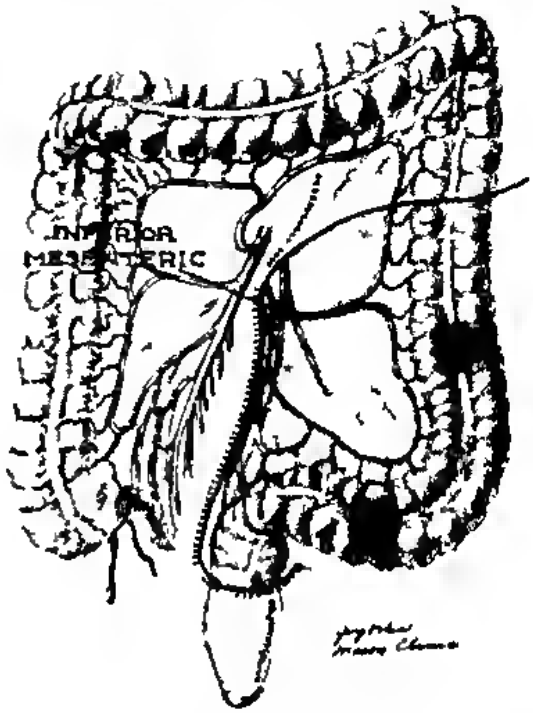


Fig 19 8 Carcinoma of the descending colon and upper sigmoid Ideally the resection should include the entire left colon and its mesentery up to the midcolic vessels However, in order to preserve a sufficient length of proximal colon to reach into the pelvis for a tension free anastomosis, it may be necessary to preserve a part of the splenic flexure Operative endoscopy of the preserved proximal bowel will demonstrate undiscovered satellite polyps

excision of bowel By operative endoscopic evaluation of this preserved proximal bowel (Fig 19 2) radiographically unsuspected polyps will be demonstrated Realizing that proximal intramural and paracolic spread does not occur more than several centimeters proximal to the lesion the policy of preserving proximal colon where there is technical need to do so would seem justified

*Lesions of the Lower Sigmoid and Rectosigmoid Colon*

One should be guided in these lesions by their relation to the lateral reflection of the pelvic peritoneum as this reflection fixes the straight course of the rectum downward and marks the junction of the sigmoid with the rectum Below this peritoneal level the lesion lies in close proximity to the levator ani muscles and the debated peritoneal restraint to lymphatic spread is lacking The significant factor is that for a cancer at or below this level, a sufficient margin distal to the tumor cannot be resected and yet leave a rectal stump for anastomosis For these lesions at or below the lateral peritoneal reflection anything less than the combined abdominal perineal resection is not recommended (Fig 19 9)

Agreement is lacking in lesions located just above the peritoneal reflection Should the distal resection be limited in an attempt to preserve a rectal stump for restoration of alimentary continuity, then the distal margin of both mural and lymphatic resection is thereby compromised Local mucosal and lymphatic recurrences after anterior resection for such low lying lesions have led a number of experienced surgeons to abandon the use of the anterior resection for lesions at this level except for those that are small, well differentiated, do not show invasion of the muscularis, and are unassociated with satellite polyps Such a decision is made only after consultation at operation with a pathologist experienced in and available for frozen section In performing this very low anastomosis, technical advantage can be obtained by the use of the end to-side rectosigmoid anastomosis as suggested by Baker (Fig 19-10) The variation in method permits the anastomosis to be accomplished deep in the small pelvis in a more convincingly secure manner In this method, the distal end of the sigmoid is closed and laid, unencumbered by clamps,

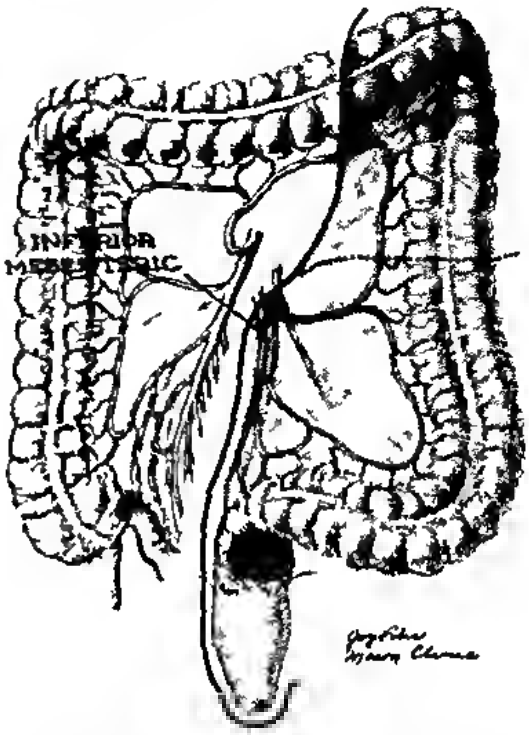

Fig 19 9 Carcinoma of the rectosigmoid Resection of the lesion situated at or above the lateral peritoneal reflection should be by means of a combined abdominoperineal resection with the proximal margin of resection including the inferior mesenteric artery, which is ligated at its origin The colon may be resected to a point proximal to the splenic flexure or it may be preserved to a point just below the splenic flexure following operative endoscopy to exclude satellite polyps

alongside the rectal stump, and then anastomosed to it The lumen is as large as the broad rectal ampulla, the posterior surface of the anastomosis is protected by approximating the rectal mesentery to the side of the sigmoid, and the pelvic peritoneum is used to reinforce the anterior side.

In those resections performed in the presence of partial small bowel obstruc-

tion, particularly in the case of right colectomy, the use of a decompressive gastrostomy as emphasized by Farris and Smith permits adequate intestinal decompression without the associated respiratory complications and discomfort of the prolonged use of a nasogastric tube Ileus is not uncommon after extensive mesenteric resection or after resection of the obstructing lesion

### *Palliative Resection*

Palliative resection is indicated for the lesion that has metastasized distantly yet exhibits obstruction or significant bleeding It is indicated in those lesions which at laparotomy prove to have metastasized to the liver or peracetic nodes Such palliative resection is usually more limited in extent than the ideal resection, encompassing only that area of bowel involved by the lesion and a limited adjacent margin In the lesion lying at or near the lateral reflection of the pelvic peritoneum in which combined abdominoperineal resection would be otherwise indicated, resection with restoration of continuity is preferred of course, in the presence of distant metastasis In the nonresectable lesion, particularly in the ascending and transverse colon, a short-circuiting side-to-side ileocolostomy may prove justified In such instance one should not neglect the worthwhile prognostic information obtained from biopsy

While the "second look" procedure has received the enthusiasm of some, its main contribution would appear to be in the

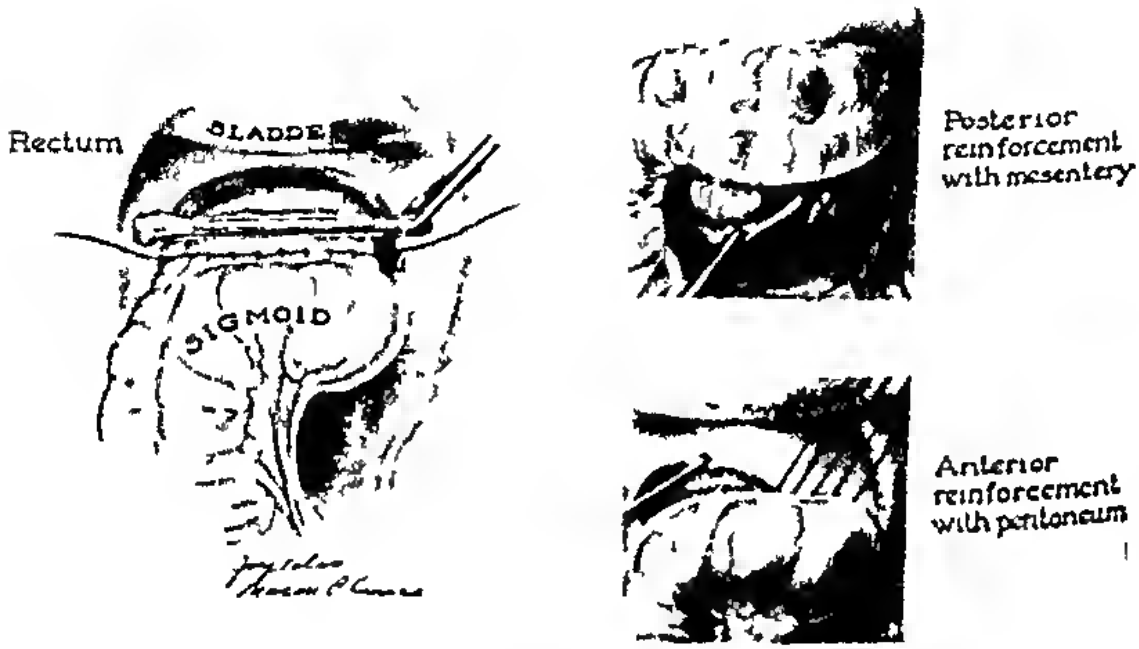


Fig 19 10 The technique of end-to-side anastomosis for the very low rectosigmoid anastomosis or where there is a discrepancy in the size of the ends to be joined The closed end of the sigmoid unencumbered by clamps, is laid across the presacral space behind the rectal stump A posterior row of interrupted silk sutures is placed at antimesenteric tinia This row is reinforced by suturing the mesentery of the rectal stump to the side of the sigmoid The anterior row is reinforced with peritoneum after completing a mucosal suture with running catgut *From* Baker J W Low end-to-side rectosigmoidal anastomosis. *Archives of Surgery 61* 143 1950 )

emphasis it lends to extending the original resection, particularly so as to encompass all resectible avenues of lymphatic spread

*Colostomy*

Colostomy is indicated (a) in carcinoma of the colon for decompression of the bowel proximal to the obstruction or perforation, and (b) for deviation of the fecal stream proximal to a less than ideal anastomosis

A double limb of bowel is isolated and delivered outside the abdomen without tension and with preservation of the marginal artery (Fig 19 11) Through an opening in the mesentery carefully made between the colon and the marginal arterial arcade, a flap of skin (and occasionally fascia) is insinuated in order to hold the colostomy in place. The anterior wall of the colostomy may be opened shortly after its performance. Complete division and defunctioning of the colostomy should await the adequate sealing of the wound in order to prevent peritoneal contamination or retraction of the limbs of the colostomy Closure of the colostomy may be carried out at the time of the secondary operation along with resection and anastomosis of the involved bowel or the closure may be deferred for a period of time should the distal anastomosis prove less than ideal Closure of the proximal colostomy at the time when a satisfactory anastomosis has been achieved helps prevent the occurrence of stenosis at the anastomotic suture line, since the re established fecal stream tends to dilate and maintain the diameter of the anastomosis In closing the temporary double barreled colostomy, the bowel is carefully prepared, the margins of the bowel are freed from the abdominal wall, the scarred tissue is resected, and the normal ends are joined

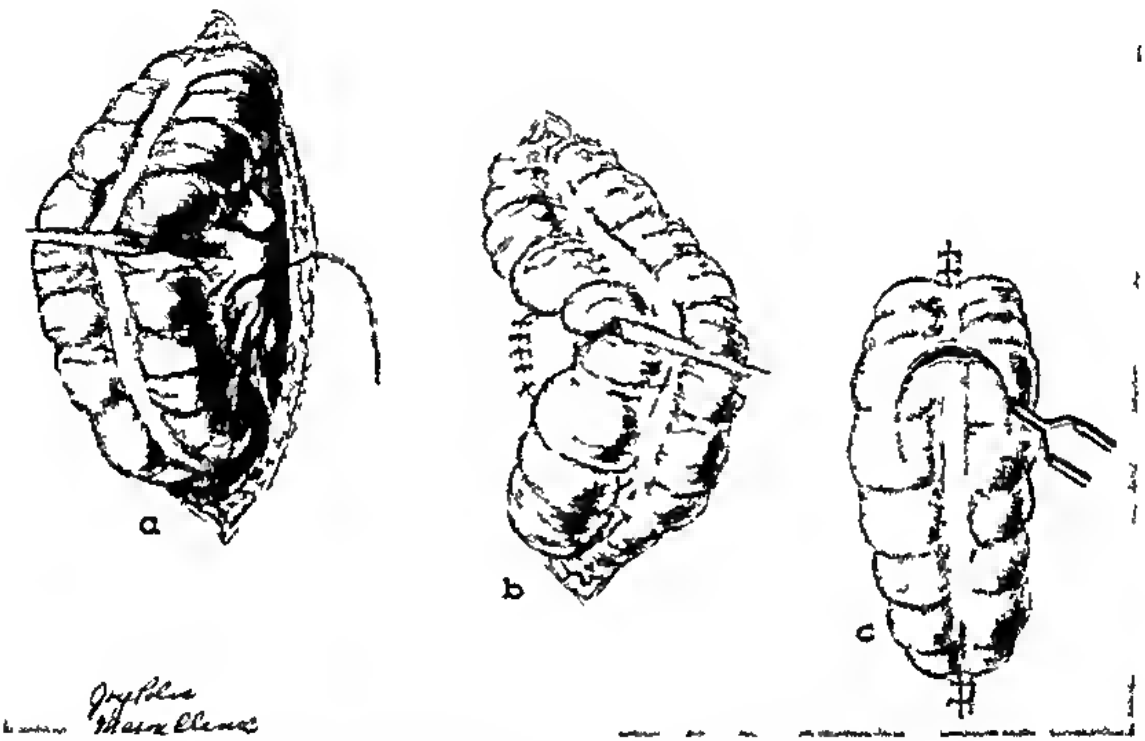


Fig 19 11 Technique of transverse colostomy A linea alba incision is used and incision is made in the mesentery between the bowel and the marginal artery (*a*) A skin bridge is placed through this mesenteric opening (*b*) The bowel is opened on its antimesenteric surface or divided completely as desired

by a two layer anastomosis, the mesentery is closed and the loop of colon then dropped back into the abdomen If the abdominal wall has been free of gross infection and the scarred edges have been resected, then a primary closure of the abdominal wall is made, preferably with buried No 32 steel sutures, otherwise, a delayed closure of the skin may be resorted to

### *Postoperative Complications*

Complications provide the main problem of postoperative care and are dealt with elsewhere in this volume Anastomotic leak at the suture line is a severe and often fatal complication that requires immediate recognition and a proximal defunctioning colostomy and rigorous antibiotic and parenteral fluid therapy for the ensuing peritonitis It should be considered a technical imperfection on the part of the surgeon Anastomotic obstruction usually responds to proximal decompression by Miller-Abbott tube or temporary proximal colostomy in the refractory case This also must be classified as a technical imperfection Postoperative small bowel obstruction will more often represent a true ileus but may result from occlusive herniation of the small bowel into an area of inadequate reperitonealization The differential diagnosis will not be as difficult if the abdomen has been diligently examined each day High-pitched peristaltic tones would point to occlusive obstruction whereas the continued absence of tones after operation favor ileus As a rule postoperative ileus is heralded by a progressively decreasing urinary output owing to increasing loss of fluid into the intestinal lumen When decompression by suction tube proves refractory then operative exploration is mandatory Decompression of the jejunum by passing a Foley catheter into its lumen and then threading the dilated bowel over the inflated balloon with constant suction on the catheter can be helpful The tube may be removed or preferably left as a decompressive jejunostomy brought out through the abdominal wall In some instances the preoperatively placed Miller Abbott tube, if beyond Treitz ligament, may be used for this purpose

Wound dehiscence and infection may occur despite the utmost diligence and scrupulous technique Resuture of the wound, utilizing through and through all layer suture is mandatory

## REFERENCES


AULT, G W, CASTRO, A T, and SMITH R S Clinical study of ligation of the inferior mesenteric artery in left colon resections *Surg Gynec & Obst 94* 223, 1952

BAKER, J W Low end to-side rectosigmoidal anastomosis Description of technic *Arch. Surg 61* 143 1950

BAKER, J W, MARGETTS, L H, and SCHUTT R P The distal and proximal margin of resection in carcinoma of the pelvic colon and rectum *Ann Surg 141* 693, 1955

BERK, J F Malignant Tumors of the Colon and Rectum, in BOCKUS H L, *Gastroenterology* vol 2 Philadelphia, W B Saunders Company, 1946, pp 743 787

COLCOCK, B P Malignancy a complication of ulcerative colitis *Lahey Clin Bull 6* 52, 1918

COLE, W H Recurrence in carcinoma of the colon and proximal rectum following resection for carcinoma *A M A Arch Surg 65* 261, 1952

COLLER, F A, KAY, L B, and MACINTYRE R S Regional lymphatic metastases of carcinoma of the colon *Ann Surg 114* 56, 1941

DUKES, C E Explanation of difference between papillomas and adenoma of rectum *Proc Roy Soc Med 40* 829, 1947

DUKES C E, and LOCKHART MUMMERY H L Familial intestinal polyposis *S Gen North America 35* 1277 1955

GILCHRIST, R K, and DAVIS V C A consideration of pathological factors influencing five year survival in radical resection of the large bowel and rectum for carcinoma *Ann Surg 126* 421 1947

HELWIG E B The evolution of adenomas of the large intestine and their relation to carcinoma *Surg Gynec & Obst 84* 36, 1947

JEGHERS, H Medical progress Pigmentation of the skin *New England J Med 231* 122 131, 1944

PEARSON, C M, and FITZGERALD, P J Carcinoid tumors, a re emphasis of their malignant nature, review of 140 cases *Cancer 2* 1005, 1949

PEYSTER, F A DE, and GILCHRIST, R K Pathology of cancer of the colon and rectum, classification and mode of spread *S Clin North America 35* 1295, 1955

ROSI, P A Selection of operations for carcinomas of the colon *S Clin North America 34* 221, 1954

SCARBOROUGH, R A Preoperative and postoperative management of patients with lesions of the colon and rectum *S Clin North America 34* 1419, 1954

SEABROOK, D, STEVENS, R SCHOOL V, and NOHLGREN J Lipomatosis of the ileocecal region *Am J Surg*, 1956

SOUTHWICH, H W, and COLE, W H Prophylactic measures in local recurrence and venous metastases in carcinoma of the colon *S Clin North America 35* 1363 1955

THORSON, A, BIORCK, A BJORKMAN, A, and WALDENSTROM J Malignant carcinoid of the small intestine with metastases to the liver, valvular heart disease of the right side of the heart, pulmonary stenosis and tricuspid regurgitation without septal defects, peripheral vasomotor symptoms, bronchoconstriction, and an unusual type of cyanosis *Am Heart J 47* 795 1954

WELCH, C E McKITTRICK, J B, and BEHRINGER, C Polyps of the rectum and colon and their relation to cancer *New England J Med 247* 959, 1952

## EDITOR S NOTE ON VOLVULUS OF THE COLON

Volvulus of the upper gastrointestinal tract is covered in another section of *Abdominal Surgery* Volvulus of the colon is a separate entity which, owing to Bruusgaard, is of interest It occurs fifteen times as frequently in the sigmoid as in the cecum It is rare in the transverse colon Clockwise rotation occurs three times as frequently as counterclockwise Volvulus is more frequent in men than in women

Dilation of the bowel and elongation of the mesentery, and inadequate peritoneal fusion, sometimes postoperative, are etiologically important

Physiologic rotation of the sigmoid of less than 180° is common When rotation of greater degree occurs, detorsion may be prevented by distention of the two limbs, which occurs rapidly Egress of fluid and air is prevented by the twist, but ingress is not As distention increases, the mesentery becomes edematous, circulation is impaired, and infarction may result Obstruction to the proximal gastrointestinal tract follows If the ileocecal valve is competent, obstruction is limited to the colon at first but eventually involves the small intestine Perforation of the cecum may occur Necrosis at the twist may cause perforation at the sigmoid

The signs and symptoms are those of intestinal obstruction crampy pain, meteorism, obstipation, and hyperactive peristalsis that becomes diminished with the onset of peritonitis or infection Inspection of the abdomen may suggest the diagnosis and x ray can be diagnostic (Figs 19-12, 19 13)

Other causes of large bowel obstruction, notably cancer, diverticulitis, and *fecal impaction* must be differentiated

Decompression of the distended sigmoid loop, ideally by rectal tube inserted with the aid of a sigmoidoscope, will provide relief Perforation is a hazard in *advanced* volvulus unless extreme care and good visualization are secured The tube should be left in place for three or more days, secured by a suture through the perianal skin Morbidity and mortality in patients decompressed with a rectal tube are slight.

When decompression through a sigmoidoscope is not possible the sigmoid can be decompressed by a tube introduced through the rectum, and guided into the lumen by the surgeon's hand within the abdomen If enterostomy is necessary, the mortality rate approaches 15 per cent Should perforation occur the mortality rate is high

Should volvulus recur it should be decompressed again through a rectal tube and elective resection of the redundant sigmoid undertaken, preceded by adequate preparation This is simple and

Fig 19 12 Bent inner tube shadow on flat plate of abdomen in patients with volvulus

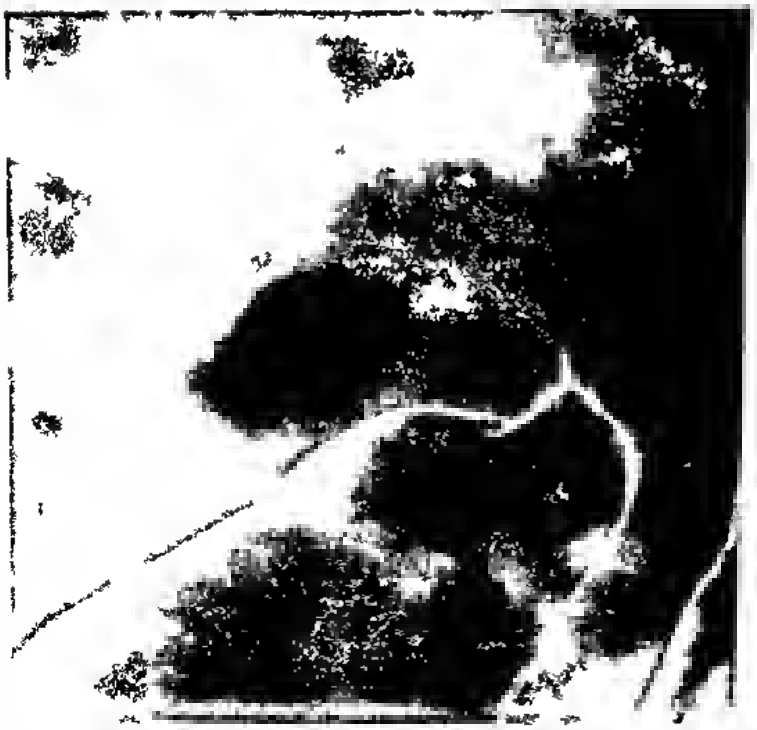

Fig 19 13 Posterior [illegible] film of a barium enema showing "chicken beak" deformity in a patient with volvulus

successful during a symptom free interval Others have reported successful prophylactic resection during acute episodes I have had no experience with this

Volvulus of the cecum or the transverse colon cannot be decompressed from below and demands prompt laparotomy When resection of gangrenous bowel is necessary, the obstructive type of Rankin may be preferred to primary anastomosis

## Reference

BRUUSGAARD, CHRISTIAN Volvulus of the sigmoid colon and its treatment *Surgery* 22 466, 1947

CHAPTER 20

# ULCERATIVE COLITIS

*Henry W Cave and James E Thompson*

From our present knowledge of ulcerative colitis, it is considered to be a nonspecific disease that manifests itself at the onset by diarrhea Progressive ulcerative colitis is characterized by spontaneous remissions and exacerbations, and there is no way of predicting the duration or severity of relapses

The clinical picture usually presented is that of a patient who has had weeks or months of diarrhea, and who may, or may not give a history of definite onset with a specific bowel infection The patient may also be in a state of poor nutrition, depending upon the phase or duration of the disease but in all cases there must be demonstrable ulceration or suppurative changes in the bowel wall in order for the diagnosis of ulcerative colitis to be made

## INCIDENCE

Ulcerative colitis seems to show a predilection for individuals from 20 to 40 years of age and is uncommon under the age of 10 or over 60 In our series, the onset occurred within the ages of 20 to 40 in 52 per cent of the cases and only in 6 per cent was the onset below the age of 10 or over 60 The disease occurs as frequently in males as in females These observations are borne out in figures given in Table 20-1, which cover our experience with 402 patients admitted to the Roosevelt Hospital from 1934 to 1957

There is general agreement in the literature that ulcerative colitis is more or less world wide, and does not seem to favor any particular nationality or ethnic group Similarly, climate is not a significant factor, unless one would attach importance to the fact that the disease is commoner in the northern than in the southern part of the United States

TABLE 20-1 AGE OF ONSET OF ULCERATIVE COLITIS IN PATIENTS ADMITTED TO THE ROOSEVELT HOSPITAL, 1934 1957

| | Patients | | Sex | |
|---|---|---|---|---|
| Age in years | Number | Per cent | Male | Female |
| Under 10 | 12 | 3 | 5 | 7 |
| 10 19 | 104 | 28 | 55 | 49 |
| 20–29 | 117 | 32 | 59 | 58 |
| 30–39 | 73 | 20 | 33 | 40 |
| 40–49 | 34 | 9 | 15 | 19 |
| 50 59 | 17 | 5 | 10 | 7 |
| 60 and over | 11 | 3 | 3 | 8 |
| Total | 368* | 100 | 180 | 188 |

*Age of onset unrecorded for 34 out of 402 patients admitted

Although there have been reports of the disease affecting more than one member in the same family, there is insufficient evidence to assume that heredity or contagion play an important part in its occurrence

## ETIOLOGY

The nature of the disease suggests it to be an infectious process and because of its

clinical and pathologic similarity to bacillary dysentery, extensive investigation has been directed toward trying to establish a relationship between the two diseases Opinion is still not unanimous on this point, and it would seem that there is as yet no conclusive evidence that the dysentery bacillus is an etiologic factor Similarly, streptococci and various colonic organisms and viruses have been suggested as possible causes, without any proof that any one of them is the primary etiologic agent It remains for developments in the future to determine definitely whether bacteria or viruses are the inciting cause, or whether they merely enter the picture as secondary invaders once the mucosal barrier has been broken The parasite most commonly suspected of playing an important part in the disease is the *entamoeba histolytica* However, its role is extremely doubtful and will be discussed further in the section on differential diagnosis

Attempts have been made to establish an allergic origin of the disease There is evidence to indicate that in certain cases, allergens do influence its course and particularly aggravate the symptoms On the other hand, it is extremely doubtful that allergic factors are primarily responsible for the pathologic lesions characteristically associated with chronic ulcerative colitis The allergens most commonly suspected include coffee, milk, chocolate, wheat, potatoes, oranges tomatoes, and strawberries In commenting in general on gastrointestinal allergies, Cooke says 'Much has been written on the subject, but a critical examination discloses the fact that while allergy might properly be suspected as the cause of symptoms, in rather few instances is the proof substantial '

Nutritional deficiency is a common and distressing feature in the advanced stages of the disease, owing to absorptive difficulties and loss of fluid and electrolytes by diarrhea It is rare to encounter a patient in whom the deficiency has antedated the onset of diarrhea Although vitamin B deficiency can produce lesions of an ulcerative and hemorrhagic nature in the intestinal tract, these are not likely to be confused with the lesions of ulcerative colitis

The role of enzymes in producing the disease has also been investigated It has been noted that in some patients the stools may contain a high concentration of lysozyme This is thought to be associated with the presence of granulation tissue and leucocytes in the colon However, although lysozyme can remove the protective colonic mucus, it is doubtful that it plays a primary part in the production of the disease, on the other hand, it may promote further ulceration by removing a protective barrier It has been suggested that there may be some deficiency in the intestinal wall that can render patients especially susceptible to infection and ulceration This may be related in some way to the absence of an intrinsic factor, such as a particular enzyme

It has been demonstrated experimentally that blockage of the lymphatics by a sclerosing solution can produce edema and inflammatory changes in the colon The resulting cellular necrosis and ulceration may thus open up a pathway for secondary invaders that eventually produce the picture of ulcerative colitis It also does not seem unreasonable to assume that by blocking the lymphatics a virus or bacterial infection might in the same manner play a primary part in the disease Further, it has been shown experimentally that stimuli such as fright, pain anxiety, and excitement may produce vasomotor changes in the colon via the autonomic nervous system It is also thought possible that the ulcerations that tend to underlie the taenia result from the prolonged contraction of the overlying longitudinal muscle band An increase in the number of ganglionic cells has at times been noted in patients suffering from the disease It is not known whether this increase in the cells is a primary feature, or whether they have developed as the result of prolonged hyperfunction The vascular changes resulting from prolonged abnormal stimulation of the autonomic system undoubtedly play a secondary part in the

disease, though it is doubtful that they are of any primary importance

Much attention has been directed to the part played by psychological factors in the development of ulcerative colitis, and there is no question that a high proportion of patients exhibit abnormal character traits These traits include excessive need for love, affection, and sympathy, excessive neatness and punctuality, repressed hostility, dependency on others, and indecision Some of these patients are not well adjusted sexually and often have a fixation on some member of the family, usually the mother Conflicts may arise as the result of a childbirth that may endanger this dependency Relapses often recur in such patients as a result of these emotional disturbances According to Bockus, "What portion of these traits are the result of the disease and what portion are of etiological importance, it is difficult to determine Perhaps the emotional immaturity at times represents a regression as a result of a severe humiliating disease with all its associated nutritional deficiencies and general toxemia Certainly a marked stabilization in personality occurs during remission in a large number of patients" In other words any disease that can be as toxic and debilitating as ulcerative colitis is likely to cause manifestations of a psychotic nature and for this reason, these traits are more likely the result of the disease rather than the cause

Avitaminosis has been considered as another possible cause However, it is more reasonable to explain its part in the disease on the basis of faulty absorption and inability to store vitamins because of the extensive bowel ulceration The general vitamin deficiency obviously adds to the gravity of malnutrition in the advanced stages of the disease

General metabolic disturbances are not thought to play any real part in the onset of symptoms However the clinical picture presented by the very ill patient might on superficial observation, suggest Graves disease with an associated elevation of the metabolic rate

## PATHOLOGY

In the typical case, ulcerative colitis is thought to begin in the rectum, and gradually to extend proximally until it involves the remainder of the colon This does not hold true in every patient, however, individuals are encountered occasionally, in whom the rectum does not appear to be affected In a small percentage, the disease may remain confined to the left colon or to the right colon, or may be located in scattered areas throughout the large bowel It is thus evident that the disease does not always follow a consistent pattern of involvement

The upward spread of infection from the rectum has been estimated by some observers to occur in as high as 90 per cent of cases, being confined in its milder forms, to the area below the mid sigmoid colon As the disease progresses, the sigmoid and descending colon gradually become affected, and in the very advanced stages, the transverse and even the entire colon may thus become diseased, see Figure 20-1 (*Left*) A limited number of patients with disease in the cecum will show involvement of the terminal ileum

The term 'right sided ulcerative colitis is used in the occasional case where only the proximal colon is diseased and the term 'segmental' or 'regional colitis" is used to describe the disease when confined to segmental areas of the large bowel The consensus is that these named types are all variations of the same disease

Early in the course of the disease, the mucous membrane, on gross appearance is hyperemic and exhibits minute punctate hemorrhages In this phase there need not be any frank ulceration and to the naked eye, the mucosa may present only an angry red appearance that will bleed freely with the slightest trauma The hyperemia is associated with edematous changes in a part of the bowel wall or in the entire wall which results in pronounced thickening As the inflammatory process develops, submucosal areas of

congestion and hemorrhage emerge, with overlying mucosal changes, these progress from shallow erosion to superficial ulceration and finally to deep, ragged ulceration, with edges that are rarely undermined As it develops, the ulcerative process results in the confluence of irregularly shaped areas, which assume a geographic pattern In the cecum and rectum, the ulcers are usually irregularly located, but in the ascending, transverse, descending, and sigmoid colon they are roughly elliptical in shape and tend to lie in the long axis of the bowel (Fig 20 1 *Right*), more or less parallel to one another In addition, irregularly circular ulcerations may be found lying in the course of the overlying circular muscle bands

In nonulcerated areas, the mucous membrane may be covered with an adherent inflammatory exudate that almost forms a membrane To add to the complexity, areas may be found in which the mucous membrane assumes a red granular appearance When ulceration occurs, it extends, with the passage of time, down into the muscularis mucosa, and eventually, the muscle fibers are replaced with inflammatory fibrous tissue This results in the development of areas of marked narrowing and thickening and, at times, of actual strictures as well It is this phenomenon that causes the marked shortening of the bowel wall, and in some instances almost eliminating the usual angulation at the splenic flexure (Fig 20-2 *Left*) In patients with long standing disease, areas of hyperplastic inflammatory tissue can be seen scattered over the bare smooth ulcerated areas, this gives an appearance of polyps, to which the term pseudopolyposis has been applied (Fig

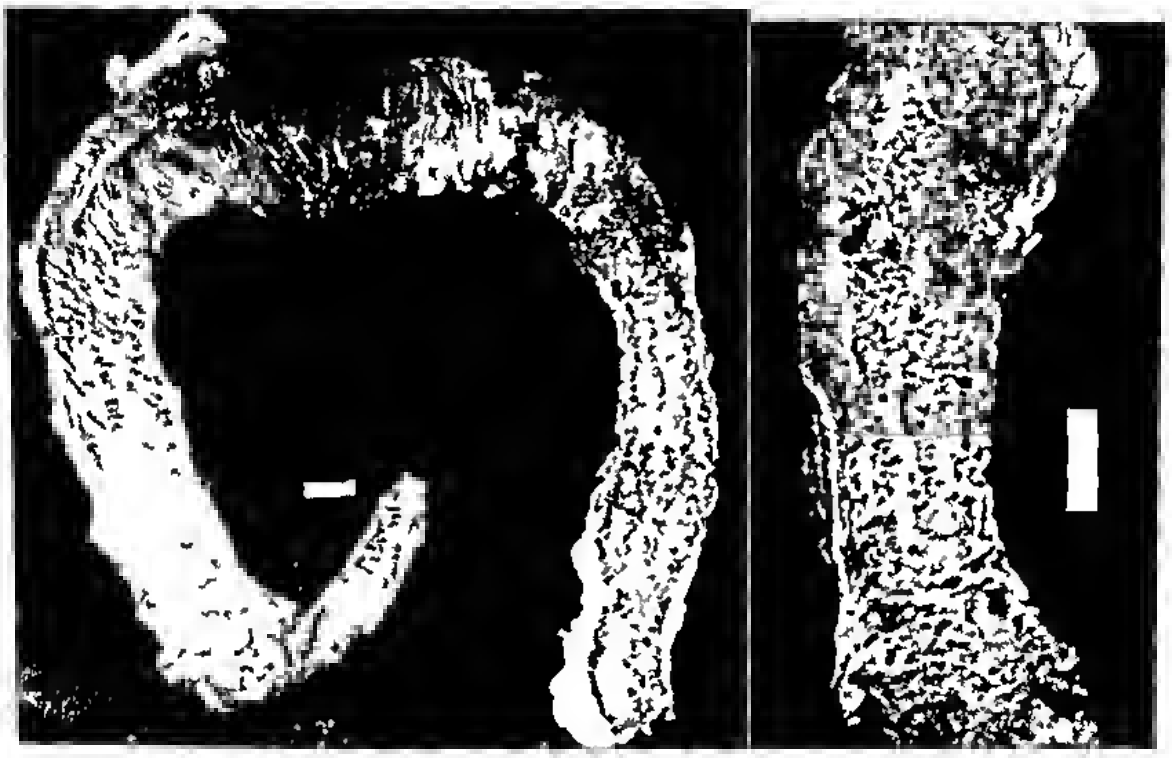

Fig 20-1 (*Left*) Fresh specimen showing extent of involvement in an advanced case of ulcerative colitis (Terminal ileum and proximal half of ascending colon are the only areas not involved ) (*Right*) *Magnified segment of descending colon The irregularly shaped, ulcerated areas are roughly elliptical and tend to lie parallel to the long axis of bowel* Early pseudopolypoid changes

20-3). It is thought by some pathologists that these constitute areas of isolated hyperplastic mucosa, and by others that they are purely inflammatory polyps.

The serosa of the bowel characteristically evidences a dull appearance, owing to loss of its normal shiny lustre. There are areas of hyperemia and redness, the intensity of which depends upon the acuteness of the underlying inflammatory reaction. In the acute fulminating form, the ulcerations may extend through the bowel wall with such rapidity as to result in free perforation. At other times, the descending or the sigmoid colon may become so adherent to the serosa of the lateral or anterior abdominal wall as to seal itself and thus prevent free perforation. The tendency to perforate may result in the formation of fistulas between the colon and other viscera.

It is not infrequent to encounter a moderate amount of inflammatory hyperplasia of the regional mesenteric lymph nodes that drain the involved areas of the colon. This feature of the pathologic picture, however, is not as prominent in ulcerative colitis as it is in regional or terminal ileitis.

Disease in the rectum, which encroaches on the anorectal junction, may involve the anal crypts at the dentate line. As a result, it is not uncommon to encounter perianal abscesses and anal fistulas in such instances.

The microscopic picture varies with the stage of the disease, but from the onset, edema of the submucosa and mucosa is a prominent feature, and is apt to show some associated necrosis and erosion of the mucosal surface. There is usually infiltration of the submucosa with monocytes, lymphocytes, and even eosinophiles. The progress then is from this stage to that of actual ulceration, where

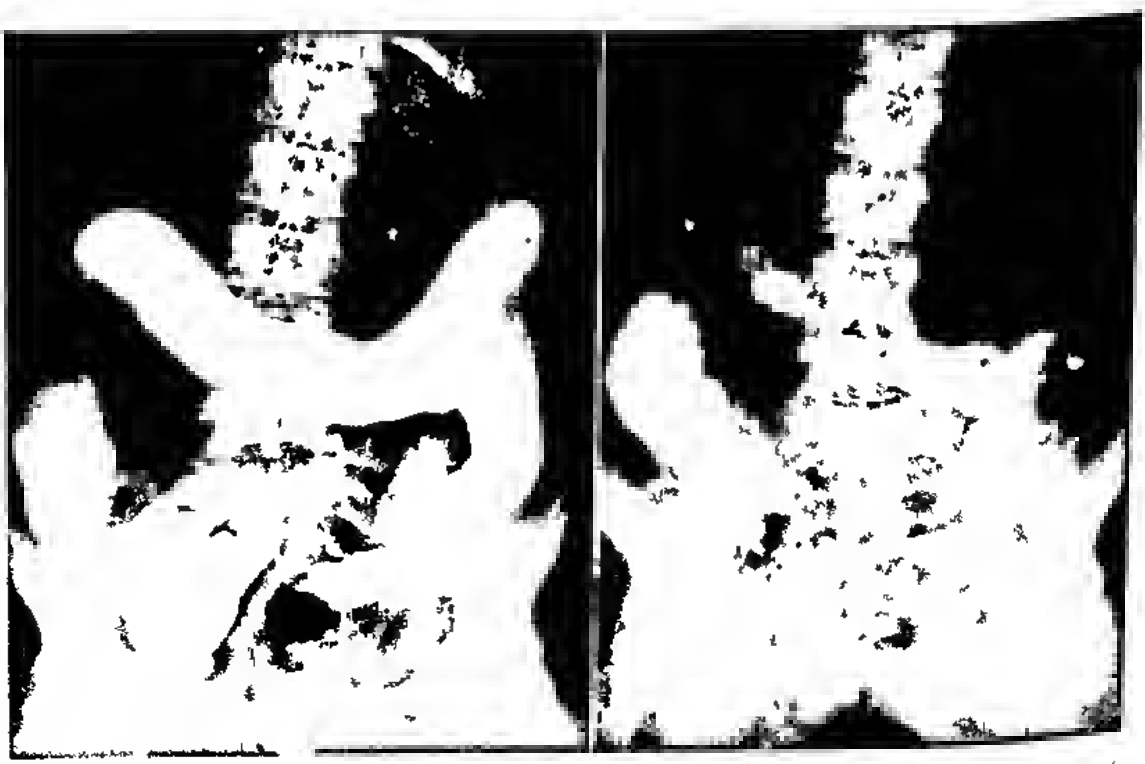

Fig. 20-2. *(Left)* Ulcerative colitis. Bowel contracted, both flexures dropped from normal high levels. Outline of transverse colon shows feathery, ragged contour. *(Right)* Post-evacuation film. Reveals mottled pattern with irregular opacities due to ulcers and pseudopolyps scattered throughout colon.

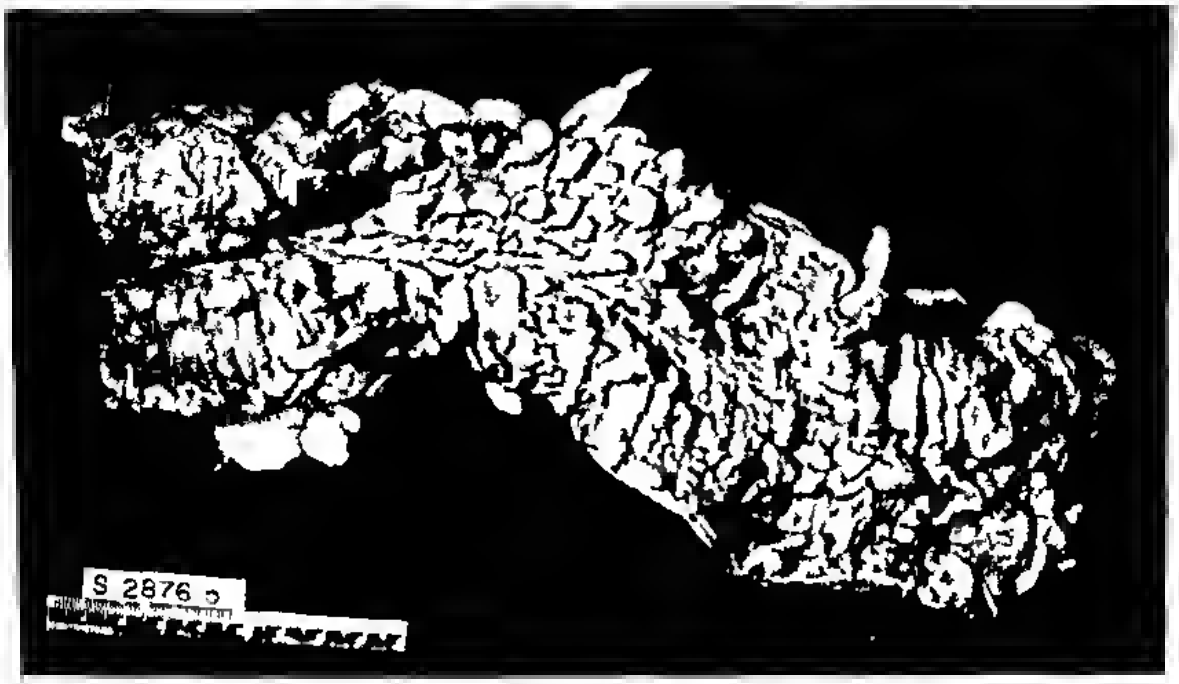


Fig 20 3 Fixed specimen sho v ng advanced pseudopolypo d changes

an infiltration with polymorphonuclear leucocytes becomes more extensive The ulcers are rarely undermined and the base of the ulcer may be in the submucosa or within the muscle layer or may be lying on a greatly thickened and edema tous serosa There is a tendency for all layers to become replaced with fibrous tis sue thus explaining the thickening and loss of pliab lity of the bowel wall in ad vanced cases

## SIGNS AND SYMPTOMS

The disease is capable of following such a varied course that it is helpful to clas sify as far as possible the forms one is most likely to encounter We feel that such a classification will aid in identifying the expected clinical course for each form and in defining the treatment which is discussed later in the chapter Bockus sug gests a simple classification which is sum marized below

I *Acute Forms* The disease may be acute from its onset or may de velop after months or years of re mission

a Insidious or mild type May last a short time May become acutely fulminating or chronic May recur after short or pro longed intervals

b Fulminating type Onset is rela tively abr pt and may reach its peak in two or three weeks May continue for months and termi nate fatally May pass into a chronic phase or into a remis sion

c Continuous type Onset is in sidious or fulminating and of mild or moderate severity Dis ease continues unabated and no remissions occur Later becomes *chronic* and continuous

II *Chronic Forms* Patients in this group are never free from symp toms and show a persistence of chronic bowel lesions without ap preciable symptoms except during exacerbations

a Continuous type A patient with this type tends to develop a con tracted fibrotic bowel may d e as result of acute exacerbation but is likely to live for years as a

semi invalid and die of another disease

b Relapsing type Most chronic forms fall under this heading Lesions and symptoms may disappear periodically but residual damage is usually present Remission may last months or years and recurrences may be seasonal or totally irregular

The onset of the disease is usually abrupt and is marked by severe diarrhea the watery stools increasing in frequency with the passage of time Many patients notice and describe bloody mucus in the bowel movement Others may develop the disease insidiously and describe merely a gradual awareness of a change in bowel habits, that is, from normal to frequent and mushy stools to frank diarrhea In some patients the only symptom may be bloody mucus on the surface of the stool and on occasion this may be associated with constipation of brief duration

The ultimate appearance of blood in the stool mixed with pus or mucus is to be expected unless the pathologic changes are confined to the right colon In the acute fulminating form of the disease, the stool may contain little or no fecal matter and may occur from twenty to thirty times a day or may develop into an almost continuous watery discharge It is in this acute form that massive hemorrhages from the bowel are most likely to occur

Colicky abdominal pain is an almost constant complaint and usually subsides or disappears after a copious evacuation The pain is most often described as being located in the left lower quadrant or in the hypogastrium but it may be anywhere in the abdomen The pain is occasioned by distention and peristalsis of the involved irritable portion of the colon and disappears as this segment is emptied through evacuation There may be associated involuntary muscle spasm occasioned by the inflammatory reaction of the serosa overlying the areas of ulceration In patients with a fulminating disease the physical signs of pain on deep pressure, the localized muscle spasm, and the rebound tenderness may simulate actual or impending perforation

Anorexia, nausea, and, at times vomiting may occur in direct proportion to the severity of the peritoneal reaction When the diarrhea is particularly bothersome patients so affected are sometimes afraid to eat because they directly relate the ingestion of food to an increase in the violence and frequency of their stools. Rectal tenesmus is a frequent symptom and is usually present in direct proportion to the severity of rectal involvement and to the frequency of stools In the milder or more chronic forms of the disease there is little or no increase in pulse rate or in elevation of temperature In the more acute forms, the pulse rate and temperature reaction keep in tempo with the degree of sepsis present Anemia is to be expected in patients showing nutritional deficiency, being a result of prolonged weakening from the disease or in the more acute forms, a result of direct loss of blood Loss of weight is an almost constant complaint unless the patient has had only an extremely mild form of the disease Extreme cachexia is one of the outstanding features of patients with the disease in the acute phase, who have been unresponsive to medical therapy In fact the weight of some of these patients drops down to 70 pounds or less This is the type of patient who is likely to maintain a septic temperature, who eats poorly if at all and passes an almost continuous watery stool heavily saturated with blood and pus

## PROCTOSCOPIC FINDINGS

In most cases important signs of the disease are evident in the rectum on proctoscopic examination It is important however, that the rectum may also appear to be normal and that the lesions encountered may not necessarily parallel the course of the disease or demonstrate the character of the lesions found elsewhere on the bowel

The earliest mucosal changes seen in the rectum are so unspectacular that one could not ordinarily be expected to make a diagnosis on the basis of the gross appearance These changes vary from a mottled discoloration, with very fine submucosal petechial hemorrhages and questionable edema, to a slightly inflamed mucous membrane that is finely granular and bleeds easily when touched with a cotton swab This state progresses to one showing small shallow ulcerations which, if present, are most likely to be located on the lower valve of Houston in the rectum The mucosa then becomes finely granular and pitted, and may bleed copiously at the points touched by the end of the proctoscope or by the cotton swab Under these circumstances, the hemorrhage from the mucosal surface may be so extensive as to make accurate inspection of the lining extremely difficult or impossible As the local process develops, ulcerations become larger, varying in size and depth, and in the intervening areas, a thick mucopurulent exudate, adherent to underlying mucosa is sometimes present

Upon examination of a patient exhibiting transition into the more chronic phase of the disease, it becomes plain that nature has been making an attempt to heal and repair the damage At this point in the course of the disease, islands of hyperplastic mucosa are seen, which assume the appearance of small polyps These lesions are called *pseudopolyps and are* thought to arise from the epithelium at the edge of the ulceration, or from the persistent islands of intact mucous membrane These polyps are also most likely to be found in the vicinity of the valves of Houston

In the more advanced stages of chronicity, the lumen of the rectum becomes narrowed and fixed and, in some places may even show evidences of stricture formation The wall loses its pliable nature and becomes almost cartilaginous There may be little or no edema in the quiescent phase, and the mucosa may not bleed on minimal trauma There is however, a tendency for the polypoid changes to persist Fistulous tracts to the perianal region may develop, and in the female patient these tracts sometimes penetrate the vaginal septum to produce a recto vaginal fistula

## RADIOLOGIC FINDINGS

One of the earliest signs of the disease detectable on barium x ray examination is an alteration of the mucous membrane pattern, caused by the edema This is most evident on the post evacuation film and is by no means pathognomonic As the pathologic process advances further, areas of opacity owing to ulceration or areas of irregularly rounded translucence owing to the polypoid changes may be detected The bowel tends to assume a tubular or ribbon like appearance, with loss of the normal haustral markings, which is in turn due to the edema and infiltration of its muscular layers This change may be more apparent on the films of the filled colon than on those taken after evacuation (Fig 20-4)

In the chronic phase of the disease, the bowel tends to become foreshortened, and the two flexures may drop from their usually high placement (see Fig 20 2 *Left, Right*) In some patients areas of persistent narrowing develop, which may progress to actual stricture formation

The typical and most frequently encountered picture demonstrates the disease as beginning in the rectum and extending *to the distal mid transverse colon* Under these circumstances, the proximal colon and terminal ileum may present a more or less normal appearance, with normal haustral markings and with normal mucous membrane pattern, the distal third or distal half of the transverse colon, the descending, and the sigmoid colon show no haustrations and appear tubelike The outline of the bowel may be perfectly smooth, but at times shows a feathery or jagged contour (see Fig 20-2 *Left*) Areas less thick with barium may reveal a mottled pattern of irregularly rounded opacities and translucencies caused by ulcers and pseudopolyps (see Figs 20-2 *Left*, 20-4 *Left, Right*)

In atypical cases the distal colon is free of disease, although the cecum and ascending colon are involved, however, this is a rare occurrence Occasionally, the entire colon is affected by the disease Other features that may be encountered on x ray examination are rigidity and loss of distensibility of the bowel wall, hypermotility, and occasional limitation of the disease to localized segments Retrogressive changes or progressive involvement of new areas within the colon may also be noted on repeated examination

It should be noted that the disease usually involves a greater length of the colon than is indicated by the roentgenograms.

Fig 20-4 (*Left*) Filled colon Film shows ribbonlike appearance and loss of haustral markings, particularly notable in descending colon. Translucencies are due to pseudopolyps in transverse colon (*Right*) Additional film showing translucencies in upper sigmoid colon, due to pseudopolyps and ulcerations

## DIAGNOSIS

The diagnosis of ulcerative colitis is revealed by the history In the more advanced stages of the disease, the proof is established by barium x ray examination and proctoscopy after ruling out other conditions that must be considered in the differential diagnosis In the milder forms of ulcerative colitis, it may take weeks, months, or years to arrive at a definite diagnosis, as the disease may go into remission before the bowel changes are definitely demonstrated on the films It is therefore worthless to attempt evaluation of any form of treatment, either medical or surgical, in the early mild form of the disease This is important inasmuch as diagnosis cannot be definite, and the remission may be spontaneous and not the result of treatment Provided the disease is sufficiently advanced, proctoscopic examination will usually suggest the disease under consideration, even if the observable lesions are not characteristic As an aid in diagnosis, areas of ulceration should be cultured, and portions of the mucous membrane should be removed for tissue examination from the edges of the ulcer or polypoid lesions On digital examination

the anus and lower rectum may seem perfectly normal, but in some patients a fibrotic change in the wall of the bowel is easily detected, and the consistency of the mucous membrane may suggest a thickened or granular change that is not as obvious on direct inspection

Abdominal examination of patients in the chronic stage of the disease is frequently unrewarding, as the abdomen may be completely devoid of any areas of tenderness or of changes from the normal In others, the descending and sigmoid colon can be outlined by palpation, as though it were formed into a rigid tube In some patients, localized areas of tenderness are found, which are due to the acute inflammatory reaction in the bowel wall

The barium x ray examination is the important factor in establishing the final diagnosis, by revealing the changes in the colon previously described Here, it is most important to issue a word of caution concerning barium x ray examinations during the acute fulminating phase of the disease or during an acute flare-up of the chronic continuous type The warning concerns the danger of bowel perforation by the introduction of the barium, and in particular, the introduction of air to obtain the contrast films In some patients, the marked irritability and spasm make it difficult or impossible to outline the colon in its entirety, but often, sufficient barium is retained in the bowel to demonstrate significant changes in the mucous membrane pattern

BACILLARY DYSENTERY This disease has a characteristic onset of severe diarrhea and high temperature, similarly seen, on occasion, in ulcerative colitis. Early in bacillary dysentery, the dysentery bacillus may grow in cultures made from fecal material removed at proctoscopy, or from scrapings obtained from the rectal ulcers After the first few days it is difficult to isolate and identify the organism, and in chronic cases, it is *rarely* possible to do so There is a strong resemblance in the clinical course of the two diseases, and the proctoscopic findings as well as those of the x ray studies may be identical It is possible that in some cases the ulcerative colitis may represent the terminal phase of bacillary dysentery

AMEBIC DYSENTERY The signs and symptoms of amebic dysentery may easily be confused with those of ulcerative colitis, but the differentiation can be established by proctoscopic examination and isolation of the ameba In patients with *acute* amebic dysentery, the ulcers are nearly always present in the rectum and vary from 0 5 to 1 5 cm in length They tend to be oval in shape and are likely to be covered with bloody pus, the removal of which gives the ulcer a punched out appearance Except under rare circumstances, amebic ulcers are discretely separated from one another by perfectly normal appearing mucosa In contrast, the ulcerations in ulcerative colitis are larger, are irregular in contour, have ragged edges, and tend to be confluent, with the intervening mucosa presenting an edematous and inflammatory appearance On the other hand, in chronic cases of amebic dysentery or in patients inadequately treated the rectum may not even present any pathologic changes

When ulcers are present the diagnosis of amebic dysentery may be made by placing the pus in a drop of saline and demonstrating microscopically the presence of motile amebae Otherwise, the ameba is searched for in a saline emulsion of a fresh warm stool specimen In patients with chronic dysentery, the fresh ameba is often impossible to detect in the stool, and an attempt should be made to demonstrate the cysts This may be accomplished by microscopic examination of an emulsion of stool, to which Lugol s solution has been added

On rare occasions, ulcerative colitis has been known to follow an attack of amebic dysentery It is also possible for a secondary infection to be superimposed upon an amebic infection, and thus produce rectal lesions indistinguishable from ulcerative colitis These two features make it imperative to search for the ameba in each instance Granulomatous lesions occasionally occur in association with

amebiasis, but such lesions are extremely rare in ulcerative colitis

REGIONAL ENTERITIS (TERMINAL ILEITIS, ENTEROCOLITIS) When first described about 25 years ago, the term "regional enteritis" referred to a localized inflammation of the terminal ileum that tends to undergo stenosis Since that time, it has been observed that in some patients enteritis can be associated with involvement of the proximal colon, and that at times segmental areas of the more distal colon exhibit similar lesions, with intervening areas of normal bowel In other patients, there may be segmental involvement of the ileum and higher jejunum, with intervening areas of normal looking small bowel The only confusion in distinguishing regional enteritis from ulcerative colitis occurs in patients who evidence involvement of the colon as well as the terminal ileum Some observers believe that the two conditions are intimately related and possibly have a common etiologic background In our opinion the differentiation is important only insofar as it affects the treatment under consideration

In regional enteritis, the clinical symptoms may be identical with those of ulcerative colitis but rarely are any ulcerations or inflammatory changes found in the rectum The two conditions can be differentiated by outlining the terminal ileum with barium In enteritis the terminal ileum appears to be narrowed and constricted and exhibits what has been termed the string sign' In ulcerative colitis where there has been retrograde spread of the disease from the colon into the terminal ileum there is marked dilatation of the ileum with a pattern of distorted mucous membrane rather than constriction

In enteritis the gross appearance of the terminal ileum is characteristic showing inflammation for a variable distance up to several feet The small bowel appears thickened and almost rigid and on palpation through its wall a lumen is undetectable The inflammatory changes extend up to the cecal wall, and there is marked thickening and edema of the mesentery with moderate enlargement of the lymph nodes Segmental areas of similar involvement may be found in the more proximal portion of the ileum or jejunum. The intervening small bowel may be normal in appearance.

TUBERCULOUS ENTERITIS The occurrence of tuberculous lesions in the colon is so rare that its differentiation from ulcerative colitis is of little practical importance The absence of an active pulmonary lesion in the presence of colonic ulcerations would be strong evidence against tuberculosis as the cause of the disease under consideration To make a definite diagnosis of tuberculous colitis, it is necessary to demonstrate that the lesion is typically tuberculous. This is accomplished microscopically by means of a diagnostic biopsy

SYPHILIS It is extremely rare to find syphilitic lesions anywhere in the large bowel except in the rectum Here the lesion is likely to be granulomatous, and is more likely to be confused with the lesions of lymphopathia venereum or with amebic granulomas.

CARCINOMA There should be no difficulty in distinguishing a carcinomatous lesion from an area of ulcerative colitis however, one should be constantly aware that the two diseases can exist and flourish in the same colon It is generally agreed that the lesions of ulcerative colitis can predispose a patient to the development of carcinoma Therefore, in each case every effort should be made to prove that there is no carcinoma present The question of malignancy will be discussed in more detail under Complications.

## PROGNOSIS

There are few diseases in which the clinical course is more unpredictable than in ulcerative colitis. However certain generalizations may be made concerning the relationship of the prognosis to the clinical manifestations of the disease It may be stated with reasonable certainty

that a high mortality can be expected in patients suffering from the acute fulminating form and that the prognosis is not good for those suffering from chronic continuous ulcerative colitis These two forms are therefore the ones in which continued effort is particularly needed toward lowering the mortality by improvements in surgical technique and management In contrast, a better prognosis is predictable for patients in whom the onset is insidious, in those in whom the disease is afebrile and nontoxic, and in others in whom regular remissions occur

The age of the patient bears a definite relationship to the outcome of his illness It has been noted by many observers that in younger patients the disease is more likely to be of the acute fulminating type In our own group of patients, this tendency was noted, in addition, complications seemed to be more frequent

The initial severity of the disease also seems to influence the outcome, and it is reasonably certain that those in whom the onset is mild are more likely to improve or recover than those in whom the initial symptoms are severe

The duration of the disease is an important factor in the life expectancy of the patient It has been noted that the mortality rate in large groups of patients drops in direct proportion to the number of years they have been suffering from their affliction The outlook seems to be best in those who have had symptoms for more than five years

The type and extent of anatomic involvement also has some effect on the prognosis Those in whom the disease is limited to the rectum and lower sigmoid are likely to do better than those with retrograde involvement up to the transverse colon Patients in whom the right colon is also affected are likely to do even more poorly In these patients, the incidence of free perforation of the bowel is higher The development of complications naturally affects the prognosis and darkens the outlook for recovery

## COMPLICATIONS

The complications that can develop in patients suffering from chronic ulcerative colitis are numerous Some are serious and others are mild, some occur frequently and others are rare They are best considered in the three categories of systemic, colonic, and anorectal, as follows

### Systemic Complications

The high fever and severe toxemia associated with the nutritional deficiencies that result from the body's inability to absorb and utilize nourishment are responsible for numerous complications Most of them, however are not peculiar to ulcerative colitis and may be seen in any patient suffering from a debilitating disease

*Anemia* is not uncommon and is of the secondary type it is either directly due to the loss of blood or is a result of the infectious process

*Hypoproteinemia* is frequently present, and there may be a reversal of the albumin globulin ratio, mainly because of a reduction of the albumin fraction

It is also possible for patients to develop a severe *electrolyte imbalance* during unusually severe bouts of diarrhea which, unless recognized and treated may result in death

The relationship of *liver disease* to the colitis is not clearly understood, but alterations in the liver have been noted and include fatty degeneration and cirrhosis The development of multiple liver abscesses has been reported, but is not likely to occur any more frequently than septicemia

*Arthritis* is a not infrequent complication and may be seen in 5 to 10 per cent of the patients It is undoubtedly toxic in nature, and unless well established usually disappears after a colectomy is performed Many observers consider arthritis an indication for colectomy, in order to prevent crippling from the resulting joint changes

*Cutaneous lesions* are common and may

rectum They might even develop following an ileostomy, and so constitute a hazard to the restoration of bowel continuity at a later date This type of narrowing is also seen in association with regional and right sided ulcerative colitis

The diagnosis of strictures in the rectum or lower sigmoid colon can be established by digital rectal examination and sigmoidoscopy, but when the lesion is located at a proximal level, barium x ray is necessary to reveal it Fluoroscopy and check up films may be needed to differentiate between a spasm and a stricture The stricture may progress to such a degree that obstructive symptoms develop, and the associated distention of the bowel at proximal levels may thus be a factor in perforation of the colon A suspicious narrowing of a defunctionalized colon should serve as a contraindication to eliminating the ileostomy and restoring bowel continuity

*Polyposis* is perhaps the most frequent complication of ulcerative colitis, but must not be confused with congenital familial polyposis, in which the polyps are entirely adenomatous As has been described in the section on pathology, the pseudopolyps in colitis are preponderantly inflammatory However, islands of adenomatous hyperplasia may also occur, which are difficult to distinguish grossly from those that are inflammatory, the inflammatory ones, or pseudopolyps, are found most commonly in the rectum on the valves of Houston In examining a removed colon, one should expect to find a steady decrease in the number of polyps, as the inspection progresses proximally This is only a generalization, however, as the disease follows no rigid pattern, and the polyposis may involve any part of the colon in a segmental or continuous pattern

*Carcinoma* of the colon occurs more frequently in association with ulcerative colitis than in the normal colon This fact has become more and more evident in the past two decades, as surgical experience has increased in the treatment of ulcerative colitis Bockus has reported the incidence of carcinoma to be 1 5 per cent in approximately 200 cases In our experience at Roosevelt Hospital, the incidence was 8 per cent in 185 patients surgically treated

It is true that some clinics and large hospitals are reporting a much higher incidence of carcinoma It must be realized, however, that the picture of the disease as a whole can be altered or confused by special circumstances or situations that surround any individual group of cases For example, a large proportion of our patients, referred to the senior author for operative treatment, were in a stage of intractability or otherwise urgently in need of surgery In addition to the fact that they had been suffering from ulcerative colitis for a period averaging seven years, 25 per cent showed pseudopolypoid changes in the colon It is reasonable to assume that a smaller incidence of carcinoma would be found if a more representative group of patients were studied This group would have to be a reasonably large one, and should include patients with the milder forms of ulcerative colitis, who are not in need of hospitalization

There is strong evidence to support the theory that the longer ulcerative colitis persists in a colon, the greater will the possibility be of carcinoma developing in that colon This is borne out by the finding that the majority of patients who develop an associated carcinoma are those who have suffered many years from the disease, or who have residual affected large bowel following ileostomy Undoubtedly, many of the latter would have died of the ulcerative colitis without the benefit of surgery, before carcinoma had sufficient time to develop or manifest itself

There continues to be some controversy as to the exact site of origin of these carcinomas Some believe that they arise from adenomatous polyps, some hold the inflammatory pseudopolyps responsible for them, while others believe that they originate from the epithelial edges of the ulcerated areas

The carcinomas may be multiple and

may occur anywhere in the affected colon, but are found most often in the rectum As a rule, these growths spread very rapidly, making for a poor prognosis

### Anorectal Complications

The complications that appear in this region are purely secondary to the purulent diarrhea and include anal fissures and hemorrhoids which often complicate fistulous formations

Other factors that may be considered equally unfavorable are emotional stresses of various kinds and the development of mental depression Interestingly enough pregnancy does not seem to influence the course of the disease

## TREATMENT

Initial treatment for every patient with ulcerative colitis should be medical, regardless of whether or not operative intervention is being considered A low residue diet high in proteins is generally preferred and patients seem to do better if the carbohydrate intake is reduced If the diarrhea is excessive it may be necessary to correct the fluid and electrolyte imbalance with intravenous therapy Along with the loss of fluid there is often a loss of minerals iron and calcium in particular The iron deficiency should be remedied by the oral administration of ferrous sulfate in doses of 0 2 to 0 4 Gm daily The calcium may be administered intravenously once a day in the form of calcium intravenous infusions The antibacterial agents that have been employed include the sulfonamides and the various antibiotics There is no convincing proof that any one of these agents has definitely influenced the ultimate course of the disease In our experience, the employment of the sulfonamides alone for five to seven days, in the form of Sulfasuxidine or Sulfathalidine, proved to be helpful as an immediate preoperative medication These are also effective agents when used in combination with neomycin In recent years we have been inclined to favor a 48 hour preparation for surgery, using 1 Gm of neomycin every four hours.

Corticotropin and the adrenal steroid hormones have been found effective in suppressing and ameliorating the symptoms, and seem to have induced remissions in some cases of the acute fulminating form of ulcerative colitis There is no concrete evidence, however, that these endocrine agents are curative or that they will ultimately alter the final result of the disease They are sometimes effective in the immediate preoperative preparation of the patient and may favorably affect the operative risk involved The steroids are believed to have the adverse effect of promoting bowel perforation and of accomplishing it in a relatively silent manner Inasmuch as the acute fulminating form of the disease is the one in which intestinal perforation is most likely to occur and is also the type in which the patient is most likely to be critically ill cortisone and ACTH must be used with

those who have failed to respond to medical therapy, and have reached such an advanced state of invalidism that they are no longer able to lead a normal life either physically or socially They may have experienced some remissions but these have become less frequent and of shorter duration Finally the diarrhea, chronic anemia, avitaminosis, and extreme state of malnutrition make it impossible for these individuals to lead a productive existence, and surgery offers them the only possibility of rehabilitation and a return to their former way of life *It is important for* both physicians and surgeons to recognize patients in this advanced stage as early as possible Months and years of invalidism may thus be avoided, and early recognition may prevent more urgent surgery at a later date, necessitated by complications

ACUTE FULMINATING ULCERATIVE COLITIS In the past, the mortality among patients with this type of disease was higher than for any of the others, regardless of whether they were treated medically or surgically However, in recent years we have been able to reduce the mortality drastically by a more aggressive approach

Early in our experience with the treatment of this phase of ulcerative colitis, the desperate physical condition of these patients usually prompted us to continue with supportive treatment, if surgery *was* attempted, the procedure was limited to an ileostomy It soon became evident, however, that dramatic improvement from an ileostomy could rarely be expected The shock of this relatively minor procedure in these extremely ill patients, together with the physiologic disturbance caused by the ileostomy, was sufficient to result in a formidable hospital mortality rate

In the past ten years, Ripstein, Ravitch (1955), Brooke (1951), and others, as well as the present authors, have advocated for these patients ileostomy combined with partial, subtotal, or even total coloproctectomy in one stage We have also abandoned simple ileostomy as a preliminary first stage procedure, and feel that the aggressive approach has proved more successful in every respect The ease with which patients have tolerated the more extensive surgery has been most gratifying The reason for success seems to lie in the removal of the source of the toxemia, which is accomplished by excising the diseased colon in its entirety whenever possible The reaction to operation has been further minimized by the use of hypothermia, which will be discussed later in the chapter

PERFORATION As mentioned previously, this is a most serious complication, but *fortunately perforation into the free peritoneal cavity* is rare The sudden development of diffuse generalized peritonitis is so shocking to the patient that, as a rule, he is unable to withstand anesthesia or the most minor surgical procedure In the past, treatment for such patients was essentially supportive, and regardless of what was done, most of these patients died When the patients improved, an ileostomy was performed at the earliest opportunity Localized abscesses were dealt with as they occurred and were treated by incision and drainage At the present time, it is possible to save many of these patients by an ileostomy and total colectomy in one stage, performed with the aid of hypothermia

Impending perforation is an urgent indication for surgery and should also be treated by ileostomy and total colectomy in one stage, if possible Perforation of the bowel, with abdominal signs indicating localization of the process, if diagnosed early before a frank abscess has formed, should be similarly treated In many instances, these perforations are sealed off against the anterior abdominal wall or some other viscera, and the spillage has been minimal, if at all

Extraperitoneal perforations originating from the involved rectum can result in perirectal abscesses and fistulas, or can extend to form a perineal abscess that will need incision and drainage It is useless, however, to attempt surgical correction of a fistula in ano, as rectal incontinence inevitably complicates the procedure Removal of the rectal segment is required to eliminate the fistula in ano Recto-

vaginal and rectovesical fistulas also occur and are additional reasons for removal of diseased bowel

Although perforation of a diseased transverse colon into the duodenum or stomach occurs only rarely, such a fistula requires resection

HEMORRHAGE The presence of blood and pus in the stool is so common in ulcerative colitis that its presence immediately suggests the diagnosis While *massive* exsanguinating hemorrhage is rare, extensive bleeding is not uncommon and is a most important indication for ileostomy and colectomy Bleeding may also occur after ileostomy alone, or after ileostomy and partial colectomy It has even been known to proceed from the rectum after ileostomy and subtotal colectomy, and from an ascending ileitis after total proctocolectomy If massive hemorrhage occurs, it should be treated aggressively by multiple transfusions, in conjunction with an emergency ileostomy and total colectomy in one stage, as this approach offers the patient the best chance of survival

TOXEMIA The extreme toxemia exhibited by some patients with ulcerative colitis is a characteristic of the acute phase, and indicates its fulminating nature The degree of toxemia is expressed by temperature elevation, rapidity of pulse, and the general appearance of the patient It is a direct expression of the extent and nature of the inflammatory ulcerative disease in the bowel Theoretically the disease process should be retarded by a complete diversion of the fecal stream and an ileostomy certainly seems the simplest means of accomplishing this end In actual practice however, the very toxic patient has proved to be a poor candidate for this simpler procedure, as it rarely checks the toxemia, and is associated with a high mortality It is now recognized that if the diseased colon is also removed when the ileostomy is performed, the toxemia will promptly disappear and there will be less reaction from the operative procedure After the more aggressive procedure, the prompt drop in temperature to normal levels is little short of dramatic, even though the pulse may remain rapid for several weeks The disturbed physiology occasioned by the ileostomy is much less marked than when the diseased colon has been left behind, and this is reflected in less disturbance of the electrolyte balance.

Occasionally, the condition of the acutely ill patient can be improved by a few days of preoperative treatment with ACTH and cortisone However, one must be well aware of the dangers involved in using the corticosteroids except for the briefest of periods, as they do promote ulceration and perforation that may sometimes occur without the slightest warning Perforations can develop from new ulcerations in the stomach, ileum, or jejunum, as well as from the old lesions within the diseased colon

OBSTRUCTION Stricture formation in the colon may result from the extensive fibrosis that is seen in patients who have had the disease over a period of years Repeated episodes of exacerbation, followed by remissions, result in the healing of ulcerated areas by scar formation The end result of this process may be an actual stricture, which can produce an obstruction as rapidly and as unheralded as a constricting carcinoma

When a patient has an acute obstruction and is in the chronic phase of the disease, the preferred treatment is an ileostomy, preparatory to a total colectomy. In the acute fulminating phase ileostomy and partial or total colectomy should be performed The patient under medical treatment who exhibits persistent and progressive narrowing of the bowel either by barium examination or proctoscopy, is a potential candidate for the development of obstruction and surgery should be advised before this complication sets in.

CARCINOMA There seems to be definite relationship between the prolonged chronicity in the colon and the development of carcinoma and this is discussed in more detail under Pathology In our series of patients, the overall incidence of car

cinoma was 3 7 per cent while the incidence in 185 patients surgically treated was 8 per cent Cattell expresses the opinion that the longer a patient suffers from ulcerative colitis, the greater is the likelihood of malignant degeneration developing in the diseased colon He states "In that group of patients who have had the disease for ten years or more it has been found to range from 25 to 50 per cent"

Carcinoma has not uncommonly been found to develop in the rectal segment some years after an ileostomy and subtotal colectomy have been performed, and this is an important reason for recommending total removal of the entire large bowel in one or two stages The rectum is the most common location for these carcinomas but they can occur anywhere in the colon Patients under medical management who have had the disease for any length of time, particularly those showing polypoid changes, should have frequent proctoscopic and barium x-ray examination, in order to detect malignant changes when they are still in their incipiency An abdominoperineal resection is strongly advised for patients who have already been subjected to ileostomy and subtotal colectomy, particularly if the rectum shows residual disease

When discovered, carcinoma should be treated without delay by radical excision In some cases, metastases may permit only a palliative procedure, in others, the local spread of the disease may even prevent palliation Unfortunately, carcinomas associated with ulcerative colitis are likely to be very malignant, a feature that is probably related to the inflammation and excessive vascularity of the area in which they arise The poor prognosis associated with these growths is a strong argument in favor of prophylactic ileostomy and colectomy in all patients showing extensive pseudopolyposis

MANIFESTATIONS OF FOCAL INFECTION There are some lesions, though not necessarily adjacent to the intestinal tract, so frequently seen in patients with ulcerative colitis that they are believed to be secondary to the infectious process in the bowel These secondary manifestations are placed in the category of focal infections, of which infectious arthritis is considered to be one of the more serious One or more joints may be affected, but usually the manifestation is polyarthritic in nature Removal of the diseased colon generally results in prompt disappearance of the acute symptoms in the joints, and should be performed before the joint changes become permanently crippling Among other focal lesions that may be considered as indications for elective surgery are pyoderma gangrenosa, recurrent skin ulceration, furunculosis, erythema nodosum, stomatitis, ophthalmitis, conjunctivitis, and neuritis

## Types of Surgical Procedures

A study of the pathogenesis of ulcerative colitis reveals it to be a disease that may assume many forms, varying from an extremely mild infection to that of a virulent one that can kill in weeks or months In the majority of patients it involves the rectum and distal half of the colon, but in some it is found in only the proximal half, or in segmental areas It is important for the surgeon to be aware of the fact that in some patients the terminal ileum may also be diseased The complex nature of the bowel disease dictates the selection of the specific operative procedure, based on the degree and extent of involvement The various procedures that may be used are discussed below

PARTIAL OR SUBTOTAL RESECTION WITHOUT ILEOSTOMY In right sided ulcerative colitis with or without involvement of the terminal ileum, a right hemicolectomy with an ileotransverse colostomy to restore continuity of the bowel is a procedure that can be used with success It represents an acceptable and conservative approach to the treatment of the disease when confined to this location In performing this operation, the surgeon must be reasonably sure that no disease exists distal to the point of anastomosis. Accordingly, in order to avoid leaving behind unrecognized pathologic tissue, a point should be

chosen approximately twelve inches away from the grossly diseased area for division of the bowel Similar precaution should be taken in dividing the ileum In order that "skip areas" of segmental disease may not be overlooked, the entire small bowel should be inspected before deciding on the level of resection The decision to perform a right hemicolectomy should be made with the realization that a recurrence may develop in either the small bowel or the remaining colon It is for this reason that patients should be followed up meticulously for years after this type of operation

If the disease is confined to the ascending and transverse colon, resection down to the sigmoid colon with an immediate anastomosis of the ileum to the sigmoid colon (ileosigmoidostomy) may be performed Although this procedure may occasionally prove successful, it has been our experience, as well as that of others, that in most patients it results in an extension of the disease and recurrence of symptoms If the disease does recur, total proctocolectomy must then be done

The danger of recommending partial colectomy for any patient with localized disease lies in the inability to determine positively the fine line of demarcation between a healthy bowel and one that is diseased Proctoscopy, barium x ray tests, and even inspection and palpation of the bowel at operation are not sufficient to enable the surgeon to make this identification positive

PROCTECTOMY WITH SIGMOID COLOSTOMY In the *rare* case where the disease is completely confined to the rectum, it may be worth performing an abdominoperineal resection with a sigmoid colon-

may recur in the residual colon, and that a secondary procedure (right hemicolectomy and ileostomy) may have to be performed The risk is a reasonable one to take, as long as there is no suspicion of disease in the transverse colon.

ILEOSTOMY In the past ten or fifteen years there has been a changing attitude toward the value of ileostomy alone as the primary procedure, with particular reference to its use in the acute fulminating phase of the disease At one time, conservatives felt that ileostomy alone carried such a forbidding mortality that patients had a better chance of recovery if kept on medical treatment Others, including the authors, took a more aggressive attitude and, for a time, in the face of a mounting mortality, persisted in employing ileostomy alone for the desperately ill patients Over the years, the mortality eventually soared to greater than 50 per cent, and although ileostomy has not been abandoned completely as the primary procedure, we now think it should be reserved as a desperation measure for exceptional cases only We believe that the best treatment for fulminating ulcerative colitis is a combined ileostomy and total colectomy in one stage In recent years, it has been shown to carry with it a greatly reduced mortality rate

As indicated above, ileostomy alone may be used as an emergency procedure for perforation, massive hemorrhage, and obstruction However, it is important to recognize that it may do little to remedy the situation Despite diversion of the fecal stream, bleeding may continue or peritoneal contamination from a thoroughly diseased and perforated colon

and for those in whom it is hoped that later restoration of bowel continuity can be established This is more than likely a vain hope, but most patients will welcome the gamble in the hope that eventual removal of the rectum will not be necessary This procedure is also recommended for patients with disease throughout the rectum and colon who, it is felt, cannot tolerate a total proctocolectomy in one stage

ILEOSTOMY AND TOTAL PROCTOCOLECTOMY IN ONE STAGE This one-stage procedure is definitely recommended for patients in a chronic phase of the disease who at the time are not acutely ill or febrile It is advantageous to use this operation when the disease is intractable and further continuation with medical therapy alone is considered hazardous

To re emphasize the point, it has been our experience in recent years that the use of hypothermia has broadened the indications for surgery With hypothermia, we find that patients with acute fulminating colitis tolerate this more formidable operation better than they tolerated *ileostomy alone* in the past

## Surgical Techniques

### *Simple Ileostomy*

A most important consideration preliminary to the performance of any ileostomy is the choice of its placement on the abdominal wall The site must be selected in such a way that the disk of the ileostomy bag will not be in contact with the navel or with scars, and will not be too close to the bony prominence of the ileum In addition, the bend of the patient's waist should *not in* any way interfere *with the* adherent qualities of the disk The choice of the exact location of the ileostomy should be made in each case with these considerations in mind Generally, the most favorable site for the ileostomy will prove to be on the right side, slightly below the mid point, between the umbilicus and the anterior superior iliac spine If necessary, the site chosen can be marked with an intradermal injection of methylene blue, just after induction of the anesthetic or on the day prior to operation

The *loop ileostomy* has proved to be a most unsatisfactory procedure as it does not adapt itself to the use of an ileostomy bag *Terminal ileostomy* is for this reason the procedure of choice When performed without colectomy, the distal divided ileum should not be closed and replaced within the abdomen, but should be brought out through a separate incision in the form of a mucous fistula Otherwise, there is the danger of a possible 'blowout" of the closed stump, resulting from the progress of the disease within the colon and terminal ileum The mucous fistula is a safety valve and acts as a vent for the escape of retained secretions

Where it is intended to limit the procedure to an ileostomy, a left rectus incision with its center at the level of the umbilicus should be used to enter the abdomen (Thus, should the surgeon change his mind and decide to do a colectomy, the incision can be lengthened in order to obtain adequate exposure ) The colon, particularly the ileum, is inspected through this incision, and a point at least 12 inches from the ileocecal valve is chosen as the site for division of the ileum It is not too uncommon to find that the disease has spread to the terminal ileum, or to find multiple 'skip" areas of inflammation in the small bowel It is therefore wise to inspect the entire small bowel before dividing it, and then take great care to choose a point at least 12 inches proximal to areas in which gross pathologic changes are suspected

It is important to develop adequate length in preparing *the limb of intestine* to be used in performing the ileostomy, so that when it is brought out on the abdominal wall, the ileum can project as much as two and a half or three inches beyond the skin level This length can be obtained by isolating, ligating, and dividing the vascular arches individually, so that the intervening fat is not shortened or 'bunched' by the ligatures In order to get added length, the mesentery of ileum can also be incised deeply towards

its base, the ileum is then completely denuded of its mesentery over a small area, where it is clamped and divided

A small circular button of skin is then excised at the site selected for the ileostomy stoma The underlying fascia is exposed, and incised in a cruciate fashion so as to prevent constriction of the ileum The underlying rectus muscle and peritoneum are then opened vertically, the proximal limb of ileum can now be brought through the opening after its division and temporary closure Another method is to pass a clamp through this opening to occlude the ileum, dividing the gut distal to the clamp, and withdrawing the clamp through the opening to bring the ileum out onto the abdominal wall

The distal ileum can be similarly brought out through a small McBurney incision, laterally or superiorly placed, so that it will not interfere with the disk of the ileostomy bag (This limb of ileum has been termed a mucous fistula," as it serves as a vent for accumulated secretions )

Proceeding with the development of the stoma, when the Turnbull or Brooke procedures are used the ileum is brought out on the abdominal wall so as to project two and a half to three inches beyond the skin level Otherwise the ileum is allowed to protrude one to one and a half inches In recent years, great emphasis has been placed on the causal relationship between the small segment of exteriorized ileum and ileostomy dysfunction It has been suggested by Turnbull and others that this dysfunction is the result of the inflammatory change, or serositis, and is limited to the exposed peritoneum of the exteriorized wall Garlock believes that this inflammation ascends to a point where it involves the intraperitoneal ileum, and thus plays an even more extensive role in the dysfunction

It is important to fix the mesentery of the ileum in one of the following ways To the lateral lumbar gutter, to the falciform ligament, as described by Turnbull or distally to the peritoneum of the anterior abdominal wall, as shown by Garlock The latter also recommends plication of several loops of ileum just proximal to the point of its emergence from the peritoneum

All these measures are important in lowering the incidence of both intestinal obstruction and prolapse through the ileostomy stoma Fixation of the mesentery to the peritoneum also prevents retraction of the ileostomy It is most important to avoid suturing the serosa of ileum to any of the layers within the anterior abdominal wall, as the resulting local irritation and secondary infection are likely to lead to stomal fistula formation

Although simple exteriorization of the ileum is the method used by many surgeons in performing the ileostomy, there are several other procedures in use, three of which are here discussed

TURNBULL METHOD The surgical steps used in developing the mucosal grafted ileostomy are shown in Figures 20 5*A* and 20 5*B*, and are as follows

Management of terminal ileum, see Figure 20 5*A*

a Circular incision of skin at ileostomy site in right lower quadrant
b Schematic representation of division by cautery of ileum between clamps, to minimize contamination
c Terminal ileum pulled through the opening until two inches are exteriorized
d Mesentery in superior position at point of exit, where it is sutured so that retraction will not take place
e The remaining mesenteric border sutured superiorly as far as the free edge of falciform ligament

Technique of preparing mucosal graft, see Figure 20 5*B*

a Mesentery of ileum ligated and divided about one inch from skin with use of fine atraumatic catgut
b Seromuscular layer carefully incised vertically and circumferentially, with dull pointed scissors held vertically
c, d Seromuscular flap carefully teased away from underlying submucosa




Fig 20-5A Steps in construction of an ileostomy (*From* R B Turnbull, Jr, *S Clin North America*, August, 1956 )

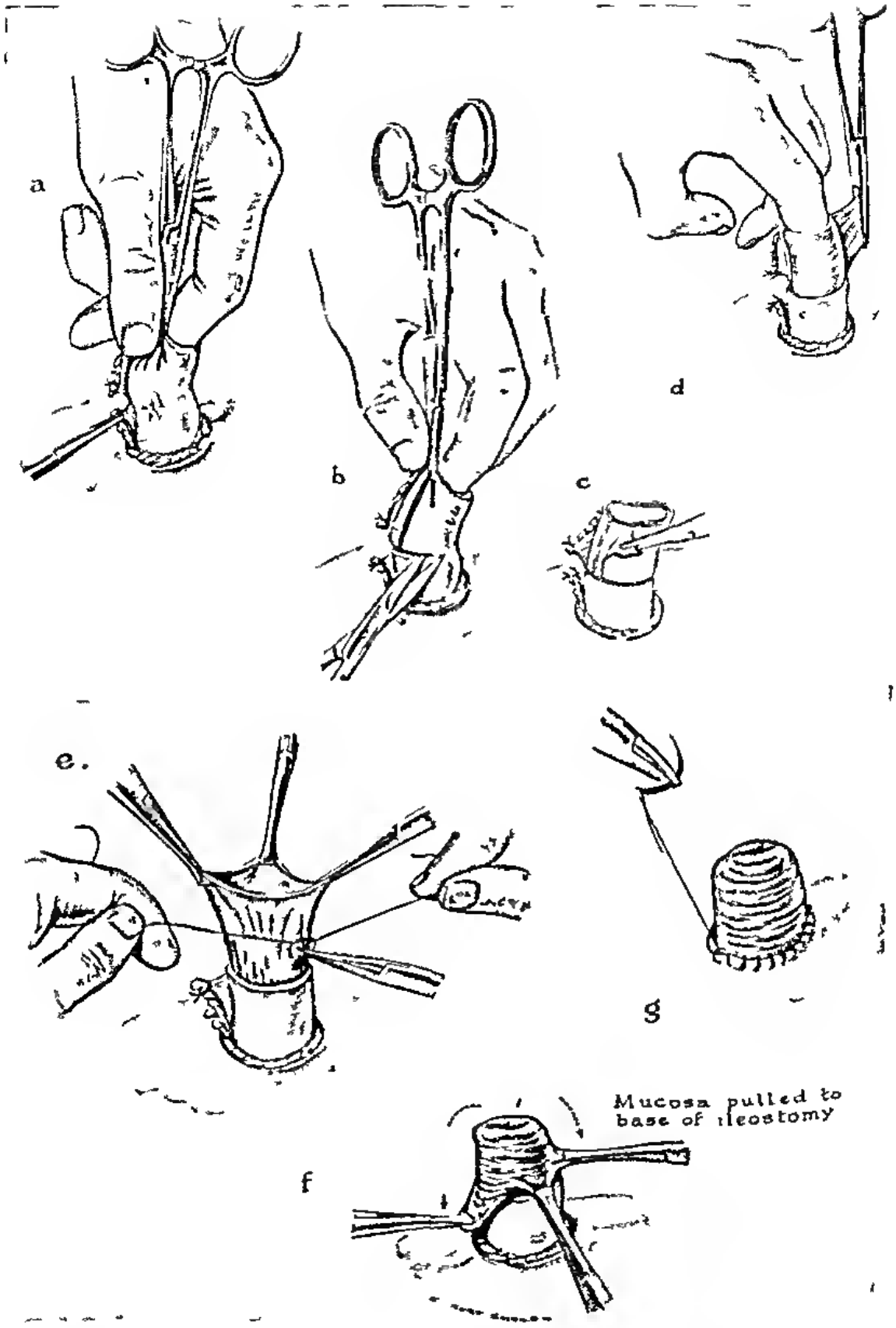


Fig 20-5*B* Steps in preparation of the mucosal graft (*From* R. B Turnbull, Jr, *S Clin North America,* August, 1956)

until proper plane is reached (The muscular layer is extremely thin and separates easily )

e One bleeding point ligated with fine catgut (Hemostasis is most important )

f Mucosal submucosal pedicle graft pulled down over undenuded proximal ileum

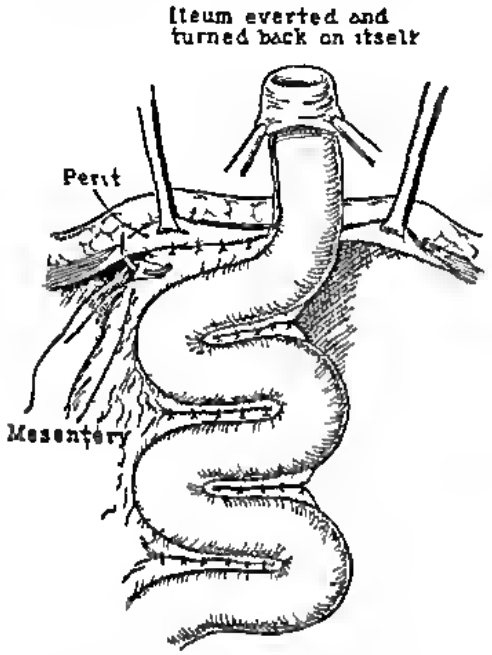


Fig 20 6*A* Noble plication, fixation of mesentery, beginning eversion of mucous membrane (Brooke) (*From* J H Garlock, *Surgery*, vol 40, October, 1956 )

g Graft very loosely approximated to skin margin, with continuous fine atraumatic No 4 0 chromic catgut

After the graft is secured to the skin, a plastic disposable ileostomy bag is applied As Turnbull points out, 'Care should be taken to avoid the use of Karaya gum powder as it causes sloughing where it comes in contact with the mucosal graft" (The powder seems to be well tolerated after the fifth postoperative day )

GARLOCK METHOD This technique varies from that of Turnbull in several important points See Figures 20 6*A* and 20 6*B*

Management of terminal ileum, see Figure 20 6*A*

The cut edge of the mesentery is fixed to the parietal peritoneum, caudad to the point of emergence of the ileum onto the abdominal wall A modified Noble plication of the terminal 18 to 24 inches of ileum is also performed These two steps are taken in the hope of preventing any tendency for later prolapse at the stoma or partial obstruction within the abdomen

Management of exteriorized ileum, see Figure 20-6*B*

The mucosa of exteriorized ileum is then everted after the fashion of Brooke

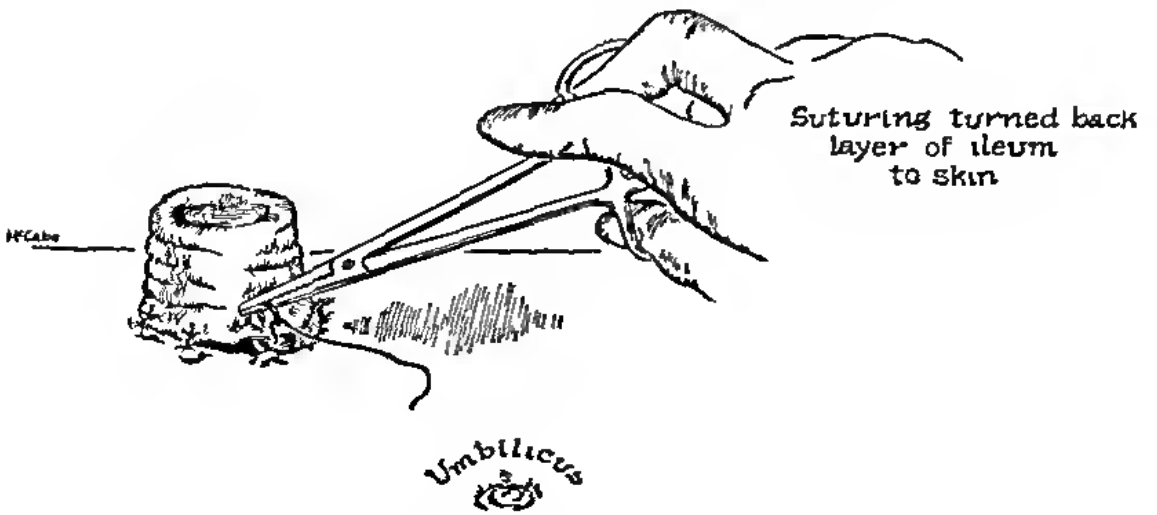


Fig 20 6*B* Completed eversion of mucous membrane and fixation to skin. (*From* J H Garlock, *Surgery*, vol 40, October, 1956 )

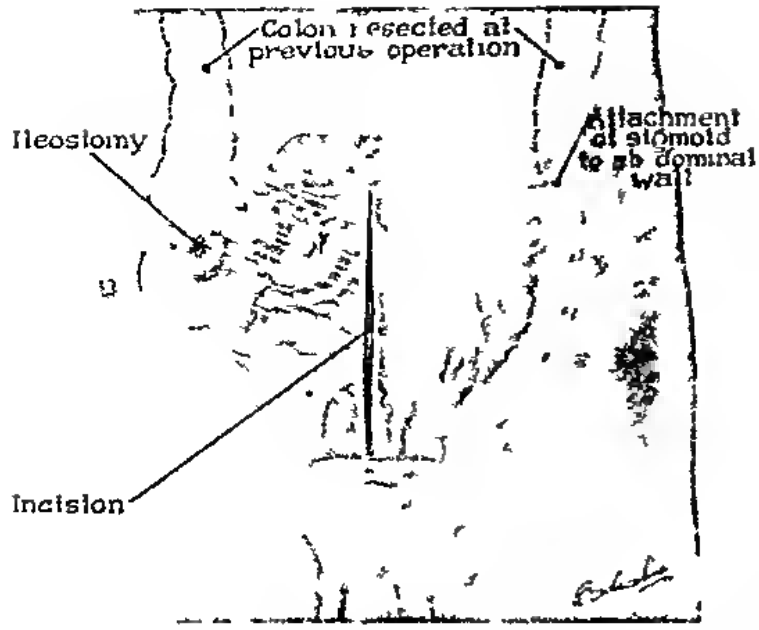


Fig 20-7 The mid line incision in a patient who had previously undergone ileostomy and subtotal colectomy (*From* M M Ravitch, *Surgery*, vol 24, August, 1948)

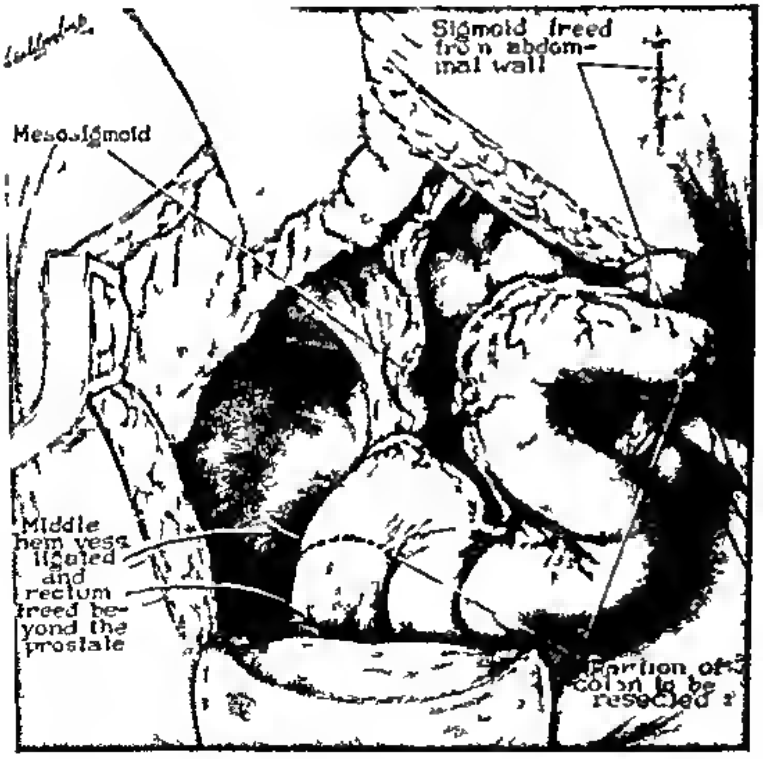


Fig 20-8 Closure of sigmoid colostomy, and mobilization of sigmoid and distal rectum to a point beyond prostate (The area to be resected is outlined) (*From* M M Ravitch, *Surgery*, vol 24, August, 1948)

(Fig 20-6*A*), the mucosa is not first denuded of its seromuscular layer, as is done in the Turnbull procedure

DRAGSTEDT METHOD This procedure consists of applying a split thickness skin graft to the ileum, protruding approximately 8 cm beyond the skin of the abdominal wall A catheter is first fixed inside the ileum, and is removed before the sixth or eighth postoperative day Slits in the skin graft are recommended to provide for drainage, a pressure dressing, snugly applied, is also suggested to promote healing of the graft

We believe there are disadvantages to this method There is a tendency for the skin graft to break down and become ulcerated, and for the bulky nature of the

Fig 20 9 Sigmoid and major portion of rectum excised ileum freed from abdominal wall and tied with heavy braided silk rectal stump similarly closed (*From* M M Ravitch *Surgery* vol 24 August 1948 )

stoma to create difficulty in using the ileostomy bag

### *Anal Ileostomy*

This procedure is still a controversial one not only because of the technical difficulties involved but also because it can later cause the patient great distress in the management of his bowel movements Schneider believes that this difficulty can be minimized by employing the anal ileostomy as a two stage procedure with the aid of a preliminary temporary ileostomy He states that in his experience patients generally experience stool urgency and frequent bowel movements during the early postoperative period but later settle down to three or four semisolid stools during the day and a similar number during the night

Even though there are reservations about this procedure it might be tried for patients who have already undergone ileostomy and subtotal colectomy and who refuse at first to have the diseased rectum removed Some of these patients become willing candidates for removal of the rectum upon learning that the ileos

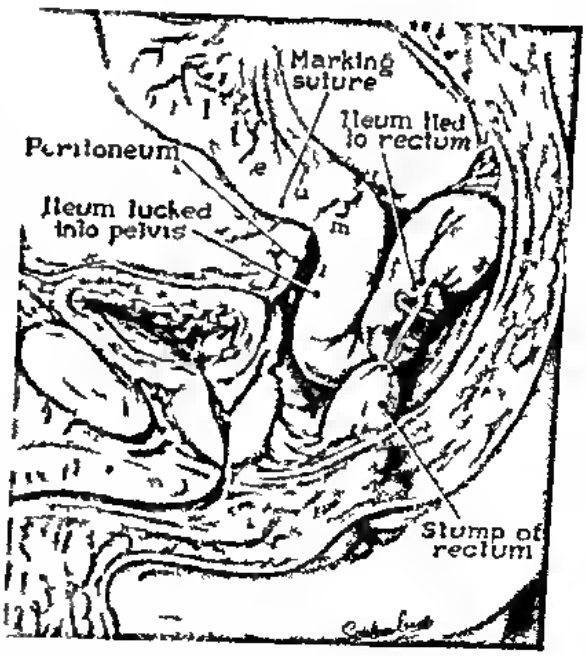


Fig 20-10 Sufficient ileum tucked low into pelvis to allow for performance of anal anastomosis without tension silk suture as marker on ileum to fix site for closing pelvic peritoneum Ligatures closing ileum and rectum tied together securely (*From* M M Ravitch *Surgery* vol 24 August 1948 )

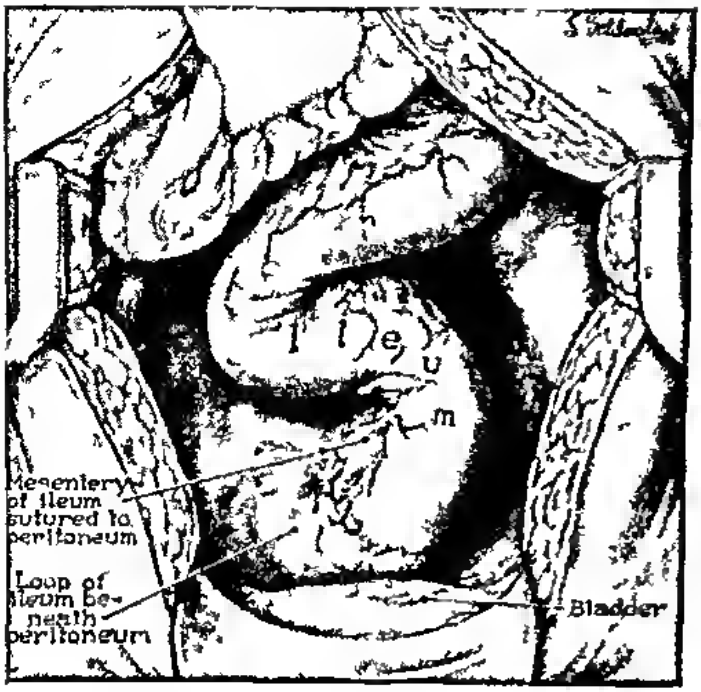


Fig 20 11 Pelvic peritoneum repaired by being attached to sides of ileal mesentery and to no more than two thirds of bowel wall (*From* M M Ravitch, *Surgery*, vol 24, August, 1948)

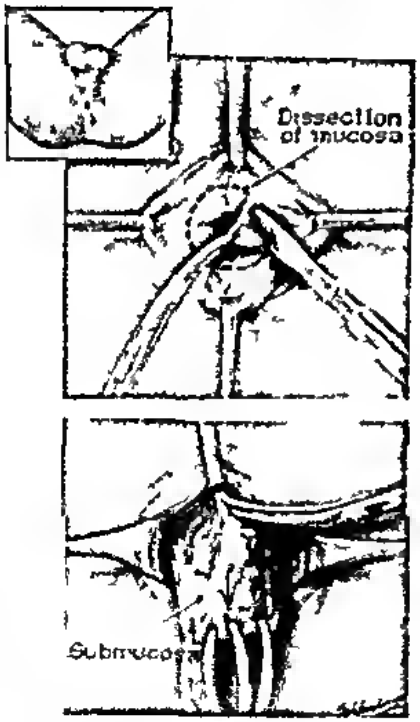


Fig 20-12 Abdominal wounds closed, and patient placed in lithotomy position anal margins grasped with Allis forceps, and circular incision made at mucocutaneous junction, internal and external sphincters retracted, cuff of mucosa and submucosa developed, with small curved scissors, over a distance of two to three inches. (*From* M M Ravitch, *Surgery*, vol 24, August, 1948)

tomy will be transplanted to the anal site. Two techniques are here presented

RAVITCH PROCEDURE The steps are shown and described in Figures 20-7 to 20 14 An alternate method of constructing the anal ileostomy is given in a more recent publication by Ravitch (1951) By this method, the procedure is performed with the patient lying in the combined lithotomy Trendelenburg position (Figure 20 15*A*, *B*)

SCHNEIDER PROCEDURE. This differs from Ravitch's mainly in the principle of producing a *nonfunctioning anal* ileostomy with a diversionary proximal ileostomy at the first stage At the second stage, the proximal ileostomy is removed from the abdominal wall and anastomosed to the proximal end of the dysfunctionalized anal ileostomy loop It is recommended, in using this procedure, that the first stage be combined with total proctocolectomy, although, as with the Ravitch procedure, it can be employed following a previous partial or subtotal colectomy where an ileostomy already exists. As described by Schneider, the operation is briefly as follows

*Stage 1* With the patient in a lithotomy position, the terminal ileum is transected through a long left paramedian incision

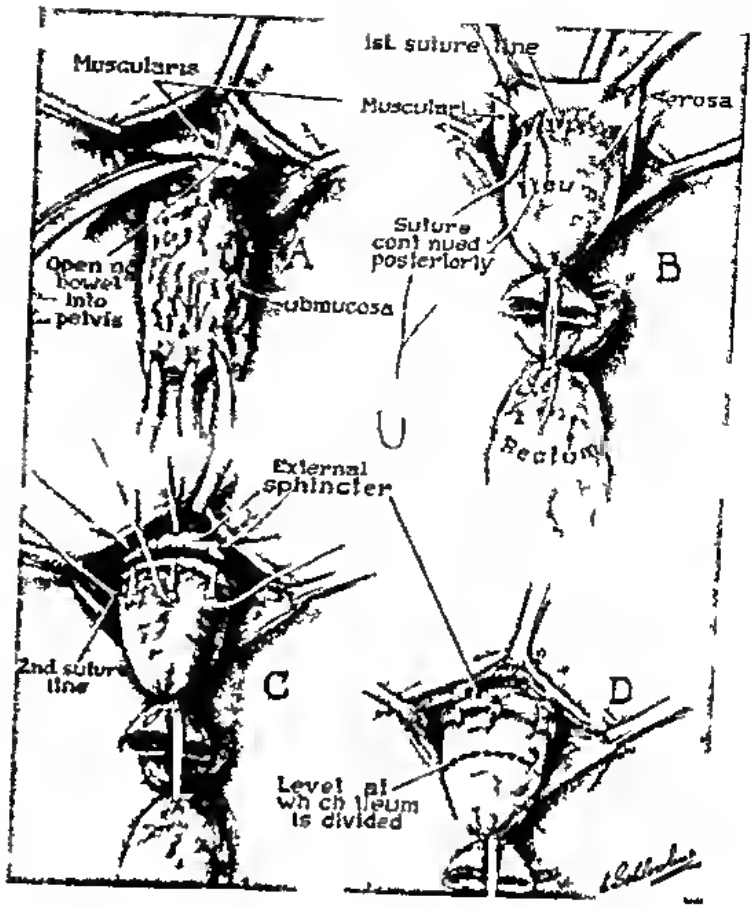


Fig 20 13 (*A*) Level at which the muscularis is incised to enter pelvis rectum freed completely by continuation of incision around entire circumference (*B*) Everted coats of muscularis attached to ileum with a continuous suture of No 0000 catgut (*C*) External sphincter also attached to ileum with interrupted fine catgut after the first suture line has been allowed to retract (*D*) Level of division of ileum (*From* M M Ravitch *Surgery* vol 24 August 1948 )

so as to be wide of diseased areas and yet so placed as to preserve a length of healthy distal ileum long enough to be pulled beyond the anal cuff The development of this segment of ileum is most important as experience has shown that tension with retraction may eventually lead to a disruption of the anal ileal anastomosis to be performed Figures 20 16 to 20 20 show the steps in the two operative procedures that complete this first stage

*Stage 2* This stage is performed about three months later An important prerequisite is having the patient demonstrate his ability to retain 100 cc of water injected into the dysfunctionalized distal ileum and to be able to retain it up to its expulsion about four hours later

The procedure entails removing the terminal ileostomy from its position in the right quadrant after reopening the lower half of the left paramedian incision An end-to-end ileoileostomy is then performed between the proximal ileum and the distal dysfunctionalized loop

*Total Proctocolectomy*

In performing the total removal of the colon and rectum the choice of anesthesia is very important Although many surgeons prefer spinal anesthesia some patients are very apprehensive and it is preferable to have them completely unconscious

Hypothermia (Fig 20 21) is also rec

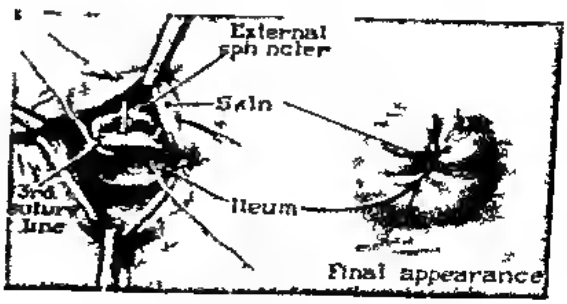


Fig 20-14 A third row of interrupted sutures inserted to approximate the cut edge of ileum to skin edge (*From* M M Ravitch *Surgery* vol 24 August 1948 )

ommended when total proctocolectomy is performed in one stage Under these circumstances the operation is usually commenced when the temperature in the process of falling has reached 94° F We enabling the patient to tolerate the extensive surgery with minimal or no reaction It is also notable that the bleeding and oozing so frequently encountered in patients with acute fulminating ulcerative

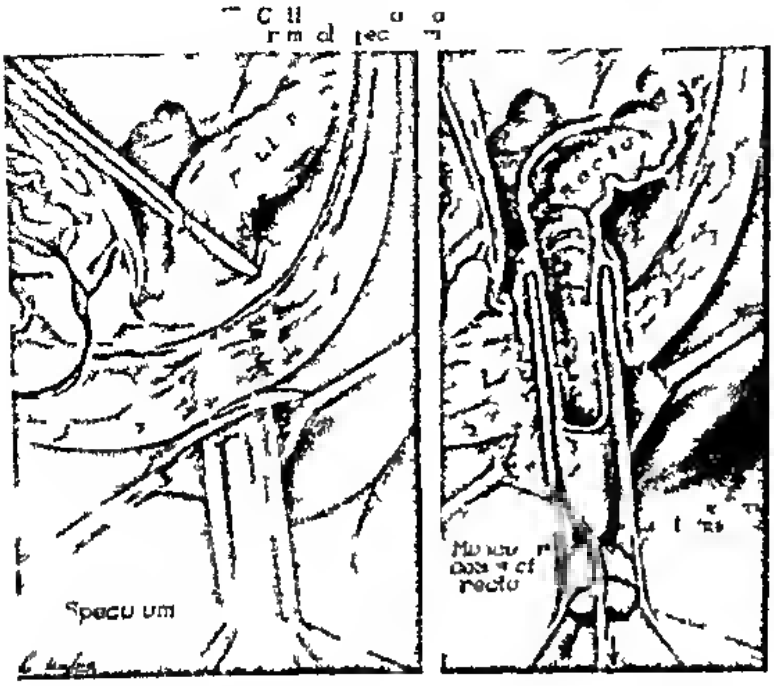


Fig 20-15 Anal ileostomy alternate method (Perineal and abdominal phases performed simultaneously) The rectal mucosa and submucosa are dissected from the rectal muscularis to a level above the levators A speculum is introduced over this cuff An incision is made on the edge of the speculum freeing the upper rectum and the lower rectal muscularis and phincter (*From* M M Ravitch and J C Handelsman *Bull Johns Hopkins Hosp* vol 88 January 1951)




Fig 20-15*B* The ileum has been drawn through the cylinder of rectal muculature and the ileal serosa is tacked to the rectal muscle Two additional rows of sutures are placed (1) between ileum and external sphincter and (2) between the end of ileum and the anal skin The peritoneum is simultaneously repaired from above Usually several loops of ileum lie beneath the peritoneum (*From* M M Ravitch and J C Handelsman *Bull Johns Hopkins Hosp* vol 88 January 1951)

have preferred to keep it at all times above 89° F and believe that the optimum temperature is 92° F (A more detailed discussion of hypothermia is given in Chap 3 on anesthesia) The fall in metabolic rate associated with hypothermia seems to be the major factor in colitis is greatly diminished An endotracheal tube is routinely used for all patients undergoing general anesthesia.

A Foley catheter is always placed in the bladder Before proceeding with the preoperative preparation of the abdominal wall the site of the ileostomy may be

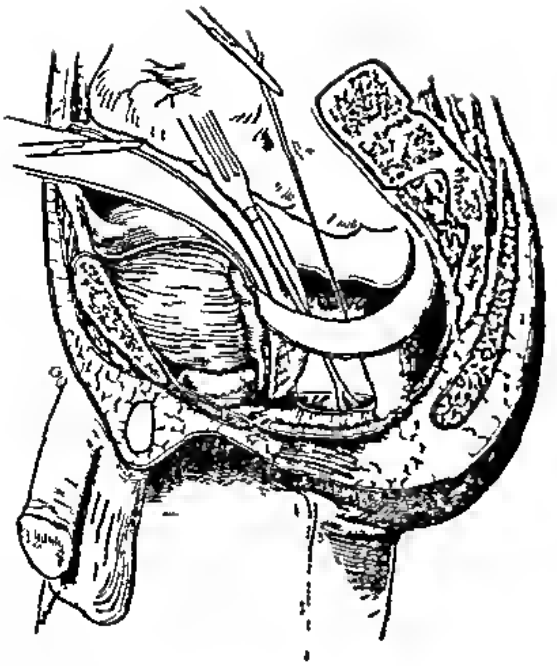

Fig 20-16 Total proctocolectomy, with preservation of small anorectal cuff, curettage from above and below of the mucous membrane lining this cuff, preparatory to pulling through the terminal ileum (*From* S Schneider, *A M A Arch Surg* vol 75 November, 1957 )

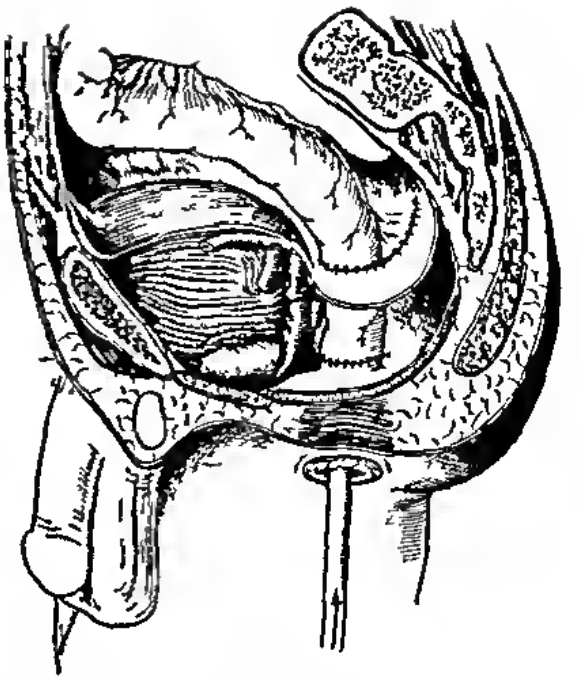

Fig 20 18 Peritoneal floor is then closed With mushroom catheter in place the prolapsed ileum is pushed back into the small rectal pouch proximal to the sphincter, to prevent any constricting effect on wall of the ileum (*From* S Schneider *A M A Arch Surg* vol 75 November 1957 )

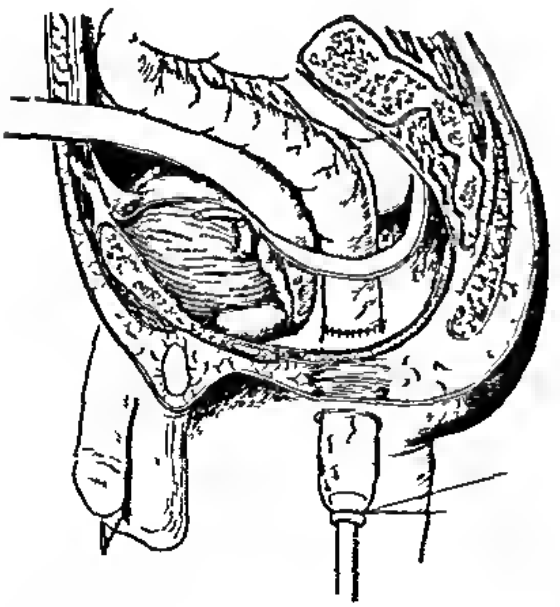

Fig 20-17 Terminal ileum is brought through and beyond the cuff and sutured to it from above (*From* S Schneider, *A.M.A Arch Surg*, vol 75, November, 1957 )

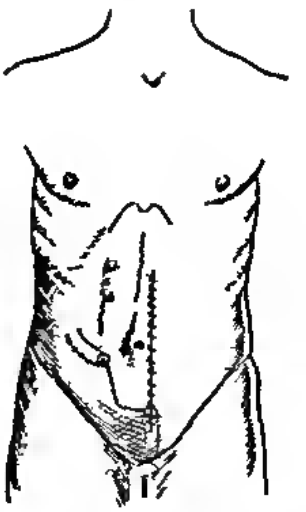

Fig 20-19 With patient in supine position ileum is transected proximally, the proximal end of the distal limb is brought out as a mucous fistula, and the proximal ileum is converted into a terminal ileostomy through a right lower quadrant stab wound (*From* S Schneider, *A.M A Arch Surg*, vol 75, November, 1957 )

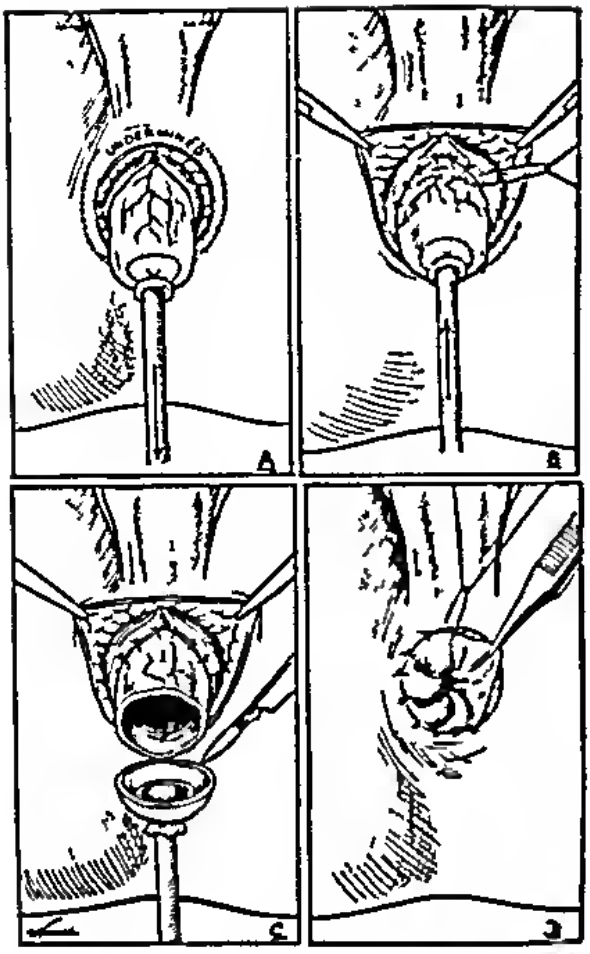


Fig 20-20 Patient in lithotomy position (two days later) (*A*) Terminal ileum is brought out of the anal pouch, and the external sphincter is exposed through a circular incision at the mucocutaneous junction (*B*) Sphincter is sutured to the serosa of the terminal ileum (*C*) Excess ileum is excised (*D*) Free edge of the ileum is sutured without tension to the perianal skin. Two operative procedures are employed in the first stage (Figs 20-16–20-19) a delay of 48 hours is recommended between the two procedures to ensure viability of the ileum for the anal anastomosis (*From* S Schneider *AMA Arch Surg*, vol 75, November 1957)

marked, as some surgeons prefer to do by either scratching with a sterile safety pin, or by indelible ink, or with an intradermal injection of methylene blue As previously mentioned in the discussion on ileostomy the usual location is slightly below the mid point of a line drawn from the umbilicus to the anterior superior iliac spine on the right. The abdomen is prepared and then opened through a long left paramedian incision, which extends from a point high in the epigastrium down to the pubic bone

The colon and entire small bowel are thoroughly inspected before proceeding with the operation, with great care taken to rule out the presence of 'skip areas' of disease involving the small intestine The terminal ileum is then identified and transected, this is done at least 12 inches proximal to the ileocecal valve, or at a similar distance above the most proximal area of gross involvement. The proximal divided ileum is then set aside for later withdrawal through the abdominal wall, to form the ileostomy (Fig 20-22)

The inferior and lateral attachments of peritoneum to the cecum and to the ascending colon along the right lumbar gutter are then incised upward with scissors, thus carrying the division of peritoneum around the hepatic flexure into the subhepatic region A few prominent veins are usually encountered in passing around the hepatic flexure, which require division and ligation

By means of blunt dissection, the right colon can now be mobilized medially, with particular care taken to avoid injury to the important structures that are exposed lying in the retroperitoneal space. These particular structures are the lower pole of the right kidney, the ureter, and the second and third portions of duodenum. The mesentery of the right colon is then divided close to the bowel wall, and the branches of the right colic artery are ligated The dissection is now carried from right to left across the upper abdomen and both the gastrocolic ligament and transverse mesocolon are clamped divided and ligated The greater omentum is usually atrophic, and although it can be left attached to the stomach as shown in Figure 20-22, it is usually allowed to remain on the transverse colon, and is removed with the specimen

The splenic flexure is then approached and if exposure is not adequate its mobilization can present the most difficult technical feature of the abdominal phase of

the operation The division of the lowermost vasa brevia along the greater curvature of the stomach is usually of great aid in visualizing the splenocolic ligament An additional help in obtaining good exposure is keeping the spleen depressed by placing two rolled up laparotomy pads between the superior pole of spleen and the diaphragm In some patients, as a result of disease, the colon will have already undergone marked contraction and shortening, with migration of the splenic flexure downward and with loss of its normal angularity (see Fig 20 2) Under these circumstances, exposure and division of the phrenocolic ligament offer no real problem

After thorough exposure the ligament is defined, doubly clamped, and divided between the clamps It is important to transfix the clamped ligament with a ligature, as it is usually traversed by at least one reasonably large blood vessel In the course of mobilizing the entire transverse colon, care should be taken to avoid injuring the underlying structures these include the head and tail of the pancreas, the third and fourth portions of the duodenum and the superior mesenteric vessels



Fig 20 21 Preparation of patient for surgery with induced hypothermia Patient lying in applicator (Therm O Rite) that zips up the sides and has coils through which a solution of denatured alcohol and water circulates Refrigeration and warming are accomplished by controls on a machine placed at the foot of the operating table

The dissection is now carried down the left lumbar gutter, with incision of the peritoneum close to its attachment to the wall of the descending and sigmoid colon, as far as the brim of the pelvis This portion of the colon is then mobilized medially by blunt dissection, with care taken to identify the left ureter Figure 20-23 shows the point at which it passes across the left common iliac artery The branches

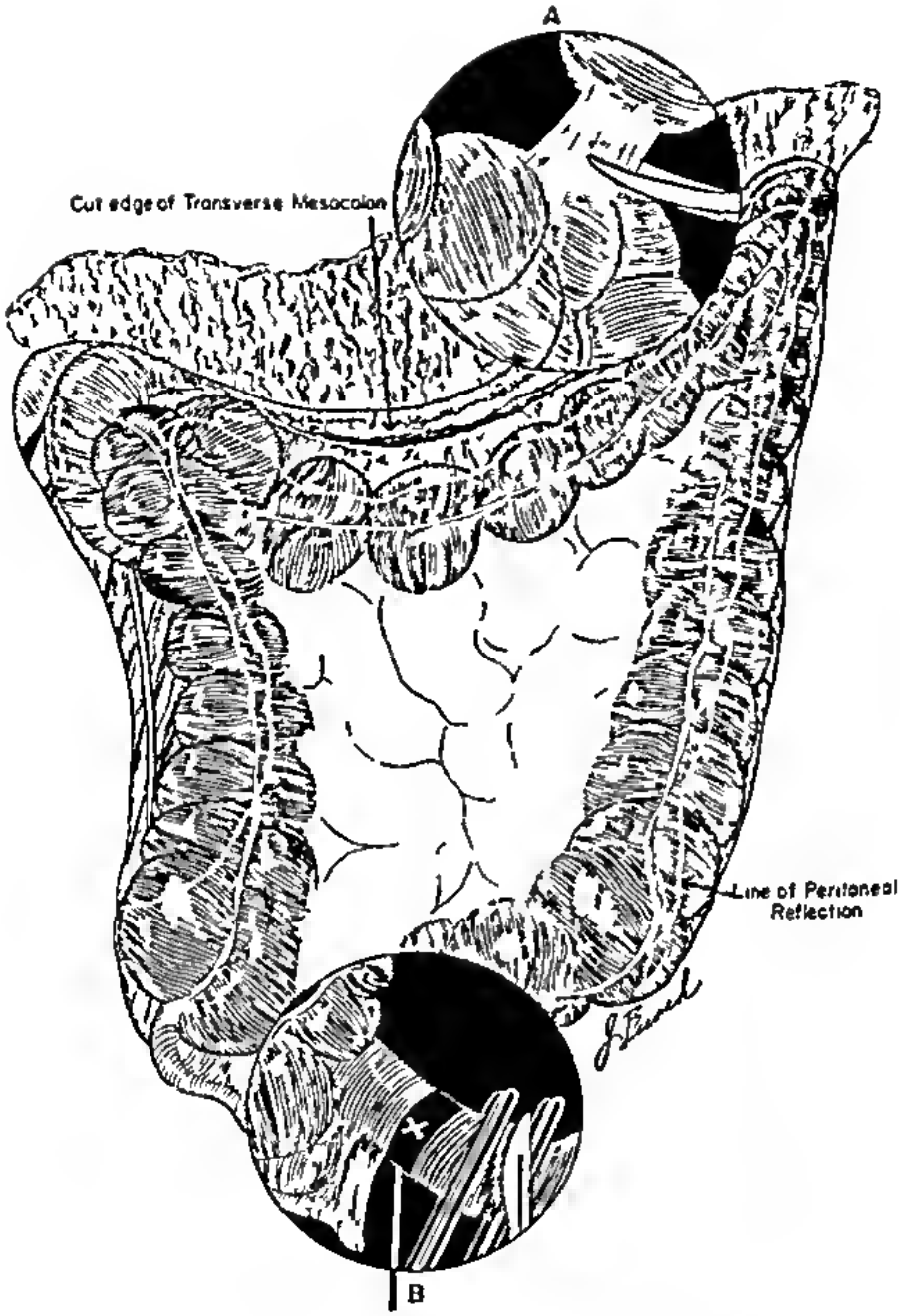


Fig 20-22 Total proctocolectomy (*A*) Division of phrenocolic ligament (*B*) Division of terminal ileum at least 12 inches from ileocecal valve

of the inferior mesenteric artery going to this part of the colon are then ligated close to the bowel wall, and the mesentery is incised down to a point opposite the promontory of sacrum At this level, the superior hemorrhoidal artery is usually encountered, where it is exposed and ligated

Where it reaches the pelvic brim, the lower end of the peritoneal incision is prolonged downward into the depths of the pelvis, at a distance of about one inch from the wall of lower sigmoid and rectum A lateral flap of pelvic peritoneum is then elevated to expose the ureter, which is either lying in the fatty tissues of the lateral pelvic wall or has remained attached to the undersurface of the flap

Particular care must be directed to identification of the ureter throughout its entire course from the point of its entrance in the operative field to its point of exit The peritoneum is then incised on the right side Similarly, a peritoneal flap is raised on the right, the ureter is identified, and the incision in the peritoneum is sected so as to allow sufficient length to be brought out and incorporated in the wound as a mucous fistula

If there is no contraindication to completion of the abdominoperineal phase of the procedure the hand is now passed downward between the rectum and the anterior surface of the sacrum and with

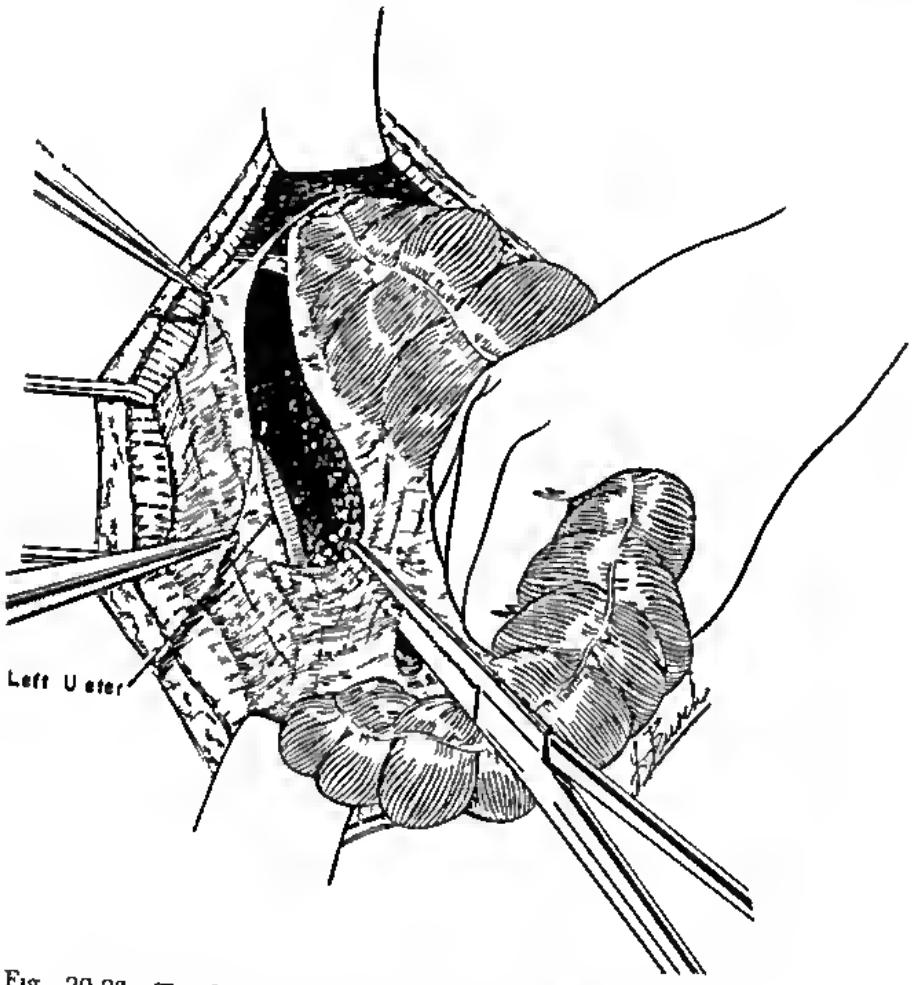


Fig 20-23 Total proctocolectomy Lower sigmoid and intraperitoneal rectum mobilized ureter identified superior hemorrhoidal vessels clamped

joined with that on the opposite side by carrying it across anteriorly in the space between the rectum and the bladder

Up to this point, the operation can be terminated at almost any stage, if the patient s condition becomes precarious. If such a situation arises, the mobilized colon is divided and removed at that level where viability of the residual colon can be assured, and the bowel is then tran the aid of blunt dissection (Fig 20-24), the rectum is completely separated posteriorly to a point at or slightly beyond the tip of the coccyx In sweeping the hand laterally and anteriorly in the depths of the wound further mobilization of the extraperitoneal rectum is prevented by dense lateral ligaments that fix the rectum to the lateral pelvic wall Dissection is now commenced anteriorly between the

bladder and rectum In the male, the seminal vesicles, which are first encountered adjacent to the base of the prostate, are gently separated from the anterior rectal wall, the dissection is then carried deeper, to reach the plane of cleavage between the prostate anteriorly and the rectum posteriorly

In the female the dissection is carried inferiorly in a plane of cleavage between the inferior uterine segment and the posterior wall of vagina anteriorly and the rectum behind

Definition of the rectal wall is then developed laterally until the anterior surface of the lateral ligament is encountered from in front This completes identification of the ligament blunt dissection with the index and middle fingers on opposite sides of the ligament facilitates its exposure Under direct vision the ligament can now be divided throughout its entire length with the aid of long handled scissors (Branches of the middle hemorrhoidal artery usually traverse this ligament and often require ligation) If exposure of the ligament is difficult, preliminary hemostatic transfixation, lateral to the point of division, is worthwhile Complete severance of the lateral ligaments assures simplicity in carrying out the perineal phase of the operation When not too difficult to perform, a complete dissection of the rectum from the prostate or the vagina will facilitate the next stage

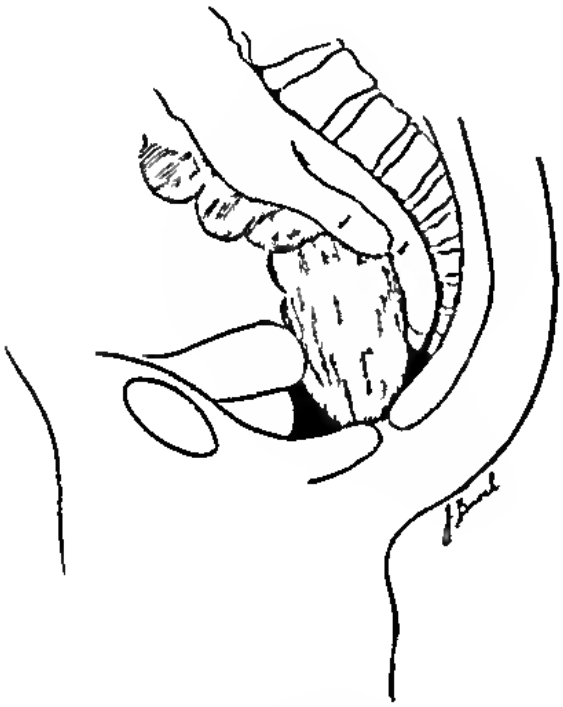

Fig 20 24 Total proctocolectomy Schematic representation of dissection posterior to rectum as far as tip of coccyx

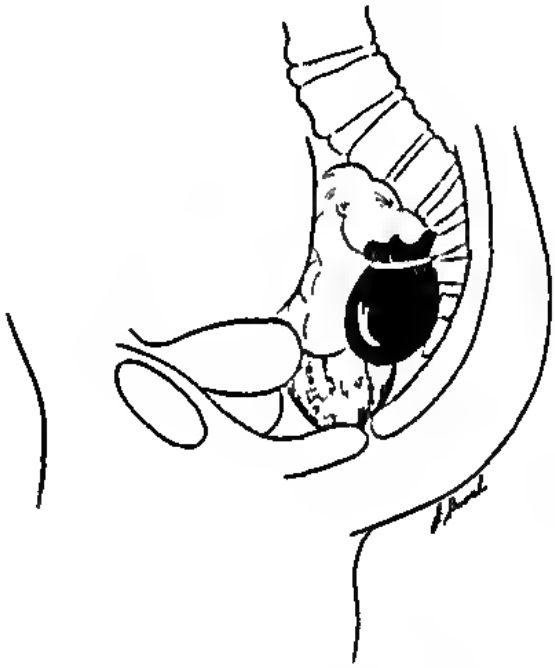

Fig 0 25 Total proctocolectomy Schematic representation of treatment of distal rectum followed by closure of pelvic peritoneum

Once the extraperitoneal part of the rectum has been thoroughly mobilized the abdominal phase of the dissection is complete The bowel is then transected with the cautery through the distal portion of the intraperitoneal rectum and the proximal bowel is removed The open end of remaining rectum is enveloped by a square of gutta percha or is enclosed in a rubber glove and is tied with heavy braided silk so as to seal off the gut thus preventing leakage of retained rectal contents Once this has been accomplished the sealed end of the rectal stump is placed in the extreme caudal portion of

the dissected space between the tip of coccyx and the distal rectum (Fig 20-25) The floor of the pelvis is then closed with a continuous chromic gut suture by reapproximating the previously raised peritoneal flaps

The proximal ileum, which had been clamped, divided, and set aside, is now ready for withdrawal through the abdominal wall to form the ileostomy in the right lower quadrant Details of this phase of the procedure are included in the discussion on ileostomy, earlier in the chapter

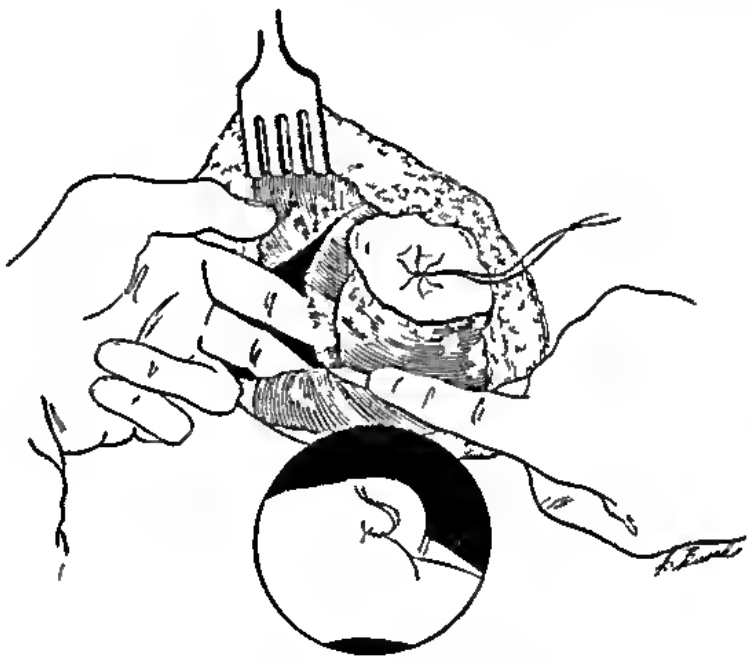

Fig 20 26 Total proctocolectomy Dotted line in insert indicates type of incision used Levator ani muscles are severed near their insertion into anus

At this phase of the operation, the peritoneum can be closed in order to cover the exposed lumbar gutters However, this step seems to be of doubtful importance although some surgeons lay great stress on it

The abdominal wall is now closed in layers, with use of continuous atraumatic chromic gut for the peritoneum and posterior rectus sheath, interrupted chromic gut for the anterior rectus sheath, and interrupted black silk sutures or metal clips for the skin Stay sutures, usually important in operating on debilitated patients, are here a disadvantage, they tend to encroach on the area of skin to which the transparent disposable plastic ileostomy bag is applied In addition these sutures are of doubtful necessity, as the removal of the large bowel results in less tendency to postoperative distention Once the ileostomy bag is securely fixed to the skin, the main wound is dressed and the patient is placed either in the lithotomy position or lying on his left side in the Sims position If the patient at this point shows any appreciable drop in blood pressure the lithotomy position is preferable

The skin of the perineum is prepared, a purse-string suture of heavy braided silk is placed in the perianal skin to close the anus, and the ends of the silk are left long to serve as tractors The incision is then made, beginning about one inch proximal to the coccyx, and is carried forward completely to encircle the closed anus, about one inch away from the purse string suture The incision is carried deeply into the subcutaneous tissues to expose the tip of coccyx and the fascia propria in the posterior mid-line, and laterally to expose the levator ani muscles (Fig 20-26) The anterior dissection in the female is directed toward finding the plane of cleavage between the vagina and rectum, in the male, palpation of the indwelling Foley catheter allows the operator to keep at a safe distance from the urethra in

order to avoid its injury, as the plane of cleavage is sought between the prostate and rectum

The anococcygeal ligament and the fascia propria are then incised transversely, in front of the tip of coccyx, in order to enter the dead space created previously while working within the abdomen Entrance into this cavity is always associated with the escape of accumulated fluid and clotted blood The incision is now carried anteriorly on each side of the anus, dividing the levator ani muscles, thus making it easier at this point to reach into the excluded pelvis, grasp the enveloped end of the proximal rectum, and deliver it to the outside (Fig 20-27)

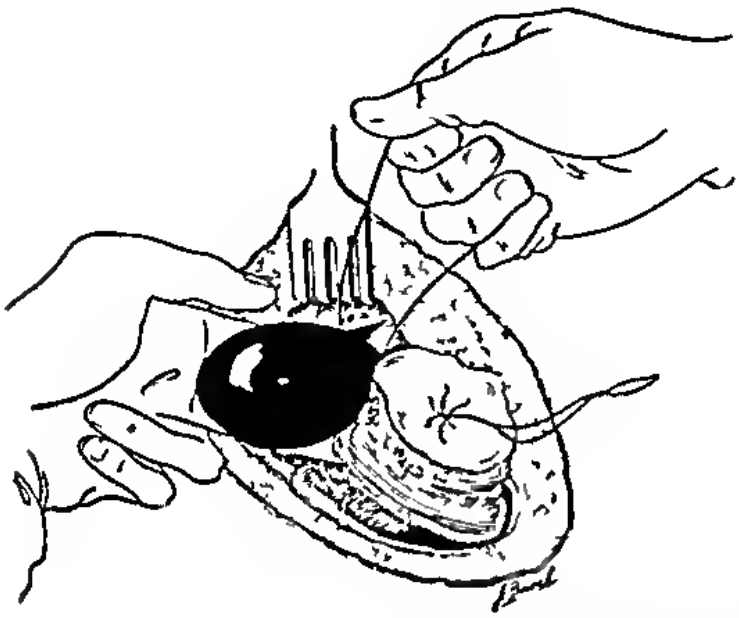

Fig 20-27 Total proctocolectomy Fascia propria and levator ani muscles are divided, enveloped proximal end of rectum is delivered to outside



Fig 20 28 Total proctocolectomy Removal of the rectal segment completed by final dissection anteriorly between rectum and prostatic bed Insert illustrates closure of wound around drain emerging from posterior angle

The rectum is removed by completing the dissection anteriorly, where it still remains adherent to either the prostate or the vagina (Fig 20-28) Thorough hemostasis is obtained, a fenestrated rubber tube drain is inserted upward into the presacral space, and the levator ani mus-

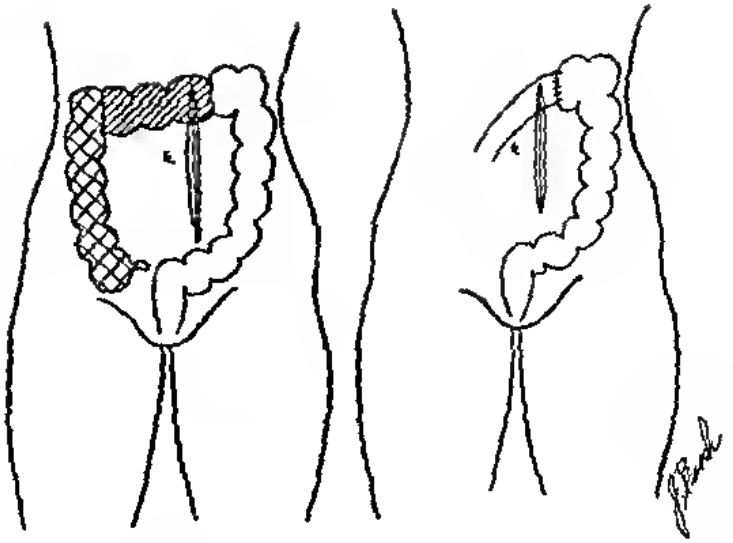

Fig 20 29 Partial colectomy with ileotransverse colostomy (*Left*) Left paramedian incision, disease confined to right colon, resection through distal transverse colon (*Right*) Level of completed anastomosis

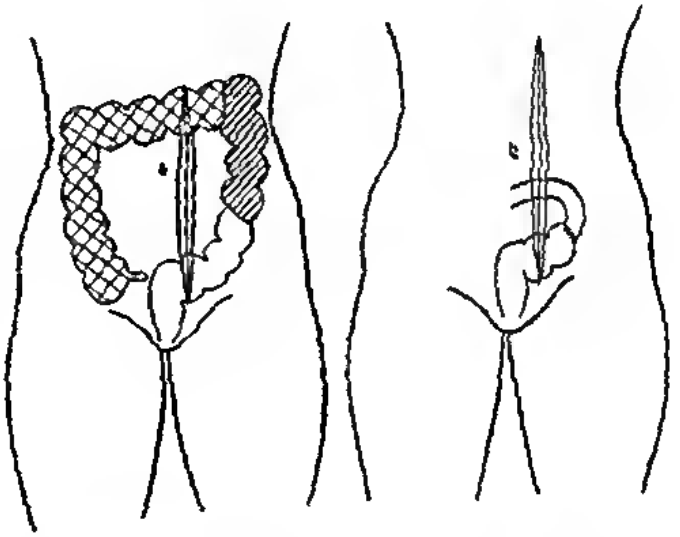

Fig 20-30 Subtotal colectomy with ileosigmoidostomy (*Left*) Left paramedian incision, disease confined to ascending and transverse colon, site of resection in upper sigmoid colon (*Right*) Level of ileosigmoidostomy

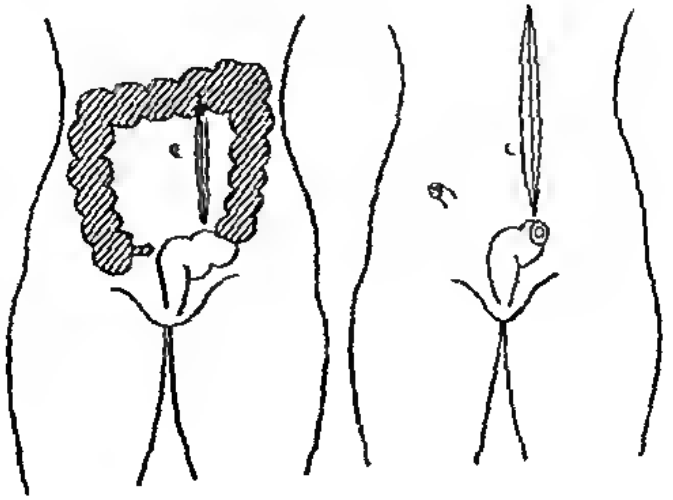

Fig. 20-31 Subtotal colectomy with ileostomy (*Left*) Left paramedian incision, level of resection (extent of disease not indicated, see text) (*Right*) Location of terminal ileostomy and mucous fistula

cles are approximated anteriorly with interrupted chromic gut sutures The skin is closed with interrupted black silk sutures

Postoperative care of the perineal wound consists of loosening and shortening the drain on the third day, and accomplishing complete removal of the drain on about the seventh postoperative day Thereafter, perineal care should include daily irrigations of the cavity with a catheter, until it is evident that a "dead space no longer exists

### *Vagotomy*

Vagus resection has been used as an adjunct in the treatment of ulcerative colitis but there is little evidence that it significantly influences the course of the disease Therefore, it seems unwarranted to recommend vagotomy as a part of the surgical treatment

### *Partial Colectomy*

As previously mentioned, the nature of ulcerative colitis with its associated complications has in the past prompted surgeons to adopt various types of palliative procedures This has been motivated by the desire to save the patient's life or to avoid eventual total removal of the colon with its attendant permanent ileostomy

There is no doubt that by being aggressive the surgical approach has been greatly simplified and made more direct However, there are still several palliative procedures as listed below, that on occasion can be used to advantage Figures 20 29 20 30 and 20 31 illustrate the operations schematically, and as indicated the left paramedian is the preferred incision in each instance The diagonal shading represents the recommended site of resection in relationship to the extent of disease which is shown by the cross hatching

*Right colectomy with ileotransverse colostomy (Fig 20 29)* This operation should be performed only in those patients in whom the disease is completely confined to the right colon

*Subtotal colectomy with ileosigmoidostomy (Fig 20 30)* This operation promises little success unless the rectum, sigmoid, and descending colon are free from disease

*Subtotal colectomy with ileostomy (Fig 20-31)* This operation is more commonly used as the first stage of a two-stage proctocolectomy It is also recommended in preference to ileosigmoidostomy for patients with no disease below the transverse colon For patients with more limited proximal disease, it is hoped that reanastomosis of the ileum to the dysfunctionalized colon can be accomplished at a later date

## CARE OF THE ILEOSTOMY

After the ileostomy has been constructed, there are several methods of dealing with it during the early postoperative period When simple ileostomy without colectomy has been performed, the stoma will probably function in 12 to 24 hours If, on the other hand, the ileostomy is combined with colectomy, the stoma is not likely to function during the first 48 hours, and it may sometimes take as long as three days for the first discharge to appear Some operators prefer to clamp the end of the ileum for 24 hours before releasing it, and others are partial to intubation with a catheter We have preferred the immediate application of a plastic transparent disposable bag which is cemented to the skin at the termination of the operative procedure. The stoma is thus easily visible for inspection and in addition, protection is afforded the skin from the moment that the ileostomy begins to function These are two very important advantages in the use of the disposable bag The main objection to any sort of intubation is the possibility that irritation of the ileum by the tube or catheter may lead to inflammation and subsequent fistulous formation at the stoma

The temporary disposable bag is preferable to the permanent type of bag during the early postoperative period The mouth of the temporary bag can be easily changed in size as the stoma is observed to go through the stages of swelling and

shrinkage, whereas the rigid opening of the permanent bag may result in injury to the mucosa of the stoma, which, in turn, can lead to the development of superficial fistulous tracts When healing of the abdominal wound is sufficiently advanced (usually on the 10th to 14th postoperative day), the patient is ready to be fitted with a more permanent type of appliance *

Types of permanent bags are described by Lyons, who states, 'The ideal ileostomy appliance should be comfortable, leak-proof, odor proof, inconspicuous under clothing, easily manipulated, inexpensive, not unsightly by itself, and safe " He finds that no bag fulfills all requirements and none is suitable for every patient It is therefore important for the surgeon to familiarize himself thoroughly with the different varieties available and to know their advantages and disadvantages It is usually possible to find one appliance that will fit the needs of even the most difficult subject Some patients prefer the 'cement on' type of bag, most of these are similar in type and include the Rutzen, Simpson, Permatype, and Henry appliances Others dislike to use the cemented bag and prefer a model with a rubber disk and detachable pouch, as provided by Davol and Fazio Lyons gives a partial list of the permanent appliances, as follows

*Cement on* (These bags can also be used without cement)

a Flat, nondetachable metal disk (Permatype, Rutzen, Henry, Simpson)
b Flat, detachable rubber cuff, metal disk (Davol [1326, 1322], Grick)
c Flat, detachable rubber pouch, plastic disk (Torbot, Marlen, Jonas, Down Bros [England])
d Disposable plastic pouch (Fazio rubber disk, Zeitz plastic disk, Royal plastic disk, Seep-Pruf, Carhart)

*Noncemented*

a Soft disk (Perry, Pierce)
b Hard plastic disk (Jonas)
c Firm rubber disk, wire support (Davol [1388])

There are certain important features to be observed in fitting the appliance, regardless of the choice of permanent bag used One needs to exert great care that the opening of the disk does not encroach too closely on the mucosa of the ileostomy, so as to avoid the irritative and abrasive effect of its edges It is safe to allow a margin of an eighth of an inch between the inner circumference of the disk and the stoma, to allow for possible swelling When shrinkage of the stoma has been completed or when swelling no longer occurs, a new bag or cuff may be necessary

If, in the transitional stage, enough shrinkage occurs to cause excoriation of the skin, it can be temporarily controlled by cementing to the disk a foam rubber patch with an opening of appropriate size

When the abdominal wall surrounding the ileostomy is particularly convex as it is in some individuals, or when the stoma is situated in a valley, it may be necessary to use a disk of sufficient convexity to fit the body contour, and to counteract any tendency for leakage to occur

It is necessary that the patient should have at least two bags, so that one can be cleansed and dried while the other is in use Each patient will develop his own habits, influenced undoubtedly by his whims or the lasting power of the cement, however, a happy medium should be sought Too frequent changes of the bag may result in irritation of the skin if cement is used, but this is obviously no problem for those who do not use cement On the other hand, a bag that is left on too long without cleansing will give off a very unpleasant odor When removed, the appliance should be cleansed with cool tap water that is allowed to flow vigorously through the bag, it should then be thoroughly cleansed with soap or a detergent Chlorox may be used as a deodorant

* Temporary plastic appliances are readily available through surgical supply companies and include Coloplast, as well as similar models made by Fazio, Grick, Marlen, and Atlantic

cles are approximated anteriorly with interrupted chromic gut sutures The skin is closed with interrupted black silk sutures

Postoperative care of the perineal wound consists of loosening and shortening the drain on the third day, and accomplishing complete removal of the drain on about the seventh postoperative day Thereafter, perineal care should include daily irrigations of the cavity with a catheter until it is evident that a dead space no longer exists

### *Vagotomy*

Vagus resection has been used as an adjunct in the treatment of ulcerative colitis but there is little evidence that it significantly influences the course of the disease Therefore it seems unwarranted to recommend vagotomy as a part of the surgical treatment

### *Partial Colectomy*

As previously mentioned the nature of ulcerative colitis with its associated complications has in the past prompted surgeons to adopt various types of palliative procedures This has been motivated by the desire to save the patient s life or to avoid eventual total removal of the colon with its attendant permanent ileostomy

There is no doubt that by being aggressive the surgical approach has been greatly simplified and made more direct However there are still several palliative procedures as listed below that on occasion can be used to advantage Figures 20 29 20 30 and 20 31 illustrate the operations schematically and as indicated the left paramedian is the preferred incision in each instance The diagonal shading represents the recommended site of resection in relationship to the extent of disease which is shown by the cross hatching

*Right colectomy with ileotransverse colostomy (Fig 20 29)* This operation should be performed only in those patients in whom the disease is completely confined to the right colon

*Subtotal colectomy with ileosigmoidostomy (Fig 20 30)* This operation promises little success unless the rectum sigmoid and descending colon are free from disease

*Subtotal colectomy with ileostomy (Fig 20 31)* This operation is more commonly used as the first stage of a two stage proctocolectomy It is also recommended in preference to ileosigmoidostomy for patients with no disease below the transverse colon For patients with more limited proximal disease, it is hoped that reanastomosis of the ileum to the dysfunctionalized colon can be accomplished at a later date

## CARE OF THE ILEOSTOMY

After the ileostomy has been constructed there are several methods of dealing with it during the early postoperative period When simple ileostomy without colectomy has been performed the stoma will probably function in 12 to 24 hours If, on the other hand the ileostomy is combined with colectomy, the stoma is not likely to function during the first 48 hours and it may sometimes take as long as three days for the first discharge to appear Some operators prefer to clamp the end of the ileum for 24 hours before releasing it and others are partial to intubation with a catheter We have preferred the immediate application of a plastic transparent disposable bag which is cemented to the skin at the termination of the operative procedure. The stoma is thus easily visible for inspection and in addition protection is afforded the skin from the moment that the ileostomy begins to function These are two very important advantages in the use of the disposable bag The main objection to any sort of intubation is the possibility that irritation of the ileum by the tube or catheter may lead to inflammation and subsequent fistulous formation at the stoma

The temporary disposable bag is preferable to the permanent type of bag during the early postoperative period The mouth of the temporary bag can be easily changed in size as the stoma is observed to go through the stages of swelling and

shrinkage, whereas the rigid opening of the permanent bag may result in injury to the mucosa of the stoma, which, in turn, can lead to the development of superficial fistulous tracts When healing of the abdominal wound is sufficiently advanced (usually on the 10th to 14th postoperative day), the patient is ready to be fitted with a more permanent type of appliance *

Types of permanent bags are described by Lyons, who states, 'The ideal ileostomy appliance should be comfortable, leak proof, odor-proof, inconspicuous under clothing, easily manipulated, inexpensive, not unsightly by itself, and safe" He finds that no bag fulfills all requirements, and none is suitable for every patient It is therefore important for the surgeon to familiarize himself thoroughly with the different varieties available and to know their advantages and disadvantages It is usually possible to find one appliance that will fit the needs of even the most difficult subject Some patients prefer the "cement-on' type of bag, most of these are similar in type and include the Rutzen, Simpson Permatype, and Henry appliances Others dislike to use the cemented bag and prefer a model with a rubber disk and detachable pouch, as provided by Davol and Fazio Lyons gives a partial list of the permanent appliances, as follows

*Cement on* (These bags can also be used without cement)

a Flat, nondetachable metal disk (Permatype, Rutzen, Henry Simpson)
b Flat, detachable rubber cuff metal disk (Davol [1326, 1322] Grick)
c Flat, detachable rubber pouch, plastic disk (Torbot, Marlen Jonas, Down Bros [England])
d Disposable plastic pouch (Fazio rubber disk, Zeitz plastic disk, Royal plastic disk, Seep-Pruf, Carhart)

*Noncemented*

a Soft disk (Perry Pierce)
b Hard plastic disk (Jonas)
c Firm rubber disk, wire support (Davol [1388])

There are certain important features to be observed in fitting the appliance, regardless of the choice of permanent bag used One needs to exert great care that the opening of the disk does not encroach too closely on the mucosa of the ileostomy, so as to avoid the irritative and abrasive effect of its edges It is safe to allow a margin of an eighth of an inch between the inner circumference of the disk and the stoma, to allow for possible swelling When shrinkage of the stoma has been completed or when swelling no longer occurs, a new bag or cuff may be necessary

If in the transitional stage, enough shrinkage occurs to cause excoriation of the skin, it can be temporarily controlled by cementing to the disk a foam rubber patch with an opening of appropriate size

When the abdominal wall surrounding the ileostomy is particularly convex, as it is in some individuals, or when the stoma is situated in a valley it may be necessary to use a disk of sufficient convexity to fit the body contour, and to counteract any tendency for leakage to occur

It is necessary that the patient should have at least two bags, so that one can be cleansed and dried while the other is in use Each patient will develop his own habits, influenced undoubtedly by his whims or the lasting power of the cement, however a happy medium should be sought Too frequent changes of the bag may result in irritation of the skin if cement is used, but this is obviously no problem for those who do not use cement On the other hand, a bag that is left on too long without cleansing will give off a very unpleasant odor When removed, the appliance should be cleansed with cool tap water that is allowed to flow vigorously through the bag, it should then be thoroughly cleansed with soap or a detergent. Chlorox may be used as a deodorant

* Temporary plastic appliances are readily available through surgical supply companies and include Coloplast, as well as similar models made by Fazio, Grick, Marlen, and Atlantic

in a dilution of five to ten times with water, in which the bag should be allowed to soak from one to 24 hours When cleansed, the bag should be hung on a hook or peg and allowed to dry thoroughly before it is used again

## COMPLICATIONS OF ILLOSTOMY

It has been our experience that in the immediate postoperative period, at least two thirds of the complications that occur bear some relation to the construction of the ileostomy In some instances, the ileostomy may discharge profusely, resulting in the loss of such excessive amounts of fluid that a serious electrolyte depletion results In other instances, the ileostomy may function so poorly as to cause crampy abdominal wall pain and occasional expulsion of gas and liquid ileal contents, creating the suspicion of an impending obstruction These two manifestations of dysfunction are most likely to occur during the early postoperative period, but may also be present as late as four weeks after operation When hypofunction occurs a catheter should be passed in retrograde fashion proximally up the stoma, to rule out the possibility of an early mechanical obstruction It is also wise temporarily to discontinue oral feedings and to supply the body requirements via the *intravenous route*

### Obstruction

Complete or incomplete mechanical obstruction may develop, which most often results from an adhesive band or from a volvulus of the small bowel around the limb of ileum leading to the stoma Meticulous care in constructing the ileostomy should lower the incidence of this complication

### Early Postoperative Complications

Other than the complications associated with the ileostomy, those seen in the *early* postoperative period are such as might be expected to occur in any desperately sick patient who has gone through an abdominal operation These complications include peritonitis, thrombophlebitis, thromboembolism, pneumonia, wound disruption, secondary peritoneal abscess formation, massive hemorrhage from residual disease in the remaining rectum or colon, coronary thrombosis, and wound infection

### Late Postoperative Complications

In most instances, *late* postoperative complications are related to the presence of an ileostomy, regardless of whether an associated partial or total colectomy was performed These complications will be considered under separate headings, as follows

SKIN EXCORIATION This condition can be most troublesome and disabling if it *gets out of* hand *It is usually* caused by the irritating effect of the intestinal contents that come into prolonged and intimate contact with the skin, which in most instances, is a direct result of an ill fitting ileostomy bag The appearance of erosions early in the convalescence can usually be prevented by the use of a plastic disposable bag, adjusted in such a manner that it fits perfectly at all times, thus preventing leakage

The depressions and elevations that result from scarring around the stoma mitigate against efficient use of the bag When such a *situation exists, it may* be necessary to revise the stoma, under some circumstances, it may even have to be transplanted to a new location at a safe distance from the scarred area In some patients, the stoma retracts to such an extent that it lies in a deep concavity in that case, a revision is necessary, as it is otherwise mechanically impossible for any type of ileostomy bag to be efficiently used Localized areas of skin irritation are sometimes found in direct association with superficial or deep stomal fistulas. Another cause of skin irritation is sensitivity to the cement or to the rubber cuff, occasionally, patients acquire this sensitivity even after using the bag for prolonged periods

PROLAPSE This is a distressing com

plication, usually requiring stomal revision (In our series, prolapse developed in 5 per cent of the patients undergoing ileostomy) In has been suggested by Garlock that fixation of the ileal mesentery to the peritoneum of the anterior abdominal wall, in conjunction with a Noble plication, will materially reduce the incidence

FISTULA The formation of fistulas about the ileostomy may originate deep within the abdominal wall Under such circumstances, their development is usually heralded by an abscess within the abdominal wall, which eventually drains alongside the stoma to establish the persistent fistula It is likely that this complication can be prevented Intubation of the ileostomy as an immediate postoperative measure, and the use of sutures that penetrate the ileum to fix it to the abdominal wall layers are probably the two most frequent causes of this condition

SUPERFICIAL STOMAL FISTULAS These fistulas, at or beyond the skin level, usually develop from the pressure or irritation caused by a poorly fitting ileostomy bag In some patients they may result from a poorly situated ileostomy, which allows the flange of the bag to irritate and press against the stoma when the patient assumes a sitting position This situation is more likely to develop when the flange is made or reinforced with metal, or any other hard substance Many, if not most, of the patients with this complication require revision of the ileostomy

When the fistula originates deeply within the abdominal wall layers, it is necessary to enter the peritoneal cavity in order to eradicate it completely The diseased portion is excised and healthy ileum is used to construct a new stoma

STENOSIS AND RETRACTION In some patients excessive scar tissue develops at the mucocutaneous juncture, and as it progresses, there may be gradual retraction of the stoma In some instances, when this condition is first recognized it can be controlled by frequent dilation with the little finger However, it must be kept in mind in using manipulation of this sort, that there is an inherent danger of its leading to fistulous formation The stenosis may progress to such a degree of dysfunction as to require revision of the ileostomy There is every evidence that this complication is less likely to develop if the ileostomy is constructed in the manner suggested by Turnbull or Brooke

RECESSION Where the mucosa of the ileostomy recedes into the abdominal wall on assuming a position of recumbency, there is usually no associated stenosis and the recession should therefore not be confused with retraction Recession usually causes no disability and can probably be prevented by proper fixation of the mesentery of the ileum to the peritoneum of the anterior abdominal wall when the ileostomy is first being constructed

ASCENDING ILEITIS The development of localized or segmental areas of ileitis proximal to the ileostomy can occur after partial or total proctocolectomy Fortunately, in our experience this has not been a frequent complication although one of our patients did have a fatal massive hemorrhage from just such a lesion Steroid therapy is suggested as the primary conservative approach to the problem However it may be necessary at a later date to resect additional ileum and to develop a new ileostomy from the small bowel proximal to the diseased area

HERNIATION Weakness of the abdominal wall may develop around the ileostomy, this can develop into a frank hernia in association with some prolapse at the stoma Under these circumstances, the ileostomy should be revised and the hernia repaired It may prove necessary to transplant the stoma to a new location in order to obtain a satisfactory result

## REFERENCES

AULT, G W Surgical treatment of chronic ulcerative colitis *Am J Surg* 75 325, 1948

*Bickham Callander Surgery of the Alimentary Tract* Ed SHACKELFORD RICHARD T Philadelphia, W B Saunders Company, 1955

BOCKUS, H H *Gastro Enterology* Philadelphia, W B Saunders Company, 1946

Brooke, B N Total colectomy in one stage for ulcerative colitis *Lancet I* 1197, 1951

Brooke, B N *Ulcerative Colitis and Its Surgical Treatment* London, E & S Livingston, Ltd, 1954

Brown, C H, Gieckler, W J, and Jones, T L Surgical treatment of chronic nonspecific ulcerative colitis Results in 106 cases *Gastroenterology 14* 165, 1950

Cattell, R B, and Corcoran, B P. The surgical treatment of ulcerative colitis *Postgrad Med 17* 114, 1955

Coke, R A *Allergy in Theory and Practice* Philadelphia, W B Saunders Co, 1947

Dennis, C, *et al* Response to vagotomy in idiopathic ulcerative colitis and regional enteritis *Ann Surg 128* 179, 1948

Dragstedt, L R, Dack, G M, and Kirsner, J B Chronic ulcerative colitis *Ann Surg 114* 653, 1941

Eddy, T D Late results of vagotomy in treatment of idiopathic ulcerative colitis and regional enteritis *Surgery 29* 11, 1951

Garlock, J H, and Kirschner, P A The prevention of ileostomy dysfunction *Surgery 40* 687, 1956

Lyons, A S Ileostomy management and complications *S Clin North America*, October, 1955, p 1411

McKittrick, L S, and Moore, F D Ulcerative colitis *J A M A. 139* 201, 1949

Miller, G. G, Rifstein, C B, and Tabah, E J Surgical management of ulcerative colitis *Surg Gynec & Obst 88* 351, 1949

Ravitch, M M Anal ileostomy with sphincter preservation in patients requiring total colectomy for benign conditions *Surgery 24* 170, 1948

Ravitch, M M, and Handelsman, J C One stage resection of entire colon and rectum for ulcerative colitis and polypoid adenomatosis *Bull Johns Hopkins Hosp 88* 59, 1951

Ravitch, M. M, and Mandelbaum, I The evolution of the surgical approach to the therapy of idiopathic chronic ulcerative colitis, one stage total colectomy and abdominoperineal resection *S Clin North America*, October, 1955, p 1401

Rifstein, C B Primary resection of colon in acute ulcerative colitis *J A M A 152* 1093, 1953

Schneider, S Anal ileostomy description of a two stage procedure *A M A Arch Surg 75* 854, 1957

Turnbull, R B, Jr Mucosal grafted ileostomy *S Clin North America*, August, 1956, p 841

CHAPTER 21

# DIVERTICULOSIS AND DIVERTICULITIS OF THE COLON

*Edward S. Judd and John M Waugh*

## DEFINITION

A diverticulum may be defined as a pouch or pocket leading from a main cavity or tube, such as the intestine A true colonic diverticulum is one that is formed by protrusion of the entire thickness of the intestinal wall A false diverticulum results from protrusion of the mucous membrane through a defect in the muscularis, in the colon, such a defect is found most often at the point of exit or entrance of a blood vessel However, diverticula in the colon frequently are detected in other zones also, such as between the taeniae, under which circumstances they occur in double rows When diverticula are scattered throughout the colon and are numerous, the condition is called 'diverticulosis" This refers only to the presence of these pouches or sacs, which in itself cannot be looked on as a true disease entity However, when diverticula become inflamed, the condition termed 'diverticulitis' results

## INCIDENCE

Diverticulosis is relatively common The roentgenologist encounters it frequently, because persons in the age group with which he deals when examining the colon often reveal rather widespread involvement Whereas studies at necropsy report diverticulosis in perhaps 10 per cent of cases, a much larger percentage is noticed after proper roentgenologic examinations following barium enemas

Diverticula are most commonly located in the sigmoid segment of the colon, although the descending colon is frequently involved also The transverse colon occasionally reveals single or multiple diverticula, but the right portion of the colon is involved much less frequently In several large series at the Mayo Clinic (Judd and Smith, Waugh and Walt, 1956 and 1957), the rectum was found to be free from any involvement

The sex incidence apparently is not important, as inflammatory changes are seen frequently in both sexes Most authorities quote a slightly higher incidence in men It would appear that the clinical symptoms might be more noticeable in men, since the protection afforded to the colon by the uterus probably masks some of the symptoms that otherwise would be apparent in women

The age factor is of great significance

in suggesting that diverticulosis can be considered a degenerative process It is relatively uncommon to encounter diverticulitis in patients less than 45 years of age Beyond the age of 50, the process is observed much more frequently This also coincides well with the necropsy findings The peak age incidence lies between 55 and 65 years

## ETIOLOGY

It would appear from the age incidence that congenital factors would play

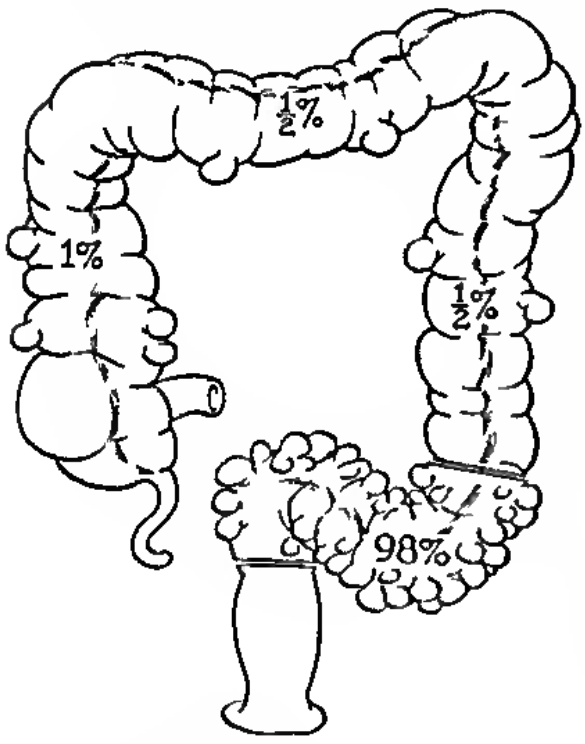


Fig 21 1 Location of the lesions in surgically proved colonic diverticulitis

an extremely minor role in diverticulosis The exact cause is unknown The solitary diverticulum of the cecum is thought to be the only congenital process of this type in the colon, this presents as a true diverticulum The weakness that develops in the colonic wall with advancing years is looked on as the logical sequel of increased pressure from within As obesity is such a common accompaniment of diverticulitis, it has been postulated that the increased fat deposited throughout the abdomen probably accounts for constipation, with resultant back pressure and secondary inflammatory changes in the diverticula

It is difficult to explain with any degree of certainty the striking preponderance of diverticulitis in the sigmoid zone of the colon (Fig 21-1) It can be speculated that the narrower lumen at this point and the much freer mesenteric attachment may well cause increased peristaltic activity, with greater pressure The circuitous course that the fecal stream may pursue in this region might contribute to these factors The stool in the left side of the colon is much more solid than that in the right half, because spasm occurs during the natural course of expulsion of the fecal material, it may be that the sigmoid colon receives a much more traumatic stimulus, whereas the cecum and ascending colon, with a much wider lumen and a more liquid type of fecal content, would be spared this trauma

Whether carcinoma is more prone to develop in a colon that is the seat of diverticulitis is a point of argument We believe that carcinoma of the lower portion of the sigmoid producing obstruction in a colon already the seat of diverticulosis may well lead to diverticulitis in the proximal regions, which would account for the occasional observation of both diseases in one short segment of intestine

## PATHOLOGY

The pathologic changes observed in diverticulitis are those of variable degrees of inflammation They vary from a mildly acute, localized process to huge abscesses with perforation and formation of fistulas It is characteristic that the intestine, which appears badly distorted from the serosal side, when opened reveals a relatively normal mucosal appearance aside from the presence of the multiple ostia This feature is relied on heavily by the radiologist who looks closely for alterations in mucosal patterns when he at

tempts to distinguish between malignant and inflammatory lesions The mesentery is always severely involved, so much so that the condition frequently appears to be one almost entirely of "perisigmoiditis" A mass is common for this reason Abscesses may be microscopic or macroscopic. The involved segment of colon is greatly shortened, with gradual diminution of the inflammatory changes as the mesentery is followed upward toward the splenic flexure Fecaliths are common, and some of these assume huge proportions, distending the already large diverticula When blood vessels are involved, hemorrhagic diverticulitis results, and this factor is only now coming to full appreciation (Mobley *et al*)

The structure most commonly involved in men after perforation of the colon in diverticulitis is the urinary bladder Fistulas into the bladder are seen in the late stages, and the degree of secondary urinary infection may be extreme Surgical drainage of such an abscess may result in a sigmoidovesicocutaneous fistula

The inflammatory process may result in a stricture producing advanced obstruction with great thickening of the wall of the colon for some distance The edematous, sometimes necrotic, epiploic tags that surround the process in the sigmoid colon form a familiar picture Fixation to the ureter, iliac blood vessels, and other viscera may be extreme

## CLINICAL SYNDROMES

### Symptoms and Signs

These vary, depending on whether the process is acute or chronic Most frequently, there will be repeated attacks of acute diverticulitis, resulting in a more chronic form It would be difficult to differentiate sharply between these from the clinical picture alone Most often the patient recalls a definite change in the bowel habits, which takes the form of constipation alternating with diarrhea The patient complains of a great deal of "gas distress" and may exhibit abdominal distention Pain is common, being located most often in the left lower abdominal quadrant because of the location of the great majority of the lesions in the sigmoid This may be a chronic, steady ache with exacerbations of more colicky "intestinal cramps" when strictures become more advanced The patient may become aware of a palpable mass, which represents perisigmoiditis involving multiple adjacent viscera Until recent years, rectal bleeding was considered pathognomonic of carcinoma of the sigmoid until proved otherwise It is now apparent that bleeding is commoner in diverticulitis than had been appreciated previously Although it is true that a polyp may be concealed within the segment of colon involved by diverticulitis and may be responsible for the bleeding, it is now known that actual hemorrhage may be a serious complication and that such hemorrhage may lead to exsanguination if it is not recognized and treated in time

If diverticulitis has progressed to perforation, the usual signs of sepsis within the abdomen will become apparent The tenderness may become generalized, paralytic ileus may be extreme, and evidence of disseminated peritonitis may be apparent If the sepsis is localized by nature, an abscess may proceed to the point of threatening rupture through the skin Surgical drainage of such an abscess often leads to a colocutaneous fistula As already mentioned, should the involved intestine perforate into the urinary bladder, a colovesical fistula results that may defy vigorous efforts at proper treatment Perforation of the intestine into the vagina, other loops of colon, or the small intestine has been noted on numerous occasions

### Laboratory Findings

These are not particularly pathognomonic Leukocytosis may be advanced but will not be particularly helpful in the differentiation of diverticulitis from other perforating intraperitoneal lesions The erythrocytic sedimentation rate may

reveal variations that also are not particularly helpful The sedimentation rate may remain increased long after the acute inflammatory process has subsided, and it is not to be relied on in attempting to decide the proper interval for surgical intervention if all other clinical manifestations have led to the proper decision The inflammation may produce its most intense findings in the right portion of the abdomen which accounts for occasional confusion with appendicitis

## DIAGNOSIS

The most important factor in establishing the proper diagnosis of diverticulitis is an accurate clinical history Previous bouts of inflammatory changes will have led to roentgenologic studies in the interval and diverticulitis will be a matter of record for the patient Accurate interpretation of the previous clinical picture combined with the present symptoms and signs will suffice in most instances

Fig 21 2 Typical x ray appearance of diverticulosis with diverticulitis

### Roentgenologic Aspects

The x ray findings are usually specific (Figs 21 2 21 3) The experienced roentgenologist looks for a strictured zone especially in the sigmoid colon When this is a long narrow segment, much longer than that commonly seen with a malignant tumor, coupled with little or no disturbance of the mucous membrane pattern and with visualization of the typical sacs whether at the same location or near it the diagnosis is not often difficult However, the most experienced roentgenologist is the first to admit that he cannot distinguish this lesion with complete certainty in some cases and he is well advised to report only an obstructing mechanism in the sigmoid colon whose true nature cannot be determined at the moment Many carcinomas of the sigmoid are coincidental with scattered diverticula so that the mere presence of sacs can be misleading If the lesion has perforated one looks for the presence of free air in the peritoneal cavity especially below the diaphragm In the chronic progressive type of obstruction roentgenologic studies reveal dilatation of the colon proximal to the offending mechanism and the results of such studies correspond accurately with the clinical picture Secondary roentgenologic findings of note in many cases of diverticulitis include spasm in the segment involved

Fig 21 3 Diverticulosis of sigmoid with a coincidental polyp (*arrow*)

which ordinarily is not present in carcinoma The sharp borders of a malignant tumor usually are evident but may not be sufficiently clear-cut to give the surgeon or the roentgenologist a complete sense of diagnostic confidence The diagnosis frequently must be made finally by the pathologist

## Proctoscopy

Proctoscopic findings are interesting but rarely are particularly helpful The proctologist will note acute angulation at the lower level of the sigmoid Pronounced fixation of the colon is present above this point, so that he is well advised not to persist too vigorously with the examination for fear of perforation of the diseased colon He will not be able to see the inflammatory process itself in the majority of cases, although he will detect ostia and sacculation in many instances The proctologist may note blood oozing from the ostia, an observation of great value to the surgeon in attempting to decide whether rectal hemorrhage is on the basis of diverticulitis alone Diverticula may become inverted and p oject into the lumen like polyps The resemblance is so close that they have even been fulgurated, which of course could result in peritonitis

The most disturbing group of patients are those who have a clinical picture suggestive of diverticulitis with proctoscopic findings that are equivocal and roentgenologic findings that are largely normal This situation prevails most often between attacks of diverticulitis The ostia presumably are edematous and closed temporarily, so that the barium passes them by and gives no visualization of the typical saclike projections The experienced surgeon will proceed with proper treatment on the basis of the clinical picture in such cases

## Differential Diagnosis

One attempts to differentiate the se vere acute form of diverticulitis from other types of acute intra-abdominal lesions that perforate and form abscesses or lead to general peritonitis The most obvious confusion arises with appendicitis Acute diverticulitis has been likened to "left-sided appendicitis ' and this is as good a description as any It might appear that a right-sided syndrome should rule out diverticulitis but, as already mentioned, the distinction between right-sided and left sided origin of the pathologic changes occasionally is most difficult to assess

Fig 21 4 The x ray impression in this case was diverticulosis with diverticulitis and ob struction At operation, a large carcinoma of the left ovary was attached to the sigmoid colon, producing obstruction from the extrinsic mass

Salpingitis or inflammatory and hemorrhagic changes produced in an ovarian cyst that has become twisted on its pedicle occasionally produce considerable confusion More than one experienced gynecologist has proceeded with surgical treatment of what was expected to be disease of the uterine adnexa, only to discover that he was actually dealing with severe diverticulitis Before one operates because of a left adnexal mass, it is comforting to have ruled out diverticulitis by means of colonic fluoroscopy

A left ureteral stone producing severe

reflex ileus associated with secondary sepsis of the upper part of the urinary tract may well pose an appreciable problem Ordinarily, proper identification will follow the usual type of urologic investigation

Masses arising from other viscera or other sites of origin within the abdomen occasionally introduce some question about the proper diagnosis (Fig 21-4) Regional enteritis may present a pattern similar to that of diverticulitis of the colon, especially if there is any attempt on the part of nature to form an abnormal communication between loops of intestine

The most important differential diagnosis to be made is that between carcinoma of the colon and diverticulitis Although on a theoretic basis the distinction should not be difficult, in the final analysis a course of treatment may have to be selected at an early date because colonic carcinoma cannot be ruled out

## COMPLICATIONS

Most of these patients have had previous attacks of acute diverticulitis that



Fig 21 5 Diverticulitis of sigmoid with spontaneous external fistula and perisigmoidal abscess

have subsided on conservative management A common complication of these attacks is stricture of the colon most often at the level of the sigmoid Routine roentgenologic studies may disclose a long narrow segment that may come as a bit of a surprise to the patient Distressingly often the patient is obese and attributes the constipation to that factor If the stricture progresses to the point of virtual loss of the lumen, obstruction becomes apparent It is not common to observe such complete obstruction that gas cannot be expelled through the rectum, but emergency measures for obstruction occasionally have been required More frequently, the obstruction takes the form of chronic pain in the left lower quadrant, with intermittent cramps The patient may expel gas frequently enough that proper treatment will be delayed and he may be forced to suffer unnecessarily on that basis The obstruction associated with diverticulitis typically is relenting in nature, so that the proximal colon may not be dilated This is in sharp contradistinction to carcinoma of the sigmoid, in which the constant unrelenting obstruction produces a dilated proximal segment

Perforation is one of the most feared complications This may involve a single diverticulum and may be sealed off quickly by epiploic tags, omentum or other viscera Frequently, however the perforation results in advanced abscess formation and occasionally in generalized peritonitis The localized pelvic abscess most often resolves, but it can lead to further intra abdominal sepsis such as subphrenic collections or suppurative processes in the portal vein system, or even to septicemia As noted previously, formation of fistulas is a relatively frequent and extremely severe complication (Fig 21 5) If the abscess has been drained surgically, the fistula will discharge on the skin of the abdominal wall and probably will remain patent until corrected surgically If the process has ruptured into the urinary bladder, the obvious vesicosigmoid fistula will persist. Other structures may become involved secondarily In the presence of any obstinate or recurrent urinary infection it is well to rule out this complication of diverticulitis by means of both cystoscopy and colonic fluoroscopy

Hemorrhage as a complication of di

verticulitis is assuming a more and more important role, although it was not recognized widely until recent years, as already noted (Mobley *et al*) Bleeding is usually intermittent and occasionally is only mild, whereas the bleeding accompanying carcinoma of the sigmoid usually is constant Although exsanguinating hemorrhage is fortunately rare, more and more reports are forthcoming concerning the necessity for emergency resection of the colon on the basis of hemorrhagic diverticulitis

## INDICATIONS FOR SURGICAL TREATMENT

The indications for surgical intervention correspond to the complications already outlined In earlier years, since resection of the colon almost always required a multiple-stage operation, internists (and many surgeons) were content to treat most patients medically This resulted in protracted loss of time from work and repeated hospitalization, with the attendant risk, expense, and psychic trauma necessarily accompanying a series of hospitalizations It is to be admitted that surgeons concurred in this conservative plan when they realized their own limitations and further remembered that they were forced to leave the patient with at least one colonic stoma for a variable number of months or even years In the light of modern developments, however, a gratifying change for the better has occurred (Gilchrist and Economou, Moore and Kirksey, Waugh and Walt, 1957, Welch *et al*) It is now common knowledge that patients no longer need be forced to 'weather through' repeated attacks, as they may be safely conducted through complete eradication of the entire process in one stage Several recent studies have proved beyond any doubt that single-stage surgical therapy now can be offered to a large majority of patients, if they are treated at the proper time and if certain rigid criteria are followed closely (Judd and Smith, Waugh and Walt, 1956 and 1957)

Recent study of several large series at the clinic shows that the commonest indication for surgical treatment at present is inability to rule out carcinoma of the colon after exhaustive study (Judd and Smith, Waugh and Walt 1957) The presence of an abdominal mass that may be felt on manual palpation of the abdomen or on rectal or vaginal examination or both, raises serious question as to the nature of the process With the present day adjuncts to surgical therapy that are universally available such a mass may be approached surgically with extremely low morbidity and mortality rates

The second commonest indication is intractability of the process in the form of recurring attacks of acute diverticulitis Although the patient may be expected to weather through an isolated attack and may feel normal several weeks later, the pathologic changes may leave considerable residue, so that at varying intervals the patient will experience the same syndrome all over again We are firmly convinced that this train of events should be interrupted at the earliest possible opportunity by orderly, elective, corrective surgical intervention carried out in thoroughly prepared patients at the optimal time (Judd)

The third commonest indication for surgical treatment in our experience has been the presence of a colonic fistula Usually such a fistula will be all too evident, but occasionally there is an imminent fistula that only the closest study will reveal at a time when it still can be corrected by early surgical intervention Therefore, the man who has severe diverticulitis and who presents suspicious microscopic findings in the urine or even definite urinary symptoms must be looked on as a candidate for the early formation of a fistula We consider that proper surgical treatment given at the proper time will produce a much more satisfactory result in such an instance

Obstruction of the colon requires relief The patient frequently may be prepared sufficiently well so that elective surgical therapy may be conducted with great safety However, we occasionally

see patients with advanced distention of the colon who cannot be prepared properly and who must accept the only alternative, namely proximal colostomy done as a preliminary procedure, followed at some interval by elective resection

Perforation of the colon demands surgical intervention, and we believe that this indication should be given more preference than it has been accorded in the past The perforation actually may be a free one, so that generalized peritonitis is already present More often, however, the omentum or adjacent viscera have sealed the perforation in part, so that formation of an abscess with extreme cellulitis has resulted Occasionally, as has been mentioned, the perforation progresses to produce fistulas in other sites, such as loops of intestine, the urinary bladder and, especially if drainage has been attempted, in the skin of the abdominal wall

Hemorrhage from diverticulitis is receiving much more attention than was the case in earlier years, since massive hemorrhage now is being recognized with increasing frequency Rarely will the surgeon be called on to resect the colon as an emergency measure with hemorrhage as the only indication However, exsanguinating bleeding will demand that this be considered more and more frequently in the future This history more often is one of recurring bleeding, whereas we formerly considered that bleeding from a mass in the colon most surely indicated carcinoma or at least a polyp, we now know that hemorrhage should take its rightful place in the list of indications for surgical intervention for diverticulitis

## OPERATIVE PROCEDURES

### Simple Suture

This operation is mentioned largely to be condemned It has been said that the offending diverticulum in the presence of perforation may be located and closed This is highly unlikely, as most often the surgeon finds a brawny indurated mass, with or without frank pus, and he is faced with an impossible situation as far as simple suture is concerned If the lesion appears to be entirely inoperable, as it occasionally will, it is necessary to provide proximal diversion of the fecal stream In instances in which a single diverticulum might be sutured, it still appears preferable to provide a proximal vent in the colon, as a fecal fistula most surely could be expected If an abscess is encountered, it has been our practice simply to drain it, as the affected intestine usually cannot be removed safely Because of the inflammatory changes involving the viscera, ureters, kidneys, and iliac blood vessels, it would be foolhardy to attempt resection Having established proper drainage, we have insisted on proximal colostomy to prevent the inevitable disorderly fecal fistula that would eventuate otherwise

### Colostomy and Subsequent Resection

Colostomy now is employed with far less frequency than in earlier years because of modern adjuncts to surgical care However, in acute diverticulitis, in diverticulitis with severe colonic obstruction, and in other similar situations, proximal colostomy is still the method of choice It has been our practice to place the colonic stoma in the proximal portion of the transverse colon, making certain that complete diversion of the fecal stream has been produced This may require actual division of the colon and separate cutaneous incisions for each loop of intestine Numerous ingenious methods have been devised to insure complete diversion We have preferred the stoma in the transverse colon, to keep the entire left abdominal wall and left abdomen free for the subsequent definitive resection of the diseased intestine Earlier we had thought it a mistake to place the stoma in the descending colon or upper part of the sigmoid, although it is granted that the character of the stool in this part of the colon is far less irritating to the skin of the abdominal wall and there is

greater ease of management of such a stoma We had been impressed in such cases with the difficulty of clean, complete, subsequent resection because of the presence of the colonic stoma At the present time, we are considering deliberate establishment of a left sided colonic stoma so that complete preparation of the colon a little later will allow not only resection of the diseased intestine but also removal of the colonic stoma at the same time, thus eliminating one stage in the multiple stage operation Our experience in a few such cases indicates that this usage may well be extended

Most patients exhibit striking improvement within a few months after establishment of the proximal colonic stoma Indeed it is a temptation then simply to close the stoma, especially when the roentgenologist pronounces the distal segment to be free of any inflammatory change Yielding to this temptation will be fraught with disappointment in at least two thirds of the cases, as recurrent diverticulitis has been the rule in such a situation Until recently, we insisted on an interval of 6 months after establishing the stoma before proceeding with definitive resection With proper preparation this interval might well be cut in half or shortened even further Considerable evidence of inflammatory changes still may be present if a shorter interval has been observed, but with present day adjuncts this has not altered the outcome One advantage of a shorter interval is that the lumen of the distal segment is not allowed to shrink down to such an unmanageable caliber as is the rule if 6 to 12 months have intervened After proximal colostomy for what is believed to be perforating diverticulitis if the patient does not show evidence of definite improvement of the perforative signs within 3 or 4 weeks, one should suspect the presence of perforating carcinoma and proceed with resection without delay

The Mikulicz type of resection had been employed in earlier days even though a proximal colonic stoma had been established This was considered necessary because the perisigmoiditis had left considerable brawny induration in the surrounding tissue and primary anastomosis did not appear feasible Use of the Mikulicz operation has been reduced sharply in recent years

In the multiple stage operation we ordinarily have waited for at least a few weeks after the definitive resection with end to end anastomosis before finally closing the preliminary proximal colonic stoma We prepare the patient thoroughly before this final operation thus eliminating the spur crushing clamp used commonly only a few years ago and reducing the number of stages considerably An accurate intraperitoneal closure of the colonic stoma may be done readily with extremely favorable morbidity and mortality rates Even at best a case of severe diverticulitis may require the patient to be away from his work for as long as a year if the type of work requires his absence when he has the colonic stoma It is obvious that any improvement in this situation should be looked on with considerable interest

## Obstructive Resection

This type of operation still has a place in the management of diverticulitis It is merely a modified Mikulicz operation that gained wide acceptance some years ago because of the work of Rankin We have employed it in borderline cases having exposed the sigmoid by a left sided incision and having decided that the inflammatory change is too severe to allow proper single stage resection with immediate primary end to-end colocolostomy In this type of resection the sigmoid is mobilized as completely as the inflammatory changes will permit Since malignant tumors are absent, only limited amounts of mesentery need be removed and the short segment of colon may be amputated over a three bladed clamp or a pair of Payr clamps (Fig 21 6) We are careful to rotate the two loops of colon so that a deliberate spur is created (Fig 21 7) After selection of this safe method, it formerly was considered advantageous to continue in the

safest possible way, which called for crushing the spur by means of clamps and the ultimate extraperitoneal closure of the stoma (Fig 21-8) With the adjuncts available today, one might well eliminate the spur crushing stages and simply close the colonic stoma after suitable preparation However, the obstructive resection itself may leave the ends of



Fig 21 6 Obstructive type of resection formerly used extensively but now reserved for emergency situations or extremely inflammatory lesions

the intestine in an awkward position, so that this is not entirely feasible Obstructive resection has been considered until recent years as a much safer method than a one stage operation, probably it will continue to have a limited field of usefulness

### Single-Stage Resection with Immediate Primary Anastomosis

This method is gaining a great deal of favor, especially throughout the United States It is never to be considered when

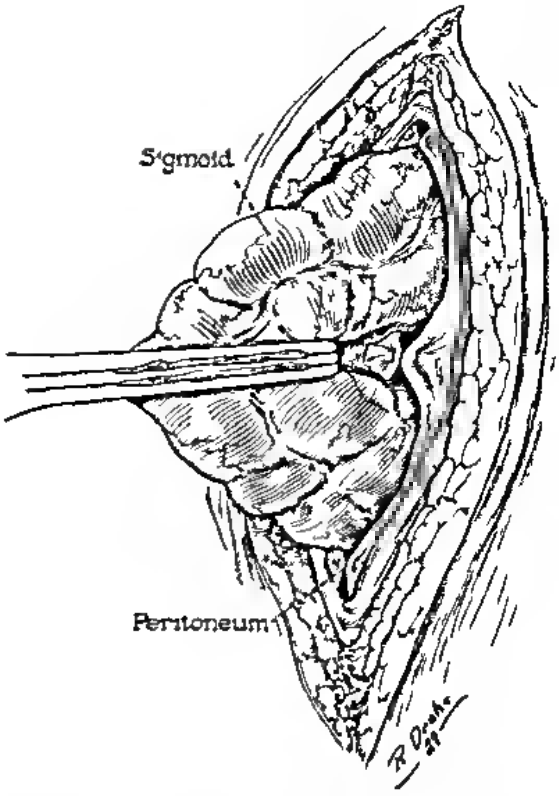


Fig 21-7 After amputation of the mass by cautery (obstructive resection), a double-barreled stoma will result when the clamp comes off

Fig 21 8 Intermediate step in the obstructive resection, consisting of application of crushing clamps to the septum, or spur" The ischemic necrosis results later in a channel between the proximal and distal loops so that the final stage of closure of the stoma is carried out at a later date

the inflammatory change has progressed to the point of rendering the operation hazardous technically However, with complete modern preparation, the method is entirely feasible and, in properly selected patients, it has been demonstrated repeatedly to be the operation of choice In several large series at the clinic, it has been found that even when fistulas are

present, including those involving the urinary bladder, a one-stage operation will be satisfactory in some cases We never have considered it when the colon is acutely distended, but our efforts of late have been directed toward impressing on our colleagues in internal medicine, as well as on the public at large, the value of resection between attacks of acute diverticulitis, because at that time we can prepare the patient and his colon completely and carry out an orderly, accurate, one stage procedure We prefer to have the patient in the hospital at least 2 days before the operation During this time, he is given saline cathartics and vigorous irrigations of the colon to render the content liquid and cleanse the intestine as well as possible Opinions differ as to the best antibacterial program to be employed, and we have tried several different plans, all of which have something to recommend them A two day period of effective antibiotic therapy planned to eradicate the coliform flora in the stool has reduced the morbidity and mortality rates to an extremely low figure Of course other factors such as anemia, low serum proteins, cardiac and pulmonary difficulties, and metabolic problems first must be brought under reasonable control

A low left rectus vertical incision extending from the pubis to a point above the umbilicus often gives satisfactory exposure. An oblique incision may be preferred by some surgeons and has many advantages in certain types of bodily configuration The colon is mobilized by incising the lateral peritoneal attachments as high as the splenic zone As already noted, removal of the mesentery need not be particularly wide if one is certain that only benign disease is present. The mere presence of diverticula in the upper part of the descending colon or the distal portion of the transverse colon has not demanded subtotal colectomy in every instance, since diverticulitis strikes only the sigmoid in 98 per cent of cases However, if melena has been a factor, it is well to extend the resection to include all obvious diverticula The point of division of the colon should be inspected with extreme care to be certain that sutures are not placed in or near diverticula, the obvious weak spots It may be necessary to mobilize the rectum posteriorly if the lesion is low, but this can be accomplished readily so that the ends of the intestine may be approximated without tension Whether one employs an 'open or a 'closed" anastomosis is entirely the choice of the individual surgeon, in our hands, the two techniques have resulted in about the same ultimate outcome We ordinarily employ a two-row anastomosis the outer layer being of interrupted sutures of silk or a similar nonabsorbable material We are careful to close the mesenteric defect to prevent internal herniation The lateral peritoneum may be closed, at least in part as the resection need not be as radical as in the average operation for carcinoma On many occasions, we have passed a long rectal tube upward through the anastomosis and left it in place for a few days

We are enthusiastic about the use of an indwelling nasogastric tube for a few days after operation to eliminate the factor of swallowed air Such tubes usually are tolerated well and are removed before any problem arises concerning esophagitis or pharyngitis Rarely is it necessary to employ the temporary 'catheter gastrostomy currently in great vogue for many types of gastrointestinal operations

## MORBIDITY AND MORTALITY

The morbidity associated with surgical treatment of diverticulitis depends entirely on the individual circumstances In the perforated intestine with generalized peritonitis or extreme abscess formation, the morbidity in earlier years was considerable. With prompt drainage and diversion of the fecal stream coupled with proper antibiotic therapy, the morbidity at present is much less Of necessity when a multiple stage operation has

been necessary, the patient must be prepared for a prolonged convalescence with multiple hospitalization problems However, modern adjuncts have done much to reduce these difficulties In addition to the complications one would expect with abdominal surgical intervention of this magnitude, one is prepared for those accompanying the infected, distended, and even perforated intestine Wound infection and abscesses are not uncommon, but their incidence may be reduced with proper preventive measures Dehiscence of the wound, although less common than was formerly noted, still must be guarded against Postoperative peritonitis still may be a factor, especially if indiscriminate antibiotic therapy has been employed and the bacteria have become resistant to ordinary agents Urinary infections are common, as the bladder and ureters may have been compromised by pre existing abscesses or fistulas

Other complications are much the same as those for surgical treatment in this general region of the abdomen When the one stage operation is done on a properly prepared patient, we have reason to expect a far less complicated convalescence Although some pulmonary complications may exist and minor wound infections may develop, we are much better prepared to deal with these problems and keep them minor Thus, whereas multiple stage operations may require the patient to be away from work for perhaps six months at least and during that time to be hospitalized for 45 to 60 days, now it is entirely reasonable to expect that a properly conducted one stage operation would necessitate a single trip to the hospital whose duration would be perhaps 12 to 14 days, including the entire preoperative preparation The advantages of this situation are too obvious for further mention

In regard to the mortality rate, surgeons in an earlier day accepted a certain mortality rate, dealing as they were with such badly complicated conditions This situation probably will continue when the disease is neglected or extremely complex However, in the most recent clinic series of 113 consecutive one stage resections, only a single death occurred in the hospital and this was from a coincidental problem having no relation to either the diverticulitis or the operation

## RESULTS

As mentioned previously, if a patient has proximal colostomy only and the stoma is closed later without resection we have learned that in two thirds of such instances recurrent diverticulitis will develop, demanding more aggressive treatment Since diverticulitis is in the sigmoid in 98 per cent of cases, one might expect that a 98 per cent rate of cure would be achieved by removing the sigmoid This, of course, is not realized in actual practice Recurrence has been reported after resection, but this may prove on careful scrutiny to be disruption of the suture line with secondary formation of fistulas or persistent abscesses Another possibility is the development of diverticulitis in the descending colon especially if a stricture has formed at the anastomosis distal to this point It is difficult to assess the rate of cure on an accurate percentage scale, but results of removal of the diseased intestine in our experience have been as satisfactory as those of any surgical treatment we undertake

## REFERENCES

Gilchrist, R K, and Economou, S Surgical treatment of diverticulitis of colon. *A.M.A Arch Surg 70* 276, 1955

Judd, E S Prophylactic resection for recurrent sigmoidal diverticulitis *Surg Gynec & Obst 101* 105, 1955

Judd, E S, and Smith, M P Present trends in surgical treatment of diverticulitis *S Clin North America*, August, 1957, pp. 1019–1027

Mobley, J E, Dockerty, M B, and Waugh, J M Bleeding in colonic diverticulitis *Am J Surg 94* 44, 1957

MOORE, R M, and KIRKSEY, O T, JR One stage resection in selected cases of sigmoid diverticulitis *Ann Surg 139* 826, 1954

WAUGH, J M, and WALT, A J Changing concepts in the treatment of diverticulitis of the sigmoid *Journal Lancet 76* 373, 1956

WAUGH, J M, and WALT A J An appraisal of one stage anterior resection in diverticulitis of the sigmoid colon *Surg Gynec & Obst 104* 690, 1957

WELCH, C E ALLEN A W and DONALDSON G A Appraisal of resection of colon for diverticulitis of sigmoid *Ann Surg 138* 332, 1953

CHAPTER 22

# TUMORS OF THE RECTUM AND ANUS

*Rupert B Turnbull, Jr , and George Crile, Jr*

## TUMORS OF THE RECTUM

### Incidence

Rectal cancer ranked sixth and seventh respectively in males and females as a cause of death from cancer in the United States from 1955* (Table 22 1) In ten major cities of the United States for 1947 and 1948† cancer of the rectum was sixth position both for men and for women with an incidence of 5 4 per cent of all cancers (skin cancer excluded) Should the rectum and colon be considered as a single organ—then cancer from the two would assume an important second place in frequency for both men and women in the United States The reported number is increasing too influenced in part by better reporting by increasing numbers of proctoscopic examinations of cancer conscious patients by an alerted profession by the inclusion of so called malignant polyps and the increased life expectancy of the population as a whole with more people coming into the cancer age

TABLE 22 1 FREQUENCY OF OCCURRENCE OF CANCER AND DEATH RATES UNITED STATES 1955

| *Male* | | | *Female* | | |
|---|---|---|---|---|---|
| *Frequency rat ng* | *S te of cancer* | *Deaths per 100,000 populat on* | *Frequency rat ng* | *S te of cancer* | *Deaths per 100 000 populat on* |
| 1 | Lung bronchus and trachea | 28 0 | 1 | Breast | 26 1 |
| 2 | Stomach | 17 5 | 2 | Uterus | 18 2 |
| 3 | Prostate | 16 6 | 3 | Colon | 16 5 |
| 4 | Colon | 14 0 | 4 | Stomach | 9 8 |
| 5 | Pancreas | 8 3 | 5 | Ovary | 8 5 |
| 6 | Rectum | 7 7 | 6 | Liver and bile passages | 6 3 |
| | | | 7 | Rectum | 5 8 |

* Nat onal Office of Vital Stat stics Stat stical Research Sect on Med cal Affairs Department American Cancer Society October 16 1957

† Public Health Service Cancer Morb d ty Series, No 1 10 1950–1957

### Age

Rankin and Graham state that "age is no barrier to the occurrence of malignant lesions of the colon and

rectum" This is true but there are relatively few patients with cancer of the rectum less than 30 years of age At the Cleveland Clinic the majority are from 55 to 65 years of age Gant, in 1902, placed the greatest incidence of cancer of the rectum between the fourth and sixth decades of life

## Site of Growth

The rectum and the sigmoid colon are the commonest sites of cancer in the large intestine The cecum is second In 3,542 patients with cancer of the colon, 75 per cent were in the terminal portion, which emphasizes the value of digital and proctoscopic examinations in the early diagnosis of this disease If the rectum is considered to extend 15 cm above the dentate line, and then arbitrarily divided into thirds about 5 cm in length roughly 80 per cent would be located above the 5 cm level (Table 22-2) (Fig 22-1 )

## Multiple Carcinoma of the Rectum

Carcinomas can coexist in the rectum However, if satellite polyps (in which histopathologic cancer can be demonstrated) and cancers arising in the presence of familial polyposis are eliminated, the incidence of dual lesions is low Generally, multiple carcinomas of the rectum are more likely to occur in young patients or in those who have polyposis of the familial or acquired type

## Etiology

The cause of rectal cancer is unknown It is unusual for cancer to be preceded by recognizable precancerous lesions in any organ of the body, even in the colon and the rectum The majority of cancers of the rectum develop insidiously without premonitory signs or symptoms, but (1) familial polyposis, (2) solitary or localized adenomatous tumors of the rectum (rectal polyps), and (3) chronic nonspecific ulcerative colitis are known precancerous lesions And, although the prompt and successful treatment of precancerous conditions could prevent intestinal cancer only in a small fraction of cases, it is the only method of control we have at this time

TABLE 22 2 SITES AND PERCENTAGES OF OCCURRENCE IN 3,542 PATIENTS WITH COLONIC AND RECTAL CANCERS
(Adapted from Rankin and Graham)

| *Site of cancer* | *Number of patients* | *Percentage of 3 542 patients* |
|---|---|---|
| Rectum | 1 599 | 45 14 |
| Rectosigmoid | 627 | 17 70 |
| Sigmoid colon | 480 | 13 55 |
| Cecum | 211 | 5 95 |
| Colon | 602 | 16 99 |
| Anus | 23 | 0 64 |

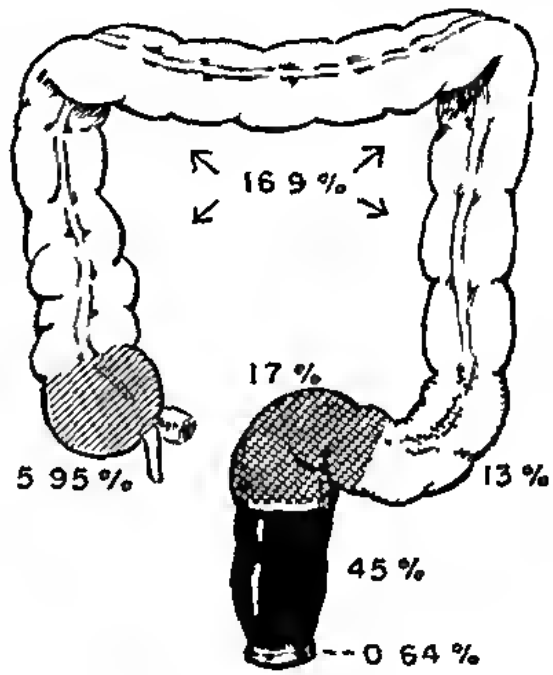


Fig 22 1 Incidence of cancer in rectum and colon By location (*After* Rankin and Graham )

## Precancerous Lesions of the Rectum

### *Familial Polyposis*

ORIGIN Familial polyposis (transmitted by a dominant gene) is accepted as a precancerous disease. Adenomatous

polyps appear in the rectum some time after birth The growth rate of the polyps is governed by unknown factors Although the polyps are usually disseminated through the colon and the rectum, we have observed some persons in whom no rectal polyps are found Cancer may develop within the polyps or from the mucosa between them at any time after the age of 16 years By the age of 40 years, most persons so afflicted will have succumbed from cancer if prophylactic surgery has not been done The diagnosis of polyposis is easily made from examination of the rectum or colon 'Parrot beaking' of the finger nails or clubbing of the fingers and toes often is present Patients with familial polyposis have a history of loose stools or excessive diarrhea and anemia A sharp change in bowel habit, the occurrence of blood, and of diarrhea alternating with constipation, may be the first indication that cancer is present In some instances there is no previous familial history of colonic cancer, but the polyposis of the colon and rectum may be of the disseminated familial type with the same potential for cancer

Rectal polyposis may exist without involvement of the colon, this is not to be included in the familial variety In the Peutz Jeghers syndrome there is disseminated polyposis of the colon and the rectum, as well as of the small intestine, and pigment is found distributed on various portions of the body, particularly the lips, in the form of lentigenes

Inflammatory polyposis (pseudopolyposis) of chronic ulcerative colitis, multiple benign lymphoid polyps of the rectum, and polypoid hypertrophy of the mucosa (mucosal polyposis), are easily differentiated by study of biopsy specimens Polypoid hypertrophy of the mucosa of the rectum may appear on proctoscopic examination to be multiple polyposis (adenomatous polyps), but again is differentiated by a microscopic study of excised tissue These mucosal polyps are not adenomas, but are simply hypertrophic polypoid projections of the mucosa For these reasons, biopsy always is indicated

TREATMENT OF FAMILIAL POLYPOSIS In this relatively rare disease prophylactic surgery will serve best to protect the patient from colorectal cancer Although Dukes found the incidence of cancer to be 70 per cent in patients with inherited polyposis, it is best that the development of a colorectal cancer should be considered inevitable and the patient treated accordingly Colectomy and a permanent ileostomy would ideally prevent the occurrence of colorectal cancer, but many of the patients are young and relatively asymptomatic In the light of recent observations on the spontaneous disappearance of rectal polyps following colectomy and ileorectal anastomosis this radical treatment may not be necessary

SURGICAL PRINCIPLES If rectal cancer is not present, it is sufficient to remove all the colon and the upper portion of the rectum, making a low ileorectal anastomosis This relatively short remnant of the large intestine may be visualized at six month intervals, and any polyps that are present may be treated by electrocoagulation Fortunately, the development of cancer in the residual rectal segment is infrequent In recent years we and others have observed that if the rectal polyps are left untreated and the colon is removed and ileorectal anastomosis is established at a low level, the rectal polyps disappear in some of the patients There is therefore little reason to remove the rectum on the grounds that too many polyps are present"

SURGICAL TECHNIQUE Colectomy with ileorectal anastomosis can be performed safely in one stage in patients who are young and in good health After adequate preparation, the colon is removed with as much of the mesentery as possible, because of the ever present threat that a small carcinoma with metastatic paracolic nodes may exist The ileum should be divided at the ileocecal valve, care being taken to preserve the ileocolic artery and vein and their branches to the

terminal ileum Anastomosis is made between the ileum and the rectum at a point about 5 or 6 cm above the peritoneal reflexion after the rectum has been freed with a posterior dissection carried down well in front of Waldeyer's presacral endopelvic fascia It is neither necessary nor desirable to divide the lateral rectal ligaments After closing the end of the terminal ileum, side to side (or end to-end) ileorectal anastomosis is easily carried out with two layers of fine chromic catgut and silk sutures, ignoring the polyps that are present Atrophy and disappearance of rectal polyps may take from six to nine months At that time electrocoagulation of residual polyps may be carried out

### *Solitary or Localized Adenomatous Tumors of the Rectum*

Dukes has said that the only variety of rectal polyp that is in any way precancerous is an adenomatous tumor These tumors, sometimes referred to as "rectal polyps," are important because of the associated symptoms and their intimate association with rectal cancer In addition, they occasionally contain cancer They occur singly or in groups in the rectum and differ from the familial variety of polyposis in that the majority of patients in whom they are found do not develop cancer of the rectum (Fig 22-2)

INCIDENCE Rectal polyps become commoner with advancing years They occur more often in males than females Coller, Ransom, and Regan have stated, "An accurate estimate of the true incidence of polyps depends on the source or nature of material studied According to data from cancer detection centers, 2 to 7 per cent of the population have undetected polyps" Blue found that 12 to 14 per cent of persons more than 40 years of age had polyps of the colon while one of every ten persons of this age group has a polyp that can be discovered on proctoscopic examination

PATHOLOGY Rectal polyps are sessile or pedunculated masses of adenomatous tissue that may be localized or diffuse Some are papillary and may be so soft as to be missed entirely on digital examination The diffuse sessile polyp is velvety to the touch Some of the localized or pedunculated adenomatous polyps are solid tumors They may be firm or hard, depending on the amount of reactive fibrosis in the stroma or whether or not they contain foci of cancer

Rectal polyps may be clinically differentiated from rectal cancers The clinically benign rectal polyp is sessile or pedunculated reasonably soft, freely

Fig 22 2 Benign rectal polyp The adjacent mucosa is polypoid and following removal becomes excrescent so called recurrence"

movable, and nonulcerating Rectal cancers, on the other hand, are ulcerating and hard and there usually is some moderate local fixation While benign polyps bleed briskly after biopsy, carcinomas bleed but little, the tissue breaking away easily in the biopsy forceps Rarely, soft, polypoid cancers are indistinguishable from benign polyps except by histologic examination

The clinical differentiation between cancer and polyps is important because an important decision is to be made in regard to the treatment of the patient with (clinically benign) rectal polyp in which there are found foci of histopathologic cancer In general it may be said that any cancer is capable of metastasis, while benign appearing polyps

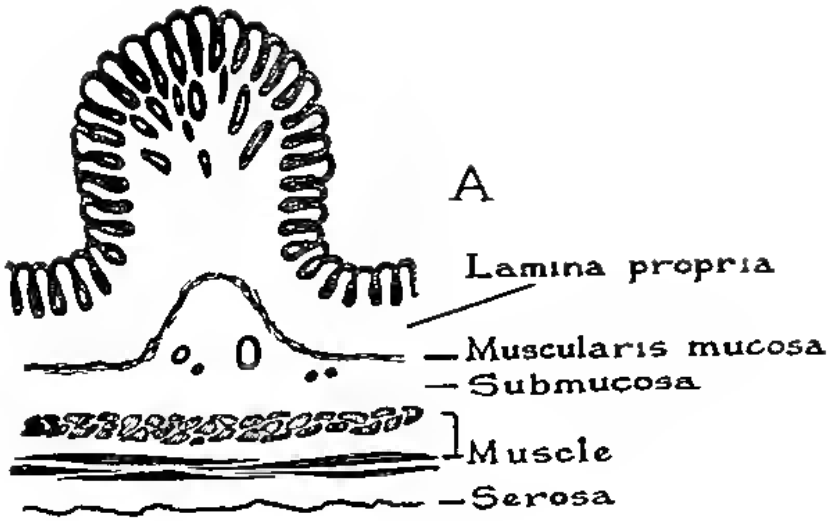


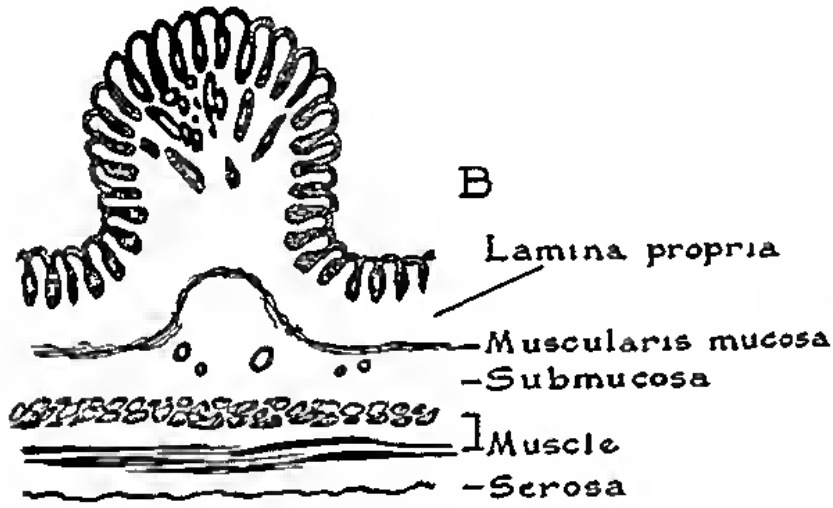


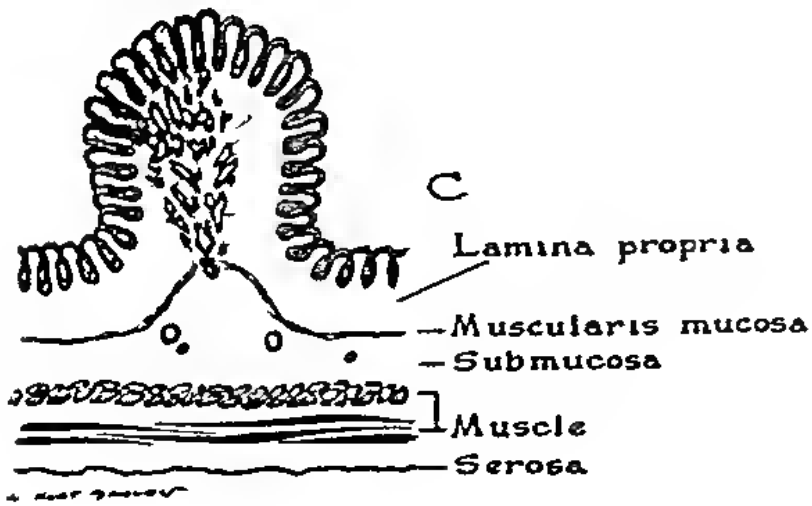


Fig 22 3 Classification of (carcinoma in) rectal polyps (*A*) *In situ* Cytologic carcinoma without invasion of basement membrane (*B*) *Superficial* Carcinoma with reduplication of the lumina and invasion of the basement membrane and lamina propria (*C*) *Invasive* carcinoma with invasion of muscularis mucosae and associated desmoplasia (*Courtesy Surgery Gynecology & Obstetrics 94* 4–5 May 1952 )

(in which there is histopathologic evidence of cancer) rarely metastasize and may be treated by local means

*Rectal polyps are important because of their association with cancer* The rectal polyp should be considered a sentinel for a cancer that may exist nearby or higher in the rectum or in the colon Half of our patients undergoing resection for colonic or rectal cancer have one or more rectal polyps At least one third of these patients have satellite polyps growing in the immediate vicinity of the cancer Although the majority of patients with a single rectal polyp have no associated cancer, the clinical rule of "look above" nevertheless is a good one to follow

CARCINOMATOUS FOCI IN RECTAL POLYPS Cancer may be histologically identified in about 10 per cent of rectal polyps, and may be invasive or noninvasive in respect to the underlying muscularis mucosae The type of cancer may be mucosal (carcinoma in situ) or superficial, extending into the lamina propria Invasive carcinoma invades the muscularis mucosae of the rectum and is accompanied by a desmoplastic tissue response

TREATMENT OF RECTAL POLYPS The most important consideration concerning rectal polyps is not " whether something should be done about the lesion, but what should be done " Polyps should be treated because of prolapse, bleeding, or the excessive secretion of mucus As precancerous lesions they should be destroyed There are certain prerequisites for treating rectal polyps First, all the mucosa of the rectum and the lower sigmoid colon should be examined minutely to ascertain whether or not a cancer exists in association with the polyp It is most important to visualize the pedicle of any polyp to be treated, to ascertain its site of origin and whether or not it is located at the margin of carcinoma Figure 22-4 depicts a small cancer closely associated with a pedunculated polyp




Fig 22-4 Pedunculated polyp of colon with small associated carcinoma

TREATMENT OF MALIGNANT RECTAL POLYPS The criteria for clinical benignancy in a rectal polyp have been stated previously Generally, rectal polyps in which there is demonstrable histologic cancer may be treated by local means if they look benign They rarely metastasize and metastasis is so infrequent that the risk of death from radical surgery far outweighs the possibility of death from spread to other organs Such a polyp must, however, appear to be benign to an experienced examiner In making

the final decision for radical surgery or the conservative removal of these polyps, one should constantly keep in mind the combined 97 7 per cent corrected five year survival rate of Dukes' *A* cancers of the rectum (Table 22-3)

TABLE 22-3 CANCER OF RECTUM FIVE YEAR SURVIVAL FOR A, B, AND C CASES*

| *Number of cases* | *Stage* | *Crude five-year survival rate, %* | *Corrected five year survival rate, %* |
|---|---|---|---|
| | MEN | | |
| 206 | A | 80 4 | 99 9 |
| 565 | B | 61 3 | 76 0 |
| 717 | C | 26 1 | 31 3 |
| | WOMEN | | |
| 129 | A | 81 8 | 93 8 |
| 206 | B | 71 6 | 82 0 |
| 433 | C | 29 1 | 32 7 |

* Republished through the courtesy of the Proceed ngs of the Royal Society of Med cine

We prefer mass coagulation as a method of treatment for rectal polyps Cold" surgical excision occasionally is indicated for a pedunculated polyp or one that has prolapsed through the anal canal and is under direct observation The cold surgical excision of polyps located higher in the rectum rarely is indicated and is difficult because of exposure and the risk of hemorrhage, moreover should occult cancer be present as it is in 10 per cent of polyps, it is not desirable to place any sutures because of the possibility of unplanting viable cancer tissues

*The removal of polyps by the electro*coagulating snare is in wide use, but has disadvantages and dangers The wire loop of the snare cannot be seen at all times when the current is applied, particularly for the removal of large polyps Damage to underlying structures or frank perforation may occur In addition, the electrocoagulating snare does not always control bleeding from the arteries in the submucosa Hemorrhage from sites above the 5 cm. level may be difficult to control other than by laparotomy We believe that "total excision" biopsy of polyps located high in the rectum is impractical and dangerous

### *Chronic Nonspecific Ulcerative Colitis*

This disease must be regarded as precancerous, but rarely under other than the following circumstances (1) long-standing ulcerative colitis, beginning before puberty, and (2) ulcerative colitis existing as active disease for more than 10 years

The over all incidence of cancer arising in the course of chronic nonspecific ulcerative colitis does not seem alarming, it is about 3 5 per cent This low incidence probably results from the annual inclusion into the total group of newly discovered cases

The pseudopolyposis of ulcerative colitis has little relation to the development of a cancer and is not an indication for colectomy Occasionally patients are examined who have had ulcerative colitis for more than 10 years and who are chronically ill but who do not particularly desire to undergo colectomy either for the treatment of their disease or for cancer prophylaxis Biopsy of the rectal mucosa at intervals has been of value in four such instances, the finding of carcinoma in situ and of the superficial type provided sufficient stimulus for the patients to undergo colectomy In each instance the mucosa of the colon was found to be similarly involved

Dukes states that " there is some evidence to suggest that cancer is most likely to develop in the healing phase of colitis at a time when medical supervision might be relaxed Perhaps this is due to the fact that at this stage two influences are operating which we know to predispose to cancer in other circumstances One of these is continual regeneration of epithelium and the other is the presence of abundant vaso-formative tissue This may provide an explanation for the liability to malignancy in the healing phase of the disease " Warning of the possibility of cancer must be given those with long-standing active colitis

Repeated roentgen study of the colon is useless, but occasional biopsy of the rectal mucosa may be the only method by which a colitis patient may be watched to detect malignant change in the mucosa

## Pathology of Carcinoma of the Rectum

### *Macroscopic Cancer*

If the pedunculated and sessile adenomatous and papillomatous polyps in which there are foci of adenocarcinoma are excluded from consideration there are four macroscopic types of cancer of the rectum

1 *Exophytic carcinoma* is a polypoid carcinoma that grows into the lumen of the bowel There is little or no invasion through the wall of the rectum The tumor is freely movable and tends to prolapse or intussuscept during bowel movements (Fig 22 5)

2 *Ulcerating sessile carcinoma* is the cancer most often seen in the rectum It grows in the direction opposite to that of the exophytic type, i e it grows into the wall of the bowel or through it In time it may slowly encompass the lumen of the rectum in napkin ring fashion There may be early lymphatic metastasis (Fig 22 6)

3 *Stenosing carcinoma* often occurs in the upper rectum and causes obstruction in the bowel The cancer is tough and resilient because of the great amount of reactive fibrosis (Fig 22 7)

4 *Diffuse carcinoma* of the rectum is surface cancer and may be noninvasive in regard to the muscularis or perirectal fat, it has an excellent prognosis On first examination it may appear to involve most of the mucosa

Fig 22 5 *Exophytic carcinoma* Note growth of the tumor into the lumen with little invasion of the bowel wall

Some carcinomas are broad and flat and are marginated by benign polypoid tumors Often this benign border is subjected to biopsy and leads to a false histopathologic diagnosis For this reason it is essential to examine carefully the mucosa of the rectum both above and below any benign appearing tumor

### *Microscopic Aspects*

Rectal cancer arises from the tubular glandular epithelium and therefore is classified as adenocarcinoma The tumor

the final decision for radical surgery or the conservative removal of these polyps one should constantly keep in mind the combined 97 7 per cent corrected five year survival rate of Dukes *A* cancers of the rectum (Table 22 3)

TABLE 22-3 CANCER OF RECTUM FIVE YEAR SURVIVAL FOR A B AND C CASES*

| *Number of cases* | *Stage* | *Crude five year survival rate %* | *Corrected five year survival rate %* |
|---|---|---|---|
| | MEN | | |
| 206 | A | 80 4 | 99 9 |
| 565 | B | 61 3 | 76 0 |
| 717 | C | 26 1 | 31 3 |
| | WOMEN | | |
| 129 | A | 81 8 | 93 8 |
| 206 | B | 71 6 | 82 0 |
| 433 | C | 29 1 | 32 7 |

* Republished through he cou tery of he Proceedings of he Royal Soc e y of Med ine

We prefer mass coagulation as a method of treatment for rectal polyps Cold surgical excision occasionally is indicated for a pedunculated polyp or one that has prolapsed through the anal canal and is under direct observation The cold surgical excision of polyps located higher in the rectum rarely is indicated and is difficult because of ex posure and the risk of hemorrhage, more over should occult cancer be present as it is in 10 per cent of polyps it is not de sirable to place any sutures because of the possibility of implanting viable cancer tissues

The removal of polyps by the electro-coagulating snare is in wide use but has disadvantages and dangers The wire loop of the snare cannot be seen at all times when the current is applied particularly for the removal of large polyps Damage to underlying structures or frank per foration may occur In addition the electrocoagulating snare does not always control bleeding from the arteries in the submucosa Hemorrhage from sites above the 5 cm. level may be difficult to con trol other than by laparotomy We be lieve that total excision biopsy of polyps located high in the rectum is im practical and dangerous

*Chronic Nonspecific Ulcerative Colitis*

This disease must be regarded as pre cancerous, but rarely under other than the following circumstances (1) long standing ulcerative colitis beginning be fore puberty, and (2) ulcerative colitis existing as active disease for more than 10 years

The over all incidence of cancer arising in the course of chronic nonspecific ulcera tive colitis does not seem alarming it is about 3 5 per cent This low incidence probably results from the annual inclusion into the total group of newly discovered cases

The pseudopolyposis of ulcerative colitis has little relation to the development of a cancer and is not an indication for colec tomy Occasionally patients are examined who have had ulcerative colitis for more than 10 years and who are chronically ill but who do not particularly desire to undergo colectomy either for the treat ment of their disease or for cancer prophylaxis Biopsy of the rectal mucosa at intervals has been of value in four such instances the finding of carcinoma in situ and of the superficial type pro-vided sufficient stimulus for the patients to undergo colectomy In each instance the mucosa of the colon was found to be similarly involved

Dukes states that there is some evidence to suggest that cancer is most likely to develop in the healing phase of colitis at a time when medical super vision might be relaxed Perhaps this is due to the fact that at this stage two influences are operating which we know to predispose to cancer in other circum stances One of these is continual re-generation of epithelium and the other is the presence of abundant *vaso-forma* tive tissue This may provide an explana tion for the liability to malignancy in the healing phase of the disease. Warning of the possibility of cancer must be given those with long-standing active colitis.

Repeated roentgen study of the colon is useless, but occasional biopsy of the rectal mucosa may be the only method by which a colitis patient may be "watched" to detect malignant change in the mucosa

## Pathology of Carcinoma of the Rectum

### *Macroscopic Cancer*

If the pedunculated and sessile adenomatous and papillomatous polyps in which there are foci of adenocarcinoma are excluded from consideration, there are four macroscopic types of cancer of the rectum

1 *Exophytic carcinoma* is a polypoid carcinoma that grows into the lumen of the bowel There is little or no invasion through the wall of the rectum The tumor is freely movable and tends to prolapse or intussuscept during bowel movements (Fig 22-5)

2 *Ulcerating sessile carcinoma* is the cancer most often seen in the rectum It grows in the direction opposite to that of the exophytic type, i e, it grows into the wall of the bowel or through it. In time it may slowly encompass the lumen of the rectum in napkin-ring fashion There may be early lymphatic metastasis (Fig 22 6)

3 *Stenosing carcinoma* often occurs in the upper rectum and causes obstruction in the bowel The cancer is tough and resilient because of the great amount of reactive fibrosis (Fig 22-7)

4 *Diffuse carcinoma* of the rectum is surface cancer and may be noninvasive in regard to the muscularis or perirectal fat, it has an excellent prognosis On first examination it may appear to involve most of the mucosa

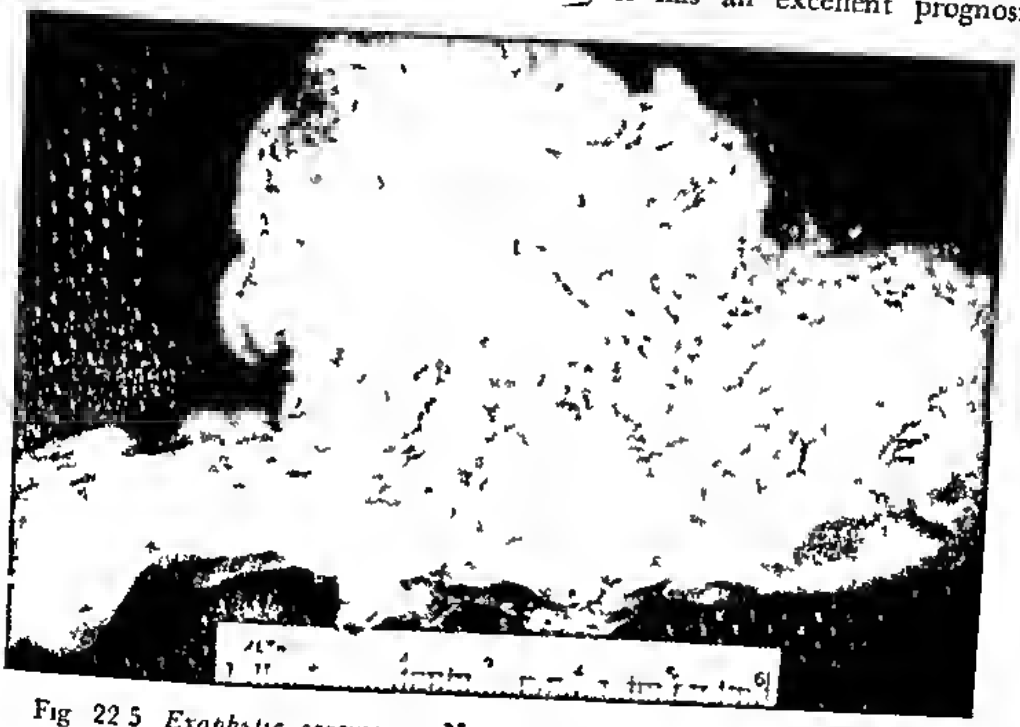

Fig 22 5 *Exophytic carcinoma* Note growth of the tumor into the lumen with little invasion of the bowel wall

Some carcinomas are broad and flat and are marginated by benign polypoid tumors Often this benign border is subjected to biopsy, and leads to a false histopathologic diagnosis For this reason it is essential to examine carefully the mucosa of the rectum both above and below any benign-appearing tumor

### *Microscopic Aspects*

Rectal cancer arises from the tubular glandular epithelium and therefore is classified as adenocarcinoma The tumor

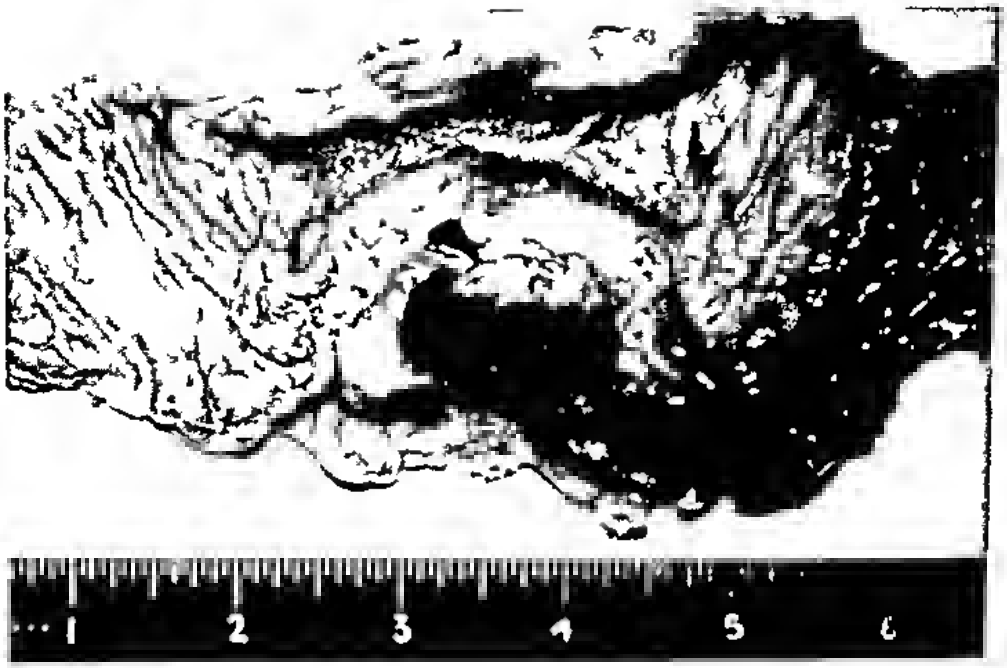


F g 22 6 Ulcerat ng sess le carc noma

F g 22 7 Stenos ng carc noma

is con posed of lam na of cuboidal or columnar cells with little tendency to form mucus Various amounts of ana plasia may be present in any one tumor

*Colloid carcinoma* is an adenocarci noma with mucus in the indiv dual cells which compresses the nucleus and cyto plasm to give the typical signet ring' appearance

*Anaplastic carcinoma* (carcinoma sim plex) shows little tendency to form glandular structures and the neoplastic cells exist as solid sheets

### *Microscopic Grading of Cancer*

Rectal cancers are graded by Broders method according to the predom nance of undifferentiated cells or glandular struc

tures seen microscopically The grading of tumors is dependent on the pathologist s interpretation of the portion of tumor selected for biopsy and is therefore not entirely representative, it involves an estimate of the amount of dedifferentiation seen on the sections Tumors of Grades 1 and 2 are least dedifferentiated and invasive and therefore have an excellent prognosis Tumors of Grades 3 and 4 are associated with vascular and lymphatic invasion and have only a fair to poor prognosis Most rectal cancers are Grade 3 Fortunately, Grade 4 tumors are less common, when discovered they have already invaded the lymphatic channels and the regional blood vessels

## Spread of Carcinoma

Carcinoma of the rectum may be confined to the lumen of the bowel or it may extend directly through the coats of the rectum into the surrounding fat or into the regional lymphatics or the blood vessels Submucosal spread of cancer of the rectum is unusual and may indicate a high grade of malignancy with extensive metastasis to the regional lymph nodes

LOCAL EXTENSION It is important to remember that fixation of a rectal cancer does not necessarily indicate inoperability or incurability Cancers on the anterior wall of the rectum may be bulky and immobile but they seldom invade the seminal vesicles prostate or neck of the bladder in the male, or the vagina in the female because of the protective Denonvilliers fascia, however, direct extension or fistulization into the cervix the vagina or the ureter is associated with a poor outlook Direct invasion of the dome of the bladder in the male by cancers located high on the anterior rectal wall does not connote a bad prognosis provided an en bloc resection is done well outside the cancerous borders Carcinomas of the upper rectum may transgress all coats of the rectum and extend directly into adjacent sigmoid colon small intestine, cecum, or appendix Although these

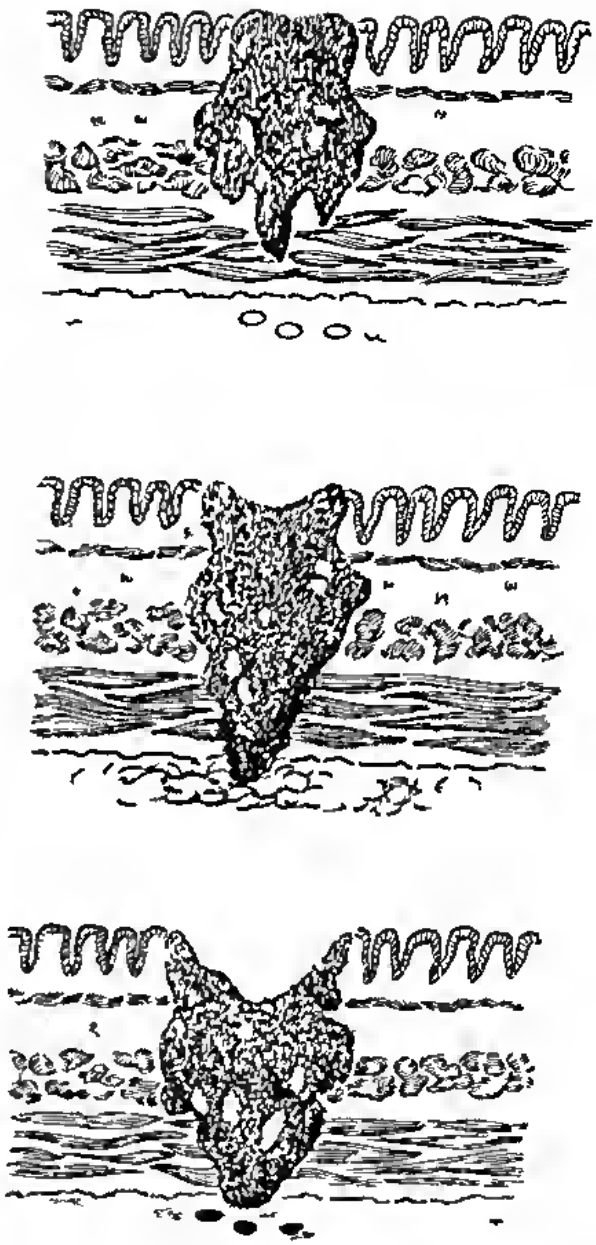

Fig 22 8 Dukes classification of cancer (*Top*) Tumor limited to rectum and its coats (*Center*) Extension into pericolic fat (*Bottom*) Lymph node metastasis

bulky masses of tumor fixed viscera present a formidable appearance in the pelvis at laparotomy lymph node metastasis often has not occurred and en masse resections are successful

### *Dukes' Classification of Cancer*

Dukes has classified rectal cancer into three stages (Fig 22 8) according to the extent of spread

Stage A Carcinoma is limited to the walls of the rectum There is no extension into extrarectal tissues and no metastasis to lymph nodes

Stage B Carcinoma extends into extra rectal tissues by direct continuity, but has not spread to the regional lymph nodes

Stage C Metastasis has extended to the regional lymph nodes

In a series of 215 patients operated upon for cancer of the rectum, Dukes found that 18 per cent could be classified as Stage A, 35 per cent as Stage B, and 47 per cent as Stage C

### *Lymphatic Spread of Carcinoma*

Carcinoma of the rectum invades the regional lymphatic structures and appears

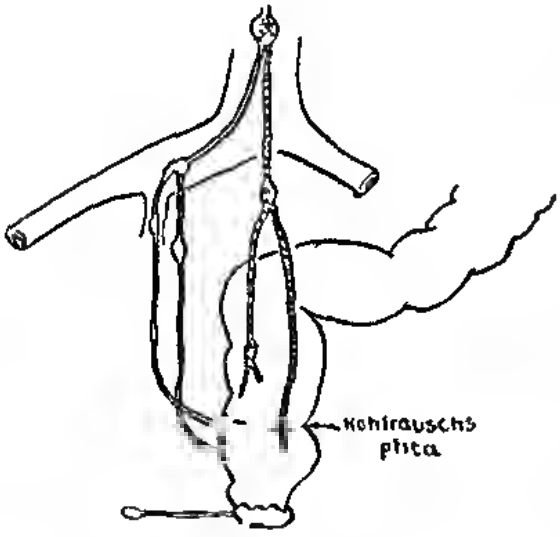


Fig 22 9 Lymphatic drainage of the rectum

as secondary growth in the regional lymph nodes in about half of the patients operated upon ( Table 22-4) The surgical treatment of cancer of the rectum was not based on accurate knowledge of this route of spread until 1904 when the work of Delamere, Poirier, and Cuneo on the lymphatics was published Further clarification of the lymphatic spread of cancer of the rectum is to be found in the classical works of Gilchrist and David, Coller, Kay and MacIntyre, and Glover and Waugh

The lymphatic drainage of the rectum parallels the arterial patterns (Fig 22 9), thus metastasis can occur upward into the inferior mesenteric lymphatics from a carcinoma at any level Metastasis downward (retrograde), however, is relatively rare and is noted particularly when the superior lymphatic routes are plugged with tumor Lateral (hypogastric) metastasis can occur from tumors located at or below the anterior peritoneal reflection of the rectum* (corresponding to the plica of Kohlrausch), but not from above this level as demonstrated by Sauer and Bacon, thus cancers located in the infraperitoneal portion of the rectum may metastasize laterally as well as upward We shall later see how this knowledge can be applied to the selection of an operative procedure for cancers at various levels in the rectum

### *Regional Lymph Nodes Draining the Rectum*

Regional lymph nodes lie along the course of the major vascular channels

* It is our contention, when viewing the ventral rectal wall in the pelvis from above during operations that the anterior rectal peritoneal reflection starts where the longitudinal muscle fibers begin to be obscured or covered by subperitoneal fat From here the peritoneum extends downward and ventrally to the cul-de sac of variable depth when it again extends upward to the bladder [male] or lower uterine segment If this anterior peritoneal reflection point is seen and tagged with silk prior to rectal excisions it will correspond to the level of the middle valve of Houston [plica of Kohlrausch] This valve is constant unless destroyed by disease If the rectum is removed the anus closed with a pursestring and the rectum filled with formalin the proximal end closed with a pursestring and the specimen left to float in a large jar of formalin so it will assume normal contour and is then opened longitudinally the following will be observed The middle valve of Houston and the tagged point of ventral peritoneal reflection will be at the same level The rectums of fifty male and female patients were examined in this manner No variation in level of more than 1 cm was demonstrated." Garnett W Ault M D Personal communication (Jan 26 1959) on unpublished work.

The surgical attack on cancer of the rectum is directed against removal not only of portions of the tumor laden viscus but also of as much of the surrounding tissues as possible, together with the tissues containing the highest, the lowest and the most lateral lymphatic nodes The primary direction of the lymph flow of the rectum is upward along the superior hemorrhoidal artery and the inferior mesenteric vessels posterior to the duodenum The lateral flow is through the anterolateral rectal ligaments containing the middle hemorrhoidal vessels into the lateral pelvic hypogastric areas The levator ani muscles are important only because direct extension of a low lying cancer may take place into them Although these muscles have lymphatic channels of their own the main collecting trunks of the rectum do not travel along with them

The terminal portion of the rectum is drained by lymphatic channels that pass to the inguinal region These channels communicate with those of the anal canal and follow the same distribution but metastasis to inguinal nodes is rare unless the anal canal is directly invaded by tumor

### *Carcinoma of the Rectum Spread by Venous Channels*

Carcinomas extending into the para rectal fat are backed by a rich network of vascular channels and often invade the veins Tumor emboli may then reach the liver through the portal venous system Highly malignant cancers are more likely to become angioinvasive than are those of low grade malignancy The frequency of vascular invasion has been determined by macroscopic and microscopic studies of the removed specimens and by a special radiographic technique In addition the portal venous blood returning from the cancer bearing segment of the colon to the liver has been examined for malignant cells These cells are demonstrable in about one third of patients undergoing operation for colorectal cancer In 1955 Fisher and Turnbull demonstrated neoplastic cells in the portal venous blood of 8 of 25 patients who had undergone operation Later one hundred consecutive patients were similarly examined for tumor cells in the portal venous blood before and after manipulation of the tumor bearing segment at the time of removal In the first 33 patients examined, the tumor bearing segment was mobilized and was resected with the usual amount of handling Ten were found to have neoplastic cells in the portal venous blood In the remaining 67 patients the bowel was divided above and below the tumor and the entire vascular pattern and mesentery were interrupted without direct manipulation of the tumor bearing segments Neoplastic cells were found in the venous blood of only ten patients These studies suggest the importance of interrupting the venous and arterial vascular patterns before

TABLE 22 4 RELATION OF AGE OF PATIENT TO INCIDENCE OF LYMPHATIC METASTASES*

| | *Males* | | | *Females* | | |
|---|---|---|---|---|---|---|
| *Age group* | *Number of patients* | *Number with metastases* | *Percentage with metastases* | *Number of patients* | *Number with metastases* | *Percentage with metastases* |
| Under 40 | 84 | 61 | 72 6 | 67 | 50 | 74 6 |
| 40–49 | 176 | 93 | 52 8 | 112 | 75 | 67 0 |
| 50–59 | 414 | 209 | 50 5 | 218 | 114 | 52 3 |
| 60–69 | 544 | 245 | 45 0 | 243 | 132 | 54 3 |
| 70 and over | 270 | 109 | 40 4 | 128 | 62 | 48 4 |
| Total | 1 488 | 717 | 48 2 | 768 | 433 | 56 4 |

* Republished through the courtesy of the Proceedings of the Royal Society of Medicine

attempting to mobilize the cancer bearing segment

Apparently the finding of malignant cells in the venous blood is not of absolute importance in prognosis, since undoubtedly exfoliation of neoplastic cells exists in more patients than those in whom it can be measured The present belief is that the host has a definite capacity for destruction of a given number of neoplastic cells, but when the capacity to destroy is exceeded, the growth of hepatic metastasis seems likely to occur Engell has reported long term survivals of patients with gastrointestinal malignancy in whom cancer cells were found in the venous blood He observed that neoplastic cells were as common in survivors as in nonsurvivors

*Peritoneal Extension of Carcinoma*

Carcinomas located on the anterior wall of the intrapelvic portion of the rectum occasionally extend to the peritoneal surface and seed on the peritoneum These neoplastic implants vary in macroscopic appearance, and are seen as tiny translucent plaques or excrescences or as hard white fibrous-appearing plaques A careful search of the omentum may reveal these implants within the folds Under these conditions resection may be inadvisable, at best the outlook is hopeless and anastomoses would soon be riddled with neoplastic tissue Invisible implants occasionally are on the ovary at the time of operation, and become cystic masses that may be so large that laparotomy is required for relief of symptoms For this reason, in menstruants, the ovaries should be removed at the same time that the cancer of the rectum or the colon is resected

## Signs and Symptoms of Cancer of the Rectum

The symptoms of cancer of the rectum depend upon its size and position in the rectum Those tumors located in the lower third of the rectum cause outlet symptoms such as false urge to deferate, frequent small movements, and discharge of blood and mucus If the sphincters are involved, there may be incontinence and pain Carcinomas located in the upper two thirds of the rectum are manifested by a change in bowel habit and rectal bleeding The change in bowel habit may suggest obstructive symptoms such as decrease in number or volume of movements accompanied by cramps, retention of gas, and abdominal distention The earliest symptom is a change in bowel habit with the passage of a small amount of blood Generally the blood is mixed with the stool, but with low lying tumors it may be discharged separately

BLEEDING Actual hemorrhage is uncommon with malignant tumors, but is more common with hemorrhoids, large benign polyps or diverticulosis A well established cancer of the rectum bleeds consistently with every bowel movement

Pain is an uncommon symptom of cancer of the rectum The mucosa of the rectum is insensitive However, a tumor that extends into the presacral fascia and is attended by inflammatory changes in that area may cause a dull postsacral pain Low lying cancers that invade the region of the dentate line and sphincters may cause pain during bowel movements or while sitting

## Diagnosis

Bleeding from the rectum is nature's "red flag" of warning, and along with any of the aforementioned signs and symptoms should be an indication for a specified order of rectal examinations external inspection digital examination, proctosigmoidoscopic examination Most cancers of the rectum can be felt with the fingers, those lying just beyond reach of the finger can be seen easily with the sigmoidoscope Roentgen examination of the rectum for cancer is inaccurate and should not be employed unless a proximal lesion is suspected

Digital examination is best carried out with the patient in the left lateral position and using the index finger of the

examiner's right hand Most tumors of the middle and the lower third of the rectum can be palpated As previously stated, certain palpable masses are easily confused with cancer of the rectum a large, irregular, hard cervix in the female atypical carcinoma of the prostate with tumor embracement of the lower rectum in the male, malignant deposits in the rectovesical pouch or the cul-de-sac, and extrarectal stenosing metastasis from scirrhous carcinoma of the stomach The absence of blood on the examining finger may be evidence that a tumor mass is covered with mucosa and does not originate in the rectum

*Sigmoidoscopy* is absolutely necessary for accurate diagnosis The head down position of the patient on a tilt table is ideal Water suction, a biopsy forceps, and a coagulating diathermy unit should be available Enema preparation is undesirable since the finding of blood or bloody stool suggests the presence of a bleeding lesion located above the rectum

removal of the rectum Moreover, attempts have been made to remove the rectum for carcinoma of the prostate, Blumer's shelf, and other hopelessly incurable metastatic deposits mentioned previously Carcinomas are fragile, and portions for study are easily obtained and with characteristically little bleeding The hardest part of the tumor should be removed for histologic evaluation since some carcinomas are marginated by soft benign papillomatous tumor

### *Differential Diagnosis*

Some tumors arising in the rectum or within the walls of the rectum or from adjacent organs may be mistaken for primary carcinoma Below are listed neoplastic or inflammatory tumors simulating cancer of the rectum Column A gives the statistically most important tumors, Columns B and C are included for the sake of completeness The importance of study of biopsy material cannot be overstressed

| *A Tumors outside the rectum* | *B Tumors arising within the rectal walls* | *C Inflammatory or other tumors* |
|---|---|---|
| Carcinoma of the prostate | Lymphoid polyp | Oleoma |
| Blumer s shelf | Carcinoid tumor | Lipogranuloma |
| Endometriosis | Lymphosarcoma | Ameboma |
| Pelvic lymphosarcoma | Varicosities | Tuberculoma |
| Metastatic scirrhous carcinoma of the stomach | Leiomyosarcoma | Actinomycosis |
| | Malignant melanoma | Syphilis |

Symptomatic patients who object to the pain of proctosigmoidoscopic examination should be examined under anesthesia

*Barium enema* study should not be attempted in patients with cancer of the rectum if there is any suggestion of obstruction The diagnosis is easily made without it Although additional lesions in the colon may be palpated at the time of operation, a good roentgen study of the colon, when possible, is even more informative

*Biopsy should be performed on every patient with a rectal tumor* The histologic report should always be available before surgery is undertaken Failure to follow this rule has led to the unnecessary

Carcinoma of the prostate, secondary malignant deposits in the rectovesical pouch or cul de sac (Blumer's shelf), and endometriosis occasionally are confused with primary carcinoma of the rectum. Atypical *carcinoma of the prostate* may embrace the rectum in the form of a hard collar, and in some instances may even produce obstruction The mucosa of the rectum is not involved, but it may be edematous and may have a papillary appearance owing to submucosal infiltration Diagnosis is made after histologic study of sections of tissue obtained with the Vim Silverman needle

*Metastatic scirrhous carcinoma of the stomach* occasionally spreads by way of the

properitoneal lymphatic channels to grow profusely in the extrarectal tissues so as to produce a cuff stricture of the rectum within an inch or two of the anus Obstruction may supervene After digital examination the examining finger is not covered with blood the patient does not have rectal bleeding as there is no mucosal lesion Endoscopic examination will reveal the area of stricture to be covered by mucosa that may be edematous because of infiltration Diagnosis is made after histologic study of sections of tissue obtained with the Vim Silverman needle Roentgen studies of the stomach reveal the primary lesion

ENDOMETRIOSIS Deposits of endometrial tissue may grow not only in the cul de sac but also may invade the rectovaginal septum and produce hard fixed nodular masses that on palpation resemble carcinoma Rarely invasion of the mucosa of the rectum on the anterior wall results in bleeding from the rectum during menstrual periods

*Pelvic lymphosarcoma* arising in the lateral hypogastric regions of the pelvis may form unilateral nodular masses easily palpable through the rectum Often there is edema of the corresponding leg or thigh There is little confusion with primary carcinoma of the rectum

*Lymphoid polyp* (benign lymphoid tumor) of the rectum is an aggregate of hypertrophied lymphoid follicles located in the submucosa It projects into the rectum from under the mucosa and is firm and pale 1 cm or less in diameter, and often is found at the time of routine examination Microscopically the lymphoid polyp resembles a lymph node and germinal centers are present however the characteristic sinusoids of the lymph node are absent Usually the overlying mucosa is intact In general they behave in a benign fashion and do not produce symptoms Diagnosis is established by the study of biopsy specimens the lesion may be treated by minimal coagulation

*Carcinoid tumor* (argentaffinoma) of the rectum is rare It arises from the Kultschitsky cells of the tubular glands and must be differentiated from carcinoma because of the treatment Usually carcinoid tumors of the rectum are firm yellow polyps of 1 cm or less in diameter and produce no symptoms Carcinoid tumors must be considered as malignant because they invade locally and sometimes metastasize In principle treatment should be directed toward the ablation of a small locally invasive lesion that seldom metastasizes Electrocoagulation of the tumor and the immediate area in which it grows is sufficient therapy Local surgical excision may be inadequate and may result in local recurrence and metastasis

Large carcinoid tumors of the lower rectum are treated by the abdominoperineal resection of the rectum and establishment of a permanent colostomy Studies of urine for the determination of the degradation product of serotonin (5 hydroxyindoleacetic acid) might be of value preoperatively as an aid to detect metastasis

Diffuse submucosal *lymphosarcoma* of the rectum may mimic carcinoma of the rectum There is bleeding loss of weight anemia and diarrhea Endoscopic examination reveals a markedly rugose and convoluted indurated bleeding mucosa simulating carcinoma of the diffuse type or the rectum may be studded with lymphosarcomatous nodules The diagnosis is established by adequate biopsy and histopathologic study

*Varicosities* of the rectum are encountered rarely The rugose bleeding mucosa may mimic primary carcinoma of the rectum Varicosities may be secondary to extrahepatic or intrahepatic block in the portal venous system or may exist simply as diffuse cavernous hemangiomas Diagnosis is made by proctoscopic examination where one can easily see and compress the large tortuous veins under the mucosa The rectal roentgenograms suggest advanced diffuse deforming inflammatory disease However scattered phleboliths that often are present in the veins may reveal the true diagnosis. Un

fortunately, plain films of the rectum are not often made, and the barium enema may obscure the phleboliths A rectal hemangioma that appeared to be a tumor of the rectum and was thought to be inoperable was reported by Hellstrom, Hultborn, and Engstedt

*Leiomyosarcoma* of the rectum is rare Tumors of 1 cm or less may be locally excised, but larger tumors arising from the muscularis of the rectal wall have a poor prognosis and often metastasize to the lungs

*Malignant melanoma* of the anus is rare About 100 cases have been published since the report by Moore in 1857, thought to be the first Malignant melanomas arising in the mucosa above the dentate line are extremely rare, and are to be differentiated from cancer of the rectum by study of biopsy material Delaney, Scudamore, and Waugh postulated that any malignant melanoma that occurs on the mucosal surface either represents an extension from a primary tumor at the dentate line or arises from cell rests that are pulled up a few centimeters from the proctoderm at the time of fusion with the hindgut An important distinction is that these primary rectal lesions do not appear to contain pigment whereas the metastatic lesions often will be heavily pigmented The prognosis with malignant melanoma of the rectum is grave The tumor follows the same pattern of metastasis as that noted when melanomas occur in other parts of the body Pack, Gerber, and Scharnagel reported that 19 of their patients having melanoma of the rectum lived five years after diagnosis Delaney, Scudamore, and Waugh reported that 5 of the 10 patients reported previously from the Mayo Clinic died from metastasis in seven months or less after diagnosis

*Squamous cell carcinoma* arising from the mucosa of the rectum is an oddity The diagnosis is established by study of biopsy material Dixon, Dockerty, and Powelson reported a pea sized squamous-cell carcinoma that arose from the mucosa of the midrectum He excised the rectum and found a lymph node with metastasis in the pararectal fat just outside of the muscularis and about 5 cm above the dentate line There is no satisfactory explanation for the occurrence of a squamous cell cancer in the mucosa of the rectum

*Submucosal oleoma* of the rectum may be observed after the injection of oil soluble anesthetics It is pale yellow, has a smooth surface, and when incised an oily substance drains freely from it Biopsy and histologic study reveal characteristic oil granuloma

*Spontaneous lipogranuloma* of the rectum is rare, but it may be confused clinically with primary carcinoma The mucosa is thrown up into deeply rugose, bright red folds and occasionally is ulcerated There are few symptoms The examiner characteristically believes the lesion to be an atypical carcinoma and repeated biopsies are usually made Histologically there is a diffuse granulomatous response in the submucosa with suppuration, and presence of numerous multinucleated giant cells surrounding fat droplets The etiopathogenesis of spontaneous lipogranuloma is not known In the several cases that we have observed, removal of the overlying mucosa has resulted in the eventual healing

*Tuberculosis* of the rectum is becoming rare Usually it takes the form of complicated fistulous disease The diagnosis is made by repeated stained smears and positive findings of tuberculosis on roentgenograms of the chest Although study of biopsy material and smears of pus from the fistulas are of value, the diagnosis cannot be proved unless the acid fast organisms are seen in section Occasionally the patient s response to an antituberculosis medical regimen is the only clue as to the diagnosis After prolonged medical treatment, surgical treatment of residual fistulas is satisfactory

*Actinomycosis* of the rectum is extremely rare Cope and associates reported only six cases in which the disease

was thought to be primary In four of the patients the actinomycotic masses were excised because they were thought to be malignant tumors This highlights the importance of a differential diagnosis that rules cancer in or out In the fifth patient, a huge tumor was thought to be an inoperable malignant mass Cope and associates considered the condition a diagnostic puzzle, primarily because it was discovered late in its course, and secondary infection tended to mask the actinomyces Chronic inflammatory tissue easily simulates malignant disease clinically Many cultures, sections, and smears are necessary to discover the invading organism. According to Cope and associates, the signs consisted of pus and mucus in the stools, and alternating constipation and diarrhea The only certain positive diagnosis can be made by finding the organism or "sulfur granules" in the pus Fortunately, actinomycosis is sensitive to massive and prolonged penicillin therapy

RADIATION ULCER The intrauterine insertion of radium for certain cancers of the cervix may cause actinic damage to the rectal mucosa The patient seeks treatment because of severe diarrhea, rectal bleeding, and intense and relentless pain The onset of symptoms may be from three weeks to 18 months after therapy Increasingly severe, deep pelvic pain may herald the appearance of a rectovaginal fistula The radiation ulcer (opposite the cervix on the anterior rectal wall) is recognized by the characteristic yellow or white slough seen in its base, and by the excessive bleeding that results from the slightest trauma to the area during examination Medical treatment comprises the administration orally of insoluble sulfa drugs, and locally, hot-oil retention enemas and nocturnal retention enemas of solutions (or suppositories) containing hydrocortisone acetate Should perforation (rectovaginal fistula) occur, a diverting sigmoid colostomy must be made Following colostomy, healing of small rectovaginal fistulas may be slow, over a year or longer The surgical closure of a rectovaginal fistula is not often successful, but in recent years "pull through" operations to remove the damaged rectum have been done

*Amebomas (amebic granulomas)* of the rectum are extremely rare Amebic ulceration resulting in localized and suppurative tumors of the rectum are mentioned here only for completeness of the record An inflammatory mass of the rectum simulating carcinoma should be investigated by study of biopsy material and spreads, for the presence of *Endamoeba histolytica* if the diagnosis is not otherwise definitive

*Syphilitic lesions* of the rectum are also rare Syphilitic "tumors" have been noted twice at the Cleveland Clinic in the last 28 years In one patient (1930) a gumma of the rectum was treated by abdominoperineal resection at a penal institution hospital The other patient was admitted with a large papillary tumor of the rectal ampulla The biopsy specimen was reported as chronic inflammatory tissue, and the patient was hospitalized with intent to repeat the biopsy, however, within three days a secondary syphilid appeared and appropriate treatment was instituted

## Treatment

The radical removal of the rectum or portions of the rectum is today the accepted treatment for most malignant tumors of that organ Under certain conditions of age and infirmity, rectal cancer may be treated by surgical diathermy and radon seed implantation The success of the treatment of any disease is measured ideally by a comparison of the results in treated and untreated patients We do not yet know the natural history of the disease or the fate of any large number of untreated patients with cancer of the rectum In 1936, Daland, Welch, and Nathanson compared findings in 100 patients with untreated cancer of the rectum to those in 42 patients who had undergone radical operation Statistically the groups were not comparable, but in the untreated group the median length

of life after diagnosis was 14 months, in the surgically treated group the median length of life from treatment to death was 27 months Both groups necessarily represented a high degree of selection which influenced the survival rates but the comparison is encouraging to the surgeon undertaking this type of procedure

Prior to 1900, removal of the rectum for cancer was accomplished through the perineum There was little thought of the upward or lateral spread of neoplastic cells, and great importance was placed upon preserving the sphincters The many variations in technique were dictated by the manner in which the coccyx or portions of the sacrum were removed Often colostomy was made in the perineum or in the area of the resected sacrum

In 1908, Miles of London reported a combined abdominal and perineal method for excision of the rectum At first the mortality associated with this procedure was formidable, but Miles and later Gabriel improved the technique to a point where the surgical mortality was equal to that for other methods and the procedure became the operation of choice

In the United States the abdominoperineal operation of Miles was performed by Jones, who, by his perserverance and skill, demonstrated its superiority and safety The survival rates following this operation were so markedly improved that the Miles operation became a standard operation for cancer of the rectum and little thought was given to alternate procedures In 1908, however Archibald demonstrator in anatomy and assistant surgeon at the Royal Victoria Hospital in Montreal, had already begun to consider the possibility of saving the lower rectal segment in patients in whom the carcinoma was located above the ampulla He was strongly opposed to colostomy in such cases and stated To sacrifice deliberately in every case all hope of the natural evacuation of the bowels will always seem to most of us a sad confession of failure nay more, a distinct step backward" In 1932 Babcock of Philadelphia devised a method of proctosigmoidectomy without colostomy, and described his experiences with the operation The classical studies on lymphatic spread of carcinoma of the rectum between 1938 and 1946, encouraged further attempts at restoration of intestinal continuity following resections of the upper portions of the rectum for cancer To Babcock and Bacon go the credit for persistence in performing sphincter saving operations during the years when the Miles operation was considered to be the procedure of choice for cancer of the rectum Since 1940 there has been such increasingly satisfactory experience with these alternative procedures that they have at last found their rightful place

Experienced intestinal surgeons may now choose one of four operative procedures for the surgical treatment of cancer of the rectum

1 Miles abdominoperineal resection with permanent colostomy
2 Abdominoperineal resection with posterior pull through anastomosis and preservation of the sphincters or the terminal rectum
3 Anterior resection of the rectum without anastomosis (extended Hartmann operation)
4 Anterior (abdominal) resection of the rectum with low colorectal anastomosi

The choice of operation depends primarily on the distance of the cancer above the anus but limiting factors are the size and the mobility of the tumor, and the patient s age and body build

The four operative procedures have been evolved to remove adequately the cancer bearing rectal segment and most of the sigmoid colon with its mesentery

*The objectives of the Miles operation* are well known The rectum and its sphincters are totally removed by a combined abdominoperineal operation A permanent colostomy is established

*Pull through operations* are performed as a combined abdominal and perineal operation The objective is to remove all or nearly all the rectum and to avoid a colostomy The name is derived from the perineal phase wherein the tumor bearing rectum and sigmoid colon are "pulled through" the sphincters

We have classified pull-through operations as type I and II, depending on whether or not all the rectum is removed The type I operation results in total rectal excision with coloanal (mucosa to-skin) anastomosis The type II operation consists of resection of all but 1 or 2 cm of the rectum, allowing colorectal (mucosa to mucosa) anastomosis just above the dentate line The anastomosis is made posteriorly after pulling the colon through the intact, everted terminal rectal segment The retention of a narrow strip of rectum in type II results in normal or nearly normal rectal continence, which cannot be expected in type I because of the removal of the lower mucosal lined rectum with its intact neurologic components

*Anterior resection of the rectum without anastomosis* results in total removal of the rectum through an abdominal incision, a colostomy is established. The indication will be discussed subsequently The procedure might be referred to as an extended Hartmann operation

*Anterior resection of the rectum with colorectal anastomosis* is accomplished through an abdominal (anterior) incision Colorectal anastomosis is completed with whatever portion of distal rectum remains following resection Colostomy is avoided

As an aid to choosing the optimal operative procedures for cancers of the rectum located at various levels, Waugh and Turner have conveniently divided the rectum into three segments of 5 or 6 cm each, beginning at the dentate line (Table 22-5)

*The lower 5 or 6 cm* of the rectum is infraperitoneal It is limited below by the dentate line and above by the middle valve of Houston (plica of Kohlrausch) which has been demonstrated by Ault* to be at approximately the same level as

* See footnote, page 614

TABLE 22 5 RECTAL CANCER LIMITING FACTORS IN CHOICE OF OPERATION

| *Site of tumor (cm above dentate line)* | *Anatomic landmarks* | *Direction of lymphatic flow* | *Operation to consider* |
|---|---|---|---|
| Lower third (0 5 cm ) | *Proctologic* below middle valve<br>*Abdominal* below peritoneal reflection* | Upward, lateral rarely downward | Miles abdominoperineal resection with colostomy |
| Middle third (5 10 cm ) | *Proctologic* above middle valve<br>*Abdominal* above peritoneal reflection | Upward rarely downward No lateral spread | (1) Abdominoperineal proctosigmoidectomy with pull-through technique<br>(2) Anterior proctosigmoidectomy with colostomy (extended Hartmann operation) |
| Upper third (10 15 cm ) | *Proctologic* Well above middle valve | Upward rarely downward | Anterior resection of rectum and sigmoid colon with colorectal anastomosis |

* See footnote, page 614

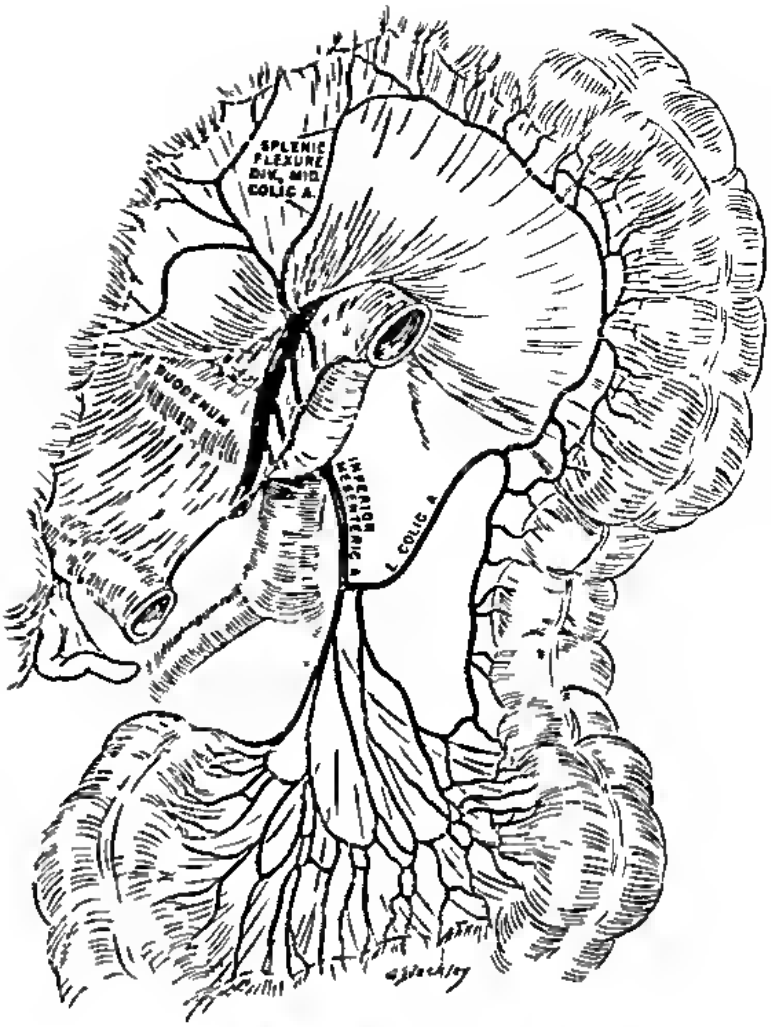


Fig 22-10 The arterial vascular pattern of the left hemicolon

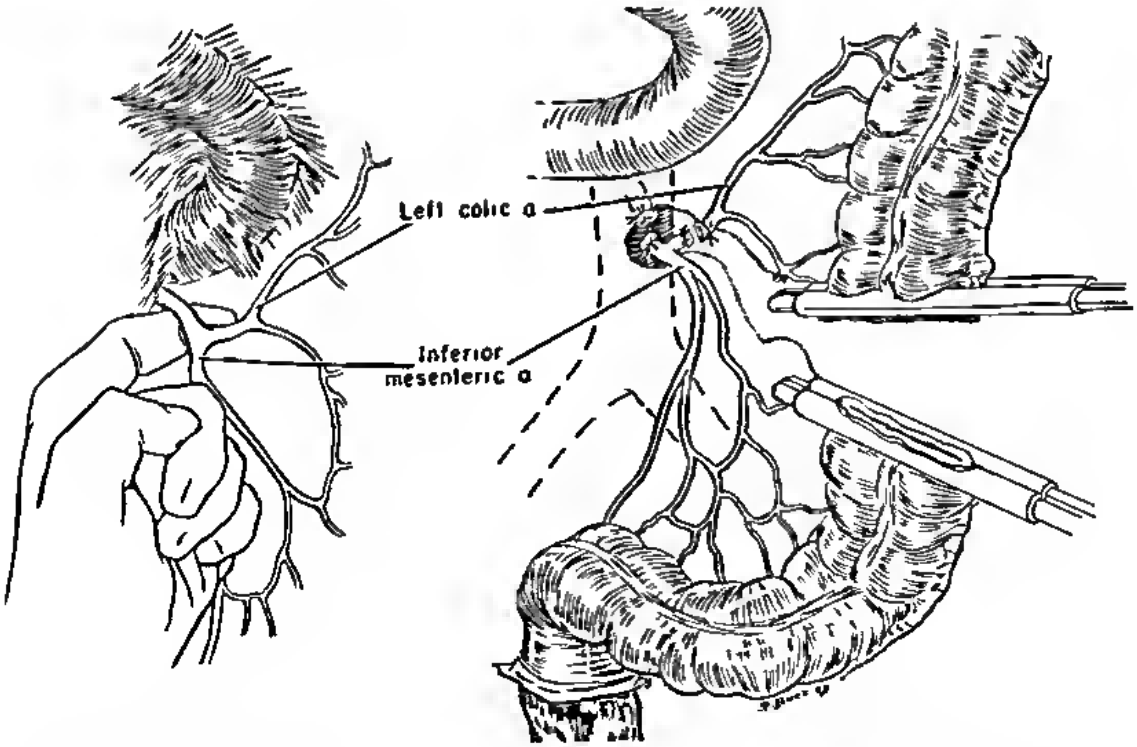


Fig 22-11 The inferior mesenteric artery is isolated beneath the duodenum and ligated at the origin from the aorta

*Pull-through operations* are performed as a combined abdominal and perineal operation The objective is to remove all or nearly all the rectum and to avoid a colostomy The name is derived from the perineal phase wherein the tumor bearing rectum and sigmoid colon are 'pulled through' the sphincters

We have classified pull through operations as type I and II, depending on whether or not all the rectum is removed The type I operation results in total rectal excision with coloanal (mucosa to skin) anastomosis The type II operation consists of resection of all but 1 or 2 cm of the rectum, allowing colorectal (mucosa to mucosa) anastomosis just above the dentate line The anastomosis is made posteriorly after pulling the colon through the intact, everted terminal rectal segment The retention of a narrow strip of rectum in type II results in normal or nearly normal rectal continence, which cannot be expected in type I because of the removal of the lower mucosal lined rectum with its intact neurologic components

*Anterior resection of the rectum without anastomosis* results in total removal of the rectum through an abdominal incision, a colostomy is established The indication will be discussed subsequently The procedure might be referred to as an extended Hartmann operation

*Anterior resection of the rectum with colorectal anastomosis* is accomplished through an abdominal (anterior) incision Colorectal anastomosis is completed with whatever portion of distal rectum remains following resection Colostomy is avoided

As an aid to choosing the optimal operative procedures for cancers of the rectum located at various levels, Waugh and Turner have conveniently divided the rectum into three segments of 5 or 6 cm each, beginning at the dentate line (Table 22-5)

*The lower 5 or 6 cm* of the rectum is infraperitoneal It is limited below by the dentate line and above by the middle valve of Houston (plica of Kohlrausch) which has been demonstrated by Ault* to be at approximately the same level as

* See footnote page 614

TABLE 22 5 RECTAL CANCER LIMITING FACTORS IN CHOICE OF OPERATION

| *Site of tumor (cm above dentate line)* | *Anatomic landmarks* | *Direction of lymphatic flow* | *Operation to consider* |
|---|---|---|---|
| Lower third (0–5 cm ) | *Proctologic* below middle valve<br>*Abdominal* below peritoneal reflection* | Upward, lateral, rarely downward | Miles abdominoperineal resection with colostomy |
| Middle third (5 10 cm ) | *Proctologic* above middle valve<br>*Abdominal* above peritoneal reflection | Upward rarely downward No lateral spread | (1) Abdominoperineal procto sigmoidectomy with pull through technique<br>(2) Anterior proctosigmoidectomy with colostomy (extended Hartmann operation) |
| Upper third (10–15 cm ) | *Proctologic* Well above middle valve | Upward rarely downward | Anterior resection of rectum and sigmoid colon with colorectal anastomosis |

* See footnote, page 614

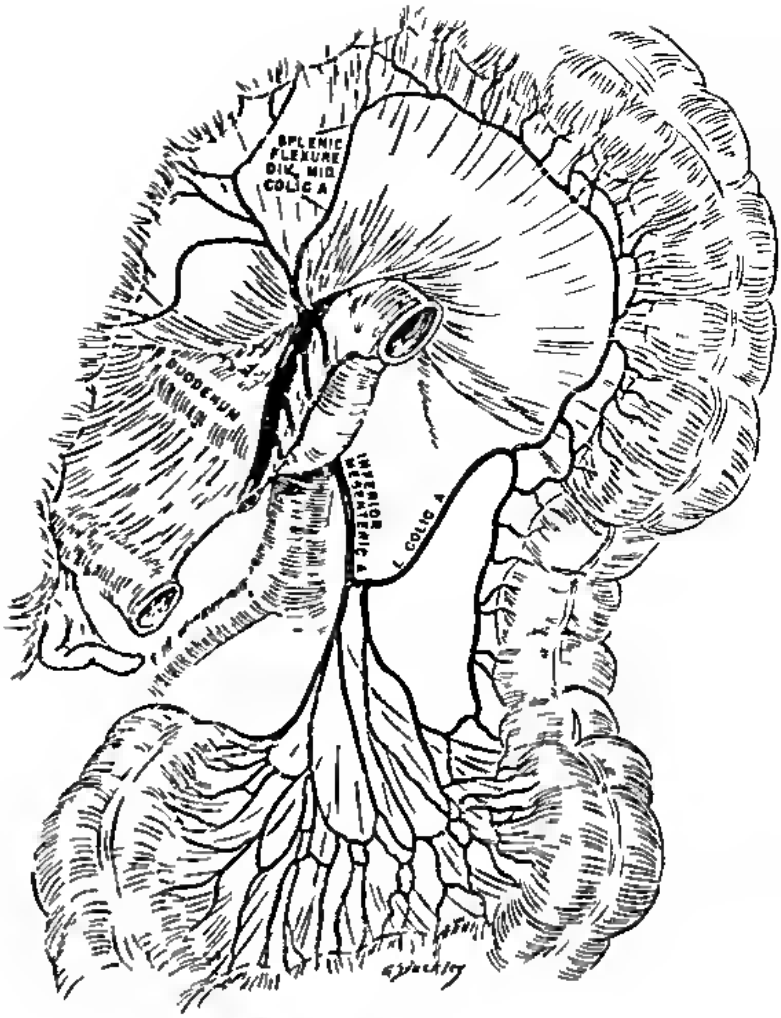


Fig 22-10 The arterial vascular pattern of the left hemicolon

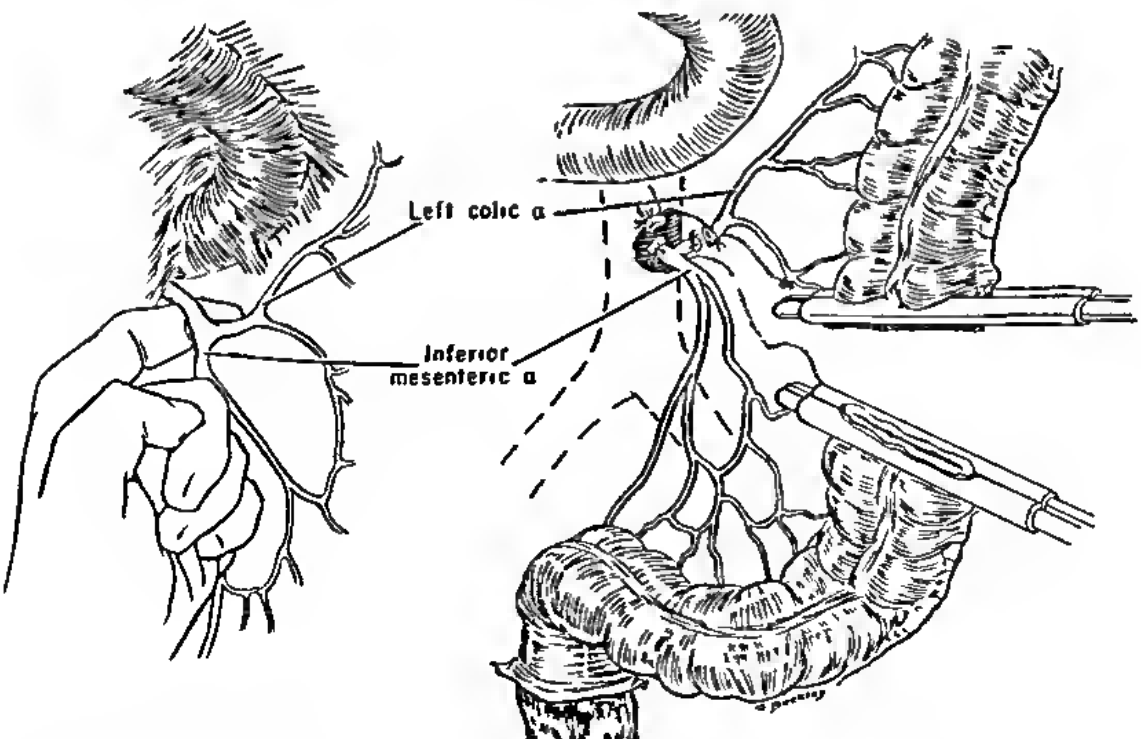


Fig 22-11 The inferior mesenteric artery is isolated beneath the duodenum and ligated at the origin from the aorta

the anterior peritoneal reflection of the rectum With these two definite anatomic landmarks there is no difficulty in accurately locating a neoplasm within the lower third of the rectum The Miles combined operation is the procedure of choice because of the proximity of the

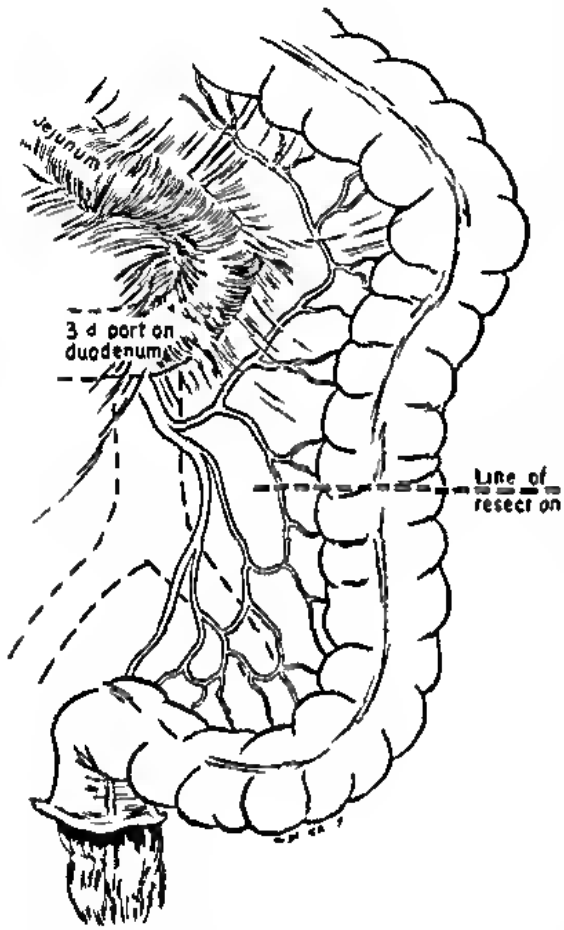


Fig 22 12 The point of division of the colon for all carcinomas of the rectum located at any level

tumor to the levator muscles, the ischiorectal fat, and anus The route of lymphatic spread of this segment is lateral as well as upward Downward (distal) spread is rare

*The middle third* of the rectum is bounded below by its own anterior peritoneal reflection and extends 5 to 6 cm above this level The route of metastasis from this segment is upward but not lateral Downward metastasis is rare Freely movable carcinomas located within this segment may be dealt with by either type of pull through procedure, or by anterior resection of the rectum without anastomosis

*The upper 5 to 6 cm* of the rectum is located well within the pelvis and there is ample rectum below to allow adequate anterior resection for most cancers in this segment Colorectal anastomosis is usually possible

## Surgical Technique

### *Modified Miles Abdominoperineal Resection*

ABDOMINAL PHASE The abdomen is opened through a left paramedian incision extending from the pubis to the mid epigastrium The left rectus muscle is retracted laterally The abdomen and the intraperitoneal portion of the rectum are thoroughly explored to determine the type of operative procedure indicated and a careful search is made for metastasis The sigmoid colon is freed from its lateral peritoneal attachments in the region of the left common iliac vessels the spermatic or ovarian vessels and the ureter are observed in turn, bringing the left common iliac vein into view The vein is followed to the bifurcation of the aorta (Fig 22 10), thence along the anterior surface of the aorta to the third portion of the duodenum, there the finger is thrust anteriorly through the peritoneum into the abdominal cavity on the right side of the pedicle containing the inferior mesenteric artery and vein The artery is divided and is ligated above the origin of the left colic artery, which in turn is divided proximally to its primary division point (Fig 22 11) The nearby colic mesentery containing the marginal artery (descending left colic branch) is divided at the sigmoid-descending colon junction which in turn is divided over a Cope De Martel clamp (Fig 22 12), thus the main arterial profusion and the primary and collateral venous drainage of the upper half of the rectum and the

sigmoid colon are interrupted prior to initiating the pelvic phase of the operation

PELVIC PHASE By drawing the uterus or the bladder in the male forward with a bent ribbon retractor, definite peritoneal folds can be seen leading from the sacral promontory forward to the depths of the cul-de sac, or of the rectovesical pouch in the male The peritoneum over these folds is opened on each side of the sacral promontory (Fig 22 13), and long handled blunt tipped curved Miles scissors are inserted and are thrust distally under the folds thus freeing and excluding the ureter laterally from the peritoneum on both sides The peritoneum is then incised over the folds each incision being carried down toward the cervix or the depths of the rectovesical pouch

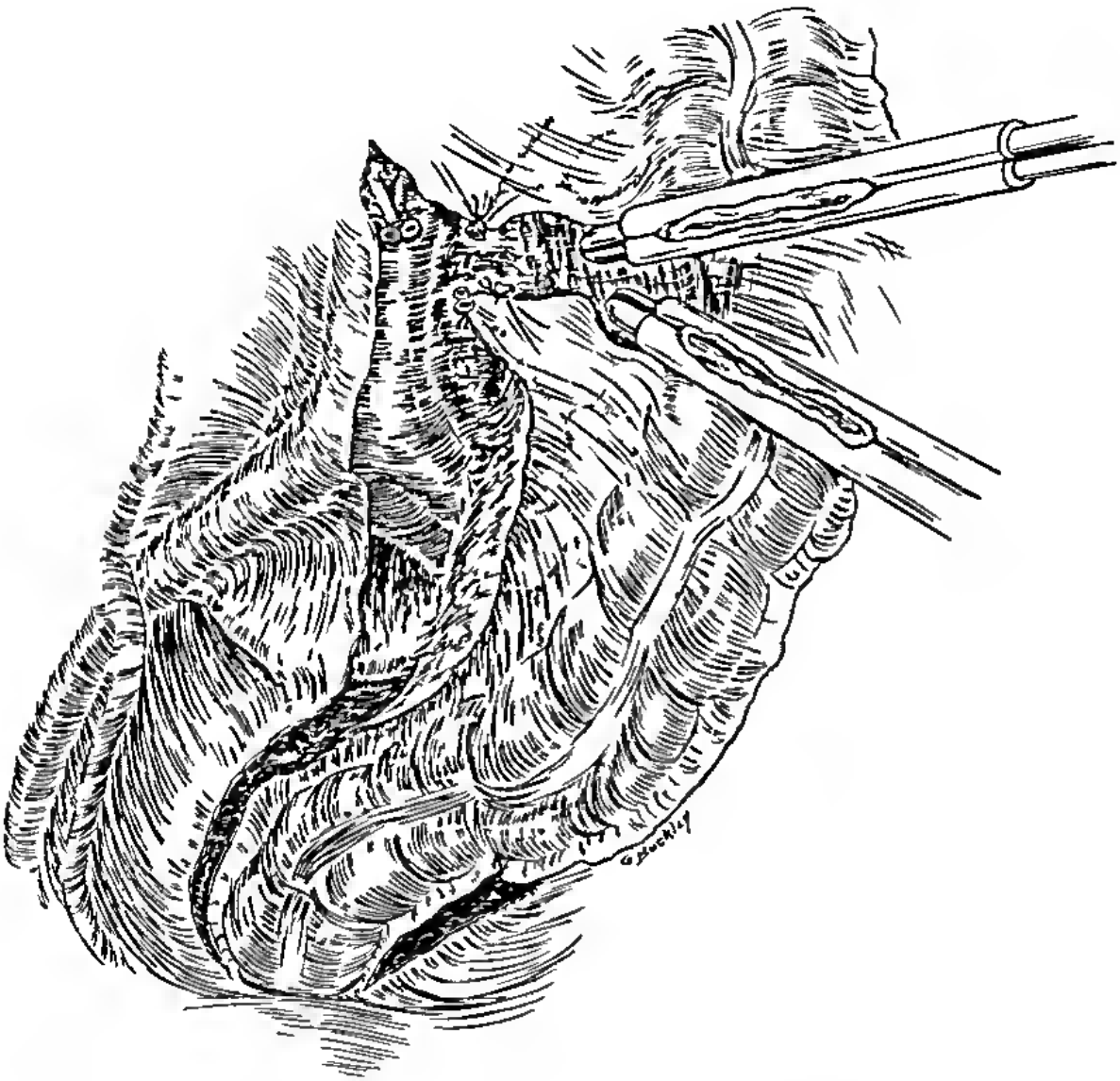

Fig 22 13 Incision of the peritoneum in the pelvic phase of an abdominoperineal resection

The presacral mobilization of the rectum is begun first by entering the presacral space below the promontory of the sacrum and just medial to the left com

mon iliac vein (Fig 22 14) Care is taken to find the space anterior to Waldeyer s fascia (presacral endopelvic fascia) because it is an avascular plane The rectum is gently freed from the presacral space as far as the tip of the coccyx

By sweeping upward and then medially on either side of the rectum with the fingers (Fig 22 15), fat and lymph nodes are cleared from the lateral hypogastric veins until the rectal stalks are encountered in the anterolateral position With the cul de sac or the rectovesical pouch now elevated, it is an easy matter to incise the peritoneum across the depths of the sac or pouch while *remaining close to the rectum* When Pean clamps and traction are applied to the rectal cuff of incised peritoneum, the rolled over border of the vaginal fornix is easily brought into

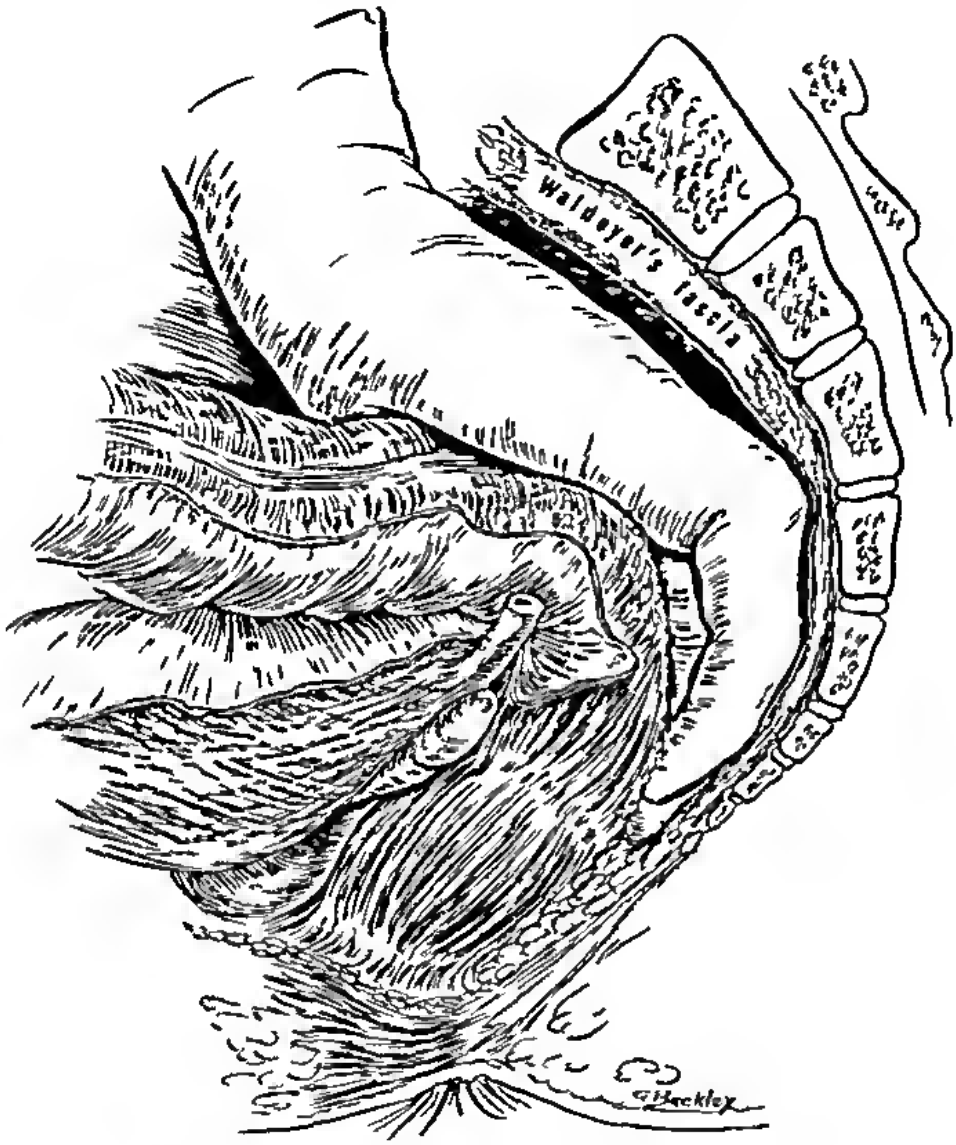


Fig 22 14 Separation of the rectum from the presacrum in the avascular plane anterior to Waldeyer s fascia

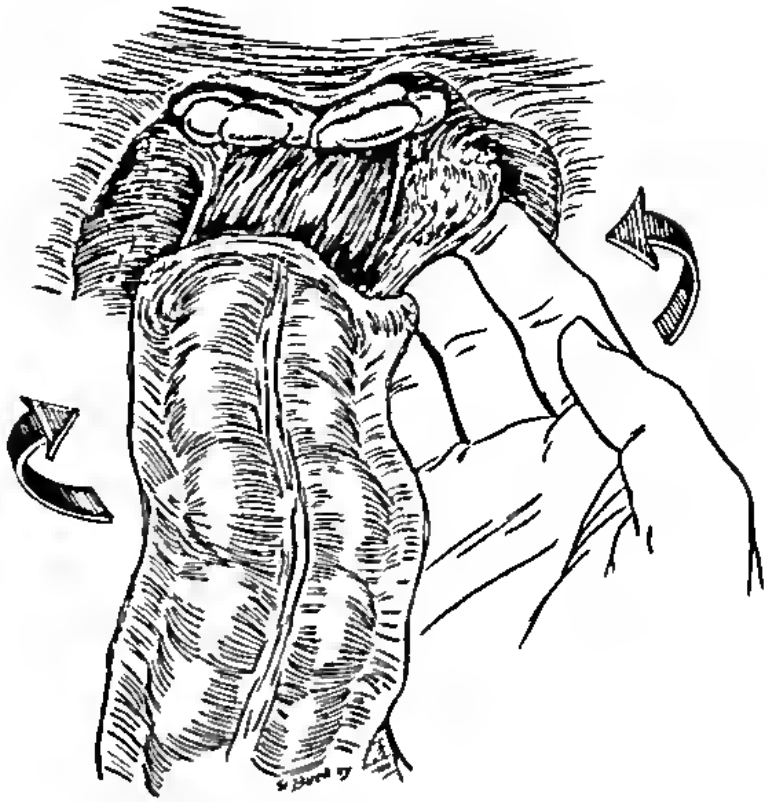

Fig 22 15 The hypogastric fat is swept from the lateral pelvic wall with the finger

view and the dissection between the vagina and the rectum is carried down as far as possible In the male, similar traction on the rectal peritoneal cuff brings the upper borders of the seminal vesicles into view (Fig 22 16) When they are held forward individually with bent ribbon retractors, the rectum is easily dissected free of the bladder neck and down to the apex of the prostate anteriorly The now well defined anterolateral rectal stalks may be divided as far laterally as practicable Serious arterial bleeding is rare except when the hypogastric artery is inadvertently opened Ligation of the middle hemorrhoidal vessels is seldom necessary A few remaining bands of tissue between the rectum and the levator muscles are divided If the rectocolonic segment is not too bulky it may be tucked into the presacral space and the pelvic peritoneum may be reconstructed over it Should the space not accommodate the distal segment, peritonization may be simply omitted and, following the perineal removal of the rectum, a Mikulicz

Fig 22 16 Exposure of the seminal vesicles by traction upon the peritoneal reflection of the rectum

pack (withdrawn gradually over a period of seven days) is placed in the pelvic outlet

The colostomy is now made by drawing the clamped end of the descending colon out through the left rectus muscle just below the umbilicus (Fig 22-17)

*The perineal phase* is carried out in a safe position While lithotomy or left lateral position is less disturbing to cardiopulmonary function, we prefer the inverted Kraske position for low-lying infiltrating lesions but recognize the dangers in the elderly or obese patient

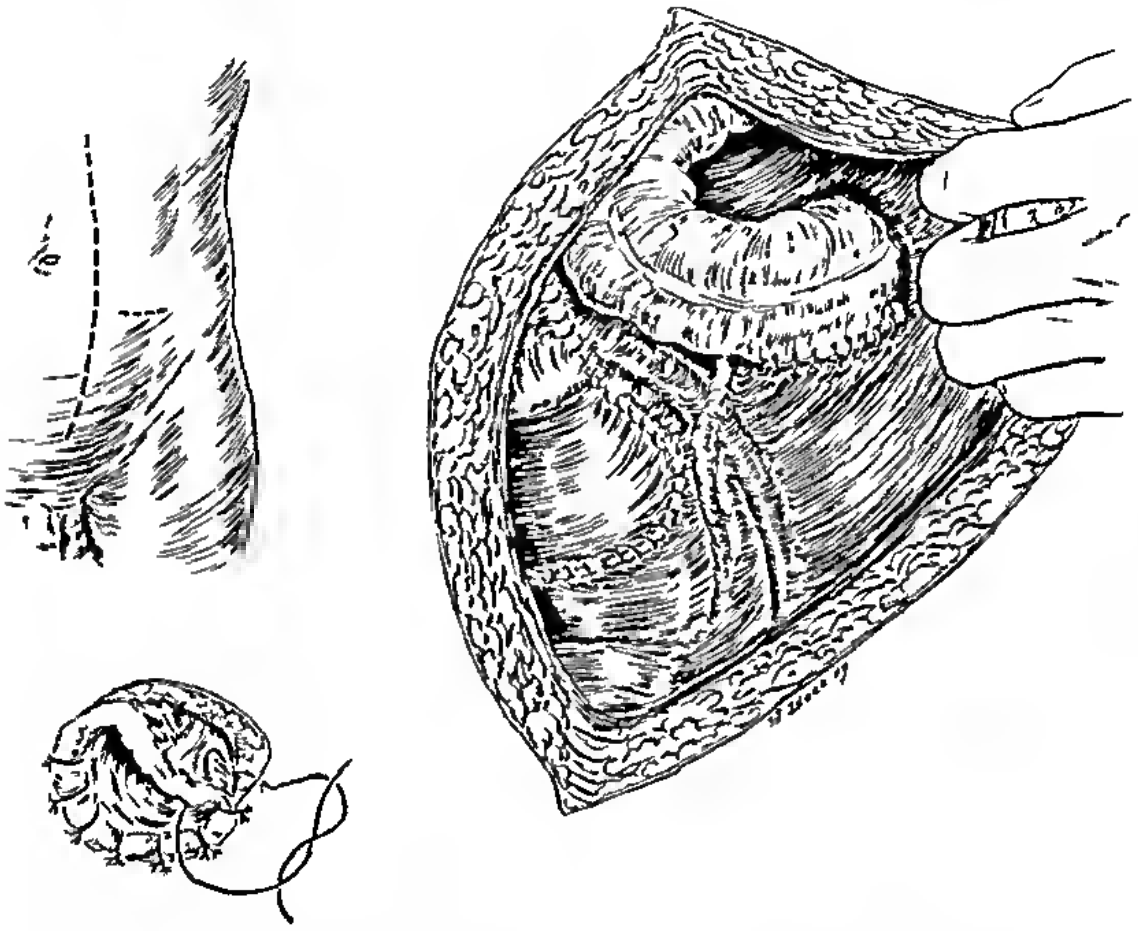

Fig 22 17 A left rectus colostomy is placed through a short transverse skin incision The lateral gutter is closed with interrupted sutures and the pelvic floor is peritonized The open end of the colostomy is approximated to the skin with interrupted catgut sutures

The hiatus between the left parietal peritoneum and the mesentery of the colostomy is closed with silk sutures The omentum is pulled down and the abdomen is closed through all layers (excluding skin and subcutaneous fat) with No 30 gauge steel wire on round needles (Fig 22-18) The colostomy is opened and immediately is fixed to the skin with interrupted chromic catgut sutures

Wide excision of ischiorectal fat and levator muscles is essential when the tumor is at the level of the sphincter If oozing from the posterior vaginal or the periprostatic veins is minimal, the posterior wound is closed by approximating the subcutaneous fat with interrupted chromic sutures, leaving a French No 18 catheter in the presacral space for irrigation with penicillin solution The skin is

approximated with fine chromic catgut sutures An alternate method is to insert a baseball-sized pack of gauze stripping covered with rubber tissue into the posterior wound Closure of the perineal wound is effected around the neck of the pack

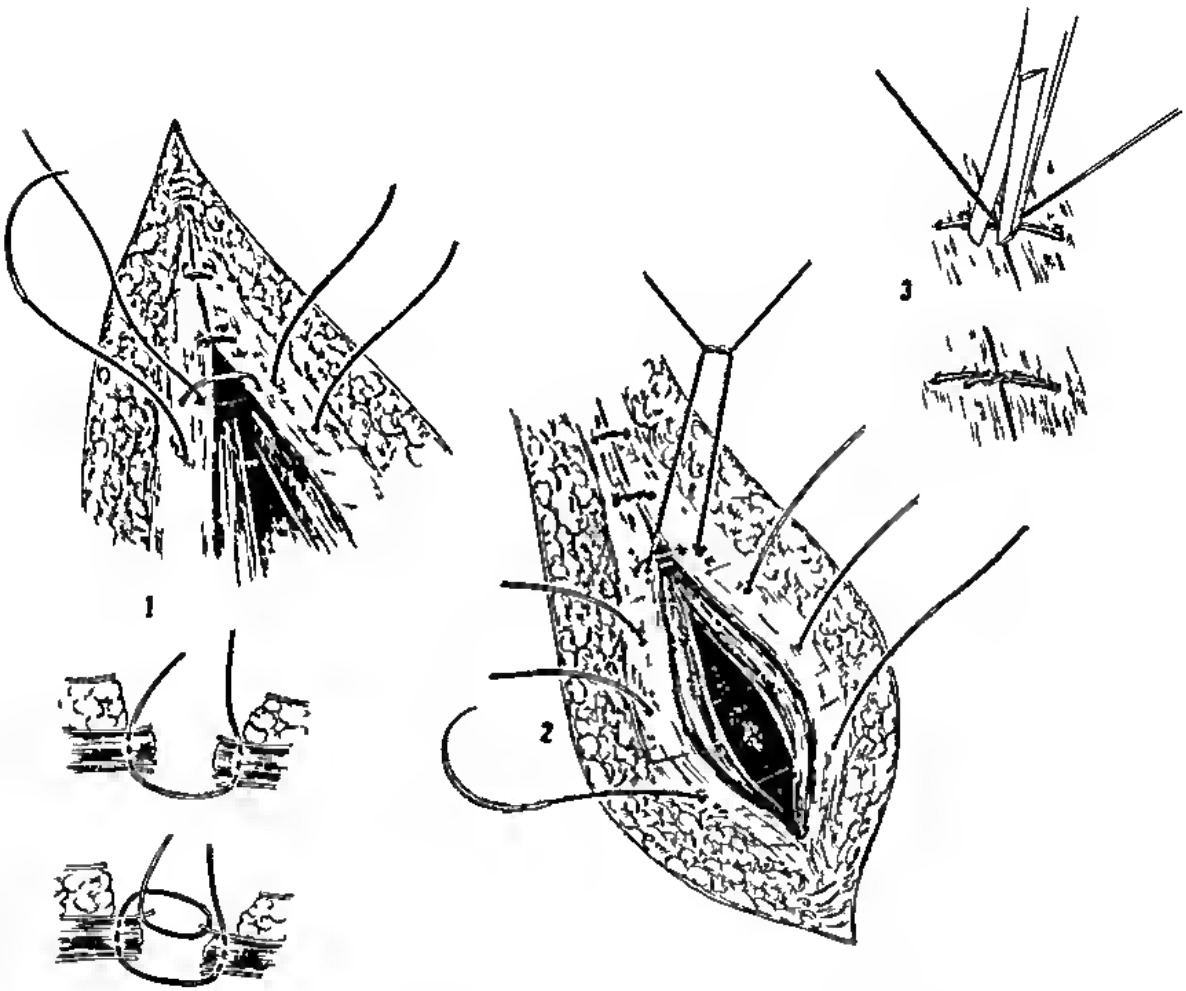


Fig 22 18 The abdominal wall is closed with figure-of eight stainless steel alloy wire sutures that go through fascia, muscle, and peritoneum

which is removed on the fourth postoperative day

### *Pull-Through Operations*

ABDOMINAL AND PELVIC PHASES After the abdomen has been opened for a pull-through procedure, the abdominal and pelvic phases are accomplished in the same manner as for the Miles operation with the following exceptions (1) Instead of dividing the bowel at the sigmoid descending colon junction it is ligated and occluded with double black-silk, (2) The pelvic dissection is carried down distally to where the rectum can easily be seen traversing the levator muscles Anteriorly, the vagina must be freed to the introitus, or to the apex of the prostate in the male, (3) A heavy double ligature is tied around the rectum *below* the neoplasm, (4) After division of the inferior mesenteric artery and the left colic artery and inferior mesenteric vein under the duodenum, the descending colon is mobilized and its mesentery is freed from the left kidney to the ligament of Treitz The splenocolic omentum is divided, the lesser omental

sac is entered, and the splenic flexure and its mesentery are mobilized to the pancreas The gastrocolic omentum is divided midway to the pyloris to free the transverse colon If the left colon still cannot be pulled down as far as the upper thigh, the splenic flexure division of the mid colic artery may be sectioned close to the pancreas, thus liberating it still further

Since the descending colon and splenic flexure ultimately are to be pulled down through the pelvis, the adequacy of the arterial blood flow in the mesentery of the descending colon above the silk ligature is determined by cutting small marginal vessels near the ligature Only a forceful thrust of blood can be accepted as an adequate flow (Note The sigmoid colon and its complex system of blood vessels are to be sacrificed )

PERINEAL PHASE The patient is now placed in the lithotomy position (the abdomen remains open but covered) The anus is dilated so that three fingers can be inserted, and the lower ampulla is irrigated with saline solution and tincture of benzalkonium chloride (Zephiran) (The silk ligature previously placed below the neoplasm prevents contamination with fragments of tumor ) Either type I or type II pull through operation can be carried out

| *Historical eponym* | *Basic objective* | *Fecal continence* |
|---|---|---|
| Type I | | |
| Hochenegg | To remove entire rectum, to establish coloanal anastomosis, to preserve sphincters | Not true continence, colon continence possible |
| Babcock, Bacon | | |
| Waugh Miller, and Kurzweg | | |
| Type II | | |
| Maunsell, Weir, Swenson and Bill, Black | To retain portion of rectum, to establish colorectal anastomosis | Complete to partial rectal continence preserved |

*Type I* (Fig 22-19 ) Three Adair clamps are placed to evert the anal canal A circular incision is made through the dentate line until the rectum is severed at this level The mucosa is picked up with hemostats, and by finger dissection the rectum is freed from the levator sling The rectum and colon are then pulled through the anal canal and the sphincters until the silk ligature around the descending colon is encountered Immediate coloanal anastomosis can be made, or a cuff of the colon may be left protruding until the tenth day, at which time it is dissected free and trimmed and coloanal anastomosis is made with interrupted catgut sutures Closure of the abdomen is effected as described below under type II There is some tendency of this anastomosis to stricture Therefore, from the end of the second postoperative week, a finger should be inserted once daily for three months

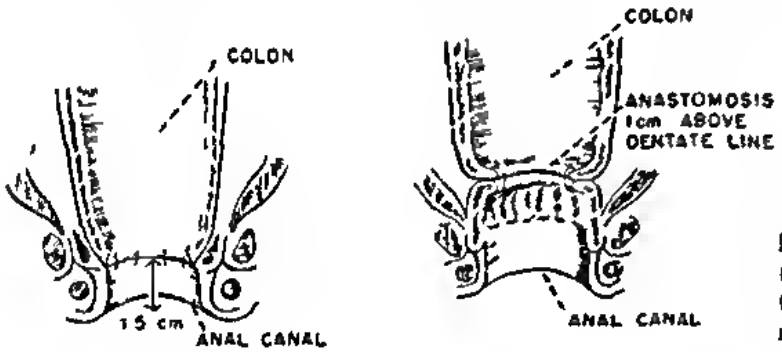


Fig 22 19 Diagrammatic illustration of Type I coloanal (*left*) and Type II colorectal (*right*) pull through anastomoses

*Type II* (Fig 22-20, Lithotomy posi

tion ) After the anus is dilated, the rectal mucosa is grasped with Adair clamps and the rectum is evaginated several centimeters The rectum is then severed completely 1 or 2 cm proximal to the dentate

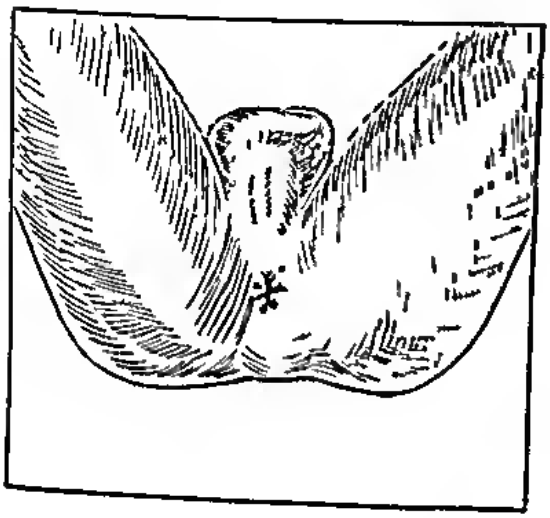

Fig 22 20 When a pull through operation is contemplated the perineal phase of a Type II can be initiated by exposure and transection of the rectum (*dotted line*) proximal to the dentate line By division through the dentate line a Type I procedure can be done

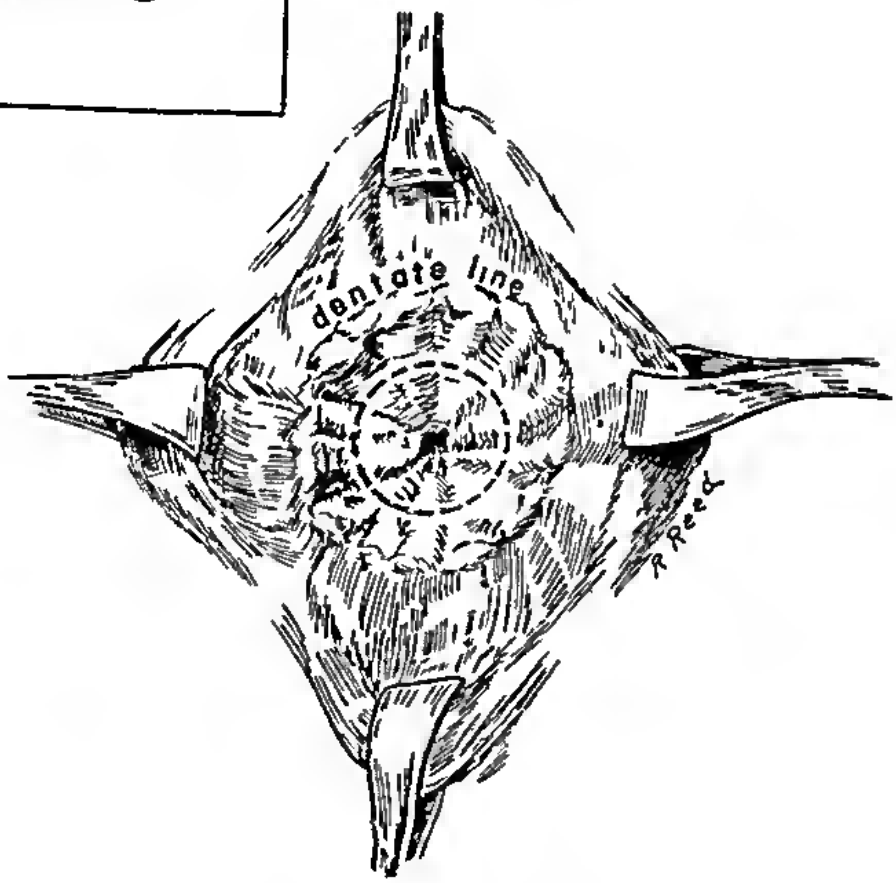


(mucocutaneous) line, and the rectocolonic segment is gently pulled through the residual lower rectal segment The occluding silk suture around the descending colon again marks the site of resection and colorectal (mucosa to-mucosa) anastomosis is carried out utilizing a one-layer or two-layer anastomosis with interrupted catgut (through all layers) and silk (seromuscular) sutures (Fig 22 21) The completed anastomosis is then pushed back into the pelvis through the sphincters, and the patient is returned to the supine position and the abdomen uncovered

The pelvis is lavaged and blood clots are removed The left lateral extremity of the greater omentum is trimmed away from the displaced splenic flexure (it may become necrotic), the tied inferior mesenteric vascular pedicles are covered with

peritoneum, but the pelvis is not reperitonized, so that accumulated blood may drain back into the peritoneal cavity rather than form an abscess under a reconstructed peritoneal floor No pelvic or sump drains are used A temporary skin level loop transverse colostomy often is used with type II pull-through technique, and is closed on the tenth postoperative day

The abdominal and pelvic phases are carried out as in the Miles operation A double silk ligature is then placed around the rectum below the tumor and the lower ampulla is flushed thoroughly with saline solution and tincture of benzalkonium chloride through an inlying rectal tube The abdominal operator grasps the rectum below the tumor, and steady traction is exerted The anus is thus drawn up between the Levator muscles and is cut across with scissors Minimal bleeding from the anal cuff is controlled by thrusting a folded laparotomy pad down between the levators This pad is withdrawn through the anus on the third postoperative day, and the presacral space is irrigated daily with 1 per cent neomycin solution On the ninth or tenth postoperative day, the space is aspirated of blood clots through a short, sterile rectoscope

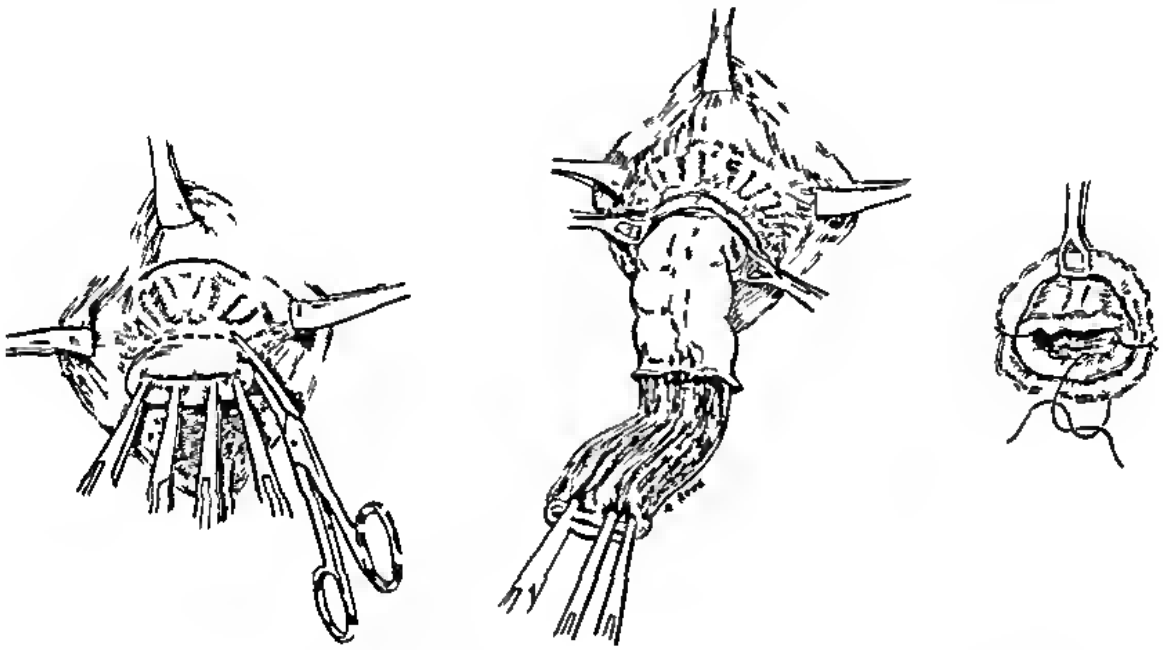

Fig 22 21 Pull through operation Type II (*Left*) Method of eversion and transection of the rectum Dentate line is indicated by arrow (*Center*) Pull through of rectocolic segment (*Right*) Colorectal anastomosis

### *Anterior Abdominal Resection of the Rectum without Anastomosis (Extended Hartmann Operation)*

Anterior (abdominal) removal of the rectum and the sigmoid colon is the preferred procedure for cancer of the midrectum, when the factors of obesity, old age, pelvic deformity, or infirmity make a pull through procedure hazardous or impossible Hartmann has described anterior resection of the rectum with closure of the distal end and the establishment of a permanent colic stoma The "extended" Hartmann operation results in the abdominal removal of all the rectum to the anal sphincters. A colostomy is established

### *Anterior Abdominal Resection of the Rectum with Anastomosis*

Abdominal resection of the rectum with colorectal anastomosis is an adequate

operation for most carcinomas located in the upper third of the rectum thus the lower border of the lesion should be from 3 to 5 cm above the anterior peritoneal reflection of the rectum In thin patients low resection and anastomosis can be accomplished for lesions located at or near the peritoneal reflection, but the principles of cancer surgery are easily compromised For such lesions the previously described pull through II operation with posterior anastomosis is a more radical procedure and is preferred to an inadequate anterior resection

TECHNIQUE The abdominal and pelvic phases are similar to those in the Miles procedure

The inferior mesenteric and left colic vessels are divided under the third portion of the duodenum and the left colon is transected over a Bainbridge clamp just below the junction of the sigmoid and the descending portion To obtain mobility it may be necessary to free the descending colon and splenic flexure and their mesenteries medially from the left kidney The rectum is lavaged with 100 ml of tincture of benzalkonium chloride injected into the colon above the carcinoma while an indwelling rectal tube drains away the solution below A heavy, double black silk ligature is tied around the rectum below the carcinoma to occlude the lumen

The posterior mesentery of the distal rectum is cut transversely two inches or more below the tumor until the muscularis is seen Bleeding vessels in the distal rectal fat are then ligated The rectum is then severed, the distal end being supported by guy sutures at the lateral angles The rectal stump will be found empty because of the inlying tube below The end of the descending colon is closed after making sure it will lie in the pelvis without tension An opening is made on the antimesenteric border to equal that of the open rectum (Fig 22 22), and anastomosis with interrupted catgut sutures through all layers is made Interrupted seromuscular sutures are placed anteriorly and finally posteriorly by turning the anastomosis around in the depths of the pelvis The tied stumps of the inferior mesenteric vessels are covered with peritoneum but the pelvis is never peritonized for reasons stated previously The cecum and terminal ileum are returned to the pelvis first followed by the rest of the small intestine The abdomen is closed No drains are placed in the pelvis

POSTOPERATIVE CARE Nasogastric suction is maintained for several days to prevent distention of the intestine with fluid or gas A French No 16 Foley catheter is placed in the bladder at the start of

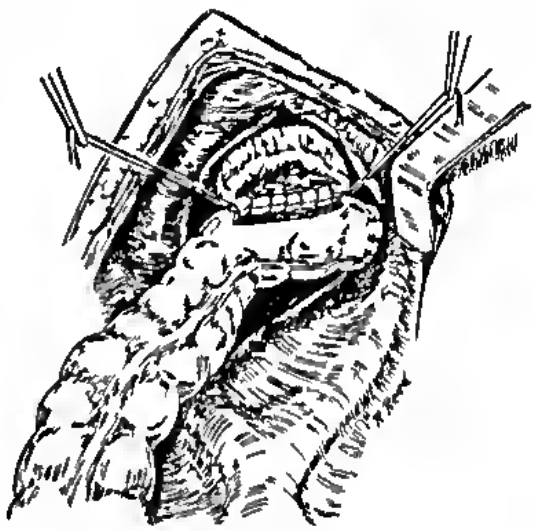

Fig 22 22 Low anterior colorectal anastomosis side to end technique of Baker

the operation and is not removed until the patient is ambulatory

FEEDING The patient is encouraged to eat whenever he wishes but will not eat substantially until the fourth or fifth postoperative day Fruit juices are banned because they cause intestinal cramps

MEDICATION Penicillin is given postoperatively, while chloramphenicol (Chloromycetin) is used as an alternate The objective is to discourage bacterial growth at the site of the open anastomosis or in the blood clot that may accumulate in the pelvis Drugs to prevent or to ameliorate urinary tract infections are administered orally on the fifth postoperative day *Enemas* are avoided until ten days or more after operation However,

they are particularly useful in some patients who have undergone low anterior resection of the rectum Although the anastomotic area is widely patent, it is fixed and inert, causing formed feces to accumulate above it and drop through the anastomosis in small amounts In this manner the sensitive ampullary remnant is stimulated to empty repeatedly A small daily enema will cleanse the segment above the anastomosis Belladonna and opium suppositories placed in the ampulla desensitize it and reduce the number of small movements or pressure sensations that follow movements The bowel habits of patients undergoing rectal resection are deeply disturbed, but almost always revert to the original pattern This holds true for any of the surgical procedures described

COLOSTOMY CARE Since colostomy is the result of an amputation, social and physical rehabilitation are carried out while the patient is in the hospital Colostomy enemas every other day aid in the establishment of "colonic control of bowel movement The use of a simple colostomy irrigating apparatus and repeated 'on the spot' irrigation instruction by a permanently employed aide (also an intestinal amputee) do much to restore the patient to a useful status

## Postoperative Complications

*Urinary tract problems* of some degree are observed in more than half the male patients, and are primarily due to an alteration in the anatomy of the pelvis through a displacement of the organs In the male, the entire prostatic urethra drops back with the bladder from the fixed point of the perineal membrane, and the natural urethral curves are lost Hypertrophy of the prostate, which is often present, adds to the difficulties Total mobilization of the rectum results in damage to the pelvic nerves with a temporary loss of detrusor power The relative painlessness of the overdistended postoperative bladder is convincing evidence that nerve injury has occurred Postoperatively, in males, we prefer to place an indwelling French No 16 Foley catheter for nine or ten days By then, the patient is in the upright position most of the time and the bladder will empty Further intermittent catheterization may be necessary until the residual urinary volume is less than 100 ml If retention persists beyond two more weeks, transurethral resection may have to be performed Persistent retention is always a trial to the patient, who wonders if he will ever void again The tendency is to expect too rapid a recovery Prolonged use of an indwelling catheter usually results in recovery of function In one patient, a suprapubic catheter was maintained for a year before micturition was resumed (Transurethral resection was done )

*Cystitis and pyelonephritis* are to be expected in patients who are catheterized repeatedly or who have an indwelling catheter We are convinced by our own experience that prophylactic drugs are of value in ameliorating or preventing infection Gantrisin is administered on the fifth postoperative day and is continued daily for three weeks Should cystitis or pyelonephritis then occur, Chloromycetin is administered in therapeutic dosage, and cultures of urine and sensitivity tests are made for future reference These two drugs are effective for 80 per cent of the infections, however, the onset of pyelonephritis owing to the organisms such as *Proteus vulgaris*, the *Streptococcus fecalis*, or *Pseudomonas aeruginosa*, may necessitate the use of other antibiotic drugs or combinations of drugs

*Urethral and ureteral fistulas* fortunately are rare, and have been observed infrequently in recent years They result from direct surgical trauma or from packing the pelvis or posterior wound too tightly, with subsequent pressure necrosis of the ureter The fistula may appear late in convalescence A constant flow of urine from the posterior wound localizes the injury to the bladder or lower ureter, while a gush of urine on voiding represents urethral injury Nephrectomy most often is the

only possible treatment for ureteral fistula, because of multiple abscesses in the parenchyma of the corresponding kidney Prolonged use of an indwelling catheter or surgical intervention may be required for bladder or urethral injury

## Postoperative Ileus or Obstruction

It is our practice to continue nasogastric suction through the first or second postoperative day and then to remove the tube, and to limit the fluid intake in the ensuing 24 hours Patients who are distended and who fail to evacuate gas by the end of the fourth postoperative day are considered to have some degree of obstruction rather than adynamic ileus Flat and upright and lateral decubitus roentgen films of the abdomen are made to determine the approximate location of the obstruction The policy is to continue nasogastric suction rather than to introduce long intestinal tubes Fluids and electrolytes are replaced as indicated There is spontaneous resolution of obstruction in most instances, however, if abdominal pain or cramps are severe secondary laparotomy is carried out The decision to reoperate upon a patient for postoperative obstruction must be individualized In general, one may safely observe "painless" obstruction over a considerable period of time

The etiology of postoperative obstruction in surgery of the colon and rectum is interesting The small intestine becomes adherent to the cut edge of the mesentery, to the ligated stumps of vascular pedicles, and to the undersurface of the abdominal incision The open peritonized pelvis and denuded parietes are seldom the cause As to prevention, it is important to close any mesenteric hiatus, particularly that between a colostomy and the left abdominal parietes in the Miles operation In addition, tied vascular stumps are trimmed short and peritonized

Late intestinal obstruction is dealt with by laparotomy, it is due to fixation of a loop of intestine at some point or volvulus around a fixed point Fixation by recurrent neoplasm is taken into consideration when obstruction is noted two years or more after operation for cancer

*Delayed perineal wound healing* occasionally occurs after removal of the rectum for cancer or inflammatory disease Primary closure of the wound will obviate this difficulty, however, it may not be desirable to close the perineal wound in all patients A "bottle" abscess must be prevented by maintaining an adequate skin opening The wound aperture is dilated daily with a sterile swab so that the presacral cavity will become obliterated from above downward Wound care of this type is carried on by some member of the family at home A persistent sinus usually will close after a vigorous curettage under light anesthesia Should this method fail, local chemical stimulation by nitrogen mustard is helpful, if good mechanical drainage has been provided Ten milligrams of nitrogen mustard is dissolved in 10 cc of water, a gauze strip saturated with this solution is packed into the sinus and is removed the following day The skin of the perineum is first thoroughly saturated with castor oil to prevent local necrosis One or two treatments at two week intervals are remarkably effective

## Postoperative Wound Complications

*Wound dehiscence* is infrequent when closure of the abdomen is effected with interrupted steel alloy wire sutures that embrace the muscles, fascia, and peritoneum Stay sutures are not used since the "far and near" figure of eight placement of interrupted steel wires is in reality a buried stay suture

*Colostomy complications* can be avoided by the method of construction shown Necrosis of the stoma, and retraction and skin strictures are now rare Colostomy is placed through the rectus muscle just below and to the left of the umbilicus Most of the sigmoid colon is removed in the Miles operation so that the colostomy segment is directly perfused by the descending branch of the left colic artery

Colonic tension is intolerable, the descending colon must be sufficiently mobilized to rise in a gentle curve to traverse the abdominal wall The left gutter is obliterated to prevent volvulus, and colocutaneous anastomosis is completed after the abdomen is closed The resultant primary union between the colon and skin prevents prolonged fecal contamination of the pericolostomic subcutaneous fat, which so frequently produces stricture

Retraction of the colostomy occurs when peristalsis cannot push a bolus of feces through the aperture of the abdominal wall (Fig 22 23) No method of surgical fixation of the colon or colostomy has prevented retraction under these circumstances Evacuation of the colon prior to operation is an ideal precaution but is not always possible when there is long standing obstruction.

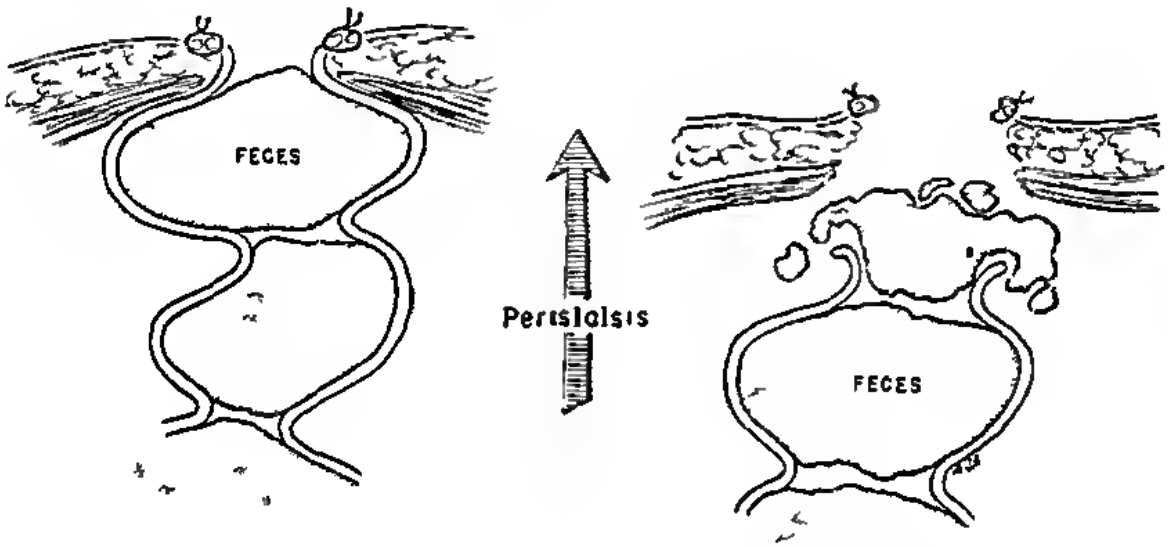


Fig 22 23 The cause of retraction of a colostomy from an impacted bolus of feces

*Wound infections* in intestinal surgery are uncommon because of preventive measures The preparation of the bowel for surgery with low residue diet insoluble antibiotics cathartics, and chemical enemas reduces organic intestinal contents to an absolute minimum Impermeable (through and through) wound drapes prevent intestinal contents from coming into contact with the exposed fat of the abdominal wall Occlusive clamps or tapes placed around the bowel proximal to a site of anastomosis prevent spillage of contents

The prevention of wound infection depends upon the technique of the individual surgeon We are certain that the following measures are important avoid trauma to the wound during the operation and closure, approximate the wound without tension, use monofilament steel alloy sutures, absolutely control wound bleeding, and lavage the wound with saline constantly during closure

*Contaminated wounds* should not be closed primarily When fecal contamination has occurred deep closure is effected with buried steel wire, but the skin and subcutaneous fat should be approximated loosely and gauze wicks should be inserted at intervals Compartmental drainage of the wound is thus provided for four days by gradual withdrawal of the wicks

Attempts to evacuate the colon preoperatively often are unsuccessful The surgeon who finds himself in this predicament at operation may (1) construct a transverse colostomy and close the abdomen or (2) proceed with the Miles operation and construct the colostomy

through an aperture in the abdominal wall made to equal the greatest diameter of the impacted colon Colocutaneous anastomosis is made and cleansing enemas are begun within a few hours after surgery

The employment of a stomal therapist as a full-time member of our team has done much to soften the psychologic blow of colostomy Hospital instruction in care and irrigation of the colostomy has rapidly restored the patients' confidence and ability to return to work The avoidance of colostomy by selecting alternate procedures has also been of utmost importance in reducing morbidity

## Results

The five-year survival rates (Table 22 6) for patients undergoing the Miles operation for cancer of the rectum are remarkably unchanged in the past 20 years Of patients subjected to operation for cure, about 54 per cent remain alive and well at the end of that time Similar survival rates are reported for pull-through operations for carcinomas located 5 cm or more above the dentate line Our own survival rates for carcinomas of the rectum treated by pull through operations and anterior resection have not been determined in the past five years, however, because of selection, they should be somewhat higher than our rate of survival after the Miles operation

TABLE 22 6 FIVE YEAR POSTOPERATIVE SURVIVAL RATES AFTER SURGICAL TREATMENT OF RECTAL CANCER AT ST MARK'S HOSPITAL, 1928–1952*
(All Operable Cases—3 373)

| *Period* | *Crude five year survival rate, %* | *Corrected five-year survival rate %* |
|---|---|---|
| 1928 32 | 49 3 | 56 5 |
| 1933–37 | 46 2 | 54 5 |
| 1938–42 | 46 8 | 54 9 |
| 1943–47 | 53 7 | 63 9 |
| 1948–52 | 46 2 | 56 1 |
| 1928 52 | 48 3 | 57 4 |

* Republished through the courtesy of the Proceedings of the Royal Society of Medicine

## TUMORS OF THE ANUS AND THE ANAL CANAL

Tumors of the anus and of the anal canal require highly specialized treatment They arise from the squamous anal epithelium and differ in many respects from cancers of the rectum, which arise from the mucosa just above the epithelium Cancers originating in the anal skin comprise about 3 per cent of all cancers of the rectum, they may be listed in two groups according to relative infrequency

*Group A Infrequent Tumors*

1 Anal epithelioma (epidermoid carcinoma)
2 Basal cell carcinoma of anus
3 Carcinoma in situ of anal skin

*Group B Rare Tumors*

1 Extramammary (anal) Paget's disease (intra epithelial carcinoma)
2 Papillary squamous cell carcinoma
3 Malignant melanoma
4 Mucinous adenocarcinoma in anal fistula

*Anal epithelioma* is a squamous cell carcinoma arising from the stratified squamous epithelium of the anal canal, or from the perianal skin The neoplasm that arises in the canal or on the anal margin often is deeply invasive, and may have metastasized by the time that it is discovered Metastasis takes place upward along the perirectal lymphatic channels to the pelvic hypogastric nodes and to the inferior mesenteric lymphatic nodes, also to one or both inguinal areas The tumor may penetrate deeply the perirectal fat or the anal muscles, and cause pain Treatment depends on the size of the lesion and its location, and whether or not metastasis is demonstrated These tumors

are particularly sensitive to roentgen therapy Cobalt 60 teletherapy has given palliation without causing the severe and disabling changes in the skin which occur after conventional external radiotherapy The only hope for cure is by means of a radical Miles operation Dissection of inguinal lymph nodes is resorted to only when nodes are palpable

Squamous cell cancers arising in the perianal skin at some distance from the anal opening are superficial and rarely metastasize to the regional nodes They are satisfactorily treated by wide local excision

*Basal cell carcinoma* of the anal skin does not metastasize It is easily and effectively excised locally In this regard it is important to know that one half of the circumference of the perianal skin may be removed without risking the formation of a stricture Larger defects are easily covered by split-thickness skin grafts

*Carcinoma in situ in the anal skin* is the diagnosis occasionally reported by the pathologist after a hemorrhoidectomy This diagnosis is not to be viewed with alarm Further surgical treatment is not indicated, instead, the anal skin should be examined at six month intervals. Unless there are notably visible premalignant changes in the skin, the occurrence of clinical carcinoma is extremely unlikely The diagnosis of *carcinoma in situ* has been known to occasion the unnecessary removal of the rectum, when the surgeon would have done better to profit by the words of Arthur Allen I would not remove a rectum for a cancer that I can not see"

*Paget's disease of the anal skin* (*intra epithelial carcinoma*) is rare In most instances it resembles Paget s disease of the breast, wherein a carcinoma at a higher level has metastasized downward into the anal skin However, it may exist in the absence of a demonstrable primary tumor In one of our cases a careful examination was initiated to locate the primary tumor None being found, the entire anal canal, perianal skin, and dentate line were removed, together with the underlying fat A skin graft was applied, suturing the upper end to the mucosa and the lower aspect to remaining perianal skin A good result was obtained, with the patient retaining rectal continence

*Papillary squamous cell cancer* of the anus is rare If it is polypoid, soft, and nonulcerating, it is cured by local excisional therapy or by mass coagulation Radical surgery seldom is indicated, since these soft superficial tumors rarely metastasize

*Malignant melanoma* of the anus is rare, it follows the same rules of metastasis and survival as elsewhere in the body when it arises in the anal epithelium

*Mucinous adenocarcinoma* occurring in chronic fistulous tracts is rare, and appears to have two separate origins (1) adenocarcinoma of the anal crypt area with fistulous extension into the ischiorectal space, and (2) carcinoma arising from epithelial remnants of congenital anal ducts or other vestigial structures One may be led to suspect the diagnosis when thick, jellylike mucus can be expressed from the external os of long standing chronic rectal fistula Papanicolaou spreads made from the mucus may be of diagnostic value but most often have no malignant cells present A vigorous curettage or biopsy of the tract is necessary to establish the diagnosis A combined abdominoperineal resection of the rectum with a radical perineal component may offer the best chance for cure

## REFERENCES


ALLEN, A W *Personal communication* 1955

ARCHIBALD, F Operative treatment of cancer of the rectum *J A M A 50* 573, 1908

BABCOCK, W W Carcinoma of rectum One-stage simplified proctosigmoidectomy with formation of perineal anus, *S Clin North America 12* 1397, 1932

BACON, H E Abdominoperineal proctosigmoidectomy for cancer of the rectum *J Nat M A 35* 158, 1943

BACON, H E Abdominoperineal proctosigmoidectomy with sphincter preservation five year and ten year survival after pull

through" operation for cancer of the rectum *J.A.M.A. 160* 628, 1956

BARRINGER, P. L., DOCKERTY, M. B., WAUGH, J. M., and BARGEN, J. A. Carcinoma of large intestine, new approach to study of venous spread *Surg. Gynec. & Obst. 98* 62, 1954

BLACK, B. M. Combined abdomino-endorectal resection, surgical procedure preserving continuity of bowel, for management of certain types of carcinoma of midrectum and upper part of rectum *Proc. Staff Meet. Mayo Clin. 23* 545, 1948

BRODERS, A. C. Squamous cell epithelioma of lip *J.A.M.A. 74* 656, 1920

BRODERS, A. C. Grading of carcinoma *Minnesota Med. 8* 726, 1925

BRODERS, A. C. Carcinoma, grading and practical application *Arch. Path. & Lab. Med. 2* 376, 1926

BUIE, L. A. Polypoid disease of the colon *Postgrad. Med. 5* 177, 1949

COLE, W. H., PACKARD, D., and SOUTHWICK, H. W. Carcinoma of the colon with special reference to prevention of recurrence *J.A.M.A. 155* 1549, 1954

COLLER, F. A., RANSOM, H. K., and REGAN, W. J., JR. *Cancer of the Rectum for the Physician* (a monograph) American Cancer Society, Inc., 1956, pp. 82–83

COPE, V. Z., *et al.* Discussion on granulomata of large intestine *Proc. Roy. Soc. Med. 42* 763, 1949

CRILE, G., JR., and ROBNETT, A. H. Primary closure of the posterior wound after combined abdominoperineal resection for carcinoma of the rectum *Cleveland Clin. Quart. 17* 5, 1950

DALAND, E. M., WELCH, C. E., and NATHANSON, IRA L. One hundred untreated cancers of the rectum *New England J. Med. 214* 451, 1936

DELANEY, L. T., SCUDAMORE, H. H., and WAUGH, J. M. Symposium on unusual surgical lesions of colon, malignant melanoma of rectum, report of case *Proc. Staff Meet. Mayo Clin. 29* 416, 1954

DIXON, C. F., DOCKERTY, M. B., and POWELSON, M. H. Symposium on unusual surgical lesions of colon, squamous cell carcinoma of midrectum, report of case *Proc. Staff Meet. Mayo Clin. 29* 420, 1954

DUKES, C. E. Classification of cancer of rectum *J. Path. & Bact. 35* 323, 1932

DUKES, C. E. Histological grading of rectal cancer *Proc. Roy. Soc. Med. 30* 371, 1937

DUKES, C. E. Surgical pathology of rectal cancer, president's address *Proc. Roy. Soc. Med. 37* 131, 1944

DUKES, C. E. Discussion on major surgery in carcinoma of rectum with or without colostomy, excluding anal canal and including rectosigmoid, general results of surgical treatment *Proc. Roy. Soc. Med. 50* 1031, 1957

DUKES, C. E. Pre-cancerous conditions of the colon and rectum *J. Roy. Coll. Surg. Edinburgh 3* 182, 1958

DUKES, C. E., and BUSSEY, H. J. R. Venous spread in rectal cancer *Proc. Roy. Soc. Med. 34* 571, 1941

ENGELL, H. C. Cancer cells in circulating blood, clinical study on occurrence of cancer cells in peripheral blood and in venous blood draining tumor area at operation *Acta chir. scandinav. (Supp.) 201* 1, 1955

FISHER, E. R., and TURNBULL, R. B., JR. Cytologic demonstration and significance of tumor cells in mesenteric venous blood in patients with colorectal carcinoma *Surg. Gynec. & Obst. 100* 102, 1955

FREEMAN, J. T., and RAVDIN, I. S. Polyps and pigment in the Peutz-Jeghers syndrome *New England J. Med. 253* 958, 1955

GABRIEL, W. B. Perineo-abdomino excision of rectum in one stage *Lancet 2* 69, 1934

GABRIEL, W. B., DUKES, C., and BUSSEY, H. J. R. Lymphatic spread in cancer of the rectum *Brit. J. Surg. 23* 395, 1935–1936

GILCHRIST, R. K., and DAVID, V. C. Lymphatic spread of carcinoma of rectum *Ann. Surg. 108* 621, 1938

GLOVER, R. P., and WAUGH, J. M. Retrograde lymphatic spread of carcinoma of rectosigmoid region", its influence on surgical procedures *Surg. Gynec. & Obst. 82* 434, 1946

GRINNELL, R. S. Spread of carcinoma of colon and rectum *Cancer 3* 641, 1950

GRINNELL, R. S., and LANE, N. Collective Review. Benign and malignant adenomatous polyps and papillary adenomas of the colon and rectum. An analysis of 1,856 tumors in 1,335 patients *Surg. Gynec. & Obst. 106* 519, 1958

HARTMANN, H. *Chirurgie du rectum.* Libraries de L'Academie de Medicine. Paris, Masson et Cie, Editeurs, 1931, pp. 344–355

HELESTROM, J., HULTBORN, K. A., and ENGSTEDT, L. Diffuse cavernous hemangioma of rectum *Acta chir. scandinav. 109* 277, 1955

HUBBARD, T. B., JR. Familial polyposis of the colon, the fate of the retained rectum after

colectomy in children *Am Surgeon 23* 577, 1957

HUGHES, E S R *Surgery of the anus, Anal Canal and Rectum* Edinburgh and London, E & S Livingstone, Ltd, 1957, p 202

JONES, T E Abdominoperineal operation for cancer of the rectum *J A M A 95* 1172, 1930

JONES, T E Technique of abdominoperineal resection for carcinoma of rectum *Am J Surg 27* 194, 1935

KOHLRAUSCH, O *Zur Anatomie und Physiologie der Beckenogane, nebst naturgetreuer Abbildung der Langsdurchschnitte des mannlichen und weiblichen Beckens* Leipzig, S Hirzel, 1854

MAYO, H W, JR, and MCKEE, E E Carcinoid of rectum *A.M A Arch Surg 62* 506, 1951

MCLANAHAN, S, GROVE, G P, and KIEFFER, R F, JR. Conservative surgical management for certain rectal adenomas showing malignant change *J A M A 141* 822, discussion 825–826, 1949

MILES W E A method of performing abdomino-perineal excision for carcinoma of the rectum and of the terminal portion of the pelvic colon *Lancet* 2 1812, 1908

MRAZEK, R G, JR., GODWIN, M C, and MOHARDT, J Carcinoid tumors, clinical and pathologic study of 27 cases *Surg Gynec & Obst 96* 661, 1953

PACK, G T, GERBER, D M, and SCHARNAGEL, I M End results in treatment of malignant melanoma report of 1190 cases *Ann Surg 136* 905, 1952

RANKIN, F W and GRAHAM, A S *Cancer of the Colon and Rectum Its Diagnosis and Treatment*, 2d ed Springfield, Ill, Charles C Thomas, 1950

SAUER, I, and BACON, H E Influence of lateral spread of cancer of rectum on radicality of operation and prognosis *Am J Surg 81* 111, 1951

SAUER, I, and BACON, H E New approach for excision of carcinoma of lower portion of rectum and anal canal *Surg Gynec & Obst 95* 229, 1952

SNOW, P J D, LENNARD-JONES, J E, CURZON, G, and STACY, R S Humoral effects of metastasizing carcinoid tumours *Lancet* 2 1004, 1955

TURNBULL, R B, JR Carcinoma in polyps of the colon and rectum, a study of 86 treated patients *Dis Colon & Rectum 1* 44, 1958

TURNBULL, R. B, JR "The Coagulation—Radon Seed Implantation for Certain Cancers of the Rectum," Chap 24, pp 528 536, in *Diseases of the Colon and Anorectum*, ed by R TURELL Philadelphia, W B Saunders Company, 1959, 608 pp

WAUGH, J M, MILLER, E M, and KURZWEG, F T Abdomino-perineal resection with sphincter preservation for carcinoma of midrectum *A M A Arch Surg 68* 469, 1954

WAUGH, J M, Personal communication, 1955

# INDEX

LIBRARY
UDAIPUR

Abdominoperineal resection, in rectal tumors, 621, 624–629
Abscess, in appendicitis, 512, 516
in colitis, ulcerative, 560
in diverticulitis of colon, 592, 596
intra-abdominal, 74
of liver, 274–278
psoas, differential diagnosis of, 127
of spleen, 450–451
subdiaphragmatic, after biliary tract surgery, 339
after splenectomy, 463
after trauma, 173
Achlorhydria, 245
after duodenal ulcer surgery, 247
Acidosis, in anesthesia, 66
Actinomycosis, of rectum, 619
Adenitis, mesenteric, differential diagnosis of, 511
subingual, differential diagnosis of, 110, 127
Adenocarcinoma, of anus, 638
of colon, 530–531
of pancreas, 431
of rectum, 611
of stomach, 212
Adenoma, of colon, 525–529
of liver, 304
of pancreatic islets, 439–441
of rectum, 607–610
of retroperitoneum, mesentery and omentum, 520
of stomach, 209
Adhesions, 487–488
intestinal, 95, 485
Adrenal glands, in anesthesia, 67
incision for, 19
insufficiency, postoperative shock from, 87–88
tumors of, differential diagnosis of, 344
wounds of, penetrating, 189
Agenesis, of gallbladder, 314
Alarm reaction, response to, 80, 81, 204
Albert sutures, 480
Albumin, levels after portal decompression, 293, 299
therapy in pancreatitis, 409
Alcoholism, and pancreatitis, 402, 416
and variceal hemorrhage, 303–304
Alkaline regurgitation after duodenal ulcer surgery 247
Alkalosis, in anesthesia, 66
Allen clamp, 475, 479
Allergy, and colitis, ulcerative 549
Ambulation, postoperative, 78–79
Amebic abscess of liver, 277
Amebic dysentery, differential diagnosis of, 557
Amebic granuloma, of rectum 620
Ampulla of Vater, tumors of 437
Amputation, mortality from, 26
Amylase levels, in pancreatitis, 401, 405–407 417, 418
Anastomosis, biliary-intestinal, 358–359
caval superior mesenteric, 283 286, 292
in colonic cancer, 535, 537 538 542
colorectal, 632 634
duct to-duct, in biliary stricture, 383–384
duct to-duodenum, in biliary stricture, 384–385
duct to jejunum, in biliary stricture, 386–387
esophagogastric, 233 235
ileorectal, with colectomy, in polyposis, 606
intestinal, 479–482, 487
clamps for, 475, 479
end to-end, 479–480
side-to side, 480
jejunoesophageal, 236–238
in pancreatic carcinoma, 435–436
portacaval, 280, 283–286
end-to-side, 287–291
side-to-side, 292
pull through operations in rectal tumors, 629–632
retrograde, in pancreatitis, 426–427
splenorenal, 282, 283–286, 291–292
*See also specific procedures*
Anatomy, 1–6
blood vessels, 6
fascia, 1–5
liver, 305
muscles, 1–5
nerves, 5–6
Anatomy (*Continued*)
skin, 1
spleen, 443–445
subcutaneous tissue, 1
Andrews Ferguson hernia repair, 115, 118, 121
Anectine, 56
in liver disease, 287
Anemia, in colitis, ulcerative, 554, 559
hemolytic, blood volume deficit in, 457
congenital, 454
idiopathic acquired, 456
hypoplastic, with hypersplenism 457
iron deficiency, after gastrectomy, 229
Mediterranean differential diagnosis of, 454
pernicious, and gastric carcinoma, 201, 211
postoperative, 83
transfusions for, 27–28
Anesthesia, 53–76
abdominal field block, 63
in abscess, intra abdominal, 74
acid base balance in, 66
adrenal glands in, 67
in appendectomy, 513
in biliary tract surgery, 71
carbohydrate metabolism in, 66
in cecostomy, 74
chlorprocaine, 62
in colonic resections, 74
cyclopropane, 54–55, 286
endotracheal intubation, 68, 69
epidural, 59–60
in esophagogastrectomy, 72
ether, 54
in evisceration, 75
field block, 63–64
in gallbladder surgery, 327–328
in gastric surgery, 71
in gastroenterostomy, 72
in gastrostomy, 72
general, 54–57
hemolytic reactions during, 31
in hernias, 75–76
hexylcaine, 62
hypotension induction, 64–65
hypothermia, 65–66, 575–576, 579
in ileostomy, 74
in infants and children, 70

Anesthesia (*Continued*)
infiltration, 64
intercostal nerve block, 63
in intestinal operations, 73
kidney function in, 67
lidocaine 61
in liver disease, 286–287, 307
liver function in, 66
in lower abdominal surgery, 74–75
of lumbar sympathetic ganglionated chain, 102–103
metabolic disorders from, 66–67
muscle relaxants, 56–57
nitrous oxide, 55 56
in pancreatic surgery, 73
paravertebral lumbar block, 64
piperocaine, 62
preoperative medications, 48–49, 70
procaine, 61
protein metabolism in, 66
reactions to drugs, 62–63
reflex activity in, 67 68
regional 57–66
respiration control in 69
selection of, factors in 53–54
in small bowel surgery, 474–475
special problems in, 70–76
spinal 57–59
splanchnic block, 64
in splenectomy, 73
spreading factors in, 62
tetracaine, 61
thiopental, 55–56
in vagotomy, 72
vasoconstrictors with, 58, 61, 62
in viscus perforation, 72
vomiting and regurgitation in, 68–69
in wound surgery, 180–181
Anesthesiologist, duties of, 29
Aneurysm, hepatic artery, 270
splenic artery 448–450
Angiosarcoma, of colon 533
Antibiotics, in intestinal obstruction, 474
in laparotomy, 182
in neutropenia, 458
in peritoneal cavity, 484
postoperative, 60
in wound surgery, 191
Anticoagulants, preoperative, 50
Antrum pyloricum role in gastric secretion, 244
Anus, ileostomy through, 573–575
melanoma of, malignant, 619
tumors of, 637–638
Aorta stenosis for, 8, 17, 19
wounds of, penetrating 190
Apnea, production of, 69
Appendectomy, 512–515
anesthesia in, 513
herniopfasty with, 123
incision for, 11, 513
mortality from, 26
Appendix, 508–518
acute appendicitis, 509–517
abscesses with, 512, 516
appendectomy in, 512–515
in children, 516–517
complications of, 512
diagnosis of, 510–512
differential diagnosis of, 344
in old age, 516–517
pathology of, 509
peritonitis with, 515–516, 517
in pregnancy, 516
prognosis of, 512
symptoms of, 509–510
treatment of, 512–517
argentaffin tumors of, 531
chronic appendicitis, 517
congenital anomalies of, 508–509
cysts of, 517–518
diverticula of, 508
double, 508
left sided appendicitis, differential diagnosis of, 595
neoplasms of, 516
position of, variations in, 508–509
vascular supply of, 515
Argentaffin tumors, of appendix, 531
of rectum, 618
of small bowel, 498
Arteries *See* Blood vessels *and specific arteries*
Arteriotomy, 65
Arthritis, with colitis, ulcerative, 559
Ascites, cirrhosis with, 281
and portal hypertension, 295
Aspiration, duodenal, in pancreatitis, 418
of gastric contents, prevention of, 50–51, 68 69
of intrahepatic abscess, 275
peritoneal, in splenic rupture, 452
tracheobronchial, postoperative, 90
Asthmatic patients, 46–47
Atelectasis, postoperative, 89–90, 92–93
Atresia, of biliary ducts, congenital, 397
duodenal, differential diagnosis, 196
intestinal, 489
Atropine, in wound surgery anesthesia 160

Baer, ileostomy, 556–583
Baker colorectal anastomosis, 633
Ballance sign, in splenic rupture, 452
Balloons, esophagogastric, 280
Barium enema, in carcinoma of colon, 534
in small bowel disorders, 469
Bassini hernia repair, 112, 118, 125, 127
Baudet, latent period of, 451
Belladonna drugs, preoperative, 48
in wound surgery, 180
Bile, in gallbladder, 313
intrahepatic cholestasis, 366
in liver, 312
metabolism disorders, 316
regurgitation of, 367
secretion of, 312–313, 367
stasis in pregnancy, 317
white, 369, 388
Biliary tract, 349–362
anastomosis, biliary intestinal, 358–359
anesthesia for surgery of, 71
anomalies of, 268
calculi, in common duct, 340–341
differential diagnosis of, 372
recurring, 355–356
small stones in cystic duct, 349–350
cholangiography, intravenous 350 351, 354–355
in pancreatitis, 405, 417
cholangiojejunostomy, intrahepatic, in biliary stricture, 387–393
cholangitis, after biliary tract surgery, 339
obliterative, 366, 372
ulcerative, 366
choledochoduodenostomy, 358–359
in biliary stricture, 384–385
in pancreatitis, 342–343
choledochoenterostomy, in pancreatitis, 424
choledochogram, postoperative, 356–358
choledochojejunostomy, 358
in biliary stricture, 386–387
choledochostomy, 351–354
cholecystectomy with, 354
mortality from, 26
in pancreatitis, 423
choledochotomy, with cholecystectomy, 333–335
in cholecystitis 325
cirrhosis, biliary, 366
and varicoal hemorrhage, 301–302
colic, biliary, 323
cystic duct remnant, after cholecystectomy, 341
drainage of, 356–358
enlargement of ducts, 349
fever in disorders, 350

Biliary tract (*Continued*)
hemobilia, 161, 173, 174
incision for, 14
jaundice, 349. *See also* Jaundice
neuromas of cystic duct, postoperative, 343
in pancreatitis, 402, 416, 421
operations for, 423–424
postcholecystectomy syndrome, 359–362
short circuiting operations, 358–359
stricture of, 363–398
congenital atresia, 397
delayed, 370, 373
diagnosis of, 369–371
differential diagnosis of, 371–373
etiology of, 363–367
incidence of, 363
pathology of, 367–369
primary, 372, 376
spontaneous nonoperative, 366–367
surgery in, 378–395
choice of operation, 373 376
cholangiojejunostomy, intrahepatic, 387–393
choledochoduodenostomy 384–385
choledochojejunostomy, 386–387
dissection technique, 380–383
end to-end anastomosis, 383
exposure technique, 378–380
preoperative preparation, 376–378
prostheses, 393–395
results of operation, 395–397
trauma causing, 364–366, 373
trauma, nonpenetrating, 157, 161
penetrating 166
strictures from, 364–366, 373
tumors of, differential diagnosis of, 373
malignant, 305
Bilirubin, 367
in gallstones, 316
levels after portal decompression, 293
Biliverdin, 312
Billroth gastric operations, 226
Bladder, cystitis after catheterization, 634
postoperative care of, 79
rupture of, 157, 162
sliding hernia of, 109, 123
suprapubic cystostomy, 187
Bladder (*Continued*)
wounds of penetrating 166 187
Bleeding *See* Hemorrhage
Blood conditions *See* Hematology
Blood pressure *See* Hypertension, Hypotension
Blood transfusions, 27–32 *See also under* Hematology
Blood vessels, 6
arteriotomy, 65
cholangiography, intravenous, 350–351, 354–355
in pancreatitis, 405, 417
of elderly patients 25–26
embolism, pulmonary post operative, 91 92
hepatic anomalies 269–270
incisions for surgery of, 17, 19
intravenous infusions, 38–40
in wound management 175, 191
in left hemicolon, 623
mesenteric lesions, 489 502
phlebothrombosis, postoperative, 101, 103–104
splenic lesions, 448–450
surgery in cardiovascular disorders, 43–44
thrombophlebitis, in colitis, ulcerative, 560
postoperative, 101, 102 103
thrombosis *See* Thrombosis
trauma of, nonpenetrating, 162
penetrating, 166
varices *See* Varices
vasoconstrictors with anesthetics, 58, 61, 62
*See also specific vessels*
Bochdalek, foramen of, 143
Boeck's sarcoid, of spleen, 452
Bone marrow, in splenic disorders, 456
Bowel conditions *See* Intestines
Breast surgery, radical, mortality from, 26
Bronchiectasis, preoperative care in, 46
Bronchopulmonary disease, preoperative preparation in, 45–47
Buttocks, penetrating wounds of, 187

Calcium deficiency, in pancreatitis, 410
Calculi, biliary, in common duct, 340–341
differential diagnosis of, 372
recurring, 355–356
small stones in cystic duct, 349–350
enteroliths, 494
fecaliths, 494
Calculi (*Continued*)
gallstones 316–322
*See also under* Gallbladder
in pancreatitis, 416, 417, 421, 425
ureteral, differential diagnosis of, 595
Calot triangle of, 364–365
Cancer *See* Tumor *and specific tumors*
Cantor tube, 471
Carbohydrate metabolism, in anesthesia, 66
Carbon dioxide poisoning, post operative, 89
Carcinoid tumor, of appendix, 517
of cecum, and portal hypertension, 303
of colon, 531–533
of rectum, 618
of small bowel, 498
Carcinoma, of ampulla of Vater, 437
of anus, 637–638
of appendix, 518
of cecum, 532
resection in, 538–539
of colon, 526, 530–544
*See also under* Colon
of gallbladder 321, 345–347
of pancreas, 431–437
lymph node metastasis from, 420 421
of prostate, differential diagnosis of, 617
retroperitoneal, 521
of small bowel, 497
of stomach, 211–216
*See also under* Stomach
Cardia lesions, 230–239
chalasia, differential diagnosis of, 196
stricture, 238
ulcer, 238
Cardioesophageal junction, exposure of, 15, 20
Cardiospasm, gastric aspects of, 238
Cardiovascular conditions *See* Blood vessels, Heart
Catheterization, infections after, 634
postoperative, 82
preoperative, 51
in wound management, 178
Cecostomy, anesthesia in, 74
in cancer of colon, 536
Cecum, carcinoid of, and portal hypertension, 303
carcinoma of, 532
resection in, 538–539
diverticulum of, 592
incision for, 15
sliding hernia of, 109
tuberculosis of, 496

Cecum (*Continued*)
wound of, penetrating, 184–185
Chalasia of cardia, differential diagnosis of, 196
Cherney incision, 18
Childhood conditions *See* Pediatrics
Chlorprocaine anesthesia, 62
Cholangitis *See* Biliary tract
Cholecystic conditions *See* Gallbladder
Cholecystokinin, function of, 313
Choledochal conditions *See* Biliary tract
Cholesterol gallstones, 316
Chordoma, retroperitoneal, 521
sacrococcygeal, 533
Chyme, preparation of, 244
Circulation, splenic, 445
Cirrhosis, biliary, 366
and varceal hemorrhage, 301 302
Hanot's, 366
hepatic 278, 279
pancreatitis with, 410
Laennec's 369
pancreatic 416
Citrate intoxication, in transfusions 31
Clamps caval, 289 290
for intestinal anastomosis 475 479
Payr, 256 258
von Petz 221
Closure of incisions, 21–23
delayed, 105–106
Coagulation defects postoperative, 85
Colectomy, in carcinoma of colon, 538–543
in diverticulitis, 598–601
ileorectal anastomosis with, in polyposis 606
mortality from, 26
partial, in colitis, 565 566 586
*in polyps of colon, 528*
proctocolectomy with ileostomy, 567, 575–586
Colic, biliary, 323
Colitis ulcerative, 548 590
acute forms of, 553
carcinoma with 561 564
chronic forms of, 553
complications of, 559–562
anorectal, 562
colonic, 560
systemic, 559
continuous, 553
diagnosis of, 556 558
differential diagnosis of, 535, 557
etiology of, 548–550
fulminating, 553 563
hemorrhage in 554, 560, 561
incidence of, 548
Colitis, ulcerative (*Continued*)
insidious, 553
invalidism in, 562–563
mild, 553
pathology of, 550–553
perforation in, 560, 563
proctoscopic findings in, 554–555
prognosis of, 558–559
pseudopolyposis in, 551, 553, 555, 561, 606, 610
radiology in, 555–556
regional, 550
relapsing, 554
right sided, 550
segmental, 550
signs and symptoms of, 553
skip areas of disease, 566, 567, 578
strictures with, 560, 564
toxemia in, 564
treatment of, 562–589
colectomy, partial, 565, 566, 586
colostomy, ileotransverse, 565, 586
ileostomy, 566–589
indications for surgery, 562–565
proctectomy with sigmoid colostomy, 566
proctocolectomy with ileostomy, 567, 575–586
surgical techniques, 567–586
types of operations, 565–567
vagotomy, 586
Colon, adenocarcinoma of, 530–531
anesthesia for resections of, 74
angiosarcoma of, 533
ascending, carcinoma of, 538–539
incision for, 15
carcinoid tumors of, 531–533
carcinoma of, 526, 530–544
ascending colon, 538–539
cecum, 520
with colitis, ulcerative, 561, 564
complications of, 535
descending colon, 539, 540
diagnosis of, 533–535
differential diagnosis of, 538, 596, 597
etiology of, 530
hepatic flexure, 539
lower sigmoid, 541
metastasis from 530–531
mid sigmoid, 539
postoperative complications of, 544
preoperative preparation in, 535–537
rectosigmoid, 541
splenic flexure, 536, 538, 539, 540
Colon, carcinoma of (*Continued*)
transverse colon, 539
treatment of, 535–544
upper sigmoid, 539, 540
colectomy, 538–543
*See also* Colectomy
colitis, ulcerative, 548–590
*See also* Colitis, ulcerative
colorectal anastomosis, 632–634
colostomy, 536, 543
*See also* Colostomy
descending, carcinoma of, 539, 540
differential diagnosis of lesions 344
diverticulosis and diverticulitis of, 591–603
abscess with, 592, 596
*colostomy and resection* 598–599
complications of, 596–597
diagnosis of, 594–596
differential diagnosis of, 534, 595–596
etiology of, 592
fistula with, 592, 597
hemorrhage with, 596–597, 598
incidence of, 591–592
indications for surgery, 597–598
intractable, 597
laboratory findings in, 593–594
morbidity and mortality in, 601–602
obstructive resection, 599–600
operative procedures in, 598 601
pathology of, 592–593
perforation with, 596, 598
proctoscopy in 595
radiology in, 594
sigmoid, 592
simple suture, 598
single stage resection with immediate anastomosis, 600 601
strictures with, 596
symptoms and signs of, 593
endometrioma of, 529
fibrosarcoma of, 533
fistula, in diverticulosis, 592, 597
gastrojejunocolic, with duodenal ulcer, 251–253
in ulcerative colitis, 560
hemangioma of, 530
hepatic flexure, carcinoma of, 539
hernia of, sliding, 109, 122
leiomyoma of, 529
leiomyosarcoma of, 533

Colon (*Continued*)
lipoma of, 529
*lymphoma of, benign*, 529
lymphosarcoma of, 533
malrotation of, differential diagnosis of, 196
perforation of, in diverticulitis, 596, 598
Peutz Jeghers syndrome, 529
polyps of, adenomatous, 525–529
diagnosis of, 526–527
familial polyposis, 529
pathology of, 525–526
pseudopolyposis in colitis, 551, 553, 555, 561, 606, 610
treatment of, 527–529
rectosigmoid, carcinoma of, 541
reduplication of, 530
sigmoid, carcinoma of, 539, 541
colostomy, in colitis, 566
diverticulitis in, 592
hernia of, sliding, 109
ileosigmoidostomy in colitis, 566, 586
incision for, 11, 16
sigmoidoscopy, in carcinoma of colon, 534
in polyps of colon, 526
splenic flexure, carcinoma of, 536, 538, 539, 540
stricture of, in diverticulitis, 596
tumors of, 525 545
benign, 525–530
malignant, 530–544
volvulus, 545 547
wounds of, nonpenetrating, 157
penetrating, 166, 184–187
Colorectal anastomosis, 632–634
Colostomy, in cancer of colon, 536, 543
complications of, postoperative, 635–636
hernia around opening of, 139, 140
*ileotransverse*, in colitis, 565, 586
incision for, 16
with Miles operation for rectal tumors, 628
postoperative care, 634
proximal, in colitis, 566
in diverticulitis of colon, 598–599
retraction of, 636
sigmoid, in colitis, 566
incision for, 11
in wound repair, 185
Complications, postoperative, 77–106
*See also* Postoperative care and complications
Congenital conditions, anemia hemolytic, 454
of appendix, 508–509
of bile ducts, 268, 397
of cecum, 592
of gallbladder, 314–317
in intestinal tract, 489 490
of liver, 266–270
of spleen, 446–448
of stomach, 195–198
Connell sutures, 480
Contamination, in abdominal cavity, 484
Coombs test, in anemia, hemolytic, 453, 454, 456
Cooper's ligament, in hernia repair, 117, 118 120, 121–122, 128, 129
Corpus hemorrhagicum, ruptured, differential diagnosis of, 511
Cortisone, in pancreatitis 410
Costal conditions, flaring angles 14, 15
*intercostal nerve block*, 63
Cranial injury, differential diagnosis of, 196
Crohn's disease, 495–496
Crural hernia, 125–130
differential diagnosis of, 111
Cullen sign, in trauma, 168
Curare, 56
Cushing, hernia repair of, 125
sutures of, 477, 480
Cyclaine anesthesia, 62
Cyclopropane anesthesia 54–55, 286
Cyst, appendiceal, 517–518
caudal gut, 520
dermoid, of retroperitoneum, mesentery and omentum, 520
echinococcus *See* Echinococcus cyst
*hepatic, congenital*, 268–269
echinococcus, 277
mesenteric, removal of, 491
ovarian, differential diagnosis of, 511, 595
pancreatic, 431
pseudocysts, 414, 415, 416, 417, 421, 428–430
pneumatoides intestinalis, 499
sebaceous, of umbilicus, differential diagnosis of, 131
splenic, 448–449
traumatic formation, 174
umbilical, removal of, 492
urachal, differential diagnosis of, 131
Cystadenoma, of pancreas, 431
of retroperitoneum, mesentery and omentum, 520
Cystic duct, neuromas, postoperative, 343
remnant, after cholecystectomy, 341
Cystic duct (*Continued*)
small stones in, 349–350
Cystitis *See* Bladder
Cytopenia, in splenic disorders, 456

Dance's sign, in intussusception, 493
Debridement, in wound surgery, 180
Decamethonium, as muscle relaxant, 56
Decompression, gastric, 79 93, 337–338
after wound surgery, 190
intestinal, 79–80, 94, 470–473, 484
portal, 279–304
*See also under* Liver
Dehiscence of wounds, 9, 11, 13, 21, 23, 26, 104–106, 635
anesthesia in resuturing for, 75
*Denervation, sensory, in pancreatitis*, 424
Dermoid cyst of retroperitoneum, mesentery and omentum, 520
Diabetes, after pancreatic surgery, 436
in pancreatitis, 411, 415
preoperative preparation in, 47–48
Diaphragm, abscess, subdiaphragmatic, after biliary tract surgery, 339
after splenectomy, 463
division of, 20
eventration of, 142–143
hernia of, 142–146
postoperative infection, subphrenic, 99
trauma, nonpenetrating, 157, 162
Diarrhea, in colitis, 548, 554
in small bowel disease, 467
Dietotherapy *See Nutrition*
Dilatation, acute gastric, postoperative, 93
Distention, abdominal, in small bowel disease, 467
Diverticulosis and diverticulitis, of appendix, 508
of colon, 591–603
*See also under* Colon
of duodenum, 263–264
pseudodiverticulum, 263
of gallbladder, 315
gastric, 197–198
Meckel's, 490–492
*See also* Meckel's diverticulum
of small bowel, 492
Douglas pouch, hernia of, 148
postoperative infection in, 100
Dowd operation for hernia, 151

Dragstedt ileostomy, 572–573
Drains, 23
in appendectomy, 515
of bile ducts, 356, 424
in cholecystectomy, 333
gastroduodenal, in splenectomy, 458
hepatic, 272–273, 276–277
pancreatic, 412, 429–430
after splenectomy, 459, 461, 462
in wounds, penetrating, *173*
Dubin-Johnson syndrome, differential diagnosis of, 372
Ducts, biliary *See* Biliary tract
cystic *See* Cystic duct
pancreatic, dilatation of, 425
ligation of, 427
longitudinally opened 427
of Santorini, 399
vitellointestinal persistent, 490, 502
of Wirsung, 399
Dunphy spleen removal, 189
Duodenum, 242–265
aspiration of, in pancreatitis, 418
atresia of differential diagnosis of 196
choledochoduodenostomy, 358–359, 384–385
diverticulum of 263–264
duodenostomy, incision for, 15
foreign body in, 494
gastroduodenal intubation, in splenectomy 458
pancreatoduodenectomy 427 432
physiology of, 244–246
pseudodiverticulum of 263
tumors of, 264
ulcer of, 242–244
burned-out 248
complications of, 248–253
etiology of, 242 243
gastrectomy in, subtotal, 252, 253–260
and gastric hypersecretion, 243
gastroduodenostomy in 260
gastroenterostomy in, 258–260, 262
gastrointestinal physiology after surgery for, 246–247
gastrojejunocolic fistula with, 251–253
hemorrhage with, 249
incidence of, 242
intractability of, 248
marginal ulcer with, 251
pain in, 235
pathology of, 247–248
perforated, 243, 249, 260, 261
after partial secretion, 255
Duodenum, ulcer of (*Continued*)
pyloric obstruction with, 250
pyloroduodenostomy in, 263
pyloroplasty in, 263
vagotomy in, 260–262
wounds of, nonpenetrating, 157, 161
penetrating, 166, 183
Dysentery, amebic, differential diagnosis of, 557
*bacillary, differential diagnosis of*, 557
Dysgerminoma, retroperitoneal, 521

Echinococcus cyst, of liver, 277
of pancreas, 431
of spleen, 448, 449
Eck fistula, 295, 300
Ectopia, of liver, 266
of pancreatic tissue, 400
of spleen, 447–448
Edema, hypoproteinemia with, 33
in pancreatitis, 402, 407, 421
pulmonary, postoperative, 92
Electrocoagulation in rectal polyps 606, 610
Electrolytes and fluids *See* Fluids
Embolism, pulmonary, postoperative 91–92
Emphysema, pulmonary, preoperative care in, 46
Endometrioma, of colon, 529
Endometriosis differential diagnosis of, 618
Endoscopy, in colonic polyps, 527 528
Endothelioma, of liver, 305
Endotracheal intubation, 68, 69
Enema, barium, in carcinoma of colon, 534
in small bowel disorders, 469
Enteritis *See* Intestines
Enzyme therapy, in pancreatitis, 418, 419
Epidural anesthesia 59–60
Epigastric hernia, 134–135
Epinephrine, with anesthetics, 58, 61, 62
Epithelioma, anal, 637
Esophagus anastomosis, gastric, 233–235
jejunal, 236 238
esophagogastrectomy, anesthesia for, 72
in variceal bleeding, 297–299
incision for, 13
varices 278–304
hemorrhage of, 279–280, 302–304
hypersplenism with 300–301, 302
Esophagus, varices (*Continued*)
and normal portal pressure, 297–299
postsplenectomy bleeders, 300
spontaneous subsidence of, 295
Ether anesthesia, 54
Eventration of diaphragm, 142–143
Evisceration, anesthesia in, 75

Fallopian tubes, incision for lesions of, 13
salpingitis, differential diagnosis of, 595
wounds of, penetrating, 188
Farber's test, in atresia of intestine, 489
Fascia, 1–5
Fat, defects after duodenal ulcer surgery, 247
intravenous emulsions, 39–40
necrosis, in pancreatitis, 402
Fatty acids, tagged in pancreatitis, 418
Fecalithis, 494
in diverticulitis of colon, 593
ulceration of, 512
Felty's syndrome, 456–457
Femoral hernia, 125–130
differential diagnosis of, 111
Ferguson hernia repair, 112, 115, 124
Ferguson-Andrews hernia repair, 115, 118 121
Fever intermittent, 350
Fibrinogen depletion, 86
Fibroma, of small bowel, 498
Fibrosarcoma, of colon, 533
of retroperitoneum, mesentery and omentum, 521
of small bowel, 497
of spleen, 453
Fibrosis, of bile ducts, stenosing, *321*
in pancreatitis, 402, 415, 421
Field block, 63–64
Finney pyloroduodenostomy, 263
Fistula, arteriovenous, of splenic vessels, 450
biliary, external, 370
cholecystoenteric, 321
in colitis, ulcerative, 560
and diverticulitis of colon 592, 597
duodenal, after gastrectomy, 228
Eck, 295, 300
gastrojejunocolic, duodenal ulcer with, 251–253
at ileostomy site, 473, 568, 577, 585 589
intestinal, 173, 502–505
pancreatic, 229, 430
after pancreatic surgery, 436
small bowel, 502–505

Fistula (*Continued*)
umbilical, 491
ureteral, after rectal cancer surgery, 634
Fluids, loss of, in pancreatitis, 407–409
transfusion in, 20
postoperative, 78, 80–83
replacement of, in small bowel disease, 473–474
Foramen, of Bochdalek, 143
of Morgagni, 143
Foreign bodies, in small intestine, 494–495
Fundus ventriculi lesions, 230–239

Gallbladder, 311–348
agenesis of, 314
anatomy and physiology of, 311–314
bilobed, 314
carcinoma of, 321, 345–347
surgery in, 346–347
cholecystectomy, 328, 329–333
accidental trauma in, 364 373
in carcinoma of gallbladder, 346–347
in cholecystitis, 325, 329–333
choledochostomy with, 354
choledochotomy with, 333 335
common duct calculi after, 340–341
incisions for, 329
incomplete, 341–342
jaundice after, 370
mortality from, 26
in pancreatitis, 423
with portal decompression, 303
radical, 346–347
recurrence of symptoms after, 340–345
splenectomy with, 459
syndrome after, 359–362
cholecystitis, acute, 324–327
differential diagnosis of, 327
physical examination in, 326
postoperative, 98
symptoms of, 326
chronic, 322–324, 329–333
differential diagnosis of, 511
cholecystogastrostomy, 358, 359
cholecystography, 323, 324
in pancreatitis, acute, 405
cholecystojejunostomy, 358
cholecystokinin, 313
cholecystostomy, 329, 333
in cholecystitis, 325
in pancreatitis, 412
congenital anomalies of, 314–317

Gallbladder (*Continued*)
diagnosis, incorrect, 343–345
diverticula of, 315
double, 314
fistula, cholecystoenteric, 321
floating, 316
incision for, 14, 329
malposition of, 315–316
stone formation, 316–322
bile metabolism disorders, 316
bilirubin, 316
cholesterol, 316
and infections, 317
in intestines, 495
in pancreatitis, 423
and portal hypertension, 303
silent calculi, 340
small stones, 349–350
with splenic disorders, 459
stage four, 321
stage one, 318–320
stage three, 321
stage two 320
and stasis of bile, 317
surgery of, 327 345
anesthesia in, 327–328
cholangitis after 339
common duct stones after, 340–341
complications after, 338–340
cystic duct remnant after, 341 342
incisions for, 329
neuromas after, 343
pancreatitis after, 340, 342 343
postoperative care, 336–338
preoperative care, 327
recurrence of symptoms after, 340–345
subdiaphragmatic abscess after, 339
subhepatic accumulations after, 339
wound infection after, 339
wounds of, nonpenetrating, 157
penetrating, 166, 184
Ganglioneuroma, of retroperitoneum, mesentery and omentum, 520
Garlock ileostomy, 571–572
Gastrocolic ligament, 444, 459
Gastroepiploic artery, 443
Gastrointestinal tract *See* Intestines, Stomach
Gastrosplenic ligament, 444, 459
Gaucher's disease, spleen in, 452, 455
Geriatrics, 25–27
appendicitis, 516–517
blood vessel conditions, 25–26
malnutrition, 26
postoperative infections, 26
Gerlach valve of 508

Glucose, blood, deficiency of, 437 438
Graft, Turnbull mucosal in ileostomy, 568–571
Grafton Smith tube, 471
Granuloma, amebic, of rectum, 620
Gridiron incision, 17, 513
Grynfeltt-Lesshaft triangle hernia through, 149
Gynecologic conditions, cyst, ovarian, differential diagnosis of, 511, 595
hernia, pelvic, 148
incisions for pelvic surgery 9 13, 17
inflammatory disease of pelvis differential diagnosis of 511
labial hernia, 109
preoperative preparation of vagina, 51
rupture of uterus, 157, 162
salpingitis, differential diagnosis of, 595
wounds, penetrating, 188

Halsted hernia repair, 112–115, 117
Hamartoma, of liver, 304
Hand Schuller Christian disease spleen in, 452
Hanot's cirrhosis, 366
Harris tube, 471
Hartmann operation in rectal tumors, 621, 622, 632
Head injury, differential diagnosis of, 196
Heart, coronary disease, differential diagnosis of, 344
diseases of, preoperative preparation in, 43–44
in postoperative shock, 89
Heineke Mikulicz pyloroplasty 263
Hemangioma, of colon, 530
of liver, 304
of spleen, 453
Hemangiopericytoma, of retroperitoneum, mesentery and omentum, 521
Hematology, anemia *See* Anemia
blood pressure *See* Hypertension, Hypotension
blood volume, hypovolemic, 34–35, 68
hypotension with, 28
in pancreatitis, 408
postoperative shock with, 87
before splenectomy, 457
coagulation defects, postoperative, 85
hypofibrinogenemia, 86
neutropenia, 454–455, 456, 458

Hematology (*Continued*)
panhematopenia, primary splenic, 455
prothrombin *See* Prothrombin time
spleen and hematologic disorders, 445, 453–457
thrombocytopenic purpura, idiopathic, 453–454
transfusions, 27–32
arterial, 30
blood bank errors, 30
blood loss in operations, 29–30
citrate intoxication from, 31
complication of, 27, 83
hazards of, 30–32
hemolytic reactions in, 31
hepatitis from, 30, 83
indications for, 28–30
overtransfusion, 30 31
in pancreatitis 408, 420
platelet, in thrombocytopenia, 458
postoperative, 83 84
potassium intoxication from 31
in wound management, 179
Hematoma postoperative 104
retroperitoneal 168 182, 190
in trauma penetrating 168
Hemicolectomy, with portal decompression 303
Hemobilia, 161 173 174
Hemolytic anemia, 454, 456, 457
Hemolytic reactions, in anesthesia 31
in transfusions 31
Hemorrhage in colitis 554 560 564
in diverticulitis of colon 593 596–597 598
in duodenal ulcer 249
after gastrectomy 229
in gastric carcinoma, 215
in gastric ulcer 207
intra abdominal, incision in, 10
intraperitoneal, 160
from liver 181 188, 271 272
in Meckel's diverticulum, 491
after pancreatic surgery 433 436
in pancreatitis, 402, 410
after portal decompression, 293–294
postoperative, 85
after splenectomy, 300
of splenic vessels, postoperative 462
in thrombocytopenic purpura, idiopathic, 453
transfusions in, 28
in trauma 174
unexpected bleeding in surgery, 364
variceal, esophagogastric, 278, 279–280
Hemorrhagic diseases, differential diagnosis of, 196
Henry hernia repair, 129
Hepatic artery, anomalies of, 270
injury to, 273
ligation of, 303
Hepatic conditions *See* Liver
Hepatic flexure of colon, carcinoma of, 539
Hepatic vein anomalies, 269
Hereditary spherocytosis 454
Hering-Breuer reflex 69
Hernia 107–155
anesthesia for, 75 76
at colostomy opening, 139, 140
complications of, 152–154
congenital, 109
crural 125–130
diaphragmatic 142 146
acquired, 143
congenital, 143
etiology of, 143
hiatus 143
inflammatory, 143
traumatic, 143
treatment of, 145 146
of Douglas pouch 148
epigastric, 134–135
diagnosis of, 135
differential diagnosis of, 131
symptoms of 134
treatment of, 135
fatty, 110
femoral, 125 130
diagnosis of, 126–127
differential diagnosis of, 111
recurrent, 129
symptoms of, 126
treatment of, 127 130
forfeiting right of domicile 109, 136
hiatus 143
differential diagnosis of, 344
gastric aspects of 238
treatment of 146
after ileostomy, 589
incarcerated, 123, 152 153
incisional, 135–140, 142
diagnosis of, 137
lumbar, 149
symptoms of, 137
treatment of, 137–140
inflamed, 110
inguinal, 108–125
complete, 109
diagnosis of, 110
direct 108, 111, 116
incomplete, 108
indirect, 108, 111, 115
physical signs of, 110
symptoms of, 110
treatment of, 111–125
aponeurosis of external oblique, 121
appendectomy with, 123
Hernia, inguinal, treatment of (*Continued*)
closing hole in transversalis fascia, 117–118
closing internal ring, 119–120
conjoined tendon, 120, 121
Cooper's ligament repair, 117, 118, 120, 121–122
handling of sac, 115–117
in infants and children 124
operations, 112–115
position of cord, 118–119
reducing size of cord, 119
relaxation incision, 118
removal of extraneous tissue, 120
suture materials, 124
tantalum gauze, 120–121
testicle removal, 119
interparietal, 141–142
interstitial 141–142
irreducible 152
ischiorectal, 148
labial 109
in linea alba 134–135
in linea semilunaris 140–141
Littre's 140
lumbar 149–151
incisional 149 151
primary, 149
of Meckel's diverticulum 140
mortality from herniorrhaphy, 26
obstructed 153
obturator, 151–152
pantaloon 116
perineal 148–149
postoperative 104
properitoneal 141
pudendal 148
Richter's 140
saddlebag 111 116
sciatic 147–148
scrotal 109, 123
sliding 109 111, 122–123
Spigelian 140–141
strangulated, 153–154
subpubic, 148
superficial 141–142
umbilical 130 134
in adults 131
in children 131, 132
congenital, 130 132
diagnosis of, 131
symptoms of 131
treatment of 133, 134
vaginal, 148
Hesselbach's triangle area, strengthening of, 117, 118 120
Hexylcaine anesthesia 62
Hiatus hernia 143
treatment of, 146

Hodgkin's disease, retroperitoneal, 521
spleen in, 455
Hoguet hernioplasty, 116
Hollander test, after vagotomy, 245
Homans sign, 103
Hopkins hernia repair, 115
Howslip Romberg phenomenon 151
Hyaluronidase, with anesthetics, 62
Hydatid cyst *See* Echinococcus cyst
Hydrocele, differential diagnosis of, 111
Hydrochloric acid secretion, 245
and peptic ulcer, 203, 243
Hyperinsulinism, and islet cell tumor, 437 439
Hypersplenism, 445–446
Hypertension, portal, 278–304 455
in childhood, 302–303
Hypofibrinogenemia, 86
Hypoglycemia, 437–438
Hypoproteinemia, 32–40
blood volume reduction in 34–35
chronic depletion, 36–37
correction of, 37–40
edema with, 33
effects of, 32–35
evaluation of, 35–37
infection susceptibility in, 34
intravenous alimentation in 38–40
liver damage in, 34
nasogastric tube feeding in 37 38
postoperative, 35
potassium intake in, 40
shock in, 33 34
transfusion in, 28
wound healing delay with, 33
Hypotension, hypovolemia with 28
induction by arteriotomy, 65
after pancreatic surgery, 436
in surgery, 68
Hypothermia anesthesia, 65–66, 575–576, 579

Icterus *See* Jaundice
Ileitis, ascending after ileostomy, 589
regional, 495–496
differential diagnosis of, 558, 596
string sign of, 470 496, 558
terminal differential diagnosis of, 558
Ileorectal anastomosis, with colectomy, in polyposis, 606
Ileosigmoidostomy, in colitis, 566, 586
Ileostomy, anal, 573 575
anesthesia in, 74
care of, 586–588
in colitis, 566–589
complications of, 588–589
Dragstedt method, 572–573
end 472–473
Garlock method 571 572
loop, 567
proctocolectomy with, total 567, 575 586
Ravitch method 574
Schneider method 574
simple, 567–573
subtotal colectomy with 566 586
terminal 567
Turnbull method, 568–571
Ileum and jejunum, 466–507
argentaffin tumors of 496
carcinoid tumors of 498
carcinoma of, 497
cholangiojejunostomy, in biliary stricture 387–393
cholecystojejunostomy, 358
choledochojejunostomy 358 386 387
decompression of 470 473 484
by operative means 472 473
by tube, 470–472
diseases of 482–497
diagnosis of, 466–470
fluids and electrolytes in 473 474
treatment of 470–482
diverticula of, 492
after duodenal ulcer surgery 247
duplex, 492
fistulas of 502–505
gastrojejunocolic, with duodenal ulcer, 251–253
foreign bodies of, 494–495
gastrojejunostomy in pancreatitis, 424
hepaticojejunostomy, with enteroanastomosis, 358
jejunoesophageal anastomosis, 236–238
jejunostomy tubes, feeding mixture for, 38
leiomyoma of, 498
lymphoma of, malignant 497
obstruction of, 482–487
antibiotics in, 474
peptic ulcer of, 497
polyps of, 498
excision of, 499, 501
radiology of, 468–470
sarcoma of, 497
surgery of, 474–482
anesthesia in, 474–475
incisions in, 8, 13, 475–479
instruments for, 479
Ileum and jejunum, surgery of (*Continued*)
suture and anastomosis in, 479–482
tuberculosis of, 496
tumors of, 497 502
operative approach in, 499, 500
typhoid ulcers of, 496
wounds of, nonpenetrating 157
penetrating 166, 184
Ileus, adynamic, 487
in pancreatitis 404, 408
postoperative 78 79, 83, 93 95, 635
after trauma, 173, 178
mechanical postoperative 95 97
Iliac vessels incision for, 17
Incarcerated hernia, 152 153
Incisions 1–23
abdominothoracic 231
anatomy 1 6
in appendectomy, 513
in biliary stricture surgery, 378–380
Cherney 18
in cholecystectomy, 329
closure of 21 23
delayed 105–106
in colonic cancer, 537
gridiron 17 513
hernia through 135–140, 142, 149
in ileostomy 567
LaRoque 116 122, 142
lateral m d abdominal muscle splitting, 10–13
left thoracoabdominal 19–20
lower quadrant oblique 16–17
McBurney 11–13, 513
modifications of 12
Marwedel 378, 389
mid line 9 10
muscle splitting 10 14
pain in 8
in pancreatic surgery, 420
paramedian, 9
Pfannenstiel, 17
modification of, 17–18
in proctocolectomy total, 578
rectus muscle splitting, 9, 13
relaxation in hernia repair, 118
right lower quadrant muscle-splitting, 11–13
right thoracoabdominal, 20
right upper oblique, 14–15
right upper quadrant muscle-splitting, 13
Rockey, 12
Rockey-Elliott-Davis, 514
in small bowel surgery, 475–479
in splenectomy, 458

Incisions (*Continued*)
subcostal, 14–16
thoracoabdominal, 18–21 379, 380, 381
transthoracic-transdiaphragmatic, 231
transverse, 14
lateral abdominal muscle splitting, 13
mid-abdominal 15
upper abdominal, 15
types of, 6–21
vertical, 7–10
abdominal, extension of 20–21
Weir, 12
in wound surgery, 180
Infants *See* Pediatrics
Infarction, of spleen, 450
Infections, in abdominal cavity 484
in hypoproteinemia 34
of operative wounds 104
postoperative in biliary tract surgery, 339
in elderly patients, 26
prevention of, 80
septic shock 88
of wounds, 173
Infiltration anesthesia 64
Inguinal hernia, 108–125
Inhalation therapy, postoperative, 90
Insulin, hyperinsulinism and islet cell tumor 437–439
test, after vagotomy 245
Insuloma, 437–439
Intestines, adhesions of 487–488
anastomosis of, 479–482 487
biliary-intestinal, 358–359
clamps for, 475, 479
pancreatic gastrointestinal in pancreatitis, 426
anesthesia in operations, 73
bowels, postoperative elimination, 78
preoperative preparation 49–50
cecum *See* Cecum
choledochoenterostomy in pancreatitis 424
colon *See* Colon
congenital anomalies of, 489–490
decompression of, 79 80, 94, 470–473, 484
after duodenal ulcer surgery 246 247
duodenum *See* Duodenum
enteritis regional *See* Ileitis regional
tuberculous, differential diagnosis of, 558
enterocolitis, differential diagnosis of, 558
postoperative, 97–98
Intestines (*Continued*)
enterogastric reflux, and gastric acidity, 244, 246
enteroliths, 494
enterolysis, in intestinal obstruction, 485
enterostomy, anesthesia in, 73
in intestinal obstruction, 485
in small intestine decompression, 472
Witzel 485, 486
enterotomy anesthesia in, 73
fistula of 502 505
cholecystoenteric 321
after trauma, 173
treatment of 503 505
ileum *See* Ileum and jejunum
ileus *See* Ileus
inflammatory lesions of, 495–496
intussusception, 492–494
jejunum *See* Ileum and jejunum
large intestine *See* Cecum, Colon Rectum
Meckel's diverticulum, 490–492
obstruction of, 482–487
anesthesia in 73
enterolysis in, 485
enterostomy in 485
mortality from, 26
postoperative, 483, 635
small bowel, 466
Peutz Jeghers syndrome 467, 498, 529, 606
pneumatoides intestinalis, 499
rectum *See* Rectum
small intestine *See* Duodenum, Ileum and jejunum
sprue 505–506
sutures for, 476, 479–482
trauma, nonpenetrating 157 161
tubes for, 470 471
vascular lesions of, 489–502
volvulus, 488
water hose kinks in 95
Whipple's disease of 505
Intracranial injury, differential diagnosis of, 196
Intravenous infusions, 38 40
in wound management, 175 191
Intubation *See* Aspiration, Catheterization, Drainage, Decompression Tube
Intussusception, 492–494
ileocolic, 492
ileoileocolic, 492
jejunogastric 492
treatment of, 493–494
Ischiorectal hernia, 148
Islet cell tumors, 437–441, 497
Jackson's veil, 508
Jaundice, 368
in bile duct disorders, 349
delayed, 370
idiopathic, 373
obstructive, 370
in pancreatic carcinoma 432
in pancreatitis, 411, 418
Jejunoesophageal anastomosis, 236–238
Jejunum and ileum, 466–507
*See also* Ileum and jejunum
Johnston tube, 471

Kehr's sign, in splenic rupture 451
Kidney disorders of differential diagnosis of 344
preoperative preparation in 44–45
function of, in anesthesia 67
postoperative 81 82
pyelonephritis after catheterization, 634
wounds of, nonpenetrating 156, 162
penetrating, 166 187
Kink Lane's 489 508
water hose 95
Kocher clamp, 479
Kocher maneuver in pancreatic surgery, 421, 426, 434, 438

Labial hernia, 109 148
Laennec's cirrhosis, 278 369
Lane's kink, 489, 508
Langer's lines 1, 8, 12 14 17
Laparotomies, 6, 21 517
anesthesia in, 73
in pancreatitis, 411
in wound surgery 168 181 183
Large bowel *See* Colon
LaRoque incision 116 122 142
Lavage gastric preoperative 50–51
Leiomyoma, of colon, 529
of retroperitoneum, mesentery and omentum 520
of small bowel 498
of stomach, 209, 217
Leiomyosarcoma of colon 533
of rectum 619
of retroperitoneum mesentery and omentum 521
of small bowel, 497
of stomach, 216
Lembert sutures, 233 234 236
interrupted, 477, 480
Leukemia, retroperitoneal 521
spleen in, 455
Leukocyte count, in appendicitis 510
Levin tube, 471
Lidocaine anesthesia, 61, 181
Lienorenal ligament 444 459

Ligaments *See specific ligaments*
Ligation, of gastric artery, 256, 257–258
of hepatic artery, 303
of pancreatic ducts, 427
Linea alba, hernia in, 134–135
Linea semilunaris, hernia in, 140–141
Lipase levels, in pancreatitis, 407, 417, 418
Lipodystrophy, intestinal, 505
Lipogranuloma of rectum, spontaneous, 619
Lipoid storage diseases, spleen in, 452, 455
Lipoma, of colon, 529
of retroperitoneum, mesentery and omentum, 520
of small bowel, 498
of spermatic cord, differential diagnosis of, 110
of stomach, 209
Lipomul I V, 40
Liposarcoma, of retroperitoneum mesentery and omentum, 521
Lithiasis *See* Calculi
Littre s hernia, 140
Liver, 266 310
abscess, 274–278
amebic, 277
diagnostic aspiration in, 275
drainage of, 276–277
pyogenic, 274–277
adenoma of, 304
anatomy, surgical, 306
in anesthesia, 66
anesthesia in surgery of, 286–287, 307
aspiration, diagnostic, 275
bile duct anomalies, 268
bile secretion, 312, 367
bleeding from, 181, 188, 271–272
cholangiomas, 305
cirrhosis of, 278, 279
*See also* Cirrhosis
in colitis, 559
congenital anomalies of, 266–270
cysts of, congenital, 268–269
echinococcus, 277
ectopic, 266
endotheliomas of, 305
hamartoma of, 304
in hemorrhage, postoperative, 85
hepatic artery, aneurysm of, 270
anomalies of, 270
injury to, 273
ligation of, 303
hepatic vein anomalies, 269
hepaticojejunostomy, with enteroanastomosis, 358
hepatitis cholangiolitic, 366, 372
Liver, hepatitis (*Continued*)
drug, differential diagnosis of, 372
from transfusions, 30, 83
viral, differential diagnosis of, 371
hepatoma, 305
in hypoproteinemia 34
papilloma of, 305
parasitic infestation of, 277–278
portacaval shunts, 280, 283–286
end to side, 287–291
side to side, 292
portal decompression 279–304
anesthesia in, 286–287
ascites formation with, 295
caval superior mesenteric shunts in, 283–286, 292
cholecystectomy with, 303
elective, 280–282
hemicolectomy with 303
hemodynamics of, 283–286
hemorrhage after, 293–294
hepatic artery ligation, 303
hepatic failure after, 294
hypersplenism after, 300–301, 302
mortality from, 293
portacaval shunts, 280, 283–286
postoperative care in, 292–293
prophylactic, 282 283
protein intolerance after, 294, 299
selection of patients for, 279
splenoportography with, 286
splenorenal anastomosis, 282, 283–286, 291 292
technique of, 287
ulcers after, gastric and duodenal, 295
portal hypertension, 455
in children, 302–303
diseases with, 303
and varceal hemorrhage, 278–304
portal vein, 444
congenital anomalies of, 269
incision for, 20
injury to, 273
thrombosis of, 278, 279
preoperative preparation in disorders, 444
resection of, 305–308
ruptured, 174
splenoportography, 286
subhepatic accumulations, after biliary tract surgery, 339
subhepatic infection postoperative, 99
Liver (*Continued*)
syphilitic lesions of, 278
territories of, 268, 306
tuberculosis of, 278
tumors of, 304 308
benign, 304
malignant, 305
metastatic, 305
vascular anomalies of, 269–270
wounds of, 270–274
complications of, 273
hepatic artery, 273
nonpenetrating, 156, 160, 271
penetrating, 166, 188, 271
portal vein, 273
treatment of, 271–273
Lucas Championniere hernia repair, 115, 121
Lumbar block, paravertebral, 64
Lumbar hernia, 149–151
Lungs *See* Respiratory tract
Lupus erythematosus, spleen in, 452
Lymph nodes, blockage of lymphatics in colitis, 549
metastases from carcinoma of pancreas, 420, 421
retroperitoneal, tumors of, 520
Lymphangioma, of retroperitoneum, mesentery and omentum, 520
Lymphoid polyp of rectum, 618
Lymphoma, of colon, 529
gastric, malignant, 216
of small bowel, malignant, 497
spleen in, 455
Lymphosarcoma, of colon, 533
pelvic, differential diagnosis of, 618
of rectum, diffuse submucosal, 618
of retroperitoneum, mesentery and omentum, 521
Lysis of adhesions, intestinal, 485
Lysozyme, in colitis, 549

McBurney incision, 11–13, 513
Malaria, spleen in, 452
Malnutrition *See* Nutritional deficiency
Marwedel incision, 378, 389
Mass casualties, 191–192
Mayo operation for umbilical hernia, 133
Meckel s diverticulum, 490–492
differential diagnosis of, 511
hernia of, 140
incision for, 13
treatment of, 491–492
Melanoma, malignant, of anus, 619, 638
retroperitoneal, 521
Melanosis, in Peutz Jeghers syndrome 498

sac is entered, and the splenic flexure and its mesentery are mobilized to the pancreas The gastrocolic omentum is divided midway to the pyloris to free the transverse colon If the left colon still cannot be pulled down as far as the upper thigh, the splenic flexure division of the middle colic artery may be sectioned close to the pancreas, thus liberating it still further

Since the descending colon and splenic flexure ultimately are to be pulled down through the pelvis, the adequacy of the arterial blood flow in the mesentery of the descending colon above the silk ligature is determined by cutting small marginal vessels near the ligature Only a forceful thrust of blood can be accepted as an adequate flow (Note The sigmoid colon and its complex system of blood vessels are to be sacrificed )

| *Historical eponym* | *Basic objective* | *Fecal continence* |
|---|---|---|
| Type I | | |
| Hochenegg<br>Babcock, Bacon<br>Waugh, Miller, and Kurzweg | To remove entire rectum, to establish coloanal anastomosis, to preserve sphincters | Not true continence, colon continence possible |
| Type II | | |
| Maunsell Weir Swenson and Bill Black | To retain portion of rectum to establish colorectal anastomosis | Complete to partial rectal continence preserved |

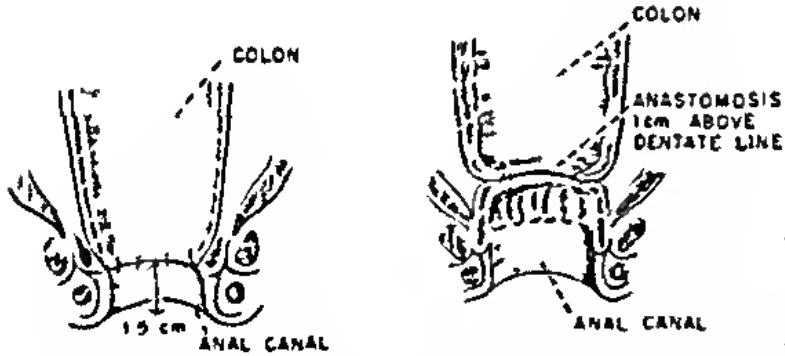


Fig 22 19 Diagrammatic illustration of Type I coloanal (*left*) and Type II colorectal (*right*) pull through anastomoses.

TRANSAL PHASE The patient is now placed in the lithotomy position (the abdomen remains open but covered) The anus is dilated so that three fingers can be inserted and the lower anal pulla is irrigated with saline solution and tincture of benzalkonium chloride (*Zephiran*) (The anal ligature previously placed below the neoplasm prevents contamination with fragments of tumor ) Either type I or type II pull through operation can be carried out

*Type I* (Fig 22-19 ) Three Adair clamps are placed to evert the anal canal A circular incision is made through the dentate line until the rectum is severed at this level The mucosa is picked up with hemostats, and by finger dissection the rectum is freed from the levator sling The rectum and colon are then pulled through the anal canal and the sphincters until the silk ligature around the descending colon is encountered Immediate coloanal anastomosis can be made, or a cuff of the colon may be left protruding until the tenth day, at which time it is dissected free and trimmed and coloanal anastomosis is made with interrupted catgut sutures. Closure of the abdomen is effected as described below under type II There is some tendency of this anastomosis to stricture Therefore, from the end of the second postoperative week a finger should be inserted once daily for three months

*Type II* (Fig 22 20, Lithotomy pos

tion ) After the anus is dilated the rectal mucosa is grasped with Adair clamps and the rectum is evaginated several centimeters The rectum is then severed completely 1 or 2 cm proximal to the dentate (mucocutaneous) line and the recto colonic segment is gently pulled through the residual lower rectal segment. The occluding silk suture around the descending colon again marks the site of resection and colorectal (mucosa to-mucosa) anastomosis is carried out utilizing a one-layer or two-layer anastomosis with interrupted catgut (through all layers) and silk (seromuscular) sutures (Fig 22 21) The completed anastomosis is then pushed back into the pelvis through the sphincters and the patient is returned to the supine position and the abdomen uncovered

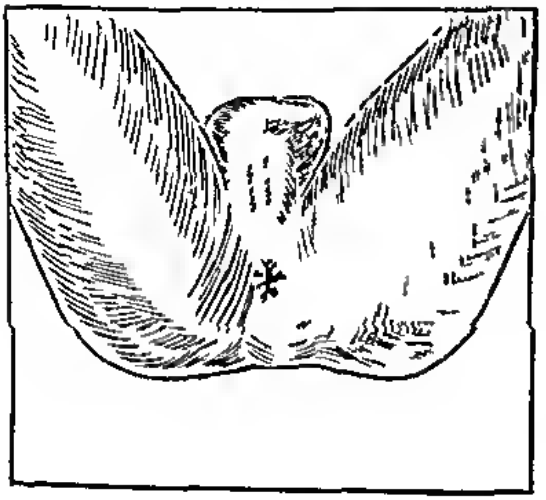

Fig 22 20 When a pull through operation is contemplated the perineal phase of a Type II can be initiated by exposure and transection of the rectum (*dotted line*) proximal to the dentate line By division through the dentate line a Type I procedure can be done




The pelvis is lavaged and blood clots are removed The left lateral extremity of the greater omentum is trimmed away from the displaced splenic flexure (it may become necrotic), the tied inferior mesenteric vascular pedicles are covered with

peritoneum, but the pelvis is not reperitonized, so that accumulated blood may drain back into the peritoneal cavity rather than form an abscess under a reconstructed peritoneal floor No pelvic or sump drains are used A temporary skin-level loop transverse colostomy often is used with type II pull through technique, and is closed on the tenth postoperative day

The abdominal and pelvic phases are carried out as in the Miles operation A double silk ligature is then placed around the rectum below the tumor and the lower ampulla is flushed thoroughly with saline solution and tincture of benzalkonium chloride through an inlying rectal tube The abdominal operator grasps the rectum below the tumor, and steady traction is exerted The anus is thus drawn up between the Levator muscles and is cut across with scissors Minimal bleeding from the anal cuff is controlled by thrusting a folded laparotomy pad down between the levators This pad is withdrawn through the anus on the third postoperative day, and the presacral space is irrigated daily with 1 per cent neomycin solution On the ninth or tenth postoperative day, the space is aspirated of blood clots through a short, sterile rectoscope

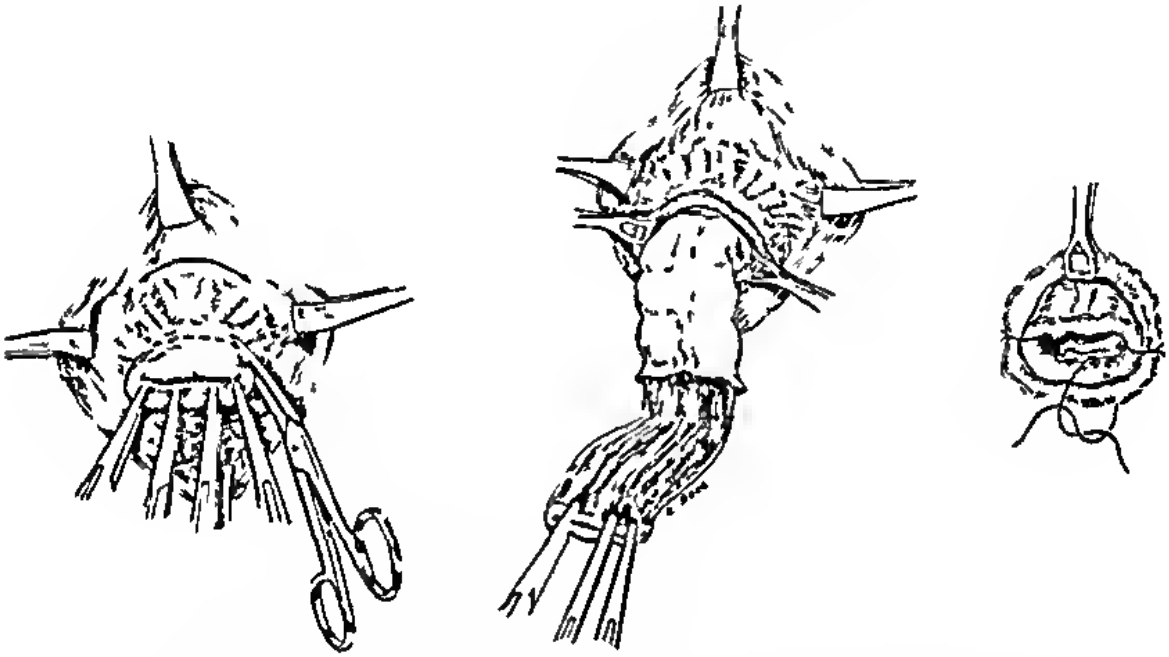

Fig 22-21 Pull through operation Type II (*Left*) Method of eversion and transection of the rectum Dentate line is indicated by arrow (*Center*) Pull through of rectocolic segment (*Right*) Colorectal anastomosis.

### *Anterior Abdominal Resection of the Rectum without Anastomosis (Extended Hartmann Operation)*

Anterior (abdominal) removal of the rectum and the sigmoid colon is the preferred procedure for cancer of the mid-rectum, when the factors of obesity, old age, pelvic deformity, or infirmity make a pull through procedure hazardous or impossible Hartmann has described anterior resection of the rectum with closure of the distal end and the establishment of a permanent colic stoma The 'extended' Hartmann operation results in the abdominal removal of all the rectum to the anal sphincters A colostomy is established

### *Anterior Abdominal Resection of the Rectum with Anastomosis*

Abdominal resection of the rectum with colorectal anastomosis is an adequate

operation for most carcinomas located in the upper third of the rectum, thus the lower border of the lesion should be from 3 to 5 cm above the anterior peritoneal reflection of the rectum In thin patients low resection and anastomosis can be accomplished for lesions located at or near the peritoneal reflection, but the principles of cancer surgery are easily compromised For such lesions the previously described pull through II operation with posterior anastomosis is a more radical procedure and is preferred to an inadequate anterior resection

TECHNIQUE The abdominal and pelvic phases are similar to those in the Miles procedure

The inferior mesenteric and left colic vessels are divided under the third portion of the duodenum and the left colon is transected over a Bainbridge clamp just below the junction of the sigmoid and the descending portion To obtain mobility it may be necessary to free the descending colon and splenic flexure and their mesenteries medially from the left kidney The rectum is lavaged with 100 ml of tincture of benzalkonium chloride injected into the colon above the carcinoma while an indwelling rectal tube drains away the solution below A heavy, double, black silk ligature is tied around the rectum below the carcinoma to occlude the lumen

The posterior mesentery of the distal rectum is cut transversely two inches or more below the tumor until the muscularis is seen Bleeding vessels in the distal rectal fat are then ligated The rectum is then severed, the distal end being supported by guy sutures at the lateral angles The rectal stump will be found empty because of the inlying tube below The end of the descending colon is closed after making sure it will lie in the pelvis without tension An opening is made on the antimesenteric border to equal that of the open rectum (Fig 22 22), and anastomosis with interrupted catgut sutures through all layers is made Interrupted seromuscular sutures are placed anteriorly and finally posteriorly by turning the anastomosis around in the depths of the pelvis The tied stumps of the inferior mesenteric vessels are covered with peritoneum, but the pelvis is never peritonized for reasons stated previously The cecum and terminal ileum are returned to the pelvis first, followed by the rest of the small intestine The abdomen is closed No drains are placed in the pelvis

POSTOPERATIVE CARE Nasogastric suction is maintained for several days to prevent distention of the intestine with fluid or gas A French No 16 Foley catheter is placed in the bladder at the start of the operation and is not removed until the patient is ambulatory

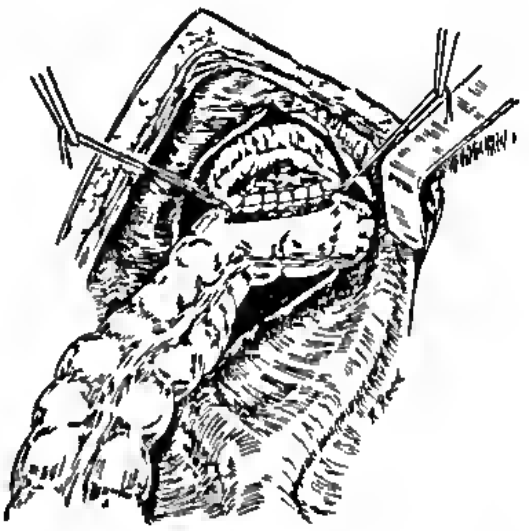

Fig 22 22 Low anterior colorectal anastomosis side to end, technique of Baker

FEEDING The patient is encouraged to eat whenever he wishes, but will not eat substantially until the fourth or fifth postoperative day Fruit juices are banned because they cause intestinal cramps

MEDICATION Penicillin is given postoperatively, while chloramphenicol (Chloromycetin) is used as an alternate. The objective is to discourage bacterial growth at the site of the open anastomosis or in the blood clot that may accumulate in the pelvis. Drugs to prevent or to ameliorate urinary tract infections are administered orally on the fifth postoperative day *Enemas* are avoided until ten days or more after operation However,

Colonic tension is intolerable, the descending colon must be sufficiently mobilized to rise in a gentle curve to traverse the abdominal wall The left gutter is obliterated to prevent volvulus and colocutaneous anastomosis is completed after the abdomen is closed The resultant primary union between the colon and skin prevents prolonged fecal contamination of the pericolostomic subcutaneous fat which so frequently produces stricture

Retraction of the colostomy occurs when peristalsis cannot push a bolus of feces through the aperture of the abdominal wall (Fig 22 23) No method of surgical fixation of the colon or colostomy has prevented retraction under these circumstances Evacuation of the colon prior to operation is an ideal precaution but is not always possible when there is long standing obstruction

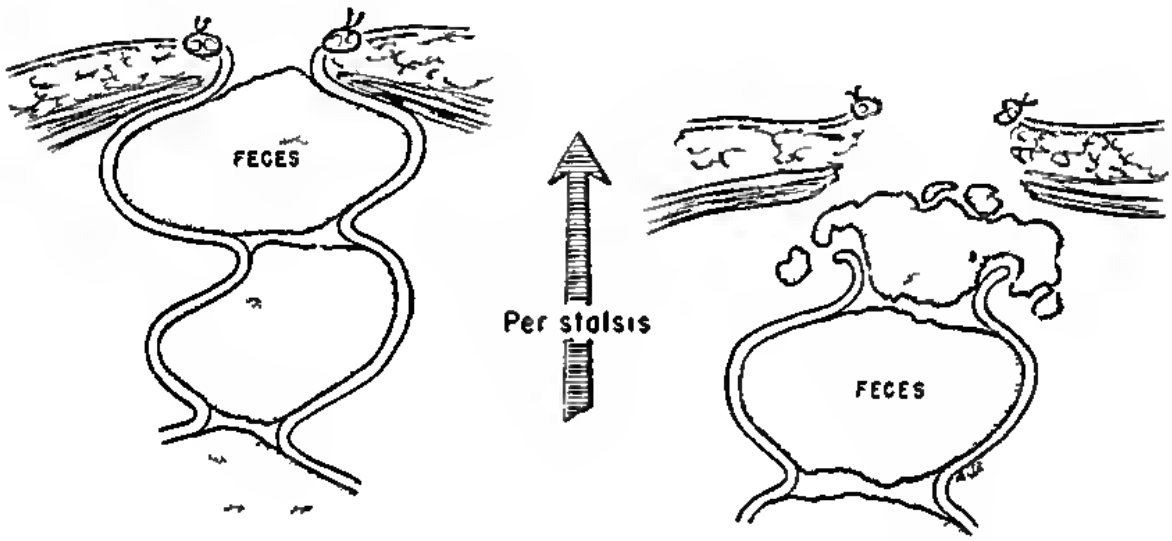


Fig 22 23 The cause of retraction of a colostomy from an impacted bolus of feces

*Wound infections* in intestinal surgery are uncommon because of preventive measures The preparation of the bowel for surgery with low residue diet insoluble antibiotics cathartics and chemical enemas reduces organic intestinal contents to an absolute minimum Impermeable (through and through) wound drapes prevent intestinal contents from coming into contact with the exposed fat of the abdominal wall Occlusive clamps or tapes placed around the bowel proximal to a site of anastomosis prevent spillage of contents

The prevention of wound infection depends upon the technique of the individual surgeon We are certain that the following measures are important avoid trauma to the wound during the operation and closure approximate the wound without tension use monofilament steel alloy sutures absolutely control wound bleeding and lavage the wound with saline constantly during closure

*Contaminated wounds* should not be closed primarily When fecal contamination has occurred deep closure is effected with buried steel wire but the skin and subcutaneous fat should be approximated loosely and gauze wicks should be inserted at intervals. Compartmental drainage of the wound is thus provided for four days by gradual withdrawal of the wicks

Attempts to evacuate the colon preoperatively often are unsuccessful The surgeon who finds himself in this predicament at operation may (1) construct a transverse colostomy and close the abdomen or (2) proceed with the Miles operation and construct the colostomy

through an aperture in the abdominal wall made to equal the greatest diameter of the impacted colon Colocutaneous anastomosis is made and cleansing enemas are begun within a few hours after surgery

The employment of a stomal therapist as a full time member of our team has done much to soften the psychologic blow of colostomy Hospital instruction in care and irrigation of the colostomy has rapidly restored the patients' confidence and ability to return to work The avoidance of colostomy by selecting alternate procedures has also been of utmost importance in reducing morbidity

## Results

The five-year survival rates (Table 22 6) for patients undergoing the Miles operation for cancer of the rectum are remarkably unchanged in the past 20 years Of patients subjected to operation for cure, about 54 per cent remain alive and well at the end of that time Similar survival rates are reported for pull-through operations for carcinomas located 5 cm. or more above the dentate line Our own survival rates for carcinomas of the rectum treated by pull through operations and anterior resection have not been determined in the past five years, however, because of selection, they should be somewhat higher than our rate of survival after the Miles operation

TABLE 22 6 FIVE YEAR POSTOPERATIVE SURVIVAL RATES AFTER SURGICAL TREATMENT OF RECTAL CANCER AT ST MARK'S HOSPITAL, 1928 1952*
(All Operable Cases—3 373)

| *Period* | *Crude five year survival rate %* | *Corrected five-year survival rate %* |
|---|---|---|
| 1928–32 | 49 3 | 56 5 |
| 1933–37 | 46 2 | 54 5 |
| 1938–42 | 46 8 | 54 9 |
| 1943–47 | 53 7 | 63 9 |
| 1948 52 | 46 2 | 56 1 |
| 1928 52 | 48 3 | 57 4 |

*Republished through the courtesy of the Proceedings of the Royal Society of Medicine

## TUMORS OF THE ANUS AND THE ANAL CANAL

Tumors of the anus and of the anal canal require highly specialized treatment They arise from the squamous anal epithelium, and differ in many respects from cancers of the rectum, which arise from the mucosa just above the epithelium Cancers originating in the anal skin comprise about 3 per cent of all cancers of the rectum, they may be listed in two groups according to relative infrequency

*Group A Infrequent Tumors*

1 Anal epithelioma (epidermoid carcinoma)
2 Basal cell carcinoma of anus
3 Carcinoma in situ of anal skin

*Group B Rare Tumors*

1 Extramammary (anal) Paget's disease (intra epithelial carcinoma)
2 Papillary squamous cell carcinoma
3 Malignant melanoma
4 Mucinous adenocarcinoma in anal fistula

*Anal epithelioma* is a squamous cell carcinoma arising from the stratified squamous epithelium of the anal canal, or from the perianal skin The neoplasm that arises in the canal or on the anal margin often is deeply invasive, and may have metastasized by the time that it is discovered Metastasis takes place upward along the perirectal lymphatic channels to the pelvic hypogastric nodes and to the inferior mesenteric lymphatic nodes, also to one or both inguinal areas The tumor may penetrate deeply the perirectal fat or the anal muscles, and cause pain Treatment depends on the size of the lesion and its location, and whether or not metastasis is demonstrated These tumors

are particularly sensitive to roentgen therapy Cobalt 60 teletherapy has given palliation without causing the severe and disabling changes in the skin which occur after conventional external radiotherapy The only hope for cure is by means of a radical Miles operation Dissection of inguinal lymph nodes is resorted to only when nodes are palpable

Squamous-cell cancers arising in the perianal skin at some distance from the anal opening are superficial and rarely metastasize to the regional nodes They are satisfactorily treated by wide local excision

*Basal cell carcinoma* of the anal skin does not metastasize It is easily and effectively excised locally In this regard it is important to know that one half of the circumference of the perianal skin may be removed without risking the formation of a stricture Larger defects are easily covered by split-thickness skin grafts

*Carcinoma in situ in the anal skin* is the diagnosis occasionally reported by the pathologist after a hemorrhoidectomy This diagnosis is not to be viewed with alarm Further surgical treatment is not indicated, instead, the anal skin should be examined at six month intervals Unless there are notably visible premalignant changes in the skin, the occurrence of clinical carcinoma is extremely unlikely The diagnosis of *carcinoma in situ* has been known to occasion the unnecessary removal of the rectum, when the surgeon would have done better to profit by the words of Arthur Allen "I would not remove a rectum for a cancer that I can not see"

*Paget's disease of the anal skin (intraepithelial carcinoma)* is rare In most instances it resembles Paget's disease of the breast, wherein a carcinoma at a higher level has metastasized downward into the anal skin However, it may exist in the absence of a demonstrable primary tumor In *one of our cases a careful examination* was initiated to locate the primary tumor None being found, the entire anal canal, perianal skin, and dentate line were removed, together with the underlying fat A skin graft was applied, suturing the upper end to the mucosa and the lower aspect to remaining perianal skin A good result was obtained, with the patient retaining rectal continence

*Papillary squamous-cell cancer* of the anus is rare If it is polypoid, soft, and nonulcerating, it is cured by local excisional therapy or by mass coagulation Radical surgery seldom is indicated, since these soft superficial tumors rarely metastasize

*Malignant melanoma* of the anus is rare, it follows the same rules of metastasis and survival as elsewhere in the body when it arises in the anal epithelium

*Mucinous adenocarcinoma* occurring in chronic fistulous tracts is rare, and appears to have two separate origins (1) adenocarcinoma of the anal crypt area with fistulous extension into the ischiorectal space and (2) carcinoma arising from epithelial remnants of congenital anal ducts or other vestigial structures One may be led to suspect the diagnosis when thick, jellylike mucus can be expressed from the external os of long standing chronic rectal fistula Papanicolaou spreads made from the mucus may be of diagnostic value but most often have no malignant cells present A vigorous curettage or biopsy of the tract is necessary to establish the diagnosis A combined abdominoperineal resection of the rectum with a radical perineal component may offer the best chance for cure

## REFERENCES


Allen, A W *Personal communication* 1955

Archibald E Operative treatment of cancer of the rectum *J A M A 50* 573, 1908

Babcock, W W Carcinoma of rectum One stage simplified proctosigmoidectomy with formation of perineal anus *S Clin North America 12* 1397, 1932

Bacon, H E Abdominoperineal proctosigmoidectomy for cancer of the rectum *J Nat M A 35* 158, 1943

Bacon, H E Abdominoperineal proctosigmoidectomy with sphincter preservation, five-year and ten year survival after pull

through" operation for cancer of the rectum *J A M A 160* 628, 1956

Barringer, P L, Dockerty, M B, Waugh, J M, and Bargen, J A Carcinoma of large intestine, new approach to study of venous spread *Surg Gynec & Obst 98* 62, 1954

Black, B M Combined abdomino endorectal resection, surgical procedure preserving continuity of bowel, for management of certain types of carcinoma of midrectum and upper part of rectum *Proc Staff Meet Mayo Clin 23* 545, 1948

Broders, A C Squamous cell epithelioma of lip *J A M A 74* 656, 1920

Broders, A C Grading of carcinoma *Minnesota Med 8* 726, 1925

Broders, A C Carcinoma, grading and practical application *Arch Path & Lab Med 2* 376, 1926

Buie, L A Polypoid disease of the colon *Postgrad Med 5* 177, 1949

Cole, W H, Packard, D, and Southwick, H W Carcinoma of the colon with special reference to prevention of recurrence *J A M A 155* 1549, 1954

Coller, F A, Ransom, H K, and Regan, W J, Jr *Cancer of the Rectum for the Physician* (a monograph) American Cancer Society, Inc, 1956, pp 82–83

Cope, V Z, *et al* Discussion on granulomata of large intestine *Proc Roy Soc Med 42* 763, 1949

Crile, G, Jr, and Robnett, A H Primary closure of the posterior wound after combined abdominoperineal resection for carcinoma of the rectum *Cleveland Clin Quart 17* 5, 1950

Daland, E M, Welch, C E, and Nathanson, Ira L One hundred untreated cancers of the rectum *New England J Med 214* 451, 1936

Delaney, L T, Scudamore, H H, and Waugh, J M Symposium on unusual surgical lesions of colon, malignant melanoma of rectum, report of case *Proc Staff Meet Mayo Clin 29* 416, 1954

Dixon, C F, Dockerty, M B, and Powelson, M H Symposium on unusual surgical lesions of colon, squamous cell carcinoma of midrectum report of case *Proc Staff Meet Mayo Clin 29* 420, 1954

Dukes, C E Classification of cancer of rectum *J Path & Bact 35* 323, 1932

Dukes, C E Histological grading of rectal cancer *Proc Roy Soc Med 30* 371, 1937

Dukes, C E Surgical pathology of rectal cancer, president's address *Proc Roy Soc Med 37* 131, 1944

Dukes, C E Discussion on major surgery in carcinoma of rectum with or without colostomy, excluding anal canal and including rectosigmoid general results of surgical treatment *Proc Roy Soc Med 50* 1031, 1957

Dukes, C E Precancerous conditions of the colon and rectum *J Roy Coll Surg Edinburgh 3* 182, 1958

Dukes, C E, and Bussey, H J R Venous spread in rectal cancer *Proc Roy Soc Med 34* 571, 1941

Engell, H C Cancer cells in circulating blood, clinical study on occurrence of cancer cells in peripheral blood and in venous blood draining tumor area at operation *Acta chir scandinav (Supp) 201* 1, 1955

Fisher, E R, and Turnbull, R B, Jr Cytologic demonstration and significance of tumor cells in mesenteric venous blood in patients with colorectal carcinoma *Surg Gynec & Obst 100* 102, 1955

Freeman, J T, and Ravdin, I S Polyps and pigment in the Peutz Jeghers syndrome *New England J Med 253* 958, 1955

Gabriel W B Perineo abdomino excision of rectum in one stage *Lancet 2* 69, 1934

Gabriel, W B, Dukes, C, and Bussey, H J R Lymphatic spread in cancer of the rectum *Brit J Surg 23* 395, 1935–1936

Gilchrist, R K, and David, V C Lymphatic spread of carcinoma of rectum *Ann Surg 108* 621 1938

Glover, R P, and Waugh, J M Retrograde lymphatic spread of carcinoma of rectosigmoid region", its influence on surgical procedures *Surg Gynec & Obst 82* 434, 1946

Grinnell, R S Spread of carcinoma of colon and rectum *Cancer 3* 641, 1950

Grinnell, R S, and Lane, N Collective Review Benign and malignant adenomatous polyps and papillary adenomas of the colon and rectum An analysis of 1,856 tumors in 1,335 patients *Surg Gynec & Obst 106* 519, 1958

Hartmann, H *Chirugie du rectum* Libraries de L'Academie de Medicine Paris, Masson et Cie, Editeurs, 1931, pp 344–355

Hellstrom, J, Hultborn, K A, and Engstedt, L Diffuse cavernous hemangioma of rectum *Acta chir scandinav 109* 277, 1955

Hubbard, T B, Jr. Familial polyposis of the colon the fate of the retained rectum after

Melena, in small bowel disease, 467
Meniscus sign, in gastric ulcer, 206
Mesenchymoma, retroperitoneal, 521
Mesenteric-caval shunts 283 286, 292
Mesenteric veins, 444
Mesentery, adenitis of, differential diagnosis of, 511
  cysts of removal of, 491
  trauma of, nonpenetrating, 161
  tumors of 520 521, 523–524
  vascular occlusion of, 499–502
Metabolism disorders, from anesthesia, 66 67
Metastasis from colonic carcinoma 530 531
  to liver 305
  lymph node from carcinoma of pancreas 420, 421
  of rectal cancer, 613–616
Methitural anesthesia, 55
Metycaine anesthesia, 62
Mikulicz operation, in diverticulitis of colon 599
  pyloroplasty 263
Miles operation in rectal cancer, 621 624 629
  abdominal phase, 624
  colostomy in 620
  pelvic phase 625 628
  perineal phase 628 629
Miller Abbott tube 470–472 536, 544
Mononucleosis infectious spleen in 452
*Morgagni foramen of* 143
Mortality rates 25 27
  with coexisting diseases in surgery 12
  from transfusions, 83
Mucocele of appendix 517
*Mucus, secretion of,* 215
Muscles anatomy of 1 5
  relaxants 56 57
  splitting incisions, 9 10 14
Myoblastoma granular cell, of retroperitoneum, mesentery and omentum 520
Myxoma, retroperitoneal 521

Narcotics preoperative 48, 70
Neck surgery radical, mortality from, 26
Necrosis in pancreatitis, 402
Neosynephrine, in wound management, 176
Nephritic conditions. *See* Kidney
Nerval anesthesia, 55
Nerves anatomy of 5 6
  sensory denervation in pancreatitis, 424
Nesacaine anesthesia, 62
Neurilemmoma, of retroperitoneum, mesentery and omentum, 520
Neurofibroma, of retroperitoneum, mesentery and omentum, 520
Neurofibrosarcoma, of small bowel, 498
Neuroma, cystic duct, postoperative, 343
Neutropenia, antibiotics in, *458*
  in Felty's syndrome, 456
  primary splenic, 454–455
Niemann Pick disease, spleen in, 452
Nitrogen balance, postoperative, 39
Nitrous oxide anesthesia, 55–56
Nutrition, in cirrhosis of liver, 281
  in colitis, 562
  intravenous alimentation, 38–40, 175, 191
  nasogastric tube feeding, 37 38
  in pancreatitis 419, 420
  preoperative, 49
Nutritional deficiency, 36
  in aged, 26
  in colitis 549
  hypoproteinemia, 32–40
  in pancreatitis, 410
  sprue 505 506
  vitamin deficiencies 40–41
  Whipple's disease, 505

Obese patients, 13 22, 23
  and diverticulitis of colon 592, 596
  and pancreatitis, 416
Obstructed hernia, 153
Obstruction, intestinal, 482 487
  small bowel, 466
Obturator hernias, 151–152
Oddi, sphincter of 312
  sphincterotomy 342–343 360 362, 423
Oleoma, submucosal, of rectum 619
Omentum, tumors of, 520 521 523–524
Omphalocele, 130–134
Oral surgery, radical, mortality from, 26
Osler-Vaquez disease 467
Ovary, cyst of, differential diagnosis of, 511, 595
  incision for lesions of, 13
  wounds of, penetrating, 163

Pages's disease, of anus 638
Pain, in appendicitis, 509
  in biliary tract, 340
  after cholecystectomy, 340, 344
  in cholecystitis, 323
  in colitis, 554
Pain (*Continued*)
  in colonic diverticulitis, 593
  in duodenal ulcer, 205
  in gastric cancer, 205
  in gastric ulcer, 205
  incisional, 8
  in intestinal obstruction, 482
  in pancreatic carcinoma, 432
  in pancreatitis, 402–403, 410, 416, 424
  in retroperitoneal tumors, *520*
  in small bowel disease, 467
Pancreas, 399–442
  aberrant, 209
  acute pancreatitis, 401–413
    amylase levels in, 401, 405 407
    calcium deficiency in, 410
    common channel theory of, 402
    complications, prevention of, 410–411
    convalescent management in, 411
    diabetes in, 411
    diagnosis of, 402–404
    differential diagnosis of, 327
    *edema in,* 402
    hemorrhage in 402, 410
    incidence of, 401
    jaundice in, 411
    laboratory aids in, 405–407
    lipase levels in, 407
    *necrosis in,* 402
    pain in 402–403, 410
    paracentesis in, 407
    pathology of, 402
    roentgenology in, 404–405
    treatment of, 407–413
      *cholecystostomy,* 412
      corticosteroids, 410
      drainage, 412
      fluid replacement, 407 409
      laparotomy, 411
      rest, *409*
      surgery, 412–413
    vomiting in, 404
  adenoma of, islet, 439–441
  anesthesia in surgery of, 73
  annular 399–400
  after biliary tract surgery, 340
  biopsy of, 421, 433 434
  carcinoma of, 431–437
    lymph node metastases from, 420, 421
    surgical technique in, 433 437
  chronic pancreatitis, 414 431
    amylase levels in, 417, 418
    calcification in, 416, 417, 421, 425
    cirrhosis with, 418
    complications of, *418–419*
    cyst formation in, 416, 421 428 430

Pancreas, chronic pancreatitis (*Continued*)
diabetes in, 415
diagnosis of, 414–415, 416–418
ductal obstruction in, 416, 421
duodenal aspiration in, 418
enzyme decrease in, 418
fibrosis in, 415, 421
fistula with, 430
jaundice in, 418
lipase levels in, 417, 418
pain in, 416, 424
pathology of, 415–416
peptic ulcer with, 419
preoperative preparation in, 419–420
recurrent, after cholecystectomy, 342–343
roentgenology in, 417
stage one, 421
stage three, 423
stage two, 423
steatorrhea in, 415, 418
treatment of, 419–431
anastomosis, retrograde, 426–427
biliary tract surgery, 423–424
cholecystectomy, 423
choledochoenterostomy, 424
choledochostomy, 423
diet, 419
direct procedures, 425–431
drainage of cysts, 429–430
ductal dilatation, 425
ductal drainage, postoperative, 424
gastrectomy, 424
gastric operations, 424
gastrojejunostomy, 424
indirect operations, 423–425
ligation of pancreatic ducts, 427
longitudinally opened pancreatic duct, 427
pancreatectomy, 425, 427
pancreatoduodenectomy, 427
sensory denervation, 424–425
sphincterotomy, 423
surgery, 419–431
vagotomy, 424
tuberculosis with, 419
cysts of, 431
neoplastic, 431
parasitic, 431
retention, 431
differential diagnosis of pancreatitis, 511
ductal anatomy, 399

Pancreas (*Continued*)
after duodenal ulcer surgery, 247
ectopic tissue, 400
exploration of, 421
hyperplasia of islet cells in infants, 438, 439
incision for, 15, 420
necrosis, after gastrectomy, 229
pancreatectomy, subtotal, 425
total, 427
pancreatic arteries, 443, 459
pancreatin in pancreatitis, 419
pancreatoduodenectomy, 427, 432
pancreatography, 423, 424
postoperative pancreatitis, 413
pseudocysts of, 414, 415, 416, 417, 421, 428–430
sphincterotomy in pancreatitis, 342–343, 360
traumatic pancreatitis, 413–414
tumors of, 431–441
ampulla of Vater, 437
islet cell 437–441, 497
and hyperinsulinism 437–439
and peptic ulcer, 439–441
wounds of nonpenetrating, 157 161
penetrating 166 189
Panhematopenia, primary splenic 455
Papilloma of liver, 305
Paracentesis, abdominal, in trauma 159
in pancreatitis diagnosis 407
Paraganglioma, of retroperitoneum mesentery and omentum 520
Parasitic cysts *See* Echinococcus cyst
Payr clamp, 256, 258
Pediatrics, anesthesia in 70
appendicitis, 516 517
bile duct anomalies, 268 397
inguinal hernia repair, 124
intestinal abnormalities, congenital, 489
intussusception, 492–494
pancreatic islet cell hyperplasia, 438, 439
pancreatitis, 401
portal hypertension, 302–303
pyloric stenosis, 13, 195–197
umbilical hernia, 131
*See also* Congenital conditions
Pelvis, hernia of, 148
incision for surgery of, 9, 13, 17
inflammatory disease of, differential diagnosis of, 511
Pepsin, 245

Pepsinogen, 245
Perforation, in colitis, 560, 563
of colon, in diverticulitis, 593, 596, 598
of duodenal ulcer, 248, 249
of gastric carcinoma, 215
of gastric ulcer, 207
of viscus, anesthesia in, 72
Perineum, abdominoperineal resection, in rectal tumors, 621, 624 629
delayed wound healing of, 635
hernia of, 148–149
Peristalsis, in appendicitis, 510
in small bowel obstruction, 468
after trauma, 178
Peritoneoscopy, in trauma, 169
Peritoneum, closure in wound surgery, 183
coping with infection, 484
postoperative infections of, 98 101
retroperitoneal syndrome, 169
*See also* Retroperitoneum
in trauma, nonpenetrating, 157 158
Peritonitis, appendiceal, 515–516, 517
postoperative 98
in wounds penetrating, 173
Petit's triangle, hernia through, 149
Peutz Jeghers syndrome, 467, 498 529, 606
Pfannenstiel incision, 17
modification of, 17 18
Pheochromocytoma 520
differential diagnosis of, 314
Phlebothrombosis, postoperative, 101, 103–104
Phrenic conditions *See* Diaphragm
Phrenicocolic ligament, 444, 459
Phrenicolienal ligament, 444, 459
Piperocaine anesthesia, 62
Plasmocytoma, mesenteric, 521
Platelets, deficiency of, 86
transfusions, in thrombocytopenia, 458
Pneumography, extraperitoneal, 521
Pneumonectomy, mortality from, 26
Pneumonia, postoperative, 90–91
Pneumoperitoneum, artificial, before hernia repair, 139–140
Polyps, of colon, adenomatous, 525 529
intestinal, familial, 529
in Peutz-Jeghers syndrome, 606
pseudopolyposis in colitis, 551, 553, 555, 561, 606, 610
of rectum, 607–610
familial, 605–607
lymphoid, 618

Polyps (*Continued*)
of small bowel, 498, 199, 501
of stomach, 209
Pontocaine anesthesia, 61
Portal conditions *See* Liver
Position of patient, postoperative, 89
Postoperative care and complications, 77–106
activity of patient, 78–79
antibiotic therapy, 80
atelectasis, 89–90, 92
bowel elimination, 78
carbon dioxide poisoning, 89
care of patient, 77–84
cholecystitis, 98
in colonic cancer, 544
after colostomy 634, 635 636
complications, 84–106
decompression, gastrointestinal, 79–80
portal, 292–293
dilatation, acute gastric, 93
Douglas cul-de sac infection, 100
edema, pulmonary, 92
embolism, pulmonary 91–92
enterocolitis, 97–98
fluids and electrolytes, 78, 80–83
in gallbladder surgery, 336–338
hemorrhage 85
ileus, adynamic 93–95
mechanical 95 97
intestinal obstruction 483 635
kidney function, 81, 82
liver function 85
medication, 79
orders, changing of, 78
after pancreatic surgery 436
pancreatitis 413
peritoneal infections, 9d–101
phlebothrombosis, 101, 103–104
pneumonia 90–91
pulmonary complications, 89–93
in rectal cancer surgery 634–637
shock 86 89
in adrenal insufficiency 87–88
cardiac basis of, 89
hypovolemic, 87
septic 88
in splenectomy, 462–463
subhepatic infection, 99
subphrenic infection, 99
thrombophlebitis, 101, 102–103
thrombosis venous, 101–104
transfusions 83–84
urinary tract problems, 79, 634
wound complications, 104–106, 636
in wound surgery, 190–191
Potassium, intake in hypoproteinemia, 40
intoxication in transfusions, 31
postoperative loss of, 81–82
Poupart's ligament, in hernia repair, 117, 118, 120, 127, 129
Pregnancy, appendicitis in, 516
bile stasis in, 317
Preoperative preparation, 24–52
anemic patients, 27
anticoagulant medicines, 50
asthmatic patients, 46–47
in biliary stricture operations 376
bowel preparation, 49–50
catheters, indwelling 51
in colonic carcinoma, 535
correction of systemic deficits, 27–41
diabetes mellitus, 47–48
diet, 49
evaluation of patient, 24–27
in gallbladder disease 327
gastric lavage 50–51
in heart disease, 43–44
hypoproteinemia 28 32–40
kidney function defects 44–45
liver damage 44
older patients, 25–27
in pancreatic carcinoma 433
in pancreatitis, 419–420
preanesthetic medication 48–49, 70
pulmonary diseases, 45–47
systemic diseases of patients 41–48
transfusions, 27–32
vaginal preparation, 51
vitamin deficiencies, 40–41
Pressure packs in liver hemorrhage, 272
Procaine anesthesia, 61 181
Proctology *See* Rectum
Prolapse, of gastric mucosa 202–203
after ileostomy, 588–589
Prostate, carcinoma of, differential diagnosis of, 617
Prostheses, in biliary stricture repair, 393–395
in hernia repair, 120
Protein, depletion of *See* Hypoproteinemia
disorders, with colitis 559
intolerance, after portal decompression, 294, 299
metabolism, in anesthesia, 66
Prothrombin time, defects of, 40 50
in liver disease 281
in pancreatic disease, 420, 433
Pseudocysts, pancreatic, 414, 415, 416, 417, 421, 428–430
Pseudopolyposis, in colitis, 551, 553, 555, 561, 606, 610
Psoas abscess differential diagnosis of, 127
Psychological factors, in colitis, 550
Pudendal hernia, 148
Pull-through operations, in rectal tumors, 629–632
Pulmonary conditions *See* Respiratory tract
Purpura, idiopathic thrombocytopenic, 453–454
Pyelonephritis, after catheterization, 634
Pyloroduodenostomy, in duodenal ulcer 263
Pyloromyotomy, Ramstedt, 11, 196–197
Pyloroplasty, in duodenal ulcer, 263
Pylorospasm, differential diagnosis of, 196
Pylorus antrum, in gastric secretion, 244
obstruction, with duodenal ulcer, 250
in gastric carcinoma, 215
in gastric ulcer, 208
ulcerogenic, 243
stenosis, congenital, hypertrophic, 195–197
incision for, 11, 13
treatment of, 196–197
Pyoderma gangrenosum, in colitis 560

Radioactive isotopes, in hemolytic anemia, 456
in pancreatitis, 418
Radiology, cholangiography, intravenous, 350, 354–355
cholecystography, 324
choledochogram, postoperative, 356–358
in colitis 555–556
in diverticulitis of colon, 594
in gastric carcinoma, 213
in gastric ulcer, 205–206
in intussusception, 493
in pancreatitis, 404–405, 417
pancreatography, 423
in retroperitoneal tumors, 521
in small bowel disorders, 468–470
splenoportography, 286, 444 453
in trauma, nonpenetrating 159
*See also specific procedures*
Ramstedt operation for pyloric stenosis, 11, 196–197
Ravitch ileostomy, 574
Rectum, actinomycosis of, 619
adenocarcinoma of, 611
adenomatous tumors of 607 610
amebic granulomas of, 620
carcinoid tumor of, 618

Rectum (*Continued*)
carcinoma of, anaplastic, 612
colloid, 612
diffuse, 611
exophytic, 611
multiple, 605
spread of, 613–616
lymphatic drainage, 614
peritoneal, 616
regional lymph nodes, 614–615
venous channels, 615–616
squamous-cell, 619
stenosing, 611, 612
ulcerating sessile, 611, 612
ileorectal anastomosis with colectomy, in polyposis, 606
leiomyosarcoma of, 619
lipogranuloma of, spontaneous 619
oleoma of, submucosal, 619
polyp of, benign, 607
carcinomatous foci in, 609
lymphoid, 618
malignant, 609
polypoid hypertrophy of mucosa, 606
polyposis, familial, 605–607
proctectomy, with sigmoid colostomy, in colitis, 566
proctocolectomy, total, with ileostomy, in colitis, 567, 575–586
resection, mortality from, 26
syphilitic lesions of, 620
tenesmus, in colitis, 554
tuberculosis of, 619
tumors of, 604–637
and colitis, 606, 610
diagnosis of, 616–620
differential diagnosis of 617–620
etiology of, 605
incidence of, 604
pathology of, 611–613
precancerous lesions, 605–611
signs and symptoms of, 616
site of growth, 605
treatment of, 620–634
colorectal anastomosis, 632–634
Hartmann operation, extended, 622, 632
Miles operation, 621, 624–629
pull-through operations, 629–632
ulcer of, from radiation, 620
varicosities of, 618
wound of, penetrating, 166, 185, 187
Rectus muscle, relaxation incision in, 118
Reflex activity in surgery, 67–68
Regurgitation, alkaline, after duodenal ulcer surgery, 247
biliary, 367
Relaxants, muscle, 56–57
Relaxation incision, in hernia repair, 118
Renal conditions *See* Kidney
Resection, abdominoperineal, in rectal tumors, 621, 624–629
of liver, 305–308
pancreatic, subtotal, 425
*See also specific procedures*
Respiratory tract, atelectasis, postoperative, 89–90, 92–93
bronchiectasis, preoperative care in, 46
bronchopulmonary disease, preoperative care in, 45–47
edema, pulmonary, postoperative 92
embolism, pulmonary postoperative, 91–92
emphysema, pulmonary, preoperative care in 46
pneumography, 521
pneumonectomy, mortality from, 26
pneumonia, postoperative 90–91
pneumoperitoneum artificial, before hernia repair 139–140
postoperative complications in, 89 93
preoperative preparation in disorders of, 45–47
respiration control, in anesthesia, 69
in liver disease, 287
Reticuloendothelial cell sarcoma spleen in, 455
Reticulum cell sarcoma, of small bowel, 498
Retroperitoneum, exposure of, 13, 16–17
tumors of, 519–523
diagnosis of, 521
prognosis of, 522
symptoms of, 520
treatment of, 521 522
Rhabdomyosarcoma, retroperitoneal, 521
Richter's hernia, 140
Rockey incision, 12
Rockey Elliott Davis incision, 514
Roentgenology *See* Radiology
Rotation, abnormal intestinal, 489
Ruggi hernia repair, 129
Rupture, of appendix, 512
of corpus hemorrhagicum, differential diagnosis of, 511
Rupture (*Continued*)
of spleen, 451–452, 462
of uterus, 157, 162
*See also* Wounds, nonpenetrating

Sacrococcygeal chordoma, 533
Salpingitis, differential diagnosis of, 595
Santorini, duct of, 399
Saphenous varix, differential diagnosis of, 127
Sarcoidosis, spleen in, 452, 455
Sarcoma, gastric, 216–217
reticuloendothelial cell, spleen in, 455
of small bowel, 497
Schatzki small intestinal enema technique, 469
Schneider ileostomy, 574
Schwannoma, malignant, retroperitoneal, 521
Sciatic hernia, 147–148
Scoops, common duct, 350, 351, 352 353, 354
Scopolamine, preanesthetic, 70
Scrotal hernia, 109, 123
Secretin effects on pancreas 417 418
Sedatives postoperative, 79
preoperative, 48–49, 70
Serotonin, in argentaffin tumors, 498
from carcinoid tumor of colon, 532
Shock, in adrenal insufficiency postoperative, 87–88
compensated, 179
in hypoproteinemia, 33 34
hypovolemic, postoperative, 87
in peritoneal contamination, 169
postoperative, 86–89
septic postoperative, 88
transfusions in, 28
in trauma 157, 178–179
Shunts *See* Anastomosis
Sigmoid colon *See* Colon
Skin, anatomy of, 1
care of, in fistulas, intestinal, 504
excoriation after ileostomy 588
lesions in colitis, 559
Small intestine, 242 265, 466–507
*See also* Duodenum Ileum and jejunum
Sodium levels after portal decompression, 293
Sounds, in small bowel obstruction, 468
Spermatic cord, in hernia repair, 118–119
lipoma of, differential diagnosis of, 110
Spherocytosis, hereditary, 454

Melena, in small bowel disease, 467
Meniscus sign, in gastric ulcer, 206
Mesenchymoma, retroperitoneal, 521
Mesenteric-caval shunts, 283–286, 292
Mesenteric veins, 444
Mesentery, adenitis of, differential diagnosis of, 511
  cysts of, removal of, 491
  trauma of, nonpenetrating, 161
  tumors of 520, 521, 523–524
  vascular occlusion of, 499–502
Metabolism disorders, from anesthesia, 66–67
Metastasis from colonic carcinoma, 530–531
  to liver, 305
  lymph node, from carcinoma of pancreas, 420, 421
  of rectal cancer, 613–616
Methitural anesthesia, 55
Metycaine anesthesia, 62
Mikulicz operation, in diverticulitis of colon, 599
  pyloroplasty, 263
Miles operation in rectal cancer, 621, 624–629
  abdominal phase, 624
  colostomy in, 628
  pelvic phase 625–628
  perineal phase, 628 629
Miller Abbott tube, 470–472, 536, 544
Mononucleosis, infectious, spleen in, 452
Morgagni foramen of, 143
Mortality rates, 25–27
  with coexisting diseases in surgery, 42
  from transfusions, 83
Mucocele, of appendix, 517
Mucus secretion of, 245
Muscles, anatomy of, 1–5
  relaxants 56–57
  splitting incisions, 9, 10–14
Myoblastoma, granular cell, of retroperitoneum, mesentery and omentum, 520
Myxoma, retroperitoneal, 521

Narcotics, preoperative, 48, 70
Neck surgery, radical, mortality from, 26
Necrosis, in pancreatitis, 402
Neosynephrine, in wound management, 176
Nephritic conditions *See* Kidney
Neraval anesthesia, 55
Nerves, anatomy of, 5–6
  sensory denervation in pancreatitis, 424
Nesacaine anesthesia, 62
Neurilemmoma, of retroperitoneum, mesentery and omentum, 520
Neurofibroma, of retroperitoneum, mesentery and omentum, 520
Neurofibrosarcoma of small bowel, 498
Neuroma, cystic duct, postoperative, 343
Neutropenia, antibiotics in, 458
  in Felty's syndrome, 456
  primary splenic, 454–455
Niemann-Pick disease, spleen in, 452
Nitrogen balance, postoperative, 39
Nitrous oxide anesthesia, 55–56
Nutrition, in cirrhosis of liver, 281
  in colitis, 562
  intravenous alimentation, 38–40, 175, 191
  nasogastric tube feeding, 37–38
  in pancreatitis, 419, 420
  preoperative, 49
Nutritional deficiency, 36
  in aged, 26
  in colitis, 549
  hypoproteinemia, 32–40
  in pancreatitis, 410
  sprue, 505–506
  vitamin deficiencies, 40–41
  Whipple's disease, 505

Obese patients, 13, 22, 23
  and diverticulitis of colon, 592, 596
  and pancreatitis, 416
Obstructed hernia 153
Obstruction, intestinal, 482–487
  small bowel, 466
Obturator hernias, 151–152
Oddi, sphincter of, 312
  sphincterotomy, 342 343, 360, 362, 423
Oleoma, submucosal, of rectum, 619
Omentum, tumors of, 520, 521, 523 524
Omphalocele, 130–134
Oral surgery, radical, mortality from, 26
Osler Vaquez disease, 467
Ovary, cyst of, differential diagnosis of, 511, 595
  incision for lesions of, 13
  wounds of, penetrating, 188

Paget's disease, of anus, 638
Pain, in appendicitis, 509
  in biliary tract, 340
  after cholecystectomy, 340, 344
  in cholecystitis, 323
  in colitis, 554
Pain (*Continued*)
  in colonic diverticulitis, 593
  in duodenal ulcer, 205
  in gastric cancer, 205
  in gastric ulcer, 205
  incisional, 8
  in intestinal obstruction, 482
  in pancreatic carcinoma, 432
  in pancreatitis, 402–403, 410, 416, 424
  in retroperitoneal tumors, 520
  in small bowel disease, 467
Pancreas, 399–412
  aberrant, 209
  acute pancreatitis, 401–413
    amylase levels in, 401, 405–407
    calcium deficiency in, 410
    common channel theory of, 402
    complications, prevention of, 410–411
    convalescent management in, 411
    diabetes in, 411
    diagnosis of, 402–404
    differential diagnosis of, 327
    edema in, 402
    hemorrhage in, 402, 410
    incidence of, 401
    jaundice in, 411
    laboratory aids in, 405–407
    lipase levels in, 407
    necrosis in, 402
    pain in, 402–403, 410
    paracentesis in, 407
    pathology of, 402
    roentgenology in, 404–405
    treatment of, 407–413
      cholecystostomy, 412
      corticosteroids, 410
      drainage, 412
      fluid replacement, 407–409
      laparotomy, 411
      rest, 409
      surgery, 412–413
    vomiting in, 404
  adenoma of, islet, 439–441
  anesthesia in surgery of, 73
  annular, 399–400
  after biliary tract surgery, 340
  biopsy of, 421, 433–434
  carcinoma of, 431–437
    lymph node metastases from, 420, 421
    surgical technique in, 433–437
  chronic pancreatitis, 414–431
    amylase levels in, 417, 418
    calcification in, 416, 417, 421, 425
    cirrhosis with, 418
    complications of, 418–419
    cyst formation in, 416, 421, 428–430

Pancreas, chronic pancreatitis (*Continued*)
diabetes in, 415
diagnosis of, 414–415, 416–418
ductal obstruction in, 416, 421
duodenal aspiration in, 418
enzyme decrease in, 418
fibrosis in, 415, 421
fistula with, 430
jaundice in, 418
lipase levels in, 417, 418
pain in, 416, 424
pathology of, 415–416
peptic ulcer with, 419
preoperative preparation in, 419–420
recurrent, after cholecystectomy, 342 343
roentgenology in, 417
stage one, 421
stage three, 423
stage two, 423
steatorrhea in, 415, 418
treatment of, 419–431
anastomosis, retrograde, 426–427
biliary tract surgery, 423–424
cholecystectomy, 423
choledochoenterostomy, 424
choledochostomy, 423
diet, 419
direct procedures, 425–431
drainage of cysts, 429–430
ductal dilatation, 425
ductal drainage, post operative, 424
gastrectomy 424
gastric operations, 424
gastrojejunostomy, 424
indirect operations, 423–425
ligation of pancreatic ducts, 427
longitudinally opened pancreatic duct, 427
pancreatectomy, 425, 427
pancreatoduodenectomy, 427
sensory denervation, 424–425
sphincterotomy, 423
surgery, 419–431
vagotomy, 424
tuberculosis with, 419
cysts of, 431
neoplastic, 431
parasitic, 431
retention, 431
differential diagnosis of pancreatitis, 511
ductal anatomy, 399
Pancreas (*Continued*)
after duodenal ulcer surgery, 247
ectopic tissue, 400
exploration of, 421
hyperplasia of islet cells in infants, 438, 439
incision for, 15, 420
necrosis, after gastrectomy, 229
pancreatectomy subtotal, 425
total, 427
pancreatic arteries 443, 459
pancreatin in pancreatitis, 419
pancreatoduodenectomy 427, 432
pancreatography 423, 424
postoperative pancreatitis, 413
pseudocysts of 414, 415, 416, 417, 421, 428 430
sphincterotomy in pancreatitis, 342–343, 360
traumatic pancreatitis, 413–414
tumors of, 431–441
ampulla of Vater, 437
islet cell, 437–441, 497
and hyperinsulinism, 437–439
and peptic ulcer, 439–441
wounds of, nonpenetrating, 157, 161
penetrating 166, 189
Panhematopenia primary splenic, 455
Papilloma, of liver 305
Paracentesis, abdominal in trauma, 159
in pancreatitis diagnosis, 407
Paraganglioma, of retroperitoneum, mesentery and omentum 520
Parasitic cysts *See* Echinococcus cyst
Payr clamp, 256, 258
Pediatrics anesthesia in 70
appendicitis, 516 517
bile duct anomalies, 268, 397
inguinal hernia repair, 124
intestinal abnormalities, congenital, 489
intussusception, 492–494
pancreatic islet cell hyperplasia, 438, 439
pancreatitis, 401
portal hypertension, 302–303
pyloric stenosis, 13, 195–197
umbilical hernia, 131
*See also* Congenital conditions
Pelvis, hernia of, 148
incision for surgery of, 9, 13, 17
inflammatory disease of, differential diagnosis of, 511
Pepsin, 245
Pepsinogen, 245
Perforation, in colitis, 560, 563
of colon, in diverticulitis, 593, 596, 598
of duodenal ulcer, 248, 249
of gastric carcinoma 215
of gastric ulcer, 207
of viscus, anesthesia in, 72
Perineum, abdominoperineal resection, in rectal tumors, 621, 624 629
delayed wound healing of, 635
hernia of, 148–149
Peristalsis, in appendicitis, 510
in small bowel obstruction, 468
after trauma, 178
Peritoneoscopy, in trauma, 169
Peritoneum, closure in wound surgery, 183
coping with infection, 484
postoperative infections of, 98 101
retroperitoneal syndrome, 169
*See also* Retroperitoneum
in trauma, nonpenetrating, 157 158
Peritonitis appendiceal, 515–516 517
postoperative 98
in wounds, penetrating, 173
Petit's triangle hernia through, 149
Peutz Jeghers syndrome, 467, 498, 529 606
Pfannenstiel incision, 17
modification of 17 18
Pheochromocytoma 520
differential diagnosis of 314
Phlebothrombosis, postoperative 101, 103 104
Phrenic conditions *See* Diaphragm
Phrenicocolic ligament, 444, 459
Phrenicolienal ligament 444, 459
Piperocaine anesthesia, 62
Plasmocytoma mesenteric, 521
Platelets, deficiency of, 86
transfusions, in thrombocytopenia, 458
Pneumography, extraperitoneal, 521
Pneumonectomy, mortality from, 26
Pneumonia, postoperative, 90–91
Pneumoperitoneum, artificial, before hernia repair, 139–140
Polyps, of colon, adenomatous, 525–529
intestinal, familial, 529
in Peutz Jeghers syndrome, 606
pseudopolyposis in colitis, 551, 553, 555, 561, 606, 610
of rectum, 607–610
familial, 605–607
lymphoid, 618

Polyps (*Continued*)
of small bowel, 498, 499, 501
of stomach, 209
Pontocaine anesthesia, 61
Portal conditions *See* Liver
Position of patient, postoperative, 89
Postoperative care and complications, 77–106
activity of patient, 78–79
antibiotic therapy, 80
atelectasis, 89 90, 92
bowel elimination, 78
carbon dioxide poisoning, 89
care of patient, 77–84
cholecystitis, 98
in colonic cancer, 544
after colostomy, 634, 635–636
complications, 84–106
decompression, gastrointestinal, 79 80
portal, 292–293
dilatation, acute gastric, 93
Douglas cul-de sac infection, 100
edema, pulmonary, 92
embolism, pulmonary, 91–92
enterocolitis, 97–98
fluids and electrolytes, 78, 80–83
in gallbladder surgery, 336–338
hemorrhage, 85
ileus, adynamic, 93–95
mechanical, 95–97
intestinal obstruction, 483 635
kidney function, 81, 82
liver function, 85
medication, 79
orders, changing of, 78
after pancreatic surgery, 436
pancreatitis, 413
peritoneal infections, 98–101
phlebothrombosis, 101, 103 104
pneumonia, 90–91
pulmonary complications, 89–93
in rectal cancer surgery, 634–637
shock, 86–89
in adrenal insufficiency, 87–88
cardiac basis of, 89
hypovolemic, 87
septic, 88
in splenectomy, 462–463
subhepatic infection, 99
subphrenic infection, 99
thrombophlebitis, 101, 102–103
thrombosis, venous, 101–104
transfusions, 83–84
urinary tract problems 79, 634
wound complications, 104–106, 636
in wound surgery, 190–191
Potassium, intake in hypoproteinemia, 40
intoxication in transfusions, 31
postoperative loss of, 81–82
Poupart's ligament, in hernia repair, 117, 118, 120, 127, 129
Pregnancy, appendicitis in, 516
bile stasis in, 317
Preoperative preparation, 24–52
anemic patients, 27
anticoagulant medicines, 50
asthmatic patients, 46–47
in biliary stricture operations 376
bowel preparation, 49–50
catheters, indwelling, 51
in colonic carcinoma 535
correction of systemic deficits, 27–41
diabetes mellitus, 47–48
diet, 19
evaluation of patient, 24–27
in gallbladder disease, 327
gastric lavage, 50–51
in heart disease, 43–44
hypoproteinemia 28, 32–40
kidney function defects, 44 45
liver damage, 44
older patients, 25–27
in pancreatic carcinoma, 433
in pancreatitis, 419–420
preanesthetic medication, 48–49, 70
pulmonary diseases 45–47
systemic diseases of patients 41–48
transfusions, 27 32
vaginal preparation, 51
vitamin deficiencies, 40–41
Pressure packs, in liver hemorrhage, 272
Procaine anesthesia, 61, 181
Proctology *See* Rectum
Prolapse, of gastric mucosa 202 203
after ileostomy, 588–589
Prostate, carcinoma of, differential diagnosis of, 617
Prostheses, in biliary stricture repair, 393 395
in hernia repair, 120
Protein, depletion of *See* Hypoproteinemia
disorders, with colitis, 559
intolerance, after portal decompression, 294, 299
metabolism, in anesthesia, 66
Prothrombin time, defects of, 40 50
in liver disease, 281
in pancreatic disease, 420, 433
Pseudocysts, pancreatic, 414, 415, 416, 417, 421, 428–430
Pseudopolyposis, in colitis, 551, 553, 555, 561, 606, 610
Psoas abscess differential diagnosis of 127
Psychological factors in colitis, 550
Pudendal hernia, 148
Pull-through operations in rectal tumors 629 632
Pulmonary conditions *See* Respiratory tract
Purpura, idiopathic thrombocytopenic, 453 454
Pyelonephritis, after catheterization, 634
Pyloroduodenostomy in duodenal ulcer 263
Pyloromyotomy, Ramstedt 11 196–197
Pyloroplasty in duodenal ulcer 263
Pylorospasm, differential diagnosis of, 196
Pylorus, antrum in gastric secretion 244
obstruction, with duodenal ulcer, 250
in gastric carcinoma 215
in gastric ulcer, 208
ulcerogenic, 243
stenosis congenital hypertrophic, 195 197
incision for, 11 13
treatment of, 196–197
Pyoderma gangrenosum in colitis 560

Radioactive isotopes in hemolytic anemia 456
in pancreatitis 418
Radiology, cholangiography in travenous, 350 354–355
cholecystography 324
choledochogram postoperative 356–358
in colitis, 555–556
in diverticulitis of colon 594
in gastric carcinoma 213
in gastric ulcer 205 206
in intussusception 493
in pancreatitis, 404–405 417
pancreatography, 423
in retroperitoneal tumors, 521
in small bowel disorders 468–470
splenoportography 286 444 453
in trauma, nonpenetrating 159
*See also specific procedures*
Ramstedt operation for pyloric stenosis, 11, 196–197
Ravitch ileostomy, 574
Rectum, actinomycosis of, 619
adenocarcinoma of, 611
adenomatous tumors of 607 610
amebic granulomas of, 620
carcinoid tumor of, 618

Rectum (*Continued*)
carcinoma of, anaplastic, 612
colloid, 612
diffuse, 611
exophytic, 611
multiple, 605
spread of, 613–616
lymphatic drainage, 614
peritoneal, 616
regional lymph nodes, 614–615
venous channels, 615–616
squamous cell, 619
stenosing, 611, 612
ulcerating sessile, 611, 612
ileorectal anastomosis with colectomy, in polyposis, 606
leiomyosarcoma of, 619
lipogranuloma of, spontaneous 619
oleoma of, submucosal, 619
polyp of, benign, 607
carcinomatous foci in, 609
lymphoid, 618
malignant, 609
polypoid hypertrophy of mucosa, 606
polyposis, familial, 605–607
proctectomy, with sigmoid colostomy, in colitis, 566
proctocolectomy, total, with ileostomy, in colitis, 567, 575–586
resection, mortality from, 26
syphilitic lesions of, 620
tenesmus, in colitis, 554
tuberculosis of, 619
tumors of, 604–637
and colitis, 606, 610
diagnosis of, 616–620
differential diagnosis of, 617–620
etiology of, 605
incidence of, 604
pathology of, 611–613
precancerous lesions, 605–611
signs and symptoms of, 616
site of growth, 605
treatment of, 620–634
colorectal anastomosis, 632–634
Hartmann operation, extended, 622, 632
Miles operation, 621, 624–629
pull-through operations, 629–632
ulcer of, from radiation, 620
varicosities of, 618
wound of, penetrating, 166, 185, 187
Rectus muscle, relaxation incision in, 118
Reflex activity in surgery, 67–68
Regurgitation, alkaline, after duodenal ulcer surgery, 247
biliary, 367
Relaxants, muscle, 56–57
Relaxation incision, in hernia repair, 118
Renal conditions *See* Kidney
Resection, abdominoperineal, in rectal tumors, 621, 624–629
of liver, 305–308
pancreatic, subtotal, 425
*See also specific procedures*
Respiratory tract, atelectasis, postoperative, 89–90, 92 93
bronchiectasis, preoperative care in 46
bronchopulmonary disease, preoperative care in, 45–47
edema, pulmonary, postoperative, 92
embolism, pulmonary postoperative, 91–92
emphysema, pulmonary, preoperative care in, 46
pneumography, 521
pneumonectomy, mortality from, 26
pneumonia, postoperative, 90–91
pneumoperitoneum, artificial, before hernia repair, 139–140
postoperative complications in, 89–93
preoperative preparation in disorders of, 45–47
respiration control, in anesthesia, 69
in liver disease, 287
Reticuloendothelial cell sarcoma, spleen in, 455
Reticulum cell sarcoma, of small bowel, 498
Retroperitoneum, exposure of, 13, 16–17
tumors of, 519–523
diagnosis of, 521
prognosis of, 522
symptoms of, 520
treatment of, 521–522
Rhabdomyosarcoma, retroperitoneal, 521
Richter's hernia, 140
Rockey incision, 12
Rockey Elliott-Davis incision, 514
Roentgenology *See* Radiology
Rotation, abnormal intestinal, 489
Ruggi hernia repair, 129
Rupture, of appendix, 512
of corpus hemorrhagicum, differential diagnosis of, 511
Rupture (*Continued*)
of spleen, 451–452, 462
of uterus, 157, 162
*See also* Wounds, nonpenetrating

Sacrococcygeal chordoma, 533
Salpingitis, differential diagnosis of, 595
Santorini, duct of, 399
Saphenous varix, differential diagnosis of, 127
Sarcoidosis, spleen in, 452, 455
Sarcoma, gastric, 216–217
reticuloendothelial cell, spleen in, 455
of small bowel, 497
Schatzki small intestinal enema technique, 469
Schneider ileostomy, 574
Schwannoma, malignant, retroperitoneal, 521
Sciatic hernia, 147–148
Scoops, common duct, 350, 351, 352–353, 354
Scopolamine, preanesthetic, 70
Scrotal hernia, 109, 123
Secretin, effects on pancreas, 417, 418
Sedatives, postoperative, 79
preoperative, 48–49, 70
Serotonin, in argentaffin tumors, 498
from carcinoid tumor of colon, 532
Shock, in adrenal insufficiency, postoperative, 87–88
compensated, 179
in hypoproteinemia, 33–34
hypovolemic, postoperative, 87
in peritoneal contamination, 169
postoperative, 86–89
septic, postoperative, 88
transfusions in, 28
in trauma, 157, 178–179
Shunts *See* Anastomosis
Sigmoid colon *See* Colon
Skin, anatomy of, 1
care of, in fistulas, intestinal, 504
excoriation after ileostomy, 588
lesions in colitis, 559
Small intestine, 242–265, 466–507
*See also* Duodenum, Ileum and jejunum
Sodium levels after portal decompression, 293
Sounds, in small bowel obstruction, 468
Spermatic cord, in hernia repair, 118–119
lipoma of, differential diagnosis of, 110
Spherocytosis, hereditary, 454

Sphincter of Oddi, 312
Sphincterotomy, 362
in pancreatitis, 342–343, 360, 423
Spigelian hernia, 140–141
Spine anesthesia of, 57–59
differential diagnosis of lesions 169, 344
hernia, lumbar, 149–151
paravertebral lumbar block, 64
Splanchnic block, 64
*Splanchnicectomy, in pancreatitis, 425*
Spleen, 443–465
abscess of, 450–451
accessory, 446–447, 459
anatomic structure of, 443–445
congenital lesions of, 446–448
cysts of, 448–449
ectopic, 447–448
in Felty's syndrome, 456–457
and hematologic disorders, 445, 453–457
in hemolytic anemia, acquired idiopathic, 456
congenital, 454
hypersplenism, 445–446
cirrhosis with, 300–301, 302
primary, 453–455
secondary, 455–456
unclassified, 456–457
in hypoplastic anemia, 457
incision for, 19
infarction of, 450
infections of, 452, 455
lipoid storage diseases, 452, 455
neutropenia, primary splenic, 454
panhematopenia, primary splenic, 455
pathologic physiology of, 445–446
physiologic function of, 445
rupture of, *451–452, 462*
splenectomy, anesthesia in, 73
antibiotic therapy with 458
blood volume restoration in, 457
elective, 458–462
emergency, 462
gastroduodenal intubation with, 458
hemorrhage after, 300
in hypertension, portal, 282
indications for, 446–457
platelet transfusions before, 458
postoperative care in, 463
preoperative preparation for, 457–458
results of, 463–464
steroid preparation for, 457, 464
technique of, 458–462
splenic arteries, 443, 459
Spleen, splenic arteries (*Continued*)
aneurysm of, 448–450
splenic vein, 444, 459
thrombosis after splenectomy, 463, 499
splenomegaly, congestive, 455
with hypersplenism, 452
splenoportography, 286, 444, 453
splenorenal shunt, 282, 283–286, 291–292
in thrombocytopenic purpura, 453–454
tumors of, 453
vascular lesions of, 448–450
wounds of, nonpenetrating, *156, 160*
penetrating, 166, 189
Splenic arteries, 443, 459
aneurysm of, 448–450
Splenic flexure, carcinoma of, 536, 538, 539, 540
Splenic vein, 444, 459
thrombosis after splenectomy, 463, 499
Splenoportography, 286, 444, 453
Splenorenal shunt, 282, 203 286, 291–292
Sprue, 505–506
Starch tolerance test, in pancreatitis, 418
Steatorrhea, in pancreatitis, 415, 418
Stenosis, intestinal, 489
pyloric, congenital hypertrophic, 195–197
Steroid therapy, in colitis, 562
in Felty's syndrome, 457
in hemolytic anemia, acquired, 456
in pancreatitis, 410
before splenectomy, 457, 464
in thrombocytopenia, 454
Stomach, 195–241
anesthesia in surgery of, 71
antrum, in gastric secretion, 244
carcinoma of, 211 216
and anemia, pernicious, 201
complications of, 215
diagnosis of, 212–213
differential diagnosis of, 213–214
etiology of, 211
hemorrhage with, 215
incidence of, 211
metastatic scirrhous, differential diagnosis of 617
pain in, 205
pathology of, 211–212
perforation of, 215
prognosis of, 214–215
pyloric obstruction with, 215
symptoms of, 212
treatment of, 215–216
Stomach, carcinoma of (*Continued*)
and ulcers, 204, 207, 211
cholecystogastrostomy, 350, 359
congenital anomalies of, 195–198
decompression, 79, 93, 337–338
after wound surgery, 190
dilatation, postoperative, 93
diverticula of, 197–198
gastrectomy, 218–226
in carcinoma, 215, 222
complications of, 228 230
incision for, 20
mortality from, 26
in prolapse of gastric mucosa, 203
proximal, complications of, 237
postoperative care in 237
subtotal, 232–235
total, 236
subtotal, dissection of duodenum, 255–257
dissection of stomach, 254
in duodenal ulcer, 252, 253–260
gastroduodenostomy with, 260
gastroenterostomy, 258–260
ligation of left gastric artery, 256, 257–258
in pancreatitis, 424
proximal, 232–235
total, 224–226
proximal, 236
in ulcers, 220
gastritis, 200–202
acute, 200
atrophic, 201
chronic, 201
corrosive, 200
hypertrophic, 201
infectious, 200
necrotizing, 201
phlegmonous, 200
simple, 200
gastrocolic ligament, 444, 459
gastroduodenal intubation in splenectomy, 458
gastroduodenostomy with gastrectomy, subtotal, 260
gastroenteritis, differential diagnosis of, 511
gastroenterostomy, 226–228, 258–260, 262
anesthesia for, 72
marginal ulcer after, 251
gastroepiploic artery, 443
gastroileostomy, after gastrectomy, 229–230
gastrojejunocolic fistula, duodenal ulcer with, 251–253

Stomach (*Continued*)
gastrojejunostomy, in pancreatitis, 424
gastrosplenic ligament, 444, 459
gastrostomy, anesthesia for, 72
feeding mixture for tubes, 38
in gastric decompression, 338
hourglass, 208
incision for, 15, 19
lavage, preoperative, 50–51
physiology of, 244–246
prolapse of mucosa, 202–203
proximal lesions, 230–239
pyloroduodenostomy, in duodenal ulcer, 263
pyloromyotomy, Ramstedt, 11, 196–197
pyloroplasty, in duodenal ulcer, 263
pylorospasm, differential diagnosis of, 196
pylorus, obstruction of, with duodenal ulcer, 250
in gastric carcinoma, 215
in gastric ulcer, 208
ulcerogenic, 243
stenosis, congenital hypertrophic, 195–197
incision for, 11, 13
treatment of, 196–197
reservoir function loss after duodenal ulcer surgery, 246
sarcoma of, 216–217
surgical techniques, 218–230
anesthesia in, 71
incision for, 15, 19
in pancreatitis, 424
tumors of, benign, 208–211
malignant, 211–217
ulcers, 203–208
complications of, 207–208
diagnosis of, 205–206
differential diagnosis of, 197, 206–207, 214
etiology of, 203–204
hemorrhage with, 207
hourglass stomach with, 208
incidence of, 203
malignancy of, 204, 207, 211
pathology of, 204
perforation of, 207
closure of, 260, 261
after portal decompression, 295
prognosis of, 207
pyloric obstruction with, 208
symptoms of, 205
treatment of, 208
vagotomy, 228
volvulus, 198–200
wounds of, nonpenetrating, 157, 161
penetrating, 166, 183
Stone operation for umbilical hernia, 134
Strangulated hernia, 153–154
Stricture, biliary, 363–398
cardial, gastric aspects of, 238
in colitis, ulcerative, 560, 564
of colon, in diverticulitis, 596
after gastrectomy, proximal 237–238
String sign, in regional ileitis 470, 496, 558
Subcutaneous tissue anatomy, 1
Succinylcholine, 56
in liver disease, 287
Suction *See* Aspiration
Sunital anesthesia, 55
Sutures, 136
Albert, 480
Connell, 480
Cushing, 477, 480
far-and near, 136, 137
in hernia repair, 124
for incision closure, 22–23
intestinal, 476, 479–482
Lembert, 233, 234, 235
interrupted, 477, 480
in peritoneum closure in wound surgery, 183
Sympathicoblastoma, retroperitoneal, 521
Syncurine, as muscle relaxant, 56
Syphilitic lesions, of colon, differential diagnosis of, 558
of liver, 278
of rectum, 620

Tamponade, pneumatic in variceal hemorrhage, 279 280
Tantalum gauze, in hernia repair, 120–121
Tenesmus, rectal, in colitis, 554
Teratoma, retroperitoneal, 521
Testicle removal, in hernia repair, 119
Tetracaine anesthesia, 61
Thiamylal anesthesia, 55
Thiopental anesthesia, 55–56
Thoracoabdominal incision, 18–21
Throckmorton method of hernia repair, 152
Thrombocytopenic purpura, 453 454
blood volume deficit in, 457
platelet transfusions in, 458
Thrombophlebitis, in colitis, 560
postoperative, 101, 102–103
Thrombosis, mesenteric artery, 499
portal, 278, 279
splenic vein, after splenectomy, 463, 499
venous, postoperative, 101–104
Thyroidectomy, mortality from, 26
Toxemia, in colitis, 564
Tracheobronchial suction, postoperative, 90
Tranquilizers, preoperative, 48, 70
Transfusions, 27–32
*See also under* Hematology
Trauma *See* Wounds
Tube, Cantor, 471
endotracheal, 68, 69
gastric, indwelling, 80
lavage, 50–51
Grafton-Smith, 471
Harris, 471
intestinal, 470, 471
in carcinoma of colon, 536, 544
Johnston, 471
Levin, 471
Miller-Abbott, 470–472
nasogastric feedings, 37–38
*See also* Aspiration, Catheterization, Drainage, Decompression
Tuberculosis, of liver, 278
pulmonary, pancreatitis with, 419
of rectum, 619
of small intestine, 496
of spleen, 452, 455
Tubocurarine, 56
in liver disease, 287
Tumor, adrenal gland, differential diagnosis of, 344
of ampulla of Vater, 437
of anus, 637–638
of appendix, 517
biliary tract, differential diagnosis of, 373
of colon, 525–545
of duodenum, 264
islet cell, 437–441, 497
of liver, 304–308
of mesentery, 520, 521, 523–524
metastasis of *See* Metastasis
of omentum, 520, 521, 523–524
of pancreas, 431–441
pelvic, incision for, 17–18
of rectum, 604–637
of retroperitoneum, 519–523
of small bowel, 497–502
operative approach to, 499, 500
of spleen, 453
of stomach, benign, 208–211
malignant, 211–217
*See also specific tumors*
Turnbull mucosal graft in ileostomy, 568–571
Typhoid ulcers, in ileum, 496

Ulcer, cardial, gastric aspects of, 238
differential diagnosis of, 327
duodenal, 242–244

Ulcer (*Continued*)
gastric, 203–208
*See also* Stomach
marginal, 251
peptic, differential diagnosis of, 344
and islet cell tumor, 439–441
of jejunum 497
pancreatitis with, 419
radiation, of rectum 620
typhoid in ileum, 496
Ulcerative colitis *See* Colitis, ulcerative
Umbilicus, cysts of, removal of 492
sebaceous differential diagnosis of, 131
fistula of, 491
hernia of, 130–134
Urachal cyst differential diagnosis of, 131
Ureter incision for, 17
wounds of, penetrating 166, 187
Urinary tract, infection of, differential diagnosis of 511
postoperative complications in 634
Urination postoperative, 79
Urobilinogen 312, 367
Uterus, rupture of, 157 162
wounds of penetrating 188

Vagina, hernia of 148
preoperative preparation of, 51
Vagotomy 228
anesthesia for, 72
in colitis 586
in duodenal ulcer 260–262
in pancreatitis 424
peptic ulcer after, 243
test for completeness of 245
Varices, esophagogastric 278–304
of rectum 618
saphenous differential diagnosis of 127
Vascular conditions *See* Blood vessels
Vasoconstrictors, with anesthetics, 58, 61, 62
Vater, ampulla of, tumors of, 437
Veins *See* Blood vessels *and specific veins*
Vena cava caval superior mesenteric shunts, 283–286, 292
incision for, 20
portacaval shunts, 280, 283–286
wounds of, penetrating, 190
Vitamins, deficiencies of 40–41
therapy, in pancreatic disease, 420, 433, 436
Vitellointestinal duct, persistent, 490, 502
Volvulus, of colon, 545–547
of small intestine, 488
of stomach, 198–200
Vomiting and regurgitation, in anesthesia, 68–69
in appendicitis, 510
in cholecystitis, 323
in colitis, 554
gastric lavage for, 58–51
in intestinal obstruction, 482
in pancreatitis 404
in small bowel disease, 467
in trauma, 178
von Petz clamp, 221

Walters excision of gastric diverticula, 198
Weight, loss of, blood volume in, 35
in colitis, 554
nutritional deficiency in, 36
in pancreatic carcinoma, 432
in pancreatitis, 416, 419
obese patients, 13, 22, 23
and diverticulitis of colon 592, 596
and pancreatitis, 416
Weir incision, 12
Whipple's disease, 505
Whipple's triad, 438
Wirsung duct of, 399
Witzel enterostomy, 485, 486
Wounds, biliary stricture from, 364–366
closure of, 21–23
delayed, 185–106
dehiscence of, 9, 11, 13, 21, 23, 26, 184–106, 635
anesthesia in resuturing for, 75
healing of, hypoproteinemia delaying, 33
perineal, delayed, 635
mass casualties, 191–192
nonpenetrating, 156–163
bile ducts, 157, 161
bladder, 157, 162
diagnosis of, 157, 158–168
diaphragm, 157, 162
etiology of, 156
gastrointestinal tract, 157, 161
history in, 157
kidney, 156, 162
laboratory aids, 158
liver, 156, 160, 271
pancreas, 157, 161
physical findings in, 157–158
Wounds, nonpenetrating (*Continued*)
sites of, 156–157
spleen, 156, 160
treatment of, 160–162
uterus, 157, 162
pancreatitis from, 413
penetrating, 164–194
adrenal glands, 189
antibiotics in, 191
aorta abdominal, 190
bladder, 187
buttocks, 187
cecum, 184–185
colon, 184–187
complications of, 173–175
diagnosis of, 168–170
duodenum, 183
etiology of, 165
fallopian tubes, 188
gallbladder, 184
gastric decompression in 190
incidence of, 164–165
initial management of, 175–179
intravenous alimentation in 191
kidney, 187
liver, 188, 271
moving of patients, 190
nursing care in, 191
operative management of, 179–183
anesthesia in, 180–181
exploratory laparotomy, 181–183
principles of surgery, 180
timing of operation, 179
ovaries, 188
pancreas, 189
pathology of, 166–168
postoperative management of, 190–191
prognosis of, 170–172
rectum, 185, 187
signs and symptoms of, 168
small bowel, 184
spleen, 189
stomach, 183
ureter, 187
uterus, 188
vena cava, 190
postoperative complications of, 104–106, 636
splenic rupture, 451

Xanthogranuloma, of retroperitoneum, mesentery and omentum, 520
Xylocaine anesthesia, 61

Zimmerman hernia repair, 130
Zollinger Ellison syndrome, 497